



Original Article

Terrible triad of the elbow: evaluation of surgical treatment[☆]



José Antonio Galbiatti^a, Fabrício Luz Cardoso^{a,*}, James Augusto Soares Ferro^b, Rafael Cassiolato Garcia Godoy^b, Sérgio de Oliveira Bruno Belluci^b, Evandro Pereira Palácio^c

^a Faculdade de Medicina de Marília (FAMEMA), Marília, SP, Brazil

^b Departamento de Ortopedia e Traumatologia, Santa Casa de Misericórdia de Marília, Marília, SP, Brazil

^c Faculdade de Medicina, Universidade Estadual Paulista, Botucatu, SP, Brazil

ARTICLE INFO

Article history:

Received 28 March 2017

Accepted 19 May 2017

Available online 11 June 2018

Keywords:

Radial fractures

Elbow joint

Dislocations

Orthopedics

ABSTRACT

Objective: This study aims at analyzing retrospectively the clinical-functional and radiographic results of surgical treatment of the terrible elbow triad, with at least 12 months of postoperative follow-up evaluating elbow function.

Methods: A group of patients for retrospective analysis from 2004 to 2015 was defined, in which 12 patients were studied. They underwent surgery due to fracture of the radial head, coronoid fracture, and elbow dislocation; they were evaluated by the Disabilities of the Arm, Shoulder and Hand (DASH) score, the degree of patient satisfaction, the degree of trauma energy, radiographic images, range of motion, and complications.

Results: There was a higher incidence of Regan and Morrey type II coronoid process fractures; in relation to the injuries, nine patients had deinsertion of the brachialis. Half of the patients suffered a fall from their own height as the mechanism of trauma. The extent of elbow flexion and extension averaged 126.6 and 24.1 degrees, respectively; the averages for pronation and supination were 64.1 and 62.0 degrees, respectively. All patients presented muscle strength of grade IV or V. The mean DASH score was 14.3, the mean pain score was 2.5, and a majority of the patients were satisfied with the treatment.

Conclusion: Despite the total loss of range of motion of the elbow, especially in extension, the treatment was satisfactory for most patients.

© 2018 Sociedade Brasileira de Ortopedia e Traumatologia. Published by Elsevier Editora Ltda. This is an open access article under the CC BY-NC-ND license (<http://creativecommons.org/licenses/by-nc-nd/4.0/>).

[☆] Study conducted at Departamento de Ortopedia e Traumatologia, Santa Casa de Misericórdia de Marília, Marília, SP, Brazil.

* Corresponding author.

E-mail: fabricioramalhense@gmail.com (F.L. Cardoso).

<https://doi.org/10.1016/j.rboe.2018.05.012>

2255-4971/© 2018 Sociedade Brasileira de Ortopedia e Traumatologia. Published by Elsevier Editora Ltda. This is an open access article under the CC BY-NC-ND license (<http://creativecommons.org/licenses/by-nc-nd/4.0/>).

Tríade terrível do cotovelo. Avaliação do tratamento cirúrgico

R E S U M O

Palavras-chave:

Fraturas do rádio
 Articulação do cotovelo
 Luxações
 Ortopedia

Objetivo: Este estudo tem o objetivo de analisar, retrospectivamente, os resultados clínico-funcionais e radiográficos do tratamento cirúrgico da tríade terrível do cotovelo, com no mínimo doze meses de acompanhamento pós-operatório, avaliando a função do cotovelo. **Métodos:** Definimos um grupo de pacientes para avaliação retrospectiva no período de 2004 a 2015, no qual foram estudados 12 pacientes, submetidos a procedimento cirúrgico devido a fratura da cabeça do rádio, fratura do processo coronoide e luxação do cotovelo; sendo avaliados pelo escore Disabilities of the Arm, Shoulder and Hand (DASH), grau de satisfação do paciente, grau de energia do trauma, radiografias, arco de movimento e complicações. **Resultados:** Observou-se maior incidência de fraturas do processo coronoide do tipo II de Regan e Morrey; em relação às lesões, nove pacientes apresentaram desinserção do músculo braquial. Metade dos pacientes apresentou queda da própria altura como mecanismo de trauma. Os graus de flexão e extensão do cotovelo tiveram respectivamente as médias: 126,6 e 24,1 graus; e as médias em graus de pronação e supinação foram respectivamente: 64,1 e 62,0 graus. Todos os pacientes apresentaram grau de força muscular IV ou V. Obtivemos escore DASH médio de 14,3, a escala de dor teve média de 2,5, e a maioria dos pacientes se disse satisfeita com o tratamento.

Conclusão: Apesar da perda de amplitude total de movimento do cotovelo, principalmente em extensão, o tratamento mostrou-se satisfatório para a maioria dos pacientes.

© 2018 Sociedade Brasileira de Ortopedia e Traumatologia. Publicado por Elsevier Editora Ltda. Este é um artigo Open Access sob uma licença CC BY-NC-ND (<http://creativecommons.org/licenses/by-nc-nd/4.0/>).

Introduction

The terrible triad described by Hotchkiss is the combination of elbow dislocation associated with radial head fracture and coronoid process fracture; it is notoriously difficult to treat¹ (Fig. 1).

Load transmission and contact between the radial head and the capitulum of the humerus is constant, occurring at any angle of extension and flexion of the elbow and at any forearm rotation, being greater in extension.²⁻⁴

Radial head fractures comprise approximately 30% of all adult elbow fractures,⁵ and are frequently associated with injuries to soft tissues and to the annular, medial, and lateral collateral ligaments, as well as with coronoid process fracture.^{2,6}

This type of elbow injury occurs during a fall with the arm extended in supination, when valgus stress, axial load, and a posterolateral rotational force are generated, typically due to the energy of the trauma,^{2,7} resulting in failure of the lateral collateral ligament complex (LCL) and sometimes of the medial collateral ligament (MCL) – the latter structure being the last one to be injured.⁸

Making a correct diagnosis is difficult, but paramount, as early treatment has a positive influence on prognosis.⁹

As a result of these injuries, the elbow becomes unstable and requires surgical intervention. Unfortunately, due to the complexity of the injury, conservative treatment is risky; the long-term complications include stiffness, pain, joint instability, and secondary arthrosis.¹⁰

The goal of surgical treatment of the terrible triad of the elbow is the restoration of humeroulnar and humeroradial

stability, thus facilitating the early onset of elbow movement in the postoperative period in order to reduce the probability of long-term joint dysfunction and stiffness.¹¹

This study is aimed at evaluating retrospectively the clinical results of patients with the terrible triad of the elbow who underwent surgical treatment with at least 12 months of follow-up.

Materials and methods

Patients with the terrible triad of the elbow, surgically treated in the period from 2004 to 2015 by two orthopedic surgeons, upper limb specialists, were retrospectively evaluated in the orthopedic and traumatology department of an upcountry city of Brazil. Diagnostic confirmation was achieved by examining anteroposterior, lateral, and occasionally oblique view radiographs; when necessary, due to associated lesions, computed tomography and/or magnetic resonance imaging of the affected elbow was performed.

The inclusion criteria were patients who underwent a surgical procedure to treat the terrible triad of the elbow, with age over 18 years, who agreed to participate and signed the Informed Consent Form, and who answered a previously prepared questionnaire.

The exclusion criteria were: inability to locate the patients for re-evaluation and presence of open fractures, pediatric fractures, isolated coronoid fractures, and isolated radial head fractures.

The patients were numbered chronologically according to the date of the surgical treatment by the orthopedists of the medical residency.

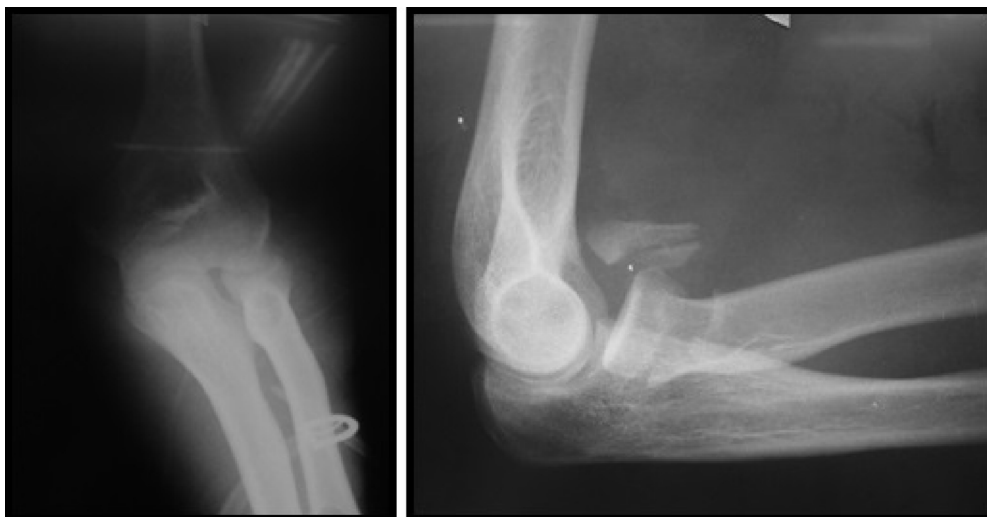


Fig. 1 – Radiographs showing the terrible triad of the elbow.

Fractures were analyzed radiographically and classified according to the degree of injury:

- Radial head fracture was classified in accordance with Mason modified by Johnston⁵
- Coronoid process fracture was classified in accordance with Regan and Morrey¹²

All postoperative files and radiographs were analyzed by two surgeons, upper limb specialists and by two resident physicians in orthopedics and traumatology. The anterior and lateral views of the elbow were evaluated to verify associated complications, such as heterotopic ossification, malunion, osteoarthritis, infection, ligamentous calcification, pseudarthrosis, and bone sclerosis around the synthesis material.¹³

Excel Office 2010 and Word 2010 softwares were used for data organization, and a statistical analysis of the weighted means was performed for the following variables: gender, affected side, trauma mechanism, associated injuries, trauma energy degree, type of fracture, degree of satisfaction, immobilization time, follow-up time, and postoperative pain.

The operated limb and the contralateral limb were compared using the Disabilities of the Arm, Shoulder and Hand (DASH) score and functional range of motion (ROM) in accordance with the criteria by Morrey; elbow flexion and extension strength was assessed using a specific muscle strength scale.^{7,8,14}

Pain was assessed using a visual analog scale (VAS)¹⁵; based on this scale, patient satisfaction in relation to the treatment was classified from 0 to 10 points, where 0 to 2.5 corresponded to poor; 2.6 to 5, fair; 5.1 to 7.5, good; and from 7.6 to 10, excellent. Furthermore, patients were directly asked whether they were satisfied or dissatisfied with the outcome of the treatment.

All patients were anesthetized to allow limb exsanguination and placement of a tourniquet on the upper end of the arm. A locoregional brachial plexus block was associated with

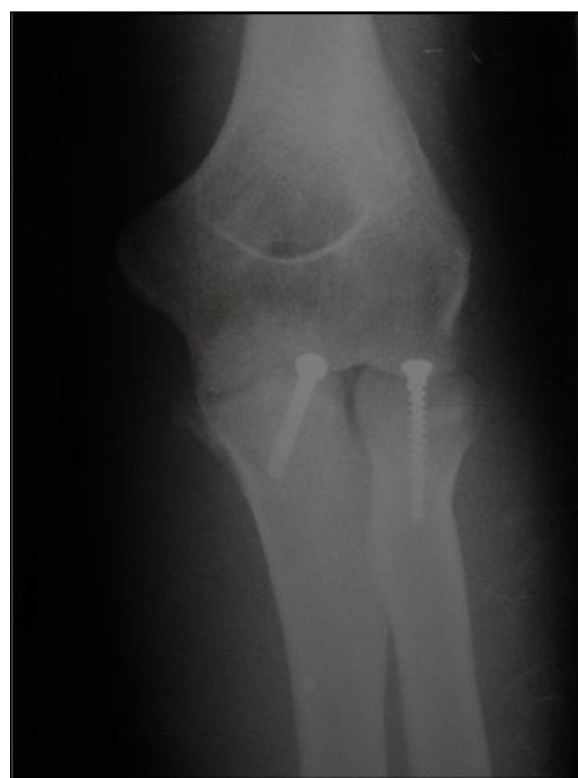

Fig. 2 – Osteosynthesis of the radius and proximal ulna.

general anesthesia and the patient was positioned in a horizontal recumbent decubitus. Antisepsis was performed with alcoholic chlorhexidine; then, a posterolateral approach was used to access the radial head, the coronoid process fracture that was repaired if possible, and also, when necessary, osteosynthesis of the proximal ulna (Fig. 2). In cases of medial instability, a medial approach isolating the ulnar nerve was used to repair lesions of the medial ligament complex of

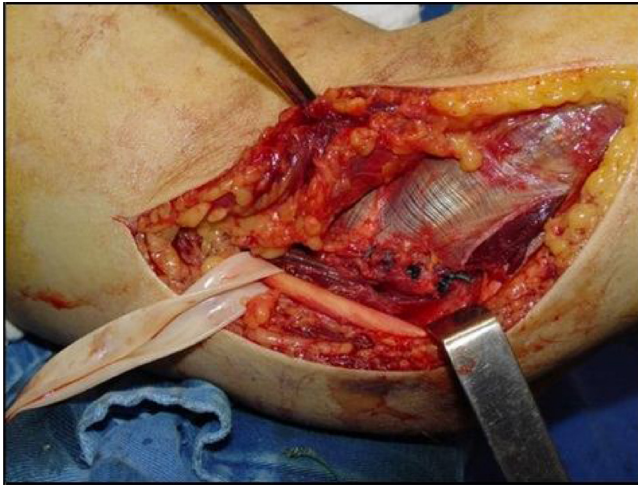


Fig. 3 – Medial incision of the elbow, isolation of the ulnar nerve, and repair of the medial collateral ligament.

the elbow (Fig. 3). Two patients presented a physical examination compatible with medial collateral ligament injury; in these cases, the injury was not observed during intraoperative examination, demonstrating the integrity of the medial ligament complex.

The surgical treatment entailed complete resection of the radial head and placement of classic titanium radial head prostheses, except for two patients, in which osteosynthesis of the radial head was performed. Ligament injuries were repaired with anchors and reinsertion of the brachialis muscle; in one patient, the coronary process was secured with a Herbert screw.

Regarding surgical treatment, the time of immobilization in the postoperative period ranged from 20 to 27 days, with a mean of 22.7 days, and the follow-up time ranged from three to 12 months, with a mean of six months (Table 1).

Regarding the postoperative period, all patients were immobilized for a short period, approximately two or three weeks; the immobilization was discontinued early based on

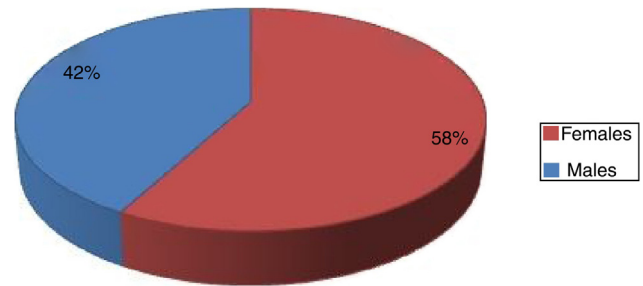


Fig. 4 – Prevalence of cases in relation to gender.

clinical and radiographic evaluations, in order to avoid complications inherent to joint immobilization.

This study was approved by the institutional research ethics committee.

Results

The authors selected a group of patients for retrospective evaluation in the period from 2004 to 2015, in which 15 medical records were retrieved; patients were invited to a clinical and functional evaluation and answered a questionnaire. All patients underwent surgical procedures due to radial head fracture, coronoid process fracture in most cases, and elbow dislocation. The total number of patients was 15; of this total, only 12 were located and returned for reassessment in the orthopedics and traumatology department.

Patient age ranged from 27 to 91 years, with a mean of 48.9 years. When stratifying by gender, the age of the female patients ranged from 27 to 91 years, with a mean of 56 years, while the age of the male patients ranged from 30 to 46 years, with a mean of 39 years. In relation to gender, five patients were males and seven, females (Fig. 4).

Six patients presented right side involvement and six, left; in females, the right was the most often involved and in males, it was the left side. When the injury side was associated with the profession of the patients, it was observed that of the

Table 1 – Surgical treatment vs. immobilization time vs. follow-up time.

Order No.	Surgical treatment	Immobilization time	Follow-up time
1	Radial head prosthesis + brachialis muscle reinsertion	7 days	3 months
2	Radial head prosthesis + lateral collateral repair (3.5-mm anchor) + brachialis muscle reinsertion	5 days	6 months
3	Radial head prosthesis + lateral collateral repair (3.5-mm anchor) + brachialis muscle reinsertion	7 days	1 year
4	Radial head osteosynthesis + lateral collateral repair (3.5-mm anchor) + brachialis muscle reinsertion	14 days	6 months
5	Radial head prosthesis + medial collateral repair (3.5-mm anchor) + brachialis muscle reinsertion	10 days	10 months
6	Radial head prosthesis	7 days	8 months
7	Radial head osteosynthesis + lateral collateral repair (3.5-mm anchor)	14 days	6 months
8	Radial head prosthesis + coronoid process fixation with one Herbert screw	5 days	6 months
9	Radial head prosthesis + four 4-mm anchors + brachialis muscle reinsertion	7 days	3 months
10	Radial head prosthesis + medial collateral repair (3.5-mm anchor) + brachialis muscle reinsertion with two 3.5-mm anchor	7 days	5 months
11	Radial head prosthesis + brachialis muscle reinsertion	2 days	3 months
12	Proximal radial head prosthesis + brachialis muscle reinsertion	7 days	4 months

Table 2 – ROM of the affected limb vs. trauma energy vs. satisfaction vs. DASH score.

Patient	Elbow flexion/extension	Forearm pronation/supination	Trauma energy	Satisfaction	DASH score
1	Flexion 130/extension 20	70/60 degrees	Low	Satisfied	12.3
2	Flexion 135/extension 30	60/60 degrees	High	Satisfied	15.4
3	Flexion 125/extension 30	65/65 degrees	Low	Satisfied	16.5
4	Flexion 135/extension 10	70/70 degrees	Low	Satisfied	10.3
5	Flexion 120/extension 30	65/55 degrees	High	Dissatisfied	15.1
6	Flexion 130/extension 25	60/60 degrees	High	Satisfied	12.1
7	Flexion 120/extension 20	60/55 degrees	High	Dissatisfied	13.4
8	Flexion 135/extension 25	75/70 degrees	High	Satisfied	14
9	Flexion 110/extension 40	50/55 degrees	Low	Satisfied	19.9
10	Flexion 135/extension 15	70/70 degrees	High	Satisfied	12.4
11	Flexion 130/extension 15	65/70 degrees	Low	Satisfied	11.9
12	Flexion 115/extension 30	60/55 degrees	Low	Satisfied	18.6

ROM, range of motion; DASH, Disabilities of the Arm, Shoulder and Hand score.

women, four were housewives (right side), one was a teacher (left side), one a saleswoman (right side), and one a public employee (left side); as for the men, one was a systems analyst (left side), one a bricklayer (left side), one a commercial manager (left side), one a physician (left side), and one case did not report his profession (right side).

According to Mason's classification, modified by Johnston⁵ (radial head fractures), one patient presented type I fracture; two patients, type II; one patient, type IV fracture; and eight patients presented type IV fracture with the presence of radial head comminution and dislocation.

According to the classification of Regan and Morrey¹² (coronoid process fractures), three patients presented type I fractures and nine, type II; regarding the associated injuries, nine patients presented brachialis muscle disinsertion, of whom five had instability of the lateral collateral ligament of the elbow and three had deinsertion of the brachialis muscle with instability of the medial collateral ligament of the elbow.

Regarding the trauma mechanism, a fall from their own height was observed in six patients, a fall from a bicycle in one patient, a fall from a motorcycle in one patient, a fall from a roof in two patients, and a car accident in two patients. The time between trauma and surgery ranged from one to 18 days, with a mean of 8.5 days.

Table 2 presents data related to degrees of elbow flexion, and extension, forearm pronation and supination, trauma energy, degree of satisfaction, and DASH score.

On clinical-functional evaluation, the degree of flexion and extension of the elbow was evaluated; flexion ranged from 110 to 135 degrees (Fig. 5), with a mean of 126.6 degrees, and extension ranged from 10 to 40 degrees, with a mean of 24.1 degrees (Fig. 6). Pronation (Fig. 7) and supination of the ipsilateral forearm (Fig. 8) were also assessed, with pronation ranging from 50 to 75 degrees, with a mean of 64.1 degrees, and supination ranging from 55 to 70 degrees, with a mean of 62.0.

Regarding muscle strength, five patients had grade IV strength and seven patients, grade V; the same criterion was used to assess the grip of the ipsilateral hand, in which six patients had grade IV and six patients, grade V.

As to pain, scores ranged from 0 to 9, with a mean of 2.4. Patient's satisfaction with treatment ranged from 8 to 10, with a mean of 9.1; patients were satisfied with the outcome of the treatment, with the exception of two patients.¹⁵

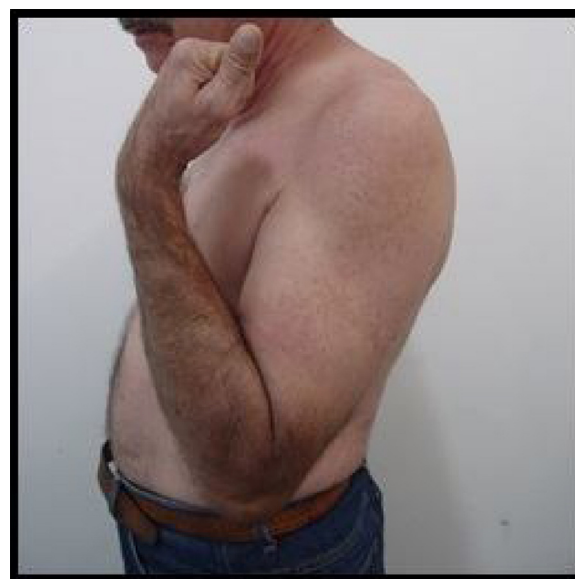

Fig. 5 – Elbow flexion.

For radiographic evaluation of the studied patients, antero-posterior view in maximum extension and 90-degree lateral view radiographs were done. The radiographs indicated some complications: one patient had osteoarthritis, two patients presented heterotopic calcification, one patient presented radiolucency around the prosthesis, and eight patients did not present radiographic changes.¹⁶⁻¹⁸

Discussion

Although some recent studies have reported good results with conservative treatment for the terrible triad of the elbow, certain criteria have to be met in order to choose said treatment, such as degree of joint reduction (humero-ulnar distance <4 mm on the elbow lateral view), a radial head fracture that does not hinder pronation-supination of the forearm, small fracture of the coronoid process (Regan and Morrey type I or II), and a stable elbow range of motion of at least 30 degrees of extension in the first ten days of injury.^{8,19}

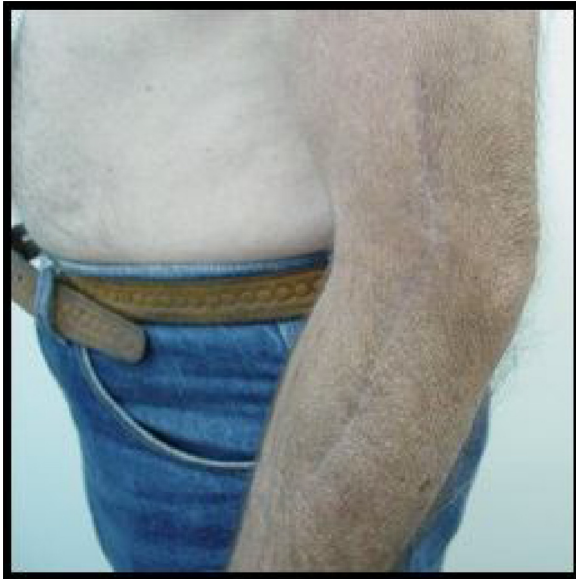

Fig. 6 – Elbow extension.

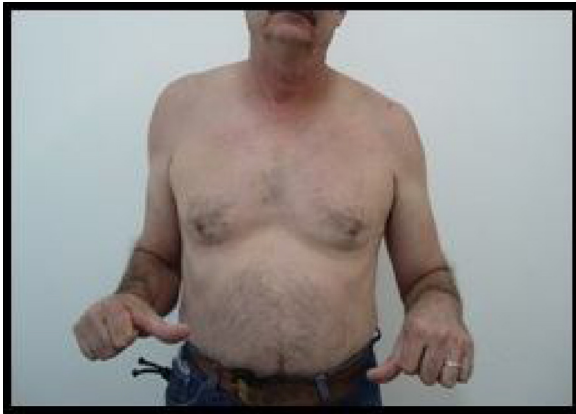

Fig. 7 – Forearm pronation.

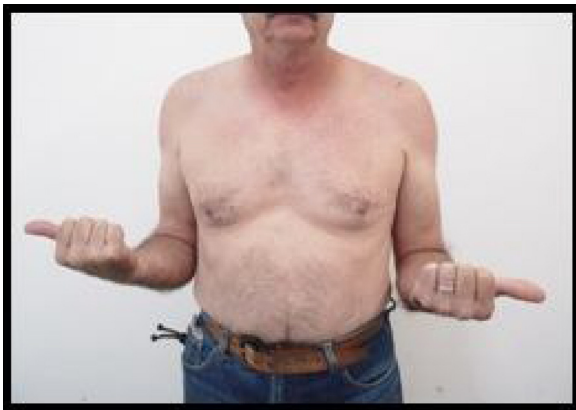


Fig. 8 – Forearm supination.

According to Chan et al.,¹³ intense clinical radiographic monitoring is necessary to monitor any subluxation, consolidation delay, and fracture displacement.

Most patients had satisfactory functional results with surgical treatment, but more research is needed to determine which surgical technique would optimize functional outcomes in order to reduce the number of complications.^{11,18}

In the present study, the mean age was approximately 48.9 years for males and females, with a predominance of females (58% vs. 42% males), which is not in agreement with the slight predominance of males in relation to females reported in the literature.^{12,20}

Regarding the affected limb, a homogeneous involvement was observed: 50% of the cases in the right upper limb and 50% in the left upper limb; the left side was predominant in males, while the right side was predominant in females. The degree of energy from the trauma was also homogenous: 50% were classified as high-energy and 50%, as low-energy, conflicting with reports in the literature, in which the most common trauma mechanism is high-energy trauma.^{7,8}

Coronoid process fracture was present in 75% of the cases; Regan and Morrey type II was the most prevalent, accounting for 66.6% of cases. Surgical treatment is recommended for Regan and Morrey types II and III.^{6,19,20}

Of the patients evaluated, 66.6% presented no complications, 16.6% had heterotopic ossification, 8% had osteoarthritis, and 8% had osteolysis around the radial head prosthesis observed on radiographs.

Heterotopic ossification and osteoarthritis are among the most common complications that do not require surgical treatment.^{21,22}

A new surgical treatment was not necessary in any case of the present study, contrasting with the reoperation data in the literature (about 12.5% of patients).^{11,19}

In the present study, good postoperative results were observed. The mean DASH score was 14.3, and 83.4% of the patients were satisfied with the treatment; unsatisfactory outcomes were related to high-energy trauma.

Conclusion

It was concluded that, despite the loss of total range of motion of the elbow, mainly in extension, the treatment was satisfactory for most patients.

Conflicts of interest

The authors declare no conflicts of interest.

Acknowledgments

The authors would like to thank the Santa Casa de Misericórdia de Marília and the Medical School of Marília for the support needed to conduct this study.

REFERENCES

1. Hebert S, Barros Filho TEP, Xavier R, Pardini Junior AG. organizadores. *Ortopedia e traumatologia: princípios e pratica*. 4ª ed. Porto Alegre: Artmed; 2009.
2. Mathew PK, Athwal GS, King GJ. Terrible triad injury of the elbow: current concepts. *J Am Acad Orthop Surg*. 2009;17(3):137-51.
3. Morrey BF, Chao EY, Hui FC. Biomechanical study of the elbow following excision of the radial head. *J Bone Joint Surg Am*. 1979;61(1):63-8.
4. Barbieri CH, Mazzer N, Madureira W. Fraturas da cabeça do rádio: revisão de 52 casos. *Rev Bras Ortop*. 1998;33(12):973-81.
5. Johnston GW. A follow-up of one hundred cases of fracture of the head of the radius with a review of the literature. *Ulster Med J*. 1962;31:51-6.
6. Chen HW, Liu GD, Wu LJ. Complications of treating terrible triad injury of the elbow: a systematic review. *PLOS ONE*. 2014;9(5):e97476.
7. Beingsner DM, Pollock JW, King GJW. Elbow fractures and dislocations. In: Court-Brown CM, Heckman JD, McQueen MM, Ricci W, Tornetta P 3rd, editors. *Rockwood and Green's fractures in adults*. 8th ed. Philadelphia: Williams & Wilkins; 2015. p. 1214-6.
8. Andrew H, Crenshaw JR. Surgical techniques and approaches. In: Canale ST, Beaty J, editors. *Campbell's operative orthopaedics*. 12th ed. Philadelphia: Mosby; 2013. p. 106-9.
9. Miyazaki AN, Checchia CS, Fagotti L, Fregoneze M, Doneux Santos P, da Silva LA, et al. Avaliação dos resultados do tratamento cirúrgico da tríade terrível do cotovelo. *Rev Bras Ortop*. 2014;49(3):271-8.
10. Santos AA, Tonelli TA, Matsunaga FT, Matsumoto MH, Archetti Netto N, Tamaoki MJS, et al. Resultado do tratamento cirúrgico da tríade terrível do cotovelo. *Rev Bras Ortop*. 2015;50(4):403-8.
11. Gomide LC, Campos DO, de Sá JM, de Sousa MRP, do Carmo TC, Andrada FB, et al. Tríade terrível do cotovelo: avaliação do tratamento cirúrgico. *Rev Bras Ortop*. 2011;46(4):374-9.
12. Regan W, Morrey B. Fractures of the coronoid process of the ulna. *J Bone Joint Surg Am*. 1989;71(9):1348-54.
13. Chan K, MacDermid JC, Faber KJ, King GJ, Athwal GS. Can we treat select terrible triad injuries nonoperatively? *Clin Orthop Relat Res*. 2014;472(7):2092-9.
14. Motta Filho GR, Cotovelo. In: Barros Filho TEP, Lech O, editors. *Exame físico em ortopedia*. 2ª ed. São Paulo: Sarvier; 2002. p. 138-46.
15. Summers S. Evidence-based practice part 2: reliability and validity of selected acute pain instruments. *J Perianesth Nurs*. 2001;16(1):35-40.
16. Forthman C, Henket M, Ring DC. Elbow dislocation with intra-articular fracture: the results of operative treatment without repair of the medial collateral ligament. *J Hand Surg Am*. 2007;32(8):1200-9.
17. Pugh DM, Wild LM, Schemitsch EH, King GJ, McKee MD. Standard surgical protocol to treat elbow dislocations with radial head and coronoid fractures. *J Bone Joint Surg Am*. 2004;86(6):1122-30.
18. Chemama B, Bonneville N, Peter O, Mansat P, Bonneville P. Terrible triad injury of the elbow: how to improve outcomes? *Orthop Traumatol Surg Res*. 2010;96(2):147-54.
19. Giannicola G, Calella P, Piccioli A, Scacchi M, Gumina S. Terrible triad of the elbow: is it still a troublesome injury? *Injury Int J Care*. 2015;46:S68-76.
20. Leigh WB, Ball CM. Radial head reconstruction versus replacement in the treatment of terrible triad injuries of the elbow. *J Shoulder Elbow Surg*. 2012;21(10):1336-41.
21. Foruria AM, Augustin S, Morrey BF, Sánchez-Sotelo J. Heterotopic ossification after surgery for fractures and fracture-dislocations involving the proximal aspect of the radius or ulna. *J Bone Joint Surg Am*. 2013;95(10):e66.
22. Wiggers JK, Helmerhorst GT, Brouwer KM, Niekel MC, Nunez F, Ring D, et al. Injury complexity factors predict heterotopic ossification restricting motion after elbow trauma. *Clin Orthop Relat Res*. 2014;472(7):2162-7.