



Case Report

A rare case of bilateral central subluxation of the hip joint with associated bilateral quadrilateral plate fracture in an elderly male due to seizure activity



Kiran Makwana^a, Mayank Vijayvargiya^a, Nitesh Agarwal^a, Ketan Desai^b, Vivek Shetty^{a,*}

^a Department of Orthopaedics, P.D. Hinduja National Hospital, Mumbai, India

^b Department of Neurosurgery, P.D. Hinduja National Hospital, Mumbai, India

ARTICLE INFO

Article history:

Received 20 December 2016

Accepted 23 January 2017

Available online 17 March 2017

Keywords:

Humeral fractures

Bone plates

Bone screws

ABSTRACT

Musculoskeletal injuries such as dislocation of the shoulder and hip joints and fractures of the femoral neck are known complications of seizures. Bilateral central subluxation of the hip joint with associated bilateral quadrilateral plate fracture is a rare entity and is prone to delayed diagnosis, even more so in patients who experience post-seizure disorientation. The authors report the case of a 74-year-old male patient with bilateral central subluxation of the hip joint with associated bilateral quadrilateral plate fracture due to seizure activity. Bilateral open reconstruction and fixation of the quadrilateral plate with a 3.5-mm pre-bent reconstruction plate reinforced with 3.5-mm pelvic brim reconstruction plate was performed. In conclusion, this case is an example of rare bilateral quadrilateral plate fracture caused due to seizure activity, a fracture for which a high level of suspicion should be kept in mind while evaluating the patient post-seizure episode.

© 2018 Sociedade Brasileira de Ortopedia e Traumatologia. Published by Elsevier Editora Ltda. This is an open access article under the CC BY-NC-ND license (<http://creativecommons.org/licenses/by-nc-nd/4.0/>).

Um caso raro de subluxação central bilateral da articulação do quadril associada a fratura bilateral da lâmina quadrilátera em um homem idoso devido a convulsões

RESUMO

Lesões musculoesqueléticas, tais como luxação das articulações do ombro e quadril e fraturas do colo do fêmur, são complicações conhecidas de convulsões. A subluxação central bilateral da articulação do quadril associada a fratura bilateral da lâmina quadrilátera do acetábulo é uma entidade rara e propensa ao diagnóstico tardio, ainda mais em pacientes

Palavras-chave:

Fraturas do úmero

Placas ósseas

Parafusos ósseos

* Corresponding author.

E-mail: vivshetty7777@gmail.com (V. Shetty).

<https://doi.org/10.1016/j.rboe.2017.03.009>

2255-4971/© 2018 Sociedade Brasileira de Ortopedia e Traumatologia. Published by Elsevier Editora Ltda. This is an open access article under the CC BY-NC-ND license (<http://creativecommons.org/licenses/by-nc-nd/4.0/>).

que experimentam desorientação pós-convulsão. Os autores relatam o caso de um paciente masculino de 74 anos de idade com subluxação central bilateral da articulação do quadril associada a fratura bilateral da lâmina quadrilátera decorrente de atividade convulsiva. Foi feita reconstrução bilateral aberta e a lâmina quadrilátera foi fixada com uma placa de reconstrução pré-dobrada de 3.5 mm, reforçada com uma placa de reconstrução da borda pélvica de 3,5 mm. Conclui-se que este caso é um raro exemplo de fratura bilateral das lâminas quadriláteras causada pela atividade convulsiva. Os profissionais de saúde devem manter um alto nível de suspeita para esse tipo de fratura ao avaliar pacientes após um episódio convulsivo.

© 2018 Sociedade Brasileira de Ortopedia e Traumatologia. Publicado por Elsevier Editora Ltda. Este é um artigo Open Access sob uma licença CC BY-NC-ND (<http://creativecommons.org/licenses/by-nc-nd/4.0/>).

Introduction

Many musculoskeletal injuries including dislocation of the shoulder and sterno-clavicular joints, hip joints, fracture of femoral neck, and pelvis are known complications of seizures. They may occur in patients with epilepsy, either due to trauma or unbalanced muscle contractions during seizure episode.^{1,2} Quadrilateral plate fracture of acetabulum with central subluxation of hip joint is rarely seen in these patients. It can be easily missed because of lack of history of trauma. High index of suspicion and thorough clinical and radiological examination should be done to prevent delay in diagnosis. We report a rare case of bilateral central subluxation of hip joint with associated bilateral Quadrilateral plate fracture due to seizure activity.

Case report

A 74-year-old male patient presented to the neurosurgery department with 15 days history of altered sensorium. There was history of generalised tonic clonic seizures for past four months. Since last 7 days, he was bedridden after an episode of severe generalised seizure. The active and passive movements of both upper and lower limbs were severely restricted due to pain. MRI scan of brain had revealed a large 7 cm × 5.5 cm × 4.5 cm size right frontal dural based meningioma. There was severe surrounding white matter oedema involving the right fronto-parietal brain. A right fronto-parietal craniotomy was performed by neurosurgeon (KD) and the meningioma was completely removed post-operatively his altered sensorium markedly improved to become conscious and alert. However the movements of bilateral upper and lower limb were restricted. Post-operative CT scan of brain revealed complete excision of the meningioma with regression of the white matter oedema in the right fronto-parietal region. In view of improved sensorium and persistent restricted, painful limb movements, an orthopaedic department consultation was taken for further evaluation.

On clinical examination, there was bruising around bilateral hip joint, tenderness was present around both hip joint, no neuro-vascular injury. X-rays of pelvis and right shoulder showed bilateral central acetabular fracture subluxation (Fig. 1), CT-scan of pelvis (Fig. 2) was done for pre-operative planning.

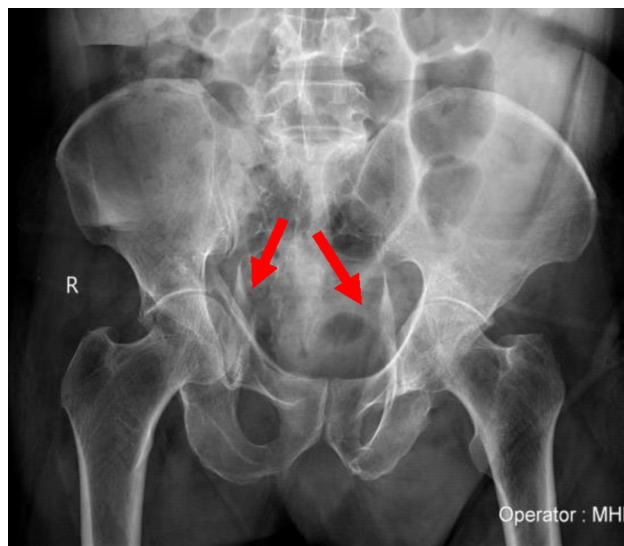


Fig. 1 – X-ray showing bilateral quadrilateral plate fracture.

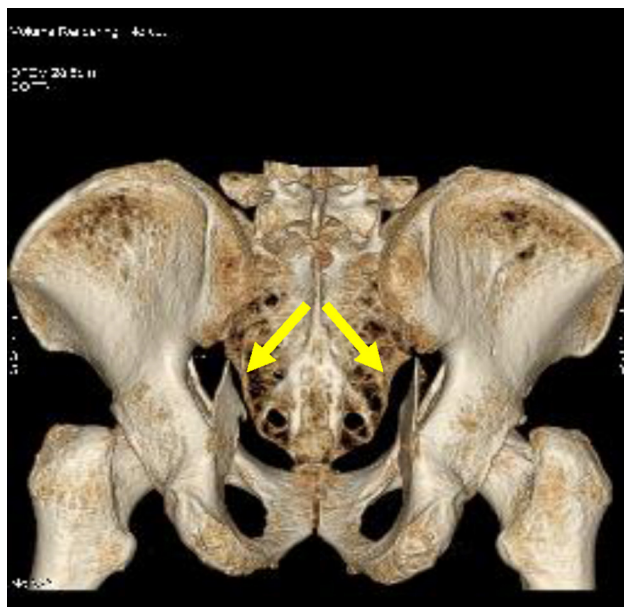


Fig. 2 – CT-scan showing bilateral quadrilateral plate fracture.

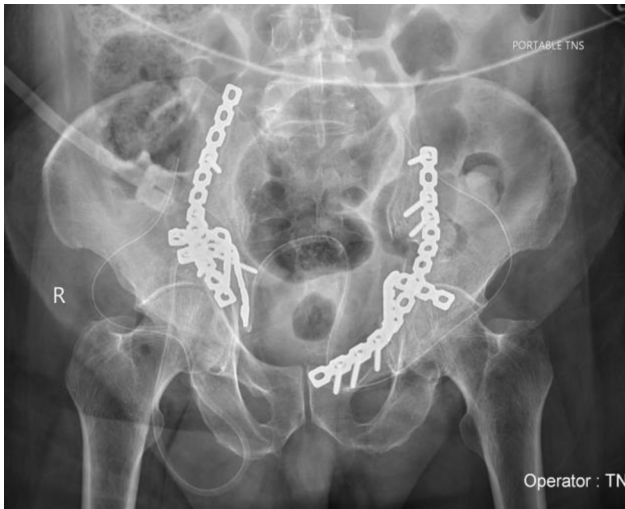

Fig. 3 – Immediate post-operative X-ray showing fixation of bilateral quadrilateral plate fracture.

Bilateral open reconstruction with fixation of quadrilateral plate fracture (Fig. 3) was done one of the authors (VS) on 12th post-operative day to primary surgery using ilio-inguinal approach with patient in supine position. Two prebent 3.5 mm reconstruction plate was used on right side and one 3.5 mm reconstruction plate on left side. Prebent plates were reinforced by 3.5 mm reconstruction plate over pelvic brim. Reduction was assessed under C-arm and was satisfactory.

Patient was allowed to sit with leg dangling by the side of bed and passive and active knee, hip range of motion exercises were started on 1st postoperative day. Patient was mobilised on wheelchair and was kept non-weight bearing. He was discharged after an inpatient stay for 16 days.

Discussion

Our case is an example of a rarer bilateral acetabular fracture pattern caused by a seizure activity which is prone to delayed diagnosis more so in patient who are disoriented leading to significant morbidity. It also highlights the importance of taking a detailed clinical history and thorough clinical examination looking for signs and symptoms such as extremity pain, deformity, ecchymosis and crepitus especially in elderly osteoporotic patients which can aid in identification of bone injury after a seizure episode.

Isolated quadrilateral plate fracture is rare fracture pattern. Laflamme et al.³ in their case report on isolated quadrilateral plate fracture suggested probable mechanism of injury could be that, the hip would have been positioned at 90° of flexion, 20° of internal rotation and maximum abduction. This could have created a force vector that caused only a partial central protrusion of the femoral head into the medial acetabulum, thus creating the isolated quadrilateral plate fracture. We believe that same mechanism of injury can explain quadrilateral plate fracture in our patient.

Quadrilateral plate fracture can be treated either operatively or non-operatively treatment depends on age, medical

condition, type of fracture, quality of bone, comminution, displacement, method of fixation, possibility of post-surgical complication, expertise and preference. Non-operative treatment of the quadrilateral fractures in elderly often results in poor outcome and high complication rate due to prolong immobilisation, early joint degeneration.⁴ Open reduction and internal fixation is considered treatment of choice for most displaced quadrilateral plate fracture. Quadrilateral plate fractures can be fixed by various fixation device like percutaneous screws, cerclage wires with or without plating, spring plates contoured over pelvic brim buttressing quadrilateral surface, H-shaped, T-shaped, L-shaped and reconstruction plates all can be used in similar manner. Synthes has introduced pre-contoured quadrilateral surface plate reinforced with pelvic brim plate with a slot for a lag screw for fixation of quadrilateral plate fractures. In a biomechanical study by Zha et al.,⁵ multidirectional titanium infrapectineal plates provides strongest fixation for such fractures, however it requires a steep learning curve and also is associated with increased bleeding rates due to injury to corona mortis while using Stoppa approach.

Ruan et al.⁶ reported satisfactory results in five patients with quadrilateral plate fractures using 3D fluoroscopic navigation and fixation with percutaneous screws positioned perpendicular to the fracture lines and close to the joint surface.

Farid⁷ proposed wire-plate composite uses a reconstruction spring plate over the pelvic brim for medial wall buttressing. One hole on its true pelvic limb provides a pulley to deviate a cerclage wire or cable passed through the greater sciatic notch into the true pelvis. He concluded that this technique provides rigid fixation of difficult comminuted and osteoporotic medial wall fractures without risk of joint penetration.

Laflamme et al.,⁸ in 2011 reported good to excellent result of 21 patients having displaced quadrilateral plate fracture with established osteoporosis fixed with infrapectineal plating

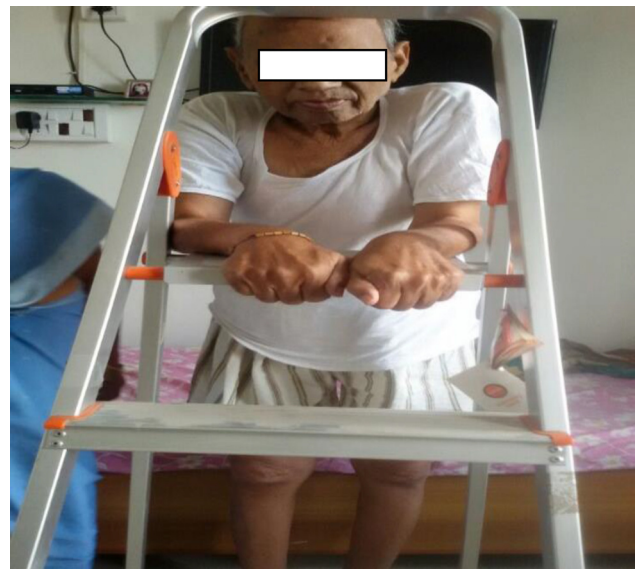

Fig. 4 – At 2 months follow up patient standing with support.

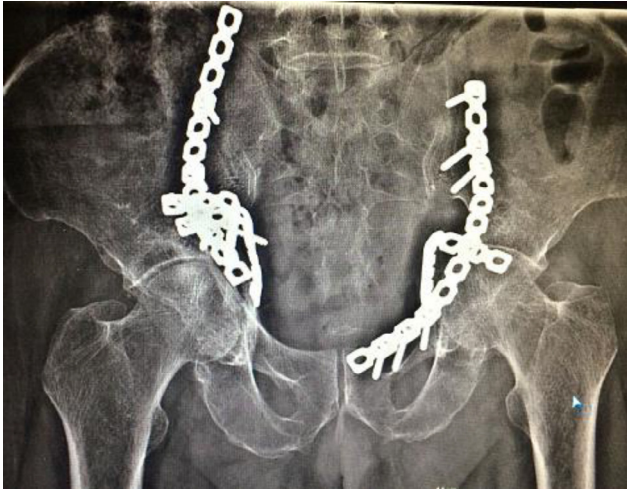

Fig. 5 – At 7 months follow up X-ray shows well maintained congruent reduction of hip.



Fig. 6 – At 10 follow-up 7 months full weight bearing walking.

using modified Stoppa approach. They concluded that internal fixation of quadrilateral plate fracture should be considered a viable alternative to total hip arthroplasty for the initial treatment of acetabular fractures in the elderly.

Since there was no associated acetabulum column injury we used ilioinguinal approach and spring plate (3.5 mm reconstruction plate) contoured over pelvic brim buttressing quadrilateral plate reinforced with pelvic brim plate. Patient was mobilised bed to chair immediately post-surgery and was kept non-weight bearing for 6 weeks. He was then allowed gradual weight bearing and walking with support (Fig. 4). On 7 months follow up X-ray shows well maintained congruent reduction of hip (Fig. 5), patient is able to walk full weight bearing without support (Fig. 6).

In conclusion, this case is an example of rare bilateral quadrilateral plate fracture caused due to seizure activity, for which high level of suspicion and possibility of such fracture should be kept in mind while evaluating patient post seizure episode.

Conflicts of interest

The authors declare no conflicts of interest.

REFERENCES

1. Vestergaard P, Tigarán S, Rejnmark L, Tigarán C, Dam M, Mosekilde L. Fracture risk is increased in epilepsy. *Acta Neurol Scand.* 1999;99(5):269-75.
2. Ach K, Slim I, Ajmi ST, Chaieb MC, Bezig AM, Chaieb L. Non-traumatic fractures following seizures: two case reports. *Cases J.* 2010;3:30.
3. Laflamme GY, Delisle J, Leduc S, Uzel PA. Isolated quadrilateral plate fracture: an unusual acetabular fracture. *Can J Surg.* 2009;52(5):E217-9.
4. Cornell CN. Management of acetabular fractures in the elderly patient. *HSS J.* 2005;1(1):25-30.
5. Zha GC, Sun JY, Dong SJ, Zhang W, Luo ZP. A novel fixation system for acetabular quadrilateral plate fracture: a comparative biomechanical study. *Biomed Res Int.* 2015;2015:391032.
6. Ruan Z, Luo CF, Zeng BF, Zhang CQ. Percutaneous screw fixation for the acetabular fracture with quadrilateral plate involved by three-dimensional fluoroscopy navigation: surgical technique. *Injury.* 2012;43(4):517-21.
7. Farid YR. Cerclage wire-plate composite for fixation of quadrilateral plate fractures of the acetabulum: a checkrein and pulley technique. *J Orthop Trauma.* 2010;24(5):323-8.
8. Laflamme GY, Hebert-Davies J, Rouleau D, Benoit B, Leduc S. Internal fixation of osteopenic acetabular fractures involving the quadrilateral plate. *Injury.* 2011;42(10):1130-4.