



## Technical Note

# Reconstruction of the distal biceps tendon using semitendinosus grafting: Description of the technique<sup>☆</sup>



Leandro Masini Ribeiro\*, Jose Inacio de Almeida Neto, Paulo Santoro Belangero, Alberto de Castro Pochini, Carlos Vicente Andreoli, Benno Ejnisman

Departamento de Ortopedia e Traumatologia, Escola Paulista de Medicina, Universidade Federal de São Paulo, São Paulo, SP, Brazil

### ARTICLE INFO

#### Article history:

Received 30 January 2017

Accepted 17 April 2017

Available online 2 August 2018

#### Keywords:

Elbow/injuries

Rupture

Reconstructive surgical procedures

Treatment outcome

#### Palavras-chave:

Cotovelo/lesões

Ruptura

Procedimentos cirúrgicos

reconstrutivos

Resultado de tratamento

### ABSTRACT

Distal ruptures of the biceps are rare when compared to proximal ruptures, with a different epidemiology and mechanism of trauma. There is no exact pathophysiology, though the hypovascular distal insertion and the mechanical impact during movement should be considered important factors. The surgical treatment of chronic cases presents worse prognosis due to muscle shortening with tendon retraction, making anatomical repair of the injury difficult, requiring the use of grafts for its reconstruction. This is a prospective study involving four patients with chronic distal biceps injury. The tendons were reconstructed with an autologous graft from the semitendinosus tendon from the ipsilateral knee and secured to the radial tuberosity with the help of two anchors. The surgical technique proved to be a simple and viable procedure for the reconstruction of chronic ruptures of the distal biceps.

© 2018 Published by Elsevier Editora Ltda. on behalf of Sociedade Brasileira de Ortopedia e Traumatologia. This is an open access article under the CC BY-NC-ND license (<http://creativecommons.org/licenses/by-nc-nd/4.0/>).

### Reconstrução do tendão distal do bíceps com enxerto de semitendíneo: descrição da técnica

#### R E S U M O

As rupturas distais do bíceps são raras quando comparadas com as rupturas proximais, têm epidemiologia e mecanismo de trauma diferentes. Não apresentam uma fisiopatologia exata; entretanto, a zona hipovascular na inserção distal e o impacto mecânico durante o movimento devem ser considerados fatores importantes. O tratamento cirúrgico dos casos crônicos apresenta pior prognóstico pelo encurtamento muscular com retração do tendão, dificulta a reparação anatômica da lesão, deve ser considerado o uso de enxertos para sua reconstrução. Este é um estudo prospectivo, envolve quatro pacientes com lesão crônica do

<sup>☆</sup> Study conducted at Universidade Federal de São Paulo, Escola Paulista de Medicina, Departamento de Ortopedia e Traumatologia, Centro de Traumatologia do Esporte, São Paulo, SP, Brazil.

\* Corresponding author.

E-mail: [lemasini@yahoo.com.br](mailto:lemasini@yahoo.com.br) (L.M. Ribeiro).

<https://doi.org/10.1016/j.rboe.2018.07.008>

2255-4971/© 2018 Published by Elsevier Editora Ltda. on behalf of Sociedade Brasileira de Ortopedia e Traumatologia. This is an open access article under the CC BY-NC-ND license (<http://creativecommons.org/licenses/by-nc-nd/4.0/>).

bíceps distal. Os tendões foram reconstruídos com enxerto autólogo do tendão semitendíneo do joelho ipsilateral e fixado na tuberosidade do rádio com auxílio de duas âncoras. A técnica cirúrgica mostrou-se um procedimento simples e viável para reconstrução das rupturas crônicas do bíceps distal.

© 2018 Publicado por Elsevier Editora Ltda. em nome de Sociedade Brasileira de Ortopedia e Traumatologia. Este é um artigo Open Access sob uma licença CC BY-NC-ND (<http://creativecommons.org/licenses/by-nc-nd/4.0/>).

---

## Introduction

The biceps brachii is the main supinator muscle of the forearm; its secondary function is elbow flexion.<sup>1</sup>

When compared with proximal insertion ruptures, distal ruptures of the biceps are rare (5% of cases) and present a different epidemiology and trauma mechanism.<sup>2</sup>

These injuries are observed mainly in men between the 4th and 6th decades of life, during eccentric contraction of the biceps, and preferentially affect the dominant side of the limbs.<sup>1</sup>

To date, the exact pathophysiology is unknown, though the hypovascular area at the distal insertion and the mechanical impact during movement should be considered important factors. Degenerative tendinopathy and some endocrine diseases have also been associated with the onset of this pathology.<sup>3</sup> The main risk factors are the use of anabolic steroids, weight lifting, and smoking.<sup>4</sup>

The clinical condition is characterized by acute pain, edema, and local ecchymosis, associated with an audible click during injury. Moreover, there is the presence of a gap on palpation proximal to the cubital fossa and loss of strength in supination of the forearm and elbow flexion.

The treatment of choice is surgical, except in elderly patients and/or in those with low functional demand. Cases with over four weeks of evolution are considered chronic.<sup>5</sup> These cases present a worse prognosis due to muscle shortening, with tendon retraction, muscular atrophy, and associated fibrosis, hindering an anatomical repair of the injury. Therefore, in chronic injuries with tendon retraction of the biceps, the use of grafts for reconstruction should be considered.

The literature describes numerous repair techniques for acute injuries, as well as graft techniques for chronic injuries; the graft options include the calcaneus, palmaris longus, tensor fasciae latae, and semitendinosus tendons.<sup>6-8</sup>

This study is aimed at presenting a reconstructive surgical technique with autologous semitendinosus tendon graft for the treatment of chronic distal biceps tendon injuries.

---

## Material and methods

This study included four patients who underwent reconstruction of the distal biceps tendon using a semitendinosus graft. All patients were male athletes (jiu-jitsu fighter, wrestler, soccer goalkeeper, and a fitness center goer), with a mean age of 37.75 years (range: 32-46). The mean follow-up was 15 months (range: 11-28) and took place between 2014 and 2015.

These athletes suffered indirect injuries in the dominant arm during sports activity. The jiu-jitsu fighter was injured during an eccentric contraction to defend himself against a blow applied by his opponent (arm clinch). The wrestler was injured during a fall in a defensive movement. The fitness center patient was in an eccentric movement during a biceps curl. Finally, the soccer goalkeeper was injured during a movement defending his goal.

On average, the athletes were operated 8.25 months after the injury (range: 4-13).

On physical examination, they presented elbow flexion loss of strength and particularly at supination. The Rulland and Hook tests were positive for all athletes. In all patients, magnetic resonance imaging (MRI) was used to assess the degree of the injury and to support the diagnosis.

All complications and risks of treatment options were explained to the athletes, as well as the need for autologous tissue for grafting if a primary reinsertion of the bicipital tendon was not possible.

---

## Surgical procedure

Surgeries were performed under general anesthesia associated with locoregional brachial plexus block; the patients were positioned in supine decubitus, and tourniquets were not used.

The technique used involved two small anterior longitudinal incisions, one proximal to recover the proximal stump and another distal for reconstruction.

At the distal orifice, a longitudinal incision of approximately 3 cm was made, 2.5 cm distal to the elbow pit, guided by fluoroscopy for initial location of the radial tuberosity. The Henry approach was used to expose the radial tuberosity in supination, with delicate soft tissue spacing, thus avoiding neurological and vascular injury. The tuberosity was scarified to allow bleeding and to potentiate graft insertion.

A second, small incision of around 3 cm was made more or less 4 cm proximal to the cubital fold to isolate the retracted tendon stump, which is normally surrounded by fibrotic tissue. A blunt digital dissection was done to release the biceps muscle belly from the deep fascia and brachialis muscle. Special care was taken in the identification of the lateral cutaneous nerve of the forearm (a branch of the musculocutaneous nerve) that passes between the biceps and the brachialis.

The criterion used for the definition of tendon reconstruction was the inability of excursion of the remnant of the tendon to reach the tuberosity of the radius even after the release of the lacertus fibrosus. The tendon path (tunnel) was

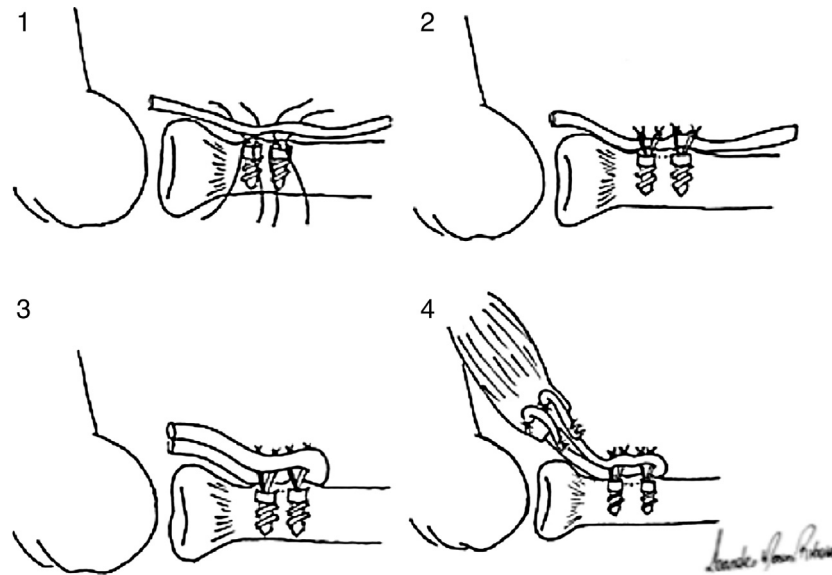


Figure 1 - Images demonstrating the reconstruction of the distal biceps with a semitendinosus graft.

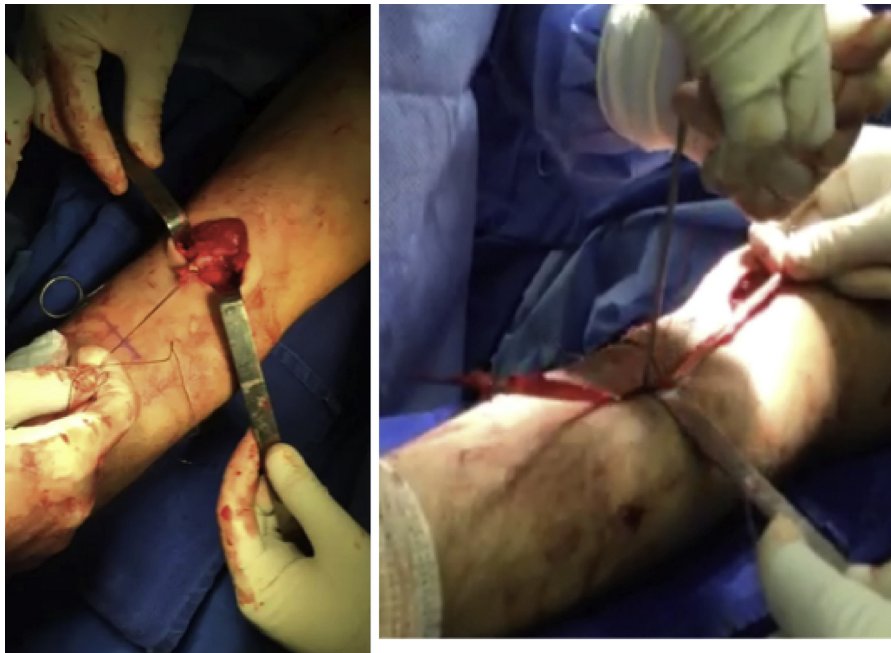


Figure 2 - Intraoperative images of the reconstruction of the distal biceps.

remade with manual divulsion up to the insertion in the radial tuberosity.

At that time, the semitendinosus graft was harvested from the ipsilateral knee.

The authors chose to insert two bioabsorbable anchors (3.5 mm) into the radial tuberosity, always with the forearm in total supination, with a mean distance of 1 cm between them. The graft was then placed over the anchors so that, after being sutured, two symmetrical portions were guided toward the proximal stump.

The graft was passed through the remodeled path and sutured into the muscle belly with high-resistance unabsorbable sutures. Preference was given to an entry point at

approximately 2 cm from the end of the stump, near the myotendinous junction. The graft was tensioned with the forearm in full supination and the elbow at 30–40° of flexion (Figs. 1 and 2).

In the immediate postoperative period, the patients were immobilized with an above-elbow splint.

## Results

The athletes evolved without vascular complications or surgical site infections. Only one patient experienced a transient loss of sensation on the lateral aspect of the forearm, with a



**Figure 3 – Six-month postoperative images of one of the athletes, demonstrating adequate range of motion and physical appearance equal to that of the contralateral limb.**

spontaneous resolution three months after the procedure. The above-elbow splint was removed after two weeks, and a simple sling was maintained until the sixth postoperative week.

Physical therapy was initiated six weeks after the surgery,<sup>11-14</sup> and was maintained for approximately two months. No restriction on the final range of motion of the elbow was observed.

Patients were assessed for joint range of motion (pronosupination and flexion-extension), presence of pain, supination force, and degree of satisfaction. All athletes evolved with no range of motion loss or pain; they also recovered supination force when compared to the contralateral limb (Fig. 3).

After four months, all patients were able to return to the sports practice at the pre-injury level.

## Discussion

In chronic injuries to the distal portion of the biceps, the marked retraction of the proximal stump observed after the third month of evolution significantly reduces the chances of an anatomical primary repair. Therefore, three treatment options are possible: non-anatomical repair with brachialis muscle attachment, attempt to mobilize the biceps with release of the lacertus fibrosus, and graft reconstruction.

A non-anatomical repair is an option that presents many restrictions due to loss of elbow function in supination and

flexion. Bell et al.<sup>6</sup> demonstrated a deficit of 40% in the supination force and of 17% in the elbow flexion force; those authors also demonstrated that this type of treatment presents similar results to the conservative method. Therefore, it is only an esthetic option for the established deformity.

The attempt to mobilize the biceps is a viable option when, after the adhesions and lacertus fibrosus are released, the muscle belly is stretched and relief incisions are made; it is possible to reach the anatomical position in the radial tuberosity with an elbow flexion of up to 30-40°.<sup>7</sup>

The authors believe that the most appropriate alternative for cases of chronic injury with significant retraction and the inability of excursion of the remnant of the tendon to reach the radial tuberosity is a reconstruction with the use of autologous or allograft. The literature describes different types of graft: tensor fasciae latae, Achilles (allograft), palmaris longus, semitendinosus, and flexor carpi radialis bundle. The results with all these grafts were similar, with good functional recovery and pain decrease.<sup>8,9</sup>

In the cases presented, an autologous graft of the semitendinosus muscle tendon was used; the graft was secured to the radial tuberosity using two anchors. This is a simple option that showed consistent results.

The literature indicates that, among the options for tendon fixation into the radial tuberosity (bone tunnel, interference screw, endobutton, and suture anchors), endobutton has the highest biomechanical resistance, followed by a suture with anchors; nonetheless, when submitted to physiological



forces, no statistical difference is observed between them.<sup>10,11</sup>

In chronic injuries of the distal biceps, it is also possible to repair the tendon using endobutton and interference screws, which allows a more rigid and resistant fixation with two implants and early rehabilitation.<sup>12</sup> However, techniques with anchors presented excellent clinical and functional results.<sup>13</sup>

Thus, the choice of using suture with two bioabsorbable anchors was based on the possibility of greater footprint coverage (the biomechanical resistance of the insertion of the fibers of the long and short heads of the biceps, which under physiological forces is similar to that of the cortical button, was considered),<sup>11</sup> and on the fact that the procedure is simple and fast.

The choice of an autologous graft of the semitendinosus tendon was based on the simplicity of the procedure and on the experience of the surgical team for its removal, as well as on the reliable length and thickness of the reconstruction. Semitendinosus graft is a reliable option that presents a low complication rate. Hallam and Bain<sup>8</sup> demonstrated that, in all patients included in their study, there was a significant improvement in pain, strength, and range of motion, without deficit or complications.

Several techniques have been developed over the years to reduce complications associated with repair, such as injury to the posterior interosseous nerve, medial cutaneous or lateral cutaneous nerve of the forearm<sup>10</sup>; heterotopic ossification; and proximal radioulnar synostosis, most commonly observed in the double approach technique described by Boyd and Anderson.<sup>14</sup>

The anterior approach, consisting of two mini-accesses, one proximal and the other distal, does not require an anterior wide S-shaped incision, and it provides a better esthetic satisfaction to the patient without complications during the treatment.

The technique presented was effective, with no complications such as graft failure or loosening, nor injury to the posterior interosseous nerve or the lateral cutaneous nerve of the forearm. The athletes progressed without postoperative pain in the two manipulated regions (anterior region of the forearm and anteromedial region of the knee). They presented full recovery of the range of movement both in pronosupination and in flexion-extension, and regained muscular strength, classified as grade 5 (normal force against total resistance) in accordance with the Medical Research Council muscular strength classification.<sup>15</sup>

While an endobutton attachment allows a greater bone-tendon integration with intramedullary graft insertion, attachment with two anchors was shown to be strong enough to hold the graft throughout the healing and rehabilitation process; it also has the benefits of greater surgeon familiarity and availability in operating rooms.

The present study also had limitations, such as strength assessment, which was performed using the traditional strength scale (which is susceptible to examiner bias), and the inclusion of a small number of cases. However, surgical treatment of chronic injuries is less frequent than acute ones.

## Conclusion

The surgical procedure presented for chronic reconstruction of the distal biceps was shown to be a simple technique that is safe and easy to perform; the results indicate its effectiveness regarding return to sports, low morbidity, and few complications.

## Conflicts of interest

The authors declare no conflicts of interest.

## REFERENCES

- Morrey BF, Askew LJ, An KN, Dobyns JH. Rupture of the distal tendon of the biceps brachii. A biomechanical study. *J Bone Joint Surg Am.* 1985;67(3):418-21.
- McDonal LS, Dewing CB, Shupe PG, Provencher MT. Disorders of the proximal and distal aspects of the biceps muscle. *J Bone Joint Surg Am.* 2013;95(13):1235-45.
- Geaney BLE, Mazzocca AD. Biceps brachii tendon ruptures: a review of diagnosis and treatment of proximal and distal biceps tendon ruptures. *Phys Sportsmed.* 2010;38(2):117-25.
- Safran MR, Graham SM. Distal biceps tendon ruptures: incidence, demographics, and the effect of smoking. *Clin Orthop Relat Res.* 2002;404:275-83.
- Baker BE, Bierwagen D. Rupture of the distal tendon of the biceps brachii. Operative versus non-operative treatment. *J Bone Joint Surg Am.* 1985;67(3):414-7.
- Bell RH, Wiley WB, Noble JS, Kuczynski DJ. Repair of distal biceps brachii tendon ruptures. *J Shoulder Elbow Surg.* 2000;9(3):223-6.
- Hang DW, Bach BR Jr, Bojchuk J. Repair of chronic distal biceps brachii tendon rupture using free autogenous semitendinosus tendon. *Clin Orthop Relat Res.* 1996;323:188-91.
- Hallam P, Bain GI. Repair of chronic distal biceps tendon ruptures using autologous hamstring graft and the Endobutton. *J Shoulder Elbow Surg.* 2004;13(6):648-51.
- Snir N, Hamula M, Wolfson T, Meislin R, Strauss EJ, Jazrawi LM. Clinical outcomes after chronic distal biceps reconstruction with allografts. *Am J Sports Med.* 2013;41(10):2288-95.
- Mazzocca AD, Burton KJ, Romeo AA, Santangelo S, Adams DA, Arciero RA. Biomechanical evaluation of 4 techniques of distal biceps brachii tendon repair. *Am J Sports Med.* 2007;35(2):252-8.
- Olsen JR, Shields E, Williams RB, Miller R, Maloney M, Voloshin I. A comparison of cortical button with interference screw versus suture anchor techniques for distal biceps brachii tendon repairs. *J Shoulder Elbow Surg.* 2014;23(11):1607-11.
- Terra BB, Rodrigues LM, Lima ALM, Cabral BC, Cavatte JM, De Nadai A. Direct repair of chronic distal biceps tendon tears. *Rev Bras Ortop.* 2016;51(3):303-12.
- Sarda P, Qaddori A, Nauschutz F, Boulton L, Nanda R, Bayliss N. Distal biceps tendon rupture: current concepts. *Injury.* 2013;44(4):417-20.
- Boyd HB, Anderson LD. A method for reinsertion of the distal biceps brachii. *J Bone Joint Surg Am.* 1961;43(7):1041-3.
- Medical Research Council Aids to examination of the peripheral nervous system. Memorandum no. 45. London: Her Majesty's Stationary Office; 1976.