

# Bilateral Atraumatic Patellar Ligament Rupture— Case Report\*

## *Ruptura atraumática bilateral do ligamento patelar—relato de caso*

Raul Hernandez Juliato<sup>1</sup> Luis Henrique Boschi<sup>1</sup> Raul Francisco Juliato<sup>1</sup> Americo Pinto de Freitas<sup>1</sup>  
Alexandre Felipe França<sup>1</sup> Lourenço Betti Bottura<sup>1</sup>

<sup>1</sup> Hospital São Domingos-Unimed, Catanduva, SP, Brazil

**Address for correspondence** Raul Hernandez Juliato, Hospital São Domingos-Unimed, Catanduva, SP, Brazil  
(e-mail: juliatoraul@hotmail.com).

Rev Bras Ortop 2019;54:223–227.

### Abstract

Bilateral atraumatic rupture of the patellar ligament is a rare lesion, usually associated with systemic diseases and drugs such as steroids and fluoroquinolones. This report presents a case of bilateral atraumatic rupture of the patellar ligament in a 43-year-old male with obesity, type 2 diabetes mellitus, and who was being treated with a systemic corticosteroid for autoimmune disease (Wegener granulomatosis). These factors caused chronic degenerative and inflammatory changes in the ligaments, confirmed by the histological examination. Due to tissue quality, a primary ligament repair associated to an augmentation with semitendinosus tendon was performed. After 1 year, the patient presented satisfactory evolution, regaining the full range of motion and returning to his usual activities without sequelae.

### Keywords

- ▶ patellar ligament
- ▶ histology
- ▶ knee/surgery

### Resumo

A ruptura atraumática bilateral do ligamento patelar é uma lesão rara, geralmente associada a doenças sistêmicas e ao uso de medicamentos como corticoides e fluoroquinolonas. Este relato apresenta um caso de ruptura atraumática bilateral do ligamento patelar em um homem de 43 anos, portador de obesidade, diabetes melitus tipo 2 e em uso de corticoide sistêmico para doença autoimune (granulomatose de Wegener). Esses fatores provocam alterações degenerativas e inflamatórias crônicas nos ligamentos, confirmadas pelo exame histológico. Devido à qualidade tecidual, foi feito reparo primário do ligamento associado a reforço com o tendão semitendíneo. Após um ano, o paciente apresentou evolução satisfatória, com ganho de amplitude de movimento completo e retorno às atividades habituais, sem sequelas.

### Palavras-chave

- ▶ ligamento patelar
- ▶ histologia
- ▶ joelho/cirurgia

## Introduction

The bilateral atraumatic rupture of the patellar ligament is a rare event. It is an important injury that involves the knee extensor mechanism, generating major functional disability and gait disturbances. The extensor mechanism of the knee

includes the quadriceps tendon, the patella, the patellar ligament and the tibial tuberosity.

The patellar ligament is an extremely strong structure, and, usually, it is not ruptured under normal physiological conditions. With a sagittal thickness ranging from 4 to 7 mm, it is composed mainly of large collagen fibers (90% of type I collagen and less than 10% of type III collagen). Elastin, proteoglycans, and other non-collagen glycoproteins form the remainder of the ligament matrix. It receives vascular

\* Work developed at Hospital São Domingos-Unimed, Catanduva, SP, Brazil.

received  
September 27, 2017  
accepted  
December 14, 2017  
published online  
April 15, 2019

DOI <https://doi.org/10.1016/j.rbo.2017.12.023>.  
ISSN 0102-3616.

Copyright © 2019 by Sociedade Brasileira de Ortopedia e Traumatologia. Published by Thieme Revinter Publicações Ltda, Rio de Janeiro, Brazil

License terms



supply from the infrapatellar fat and the retinacula; both ligament attachments are relatively avascular, consisting in fibrocartilage. In healthy ligaments, rupture requires a force of 17.5 times the body weight, and even a 75% injury in its thickness is unlikely to cause complete rupture.<sup>1</sup>

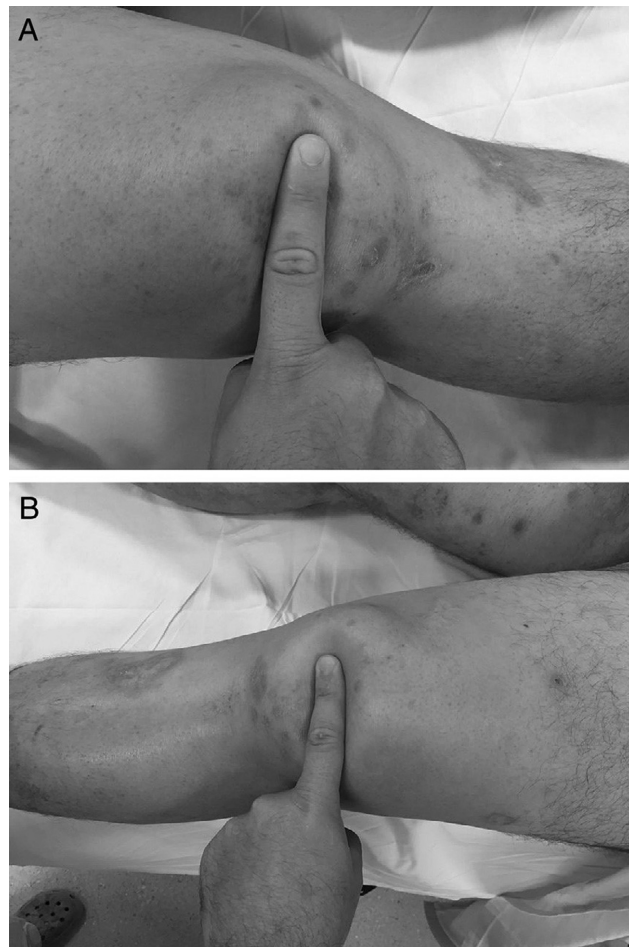
Bilateral atraumatic ruptures occur mostly in the ligament substance and they are usually associated with systemic diseases, such as systemic lupus erythematosus, rheumatoid arthritis, diabetes, obesity, chronic renal failure, and hyperparathyroidism, as well as with medications, such as local and systemic corticosteroids, and antibiotics such as fluoroquinolones.<sup>1,2</sup> These conditions and medications have been implicated as risk factors for these knee injuries due to microstructural changes in the ligament substance; moreover, they weaken collagen and cause rupture after minimal traumatic events or even in atraumatic conditions.

This study aims to present a case of bilateral atraumatic rupture of the patellar ligament.

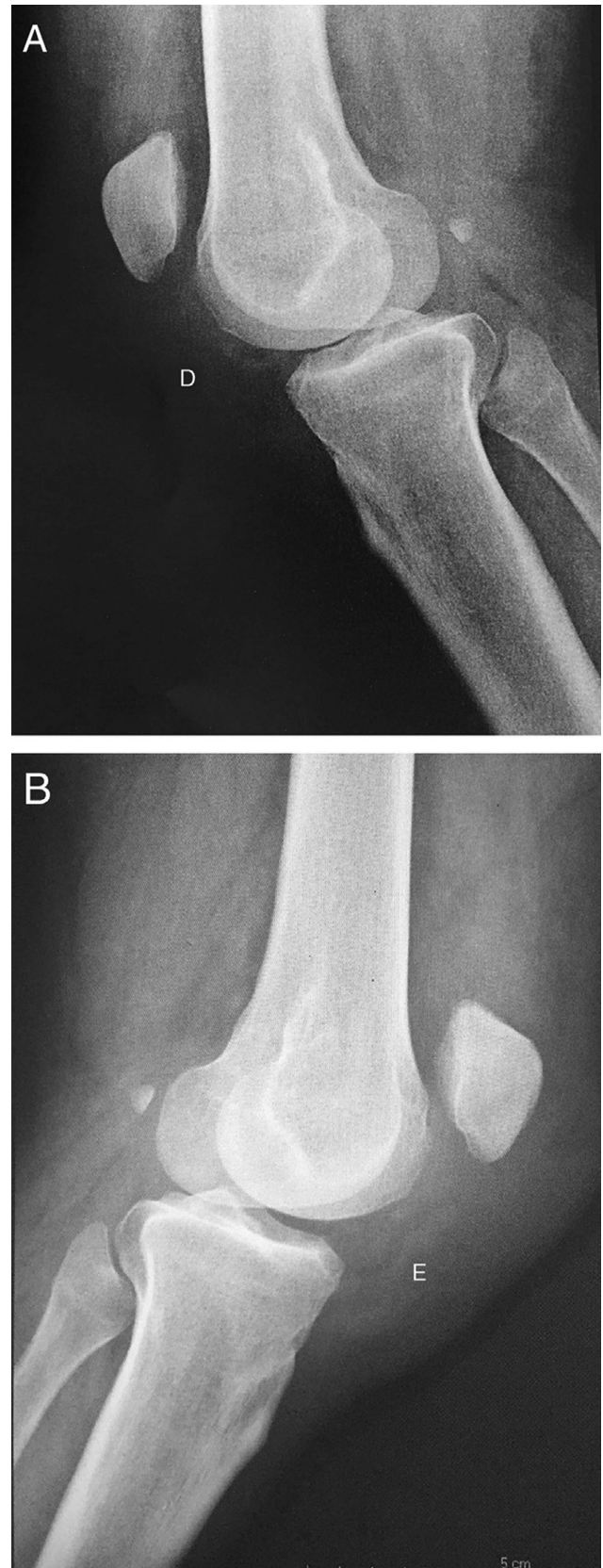
### Case Report

Male patient, 43 years-old, obese (body mass index: 40.6), with history of type 2 diabetes (treated with metformin, 850 mg twice a day) and Wegener granulomatosis (treated with prednisone, 20 mg/day, and cyclophosphamide mono-

hydrate, 50 mg, 3 times a day) for 6 months, came to the orthopedic service of the emergency room complaining of bilateral knee pain when getting off a police car, followed by a



**Fig. 1** Palpation with infrapatellar gap (A) Right knee; (B) Left knee.



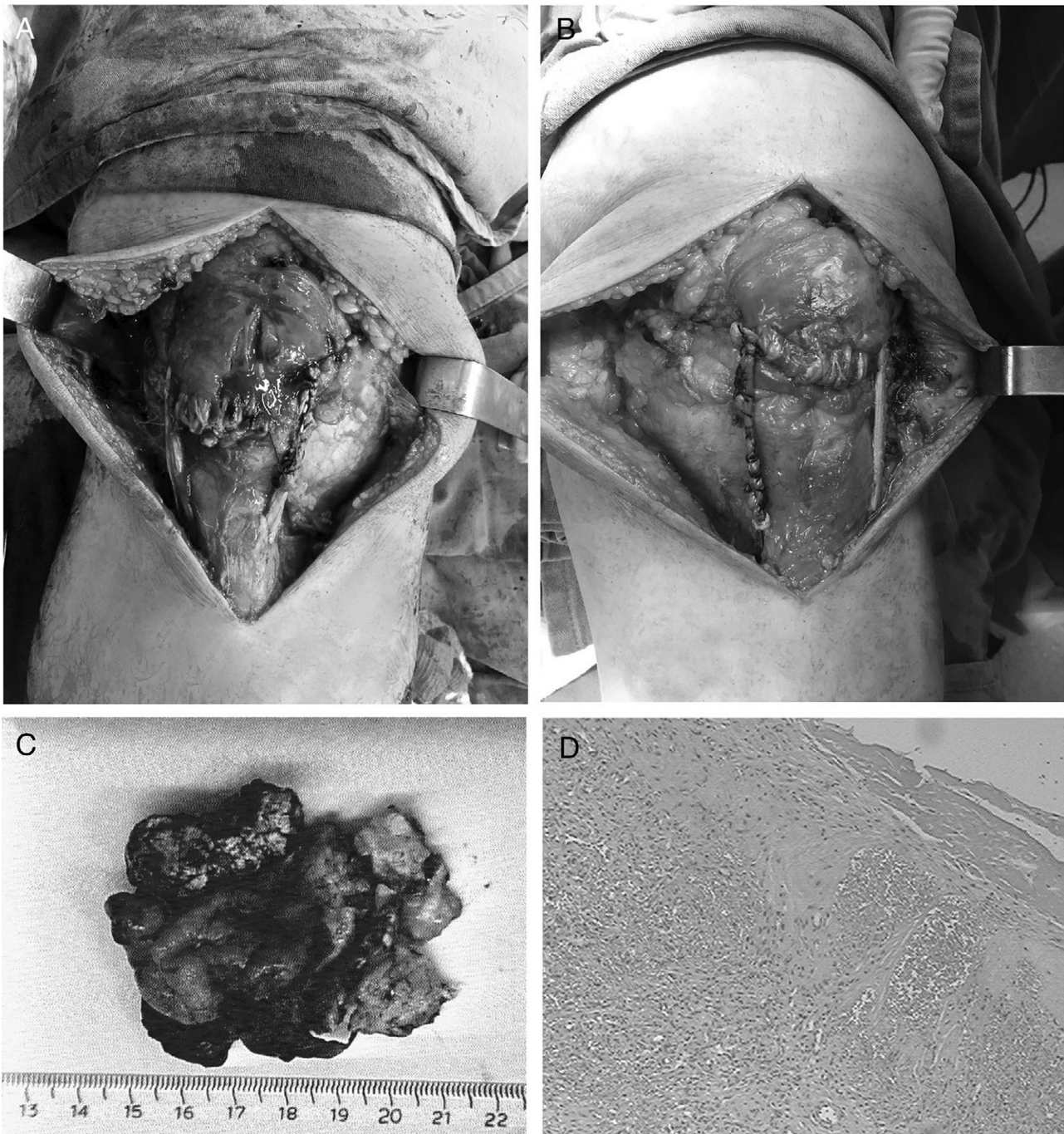
**Fig. 2** Bilateral high patella (*patella alta*).

bilateral knee popping sensation and inability to walk. On physical examination, he had several cutaneous ulcers in the lower limbs at different stages of healing and palpation showed a joint effusion and a bilateral infrapatellar gap (**Fig. 1**) associated with an incapacity for active extension.

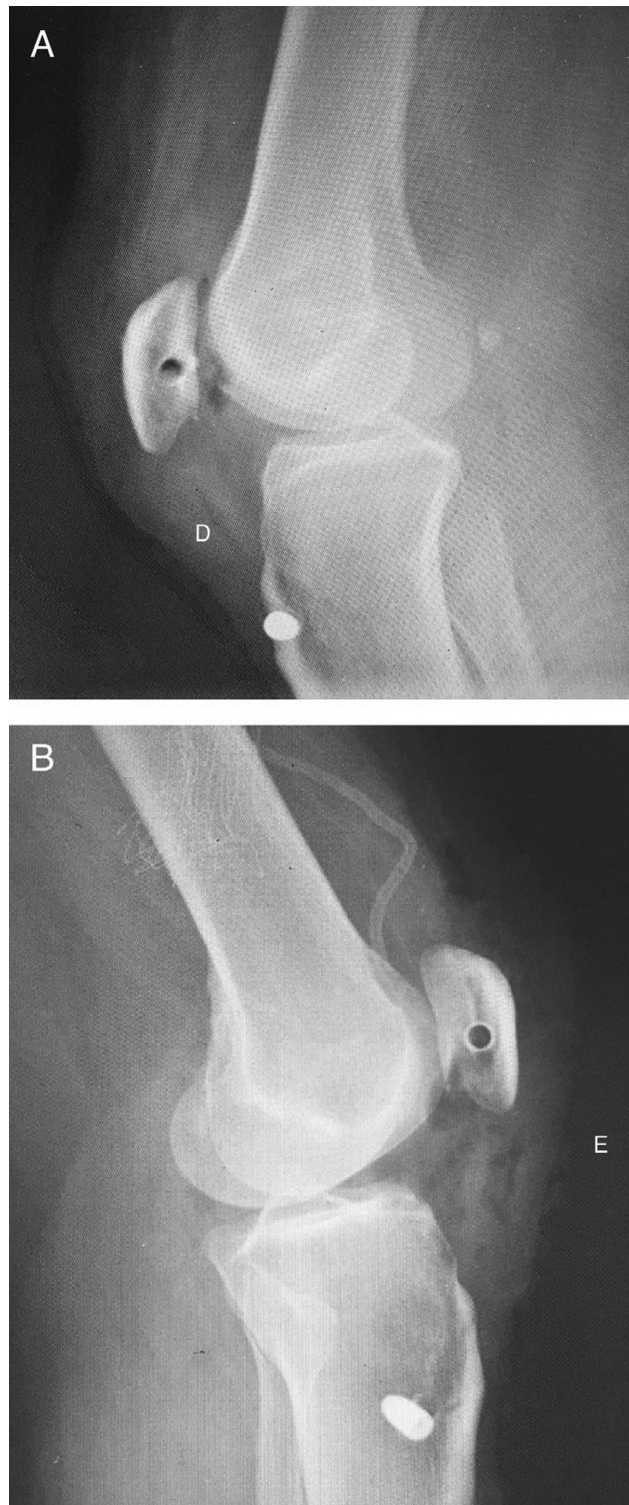
In simple lateral radiographs, at 30° flexion, a bilateral high patella was observed (**Fig. 2**). An ultrasound examination confirmed the complete bilateral rupture of the patellar ligaments. Surgical treatment was delayed for 7 to 15 days while waiting for the multiple granulomatous ulcers around the knee to heal completely. During the surgical procedure, after medial incision, we found a lesion in the ligament substance,

with low-quality aspect, extending to the medial and lateral retinacula. A 0.5 fragment of ligament tissue from both stumps was collected for histological evaluation (**Fig. 3**) and, then, the primary ligament and retinaculum repair was performed with Vycril suture and semitendinosus tendon reinforcement, as described by Zekcer et al<sup>3</sup> (**Fig. 3**).

After the surgery, the patellar height was rechecked with the Insall-Salvati index. The indexes in the right and left knees decreased from 1.71 and 1.69 to 1.01 and 0.93, respectively (**Fig. 4**). An index up to 1.2 is considered acceptable. The lower patella poles were within 2 cm from the Blumensaat line, which is also deemed acceptable.

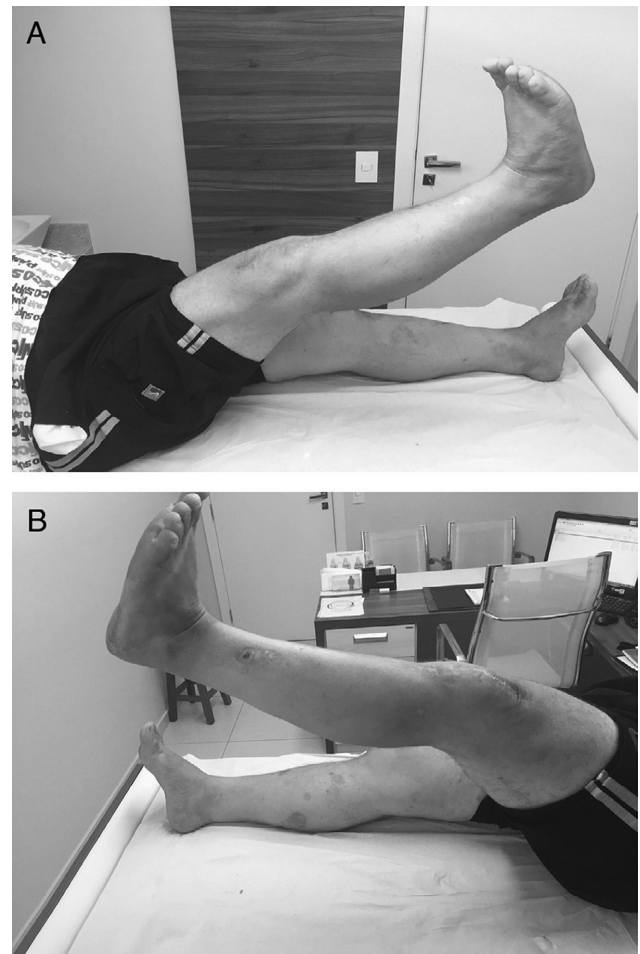


**Fig. 3** (A and B) Immediate postoperative period; (C) Ligamental tissue; (D) Histological slide.



**Fig. 4** Bilateral, postoperative knee radiographs.

Both knees were immobilized in extension with inguino-malleolar bracing for 6 weeks. Isometric and passive exercises started early, as well as the support in crutches. Active extension exercises started after 6 weeks. The patient presented a satisfactory evolution and at the 1 year of follow-up, he was walking unassisted, presenting a bilateral range of motion from 0 to 130° and good muscular strength (grade 4); as such, the patient returned to his daily activities without restrictions (→ **Fig. 5**).



**Fig. 5** One-year post surgery.

## Discussion

Most bilateral atraumatic ruptures of the patellar ligament result from systemic alterations or medication use. In 2001, Rose and Frassica<sup>4</sup> found 48 patients with bilateral patellar ligament rupture, with 16 atraumatic cases. Among these patients, 75% had a systemic condition, including previous steroid injections, rheumatic disease, renal failure and metabolic disorders. Our patient presented diabetes mellitus, corticosteroid use for Wegener granulomatosis and obesity as systemic factors.

Diabetes results in ligament weakening due to non-enzymatic glycosylation, which alters collagen cross-linking. A study by Fox et al,<sup>5</sup> in experimental rat models, found that diabetic patellar ligaments had a significantly reduced Young modulus and a greater predisposition for ligament substance tears compared with control, non-diabetic individuals.

We found no association in the literature of Wegener granulomatosis, a vasculitis of small and medium arteries, with atraumatic ligament ruptures, but the use of systemic and local corticosteroids has been implicated in these lesions. These drugs are known to weaken collagenous structures due to its antimetabolic and fibroblast synthesis effects, in addition of stimulating collagenase.<sup>6</sup> Other studies associate overweight/

obesity with atraumatic patellar ligament ruptures because of the chronic stress imposed on these structures.<sup>7</sup>

The histological examination of the ligament substance from the patient revealed degenerative changes, characterized as dense fibrous connective tissue with nonspecific inflammatory repair process (granulation tissue) and fibrosis with hyaline degeneration, but not vasculitis. Kannus and Jozsa<sup>8</sup> studied the histology of 891 samples of atraumatic tendinous and ligament ruptures, including 53 patellar samples, and found degenerative alterations in all specimens.

Surgical treatment is mandatory in cases of patellar ligaments rupture and early procedures yield better outcomes.<sup>1,2,9</sup> In atraumatic cases, the ligaments' tissue and healing are often poor; since their isolated primary repair can shorten and increase the risk of low patella, it is considered insufficient to withstand traction and it must be associated with a suture reinforcement.

The semitendinosus reinforcement has been used by several authors with excellent functional outcomes.<sup>1,3,9</sup> Mihalko et al<sup>10</sup> reported a cadaveric analysis in which tendon reinforcement decreases the slits formation at the repair site compared with the isolated primary suture. Therefore, we opted for a technique that uses an autologous tendon graft, the semitendinosus graft, as a reinforcement, since we consider that pes anserinus tendons are optimal due to their easy handling, strong nature, minimal functional damage and routine collection in tendons and ligaments reconstruction; in addition, no further surgery is required for implant removal and postoperative outcomes are excellent.

In conclusion, we present the case report of a 43-year-old male patient with bilateral patellar ligament rupture after minimal effort, a rare orthopedic event. The systemic factors were obesity, diabetes and corticosteroids use for Wegener granulomatosis. Histological examination confirmed the existence of inflammatory and degenerative damage in ligamental tissue. The primary repair associated with sem-

itendinosus tendon reinforcement due to the low tissue quality yielded a satisfactory clinical outcome after 1 year.

#### Conflicts of Interest

The authors declare that there is no conflict of interest.

#### References

- 1 Savarese E, Bisicchia S, Amendola A. Bilateral spontaneous concurrent rupture of the patellar tendon in a healthy man: case report and review of the literature. *Musculoskelet Surg* 2010;94(02):81–88
- 2 Rosso F, Bonasia DE, Cottino U, Dettoni F, Bruzzone M, Rossi R. Patellar tendon: from tendinopathy to rupture. *Asia-Pacific J Sports Med Arthrosc. Rehabil Technol* 2015;2(04):99–107
- 3 Zekcer A, Carneiro AC, Minervini S, Navarro R. Rer-ruptura do ligamento patelar: uma proposta para o tratamento cirúrgico. *Rev Bras Ortop* 2001;36(1/2):41–43
- 4 Rose PS, Frassica FJ. Atraumatic bilateral patellar tendon rupture, A case report and review of the literature. *J Bone Joint Surg Am* 2001;83-A(09):1382–1386
- 5 Fox AJ, Bedi A, Deng XH, Ying L, Harris PE, Warren RF, et al. Diabetes mellitus alters the mechanical properties of the native tendon in an experimental rat model. *J Orthop Res* 2011;29(06):880–885
- 6 Erdem M, Sen C, Güneş T. [Atraumatic bilateral patellar tendon rupture in a patient receiving steroid therapy]. *Acta Orthop Traumatol Turc* 2006;40(05):411–416
- 7 Panasiuk M, Groblewski M. [Spontaneous patellar tendon rupture as a result of morbid obesity]. *Pol Orthop Traumatol* 2011;76(06):353–354
- 8 Kannus P, Józsa L. Histopathological changes preceding spontaneous rupture of a tendon. A controlled study of 891 patients. *J Bone Joint Surg Am* 1991;73(10):1507–1525
- 9 Maffulli N, Del Buono A, Loppini M, Denaro V. Ipsilateral hamstring tendon graft reconstruction for chronic patellar tendon ruptures: average 5.8-year follow-up. *J Bone Joint Surg Am* 2013;95(17):e1231–e1236
- 10 Mihalko WM, Vance M, Fineberg MJ. Patellar tendon repair with hamstring autograft: a cadaveric analysis. *Clin Biomech (Bristol, Avon)* 2010;25(04):348–351