

# Florid Reactive Periostitis of the Proximal Phalanx—Case Report and Literature Review\*

## *Periostite reativa florida da falange proximal – relato de caso e revisão de literatura*

José Neias Araujo Ribeiro<sup>1</sup> Maria Luzete Costa Cavalcante<sup>1</sup> Diogo Araujo Farias Junior<sup>1</sup>  
Rudy Diavila Bingana<sup>2</sup>

<sup>1</sup> Orthopedics Department, Universidade Federal do Ceará, Hospital Walter Cantídio, Fortaleza, CE, Brazil

<sup>2</sup> Faculty of Medicine, Universidade Federal do Ceará, Fortaleza, CE, Brazil

**Address for correspondence** Maria Luzete Costa Cavalcante, Rua Professor Costa Mendes, 1608, Rodolfo Teófilo, Fortaleza, CE, Brasil. CEP: 60430-140.  
(e-mail: marialuzetecosta@gmail.com; joseneias2@yahoo.com.br).

Rev Bras Ortop 2019;54:335–338.

### Abstract

Florid reactive periostitis is a benign and rare lesion that is a recurrent diagnostic problem. Its etiopathogenesis remains unknown. Florid reactive periostitis consists of a fibrotic, cartilage-producing tumor accompanied by an aggressive inflammatory periosteal and soft tissue reaction. It typically occurs in adolescents and young adults, mostly female; it often affects hand and foot bones, and it may occur in long bones. Its diagnosis remains a major challenge due to the vast possibility of differential diagnoses. Therefore, careful clinical, radiological, and pathological evaluation is required to establish a proper diagnosis. We report the case of a patient with florid reactive periostitis in the proximal phalanx of the right index finger, who underwent surgical excision with a wide margin, from the second ray to the proximal third of the second metacarpal bone, and evolved without complications, with satisfactory range of motion and strength.

### Keywords

- ▶ finger phalanges
- ▶ periostitis
- ▶ bone neoplasms


### Resumo

A periostite reativa florida é uma lesão benigna e rara que constitui um problema recorrente de diagnóstico. Sua etiopatogênese permanece desconhecida. A periostite reativa florida caracteriza-se por ser uma reação periosteal agressiva e inflamatória do tecido mole e um tumor portador de fibrose e produtor de cartilagem. Ocorre em adolescentes e adultos jovens, com predomínio no sexo feminino, e acomete com frequência os ossos das mãos e dos pés, podendo acometer também ossos longos. O diagnóstico permanece um grande desafio devido à enorme possibilidade de diagnósticos diferenciais. Por isso, uma cuidadosa avaliação clínica, radiológica e patológica é necessária para fechar o diagnóstico. Relata-se o caso de um paciente com periostite reativa florida na falange proximal do segundo dedo da mão direita, que foi submetida à excisão cirúrgica com margem ampla do segundo raio até o terço proximal do segundo metacarpo, e evoluiu sem queixas, com amplitude de movimento e força satisfatória.

### Palavras-chave

- ▶ falanges dos dedos da mão
- ▶ periostite
- ▶ neoplasias ósseas

\* Work performed at Universidade Federal do Ceará, Hospital Walter Cantídio, Fortaleza, Ceará, Brazil.

 Maria Luzete Costa Cavalcante's ORCID is <https://orcid.org/0000-0002-3363-6916>.

received  
July 28, 2017  
accepted  
July 2, 2018

DOI <https://doi.org/10.1055/s-0039-1692430>.  
ISSN 0102-3616.

Copyright © 2019 by Sociedade Brasileira de Ortopedia e Traumatologia. Published by Thieme Revnter Publicações Ltda, Rio de Janeiro, Brazil

License terms



## Introduction

Florid reactive periostitis is a benign and rare lesion, part of a family of reactive bone and soft tissue lesions that constitute a recurring diagnostic problem. One of the earliest descriptions of the lesion dates back to the 1930s, when Tracy B. Mallory<sup>1</sup> (1933) reported 6 cases, including 4 with tumor lesions that were very similar, if not identical, to reactive periostitis. About 30 years later, Hutter et al<sup>2</sup> proposed the term “parosteal fasciitis” because of the histological resemblance with soft parts nodular fasciitis; moreover, the term “parosteal” anatomically located the lesion.

Florid reactive periostitis is more frequent in the second and third decade of life, although the affected age group reported in the literature ranged from 5 to 70 years-old.<sup>3-5</sup> According to Fechner e Mills,<sup>6</sup> the male to female ratio is 1 to 1.5. The lesion is commonly found in the phalanges of the hand, mainly in the proximal phalanx.

This disease is characterized by an exuberant osteoblast production in a fibrous proliferative stroma originating at the level of the finger periosteum. The radiographic study shows soft tissues swelling and periosteal bone neoformation, which may appear as lamellar or mature bone. The cortex is usually intact.

Differential diagnoses include septic tenosynovitis, soft-tissue abscess, bone tumors, cortical osteomyelitis, myositis ossificans, benign giant-cell tumors and osteosarcoma.

This case study discusses the clinical history, radiologic and histologic findings, and treatment of a patient with florid reactive periostitis in the proximal phalanx of right index finger.

## Case Report

A female, 17-year-old patient presented with a history of tumor lesion in the right index finger for the last 4 years. Three years earlier, she had sought medical attention because of lesion growth. A biopsy was performed in May 2014. The histological analysis revealed mature bone trabeculae

involving typical adipose cells disposed in sheets, in addition to mild inflammatory lymphocytic infiltrate. In September 2014, the patient underwent a computed tomography scan, which revealed a massive bone exostosis in the second ray of the proximal phalanx, measuring  $4.2 \times 3.3 \times 2.2$  cm, with lobulated and well defined borders and a cortical sharpening area, but no rupture or extension to adjacent soft parts (–Fig. 1).

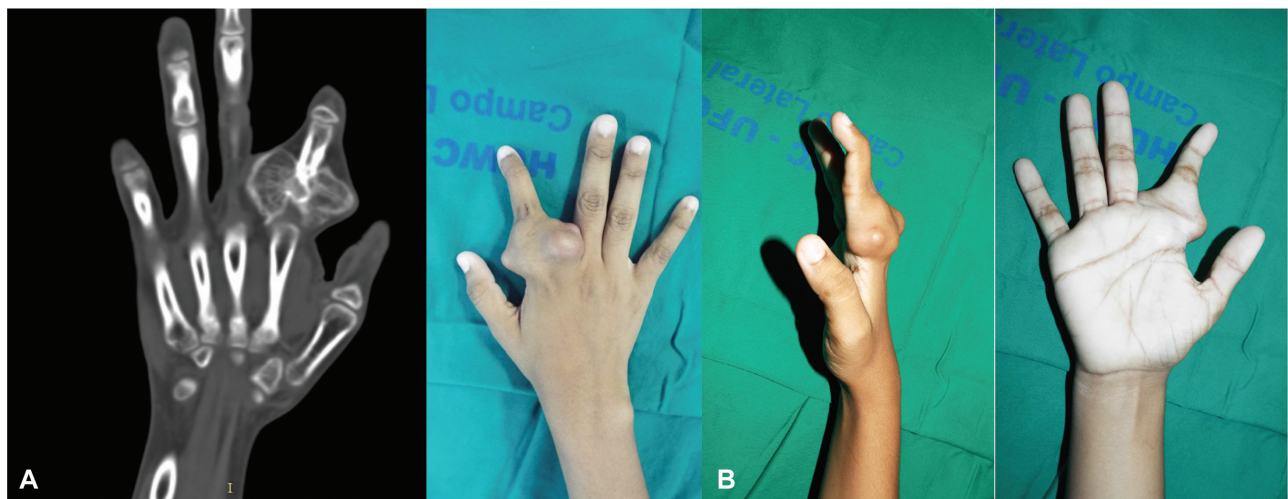
In January 2015, a new histopathological study was carried out, revealing the presence of cartilaginous tissue containing large nuclei chondrocytes and a calcified matrix, associated with bone trabeculae permeated by adipose tissue with no atypia, suggestive of Nora’s florid periostitis.

The patient came to the outpatient clinic in April 2015 reporting a flexion deficit at the affected finger. Physical examination showed a solid tumor growth located in the proximal phalanx of the index finger, measuring  $3.0 \times 2.5$  cm. On the occasion, a radiographic study of the right hand revealed a large tumoral mass affecting all proximal phalanges of the index finger (–Fig. 2).

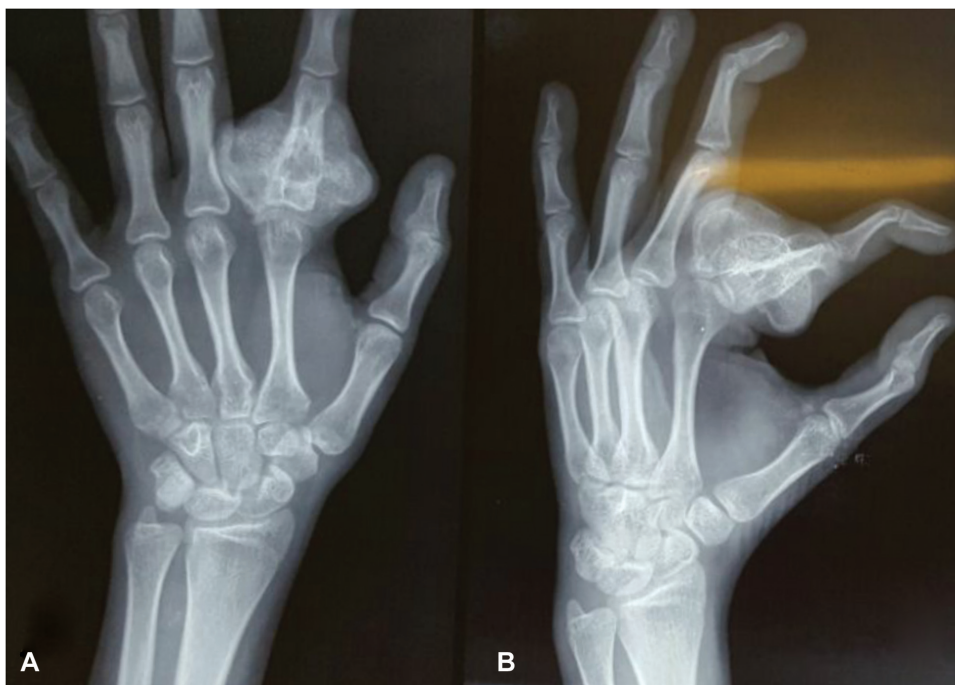A third incisional biopsy demonstrated bone trabeculae permeated by adipose tissue, associated with an area of fusocellular proliferation with activated aspect within a collagen matrix deposition, with low mitotic activity and absence of necrosis, consistent with florid periostitis. A surgical procedure was scheduled, but not performed because the patient was pregnant; she returned after 11 months.

Upon return, at the physical examination, the lesion had increased in size, and the following macroscopic features were noted: irregular, circumferential edges, and  $6.0 \times 4.5$  cm in size. A magnetic resonance imaging (MRI) of the right hand revealed an expansive, vegetative bone lesion, measuring  $4.1 \times 1.9 \times 3.2$  cm, covered by a thin cartilage sheet and pedunculated to the metaphyseal area of the index finger metacarpus (–Fig. 3).

Biopsy and imaging results led to the surgical excision with a wide margin, from the second ray up to proximal third of the second metacarpal bone (–Fig. 4).



**Fig. 1** Coronal computed tomography scan of the right hand showing an inflated lesion with tapering, cortical sclerosis and periosteal reaction in the proximal phalanx of the index finger (A); Preoperative clinical aspect of the hand, with limited index finger function (B).



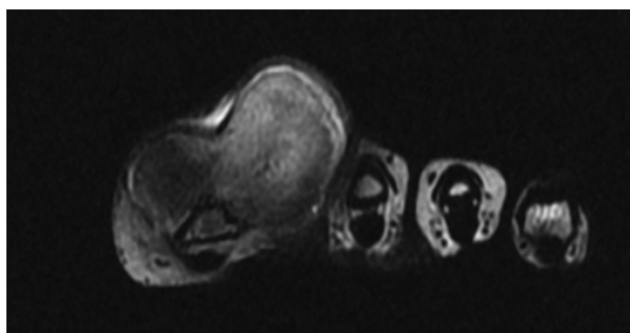
**Fig. 2** An anteroposterior radiography shows edema and an ossified mass of soft tissue in the proximal phalanx of the index finger (A), whereas an oblique radiography shows evidence of intraarticular tumor extension (B).

The patient evolved with no aesthetic or pain complaints and with satisfactory range of motion and strength.

**Discussion**

Florid reactive periostitis is a benign condition that can mimic osteomyelitis or a malignant bone neoplasm due to its clinical and radiological features. Although it is a benign condition, the clinical presentation is usually alarming and requires exclusion of other pathological conditions, such as osteomyelitis, osteochondroma, giant tendon sheath cell tumors, chondrosarcoma and parosteal osteosarcoma.

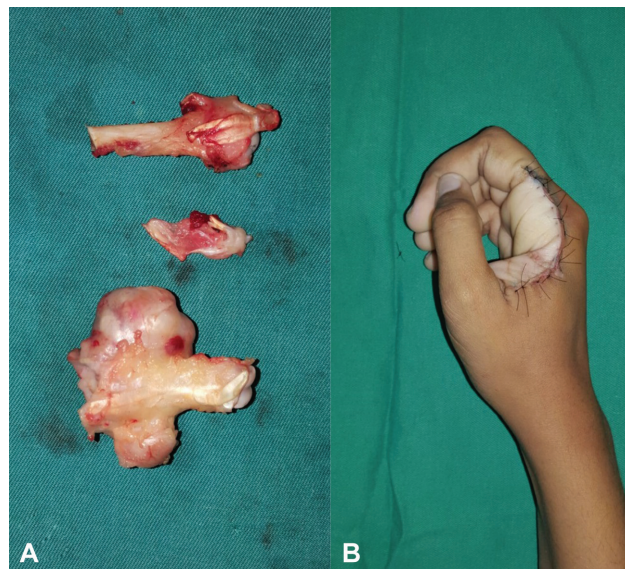
Radiological evaluation reveals edema or an ossified soft-tissue mass, sometimes accompanied by periosteal bone neof ormation.<sup>4,7,8</sup> Magnetic resonance imaging clearly reveals a soft-tissue mass, rarely evidenced by radiography. Computed tomography (CT) scans may better reveal bone erosion or destruction.<sup>8</sup>



**Fig. 3** Axial magnetic resonance imaging of the right hand showing an expansive bone lesion with a thin cartilage sheet and soft tissue involvement.

The final diagnosis is histological, evidencing an osteoid formation and a bone and cartilaginous mass within a fibroproliferative stroma fundus. The fibrous component consists of a large nuclei axis, but no atypical mitoses. Giant cells and inflammatory cells in varying numbers can be noted.<sup>3-5</sup>

Florid reactive periostitis can be easily confused with other serious conditions. It is difficult to differentiate florid periostitis from bizarre parosteal osteochondromatous proliferation (BPOP). Also known as Nora’s lesion, BPOP is a rare, but aggressive condition.



**Fig. 4** Surgical specimens photographed after lesion removal (A) and immediate postsurgical appearance (B).

Turret's exostosis or acquired osteochondroma is a rare dome-shaped bone disease affecting the dorsum of the proximal and middle phalanges of the fingers.<sup>2</sup>

Myositis ossificans, subungueal exostosis, osteosarcoma, periosteal osteosarcoma, periosteal chondroma and periosteal chondrosarcoma are also included in the differential diagnosis. The lack of cellular pleomorphism and atypical mitotic figures at the histological evaluation allows the differentiation between florid reactive periostitis and malignant lesions.<sup>4</sup>

Some authors agree that local and total tumor resection is sufficient for complete treatment.<sup>9</sup> However, other authors report relapses<sup>3,4</sup> that may lead to an additional resection.<sup>9</sup> In a literature review, Patel e Desai<sup>10</sup> recommended the use of the Enneking surgical staging system<sup>11</sup> for benign tumors in florid reactive periostitis cases to consider differences in tumor recurrence. They concluded that local resection would be appropriate for less aggressive, grade I tumors, but not for grade II and III tumors, which require ray amputation for relapse prevention.<sup>10</sup> Since our patient presented a stage III lesion, as per the Enneking classification,<sup>11</sup> a surgical excision with wide margin was performed.

The diagnosis of florid reactive periostitis remains a challenge due to the wide range of differential diagnoses, especially malignant conditions. Therefore, careful clinical, radiological and pathological evaluation are required to establish the appropriate diagnosis.

#### Conflicts of interest

The authors declare that there are no conflicts of interest.

#### References

- 1 Mallery TB. A Group of Metaplastic and Neoplastic Bone- and Cartilage-Containing Tumors of Soft Parts. *Am J Pathol* 1933;9 (Suppl):765-776, 3
- 2 Hutter RV, Foote FW, Francis KC, Higinbotham NL. Parosteal fasciitis. A self-limited benign process that simulates a malignant neoplasm. *Am J Surg* 1962;104:800-807
- 3 Spjut HJ, Dorfman HD. Florid reactive periostitis of the tubular bones of the hands and feet. A benign lesion which may simulate osteosarcoma. *Am J Surg Pathol* 1981;5(05):423-433
- 4 Rogers GF, Brzezienski MA. Florid reactive periostitis of the middle phalanx: a case report and review of the literature. *J Hand Surg Am* 1999;24(05):1014-1018
- 5 Dupree WB, Enzinger FM. Fibro-osseous pseudotumor of the digits. *Cancer* 1986;58(09):2103-2109
- 6 Fechner RE, Mills SE. Tumors of the Bones and Joints (Atlas of Tumor Pathology Series IV). Washington DC: Armed Forces Institute Pathology; 1993:268-269
- 7 Solana J, Bosch M, Español I. Florid reactive periostitis of the thumb: a case report and review of the literature. *Chir Main* 2003; 22(02):99-103
- 8 Gao Z, Wang J, Wang Z, Meng Q. Florid reactive periostitis of the metacarpal and phalanx: 2 case reports. *J Hand Surg Am* 2013;38 (11):2134-2137
- 9 Howard RF, Slawski DP, Gilula LA. Florid reactive periostitis of the digit with cortical erosion: a case report and review of the literature. *J Hand Surg Am* 1996;21(03):501-505
- 10 Patel MR, Desai SS. Pseudomalignant osseous tumor of soft tissue: a case report and review of the literature. *J Hand Surg Am* 1986;11 (01):66-70
- 11 Enneking WF. Staging of musculoskeletal neoplasms. In: Uthoff HK, Stahl E, eds. *Current concepts of diagnosis and treatment of bone and soft tissue tumors*. Berlin: Springer-Verlag; 1984:1-21