


Proximal Femur Fracture and Vascular Injury in Adults—Case Report*

Fratura proximal do fêmur e lesão vascular em adultos – Relato de caso

Pedro José Labronici^{1,2} Fernando Claudino dos Santos Filho¹ Yuri Leander Oliveira Diamantino¹
Eduardo Loureiro^{3,4} Maria Cristina Diniz Gonçalves Ezequiel² Sérgio Delmonte Alves⁵

¹ Orthopedics and Traumatology Service, Hospital Santa Teresa, Petrópolis, RJ, Brazil

² Universidade Federal Fluminense, Niterói, RJ, Brazil

³ Vascular Surgery, Hospital Santa Teresa, Petrópolis, RJ, Brazil

⁴ Vascular Surgery, Hospital Federal da Lagoa, Rio de Janeiro, RJ, Brazil

⁵ Trauma Service, Hospital Escola São Vicente Paula, Passo Fundo, RS, Brazil

Address for correspondence Pedro José Labronici, PhD, Serviço de Ortopedia e Traumatologia, Hospital Santa Teresa, Petrópolis, RJ, Brasil (e-mail: plabronici@globo.com).

Rev Bras Ortop 2019;54:343–346.

Abstract

Keywords

- ▶ femoral fractures
- ▶ vascular system injuries
- ▶ bone screws
- ▶ hip/surgery

Vascular complications in the surgical treatment of hip fractures are rare. Depending on the arterial injury, severe intraoperative bleeding or a subacute hematoma formation with arterial pseudoaneurysm development can occur. In the literature, the more frequently described complications are large local hematomas after osteosynthesis with sliding hip screws. This report shows a case of delayed arterial injury after proximal femur osteosynthesis.

Resumo

Palavras-chave

- ▶ fraturas do fêmur
- ▶ lesões do sistema vascular
- ▶ parafusos ósseos
- ▶ quadril/cirurgia


Complicações vasculares no tratamento cirúrgico de fratura do quadril são raras. A depender da lesão arterial, pode ocorrer um grave sangramento intraoperatório ou formação de hematoma subagudo com desenvolvimento de pseudoaneurisma arterial. Na literatura, as complicações mais frequentemente relatadas são a formação de grandes hematomas locais após osteossíntese com parafuso deslizante do quadril. O objetivo deste relato foi demonstrar um caso de lesão arterial tardia após osteossíntese proximal do fêmur.

Introduction

The rate of vascular complications in the surgical treatment of hip fractures is as low as 0.2%.¹ Vascular compromise in

this anatomical region can be caused by bone fragments formed due to iatrogenic reasons, intramedullary nail locking screws, poor retractor positioning, drilling perforation or bone fragments movement during reduction.² Depending on the vessel wall defect, the lesion may cause a massive intraoperative bleeding or subacute hematoma formation with arterial pseudoaneurysm development. Several authors have observed high rates of occult vascular compromise after the use of proximal femoral plates.³ The literature reports the formation of large local hematomas following osteosynthesis

* Work performed at the Orthopedics and Traumatology Service, Hospital Santa Teresa, Petrópolis, RJ, Brazil. Originally published by Elsevier Ltda.

 Pedro José Labronici's ORCID is <https://orcid.org/0000-0003-4967-7576>.

received
August 16, 2017
accepted
September 19, 2017

DOI <https://doi.org/10.1016/j.rbo.2017.09.003>.
ISSN 0102-3616.

Copyright © 2019 by Sociedade Brasileira de Ortopedia e Traumatologia. Published by Thieme Revnter Publicações Ltda, Rio de Janeiro, Brazil

License terms



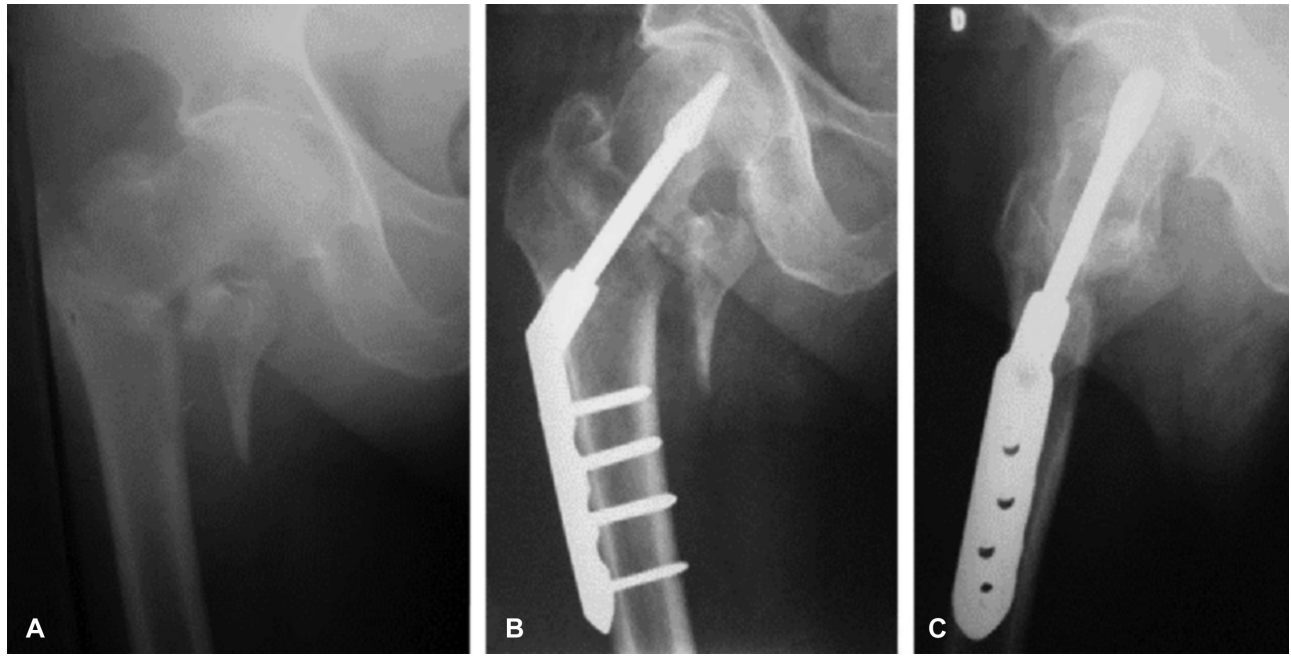


Fig. 1 A, Radiography of a right transtrochanteric fracture; B and C, fracture treated with a hip sliding screw (dynamic helical hip system [DHHS]).

with a sliding hip screw as the most frequent complication.¹⁻³

This paper reports a case of late arterial damage after proximal femoral osteosynthesis.

Case report

A caucasian, male, 87-year-old patient was brought to the emergency room within 3 hours after falling, presenting pain, functional disability and external rotation of the left lower limb. The radiographic examination showed a proximal fracture of the left femur, of the transtrochanteric type and classification AO classification 31-A2. The patient reported type II diabetes mellitus, diabetic polyneuritis, osteopenia, and systemic arterial hypertension as comorbidities.

The patient was successfully treated 24 hours after the fall with a nail type osteosynthesis and DHHS Synthes sliding plate (DePuy-Synthes companies of Johnson&Johnson) (► **Fig. 1**). Twenty-three days after the surgery, the patient presented sudden pain, and an important left lower limb functional disability, irradiating to the ipsilateral knee and increasing the diameter of the thigh (55 cm to 58 cm). Physical examination showed arterial hypotension (blood pressure 90 × 60 mm Hg), heart rate of 100 beats per minute, cold sweating and pallor; the packed cell volume was 16%, and the hemoglobin level was 58%.

Ultrasound examination of the left hip revealed a large soft-tissue infiltration with debris at the thigh, leg and lower abdominal quadrant.

An arteriography revealed an aneurysm lesion communicating with the left femoral leak.

The vascular surgeon decided to place two stents in the deep femoral artery; the patient presented a significant

improvement in the clinical picture and was discharged from the hospital (► **Fig. 2**).

Six months after the last surgical intervention, the patient complained of burning sensation and acute pulsatile pain in the medial thigh region and on the left knee, which worsened with dorsal recumbency and improved upon standing up. A computed tomography angiography identified a small trochanter bone spike piercing the deep femoral artery (► **Fig. 3A** and **B**). The patient underwent a new surgical procedure to remove the minor trochanter fragment injuring the deep femoral artery, which was sutured (► **Figs. 4** and **5**).

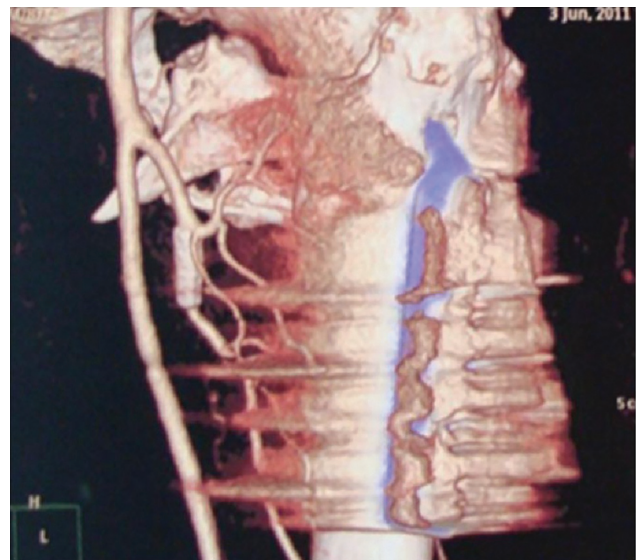


Fig. 2 Computed tomography angiography showing the minor trochanter deviation and the stented deep femoral artery.

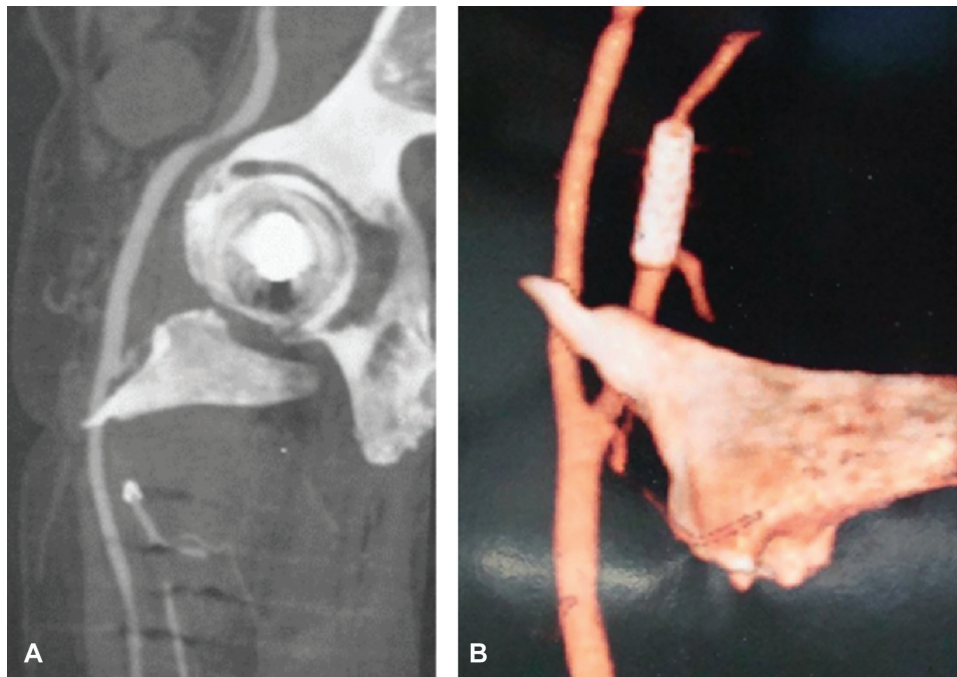


Fig. 3 A and B, Computed tomography angiography showing a minor trochanter piercing the deep femoral artery.

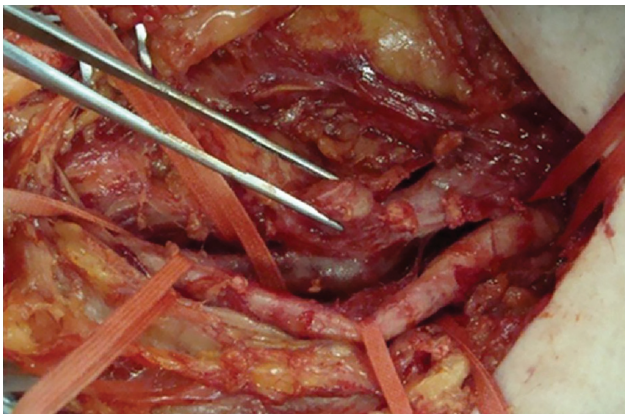


Fig. 4 Photograph showing anatomical tweezers at the deep femoral artery pseudoaneurysm.

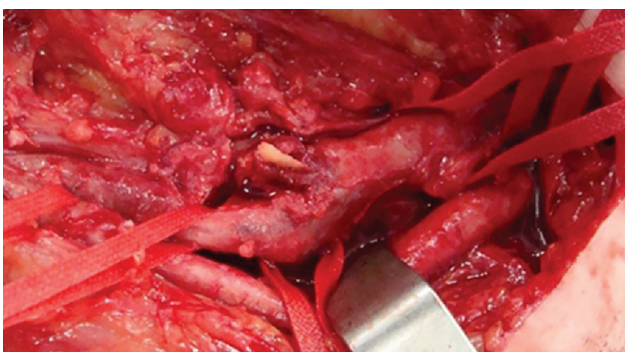

Fig. 5 Photograph showing a minor trochanteric bone fragment piercing the deep femoral artery.

Two days after the surgical intervention, the patient was discharged without further complications.

Discussion

The incidence of vascular compromise after hip fracture stabilization is rare. However, if present, these complications can cause limb dysfunction over time or even be life-threatening.

Barquet et al⁴ showed that most vascular lesions are extrapelvic (91.20%) instead of intrapelvic (8.24%). In the extrapelvic group, the prevalence of lesions in the deep femoral artery and its branches was as high as 78.31%. Few cases occurred in superficial femoral vessels (10.84%), and even fewer involved other thigh arteries. Our patient presented a lesion in the deep femoral artery, the most commonly involved artery.

Vascular lesion types include compression with blood flow restriction, intimal flap injury with decreased distal flow, intimal or atherosclerotic plaque rupture resulting in arterial thrombosis or thromboembolism, limb ischemia due to surgical ligation, acute hemorrhage by laceration or transection and perforation, and progressive arterial erosion, which produces a pseudoaneurysm or arteriovenous fistula.^{1,5,6} Arterial erosion is highly prevalent and results in the formation of a pseudoaneurysm. Our patient suffered two stages of arterial injury. The 1st one was compression with blood flow restriction, developing hip pain for a period of 1 year with thigh edema higher than 3 cm, which was treated by arterial stenting. Next, at a second stage, the patient presented acute pain in the inguinal region, with perforation, progressive arterial erosion, and the development of a pseudoaneurysm.

Vascular lesions may be caused by fracture fragments, predominantly the diverted minor trochanter.⁷ Barquet et al⁴ demonstrated seven non-iatrogenic lesions produced by minor trochanter or other bone fragments, both in patients submitted to the conservative treatment or after surgical fixation. Some authors recommend the perioperative monitoring of the minor trochanter with medial or proximal deviation, which may require fragment reduction, fixation or removal.⁸⁻¹⁰ Our patient presented a late femoral artery lesion with pseudoaneurysm formation due to a deviated minor trochanter 1 year after the fracture.

Vascular lesions after proximal femoral fractures mainly affect the deep femoral artery. Pseudoaneurysms are more frequent and reveal the late lesion diagnosis. The most frequent non-iatrogenic lesion is the one caused by a minor trochanteric fragment deviation.

Conflicts of interest

The authors declare that there are no conflicts of interest.

References

- 1 Karanikas I, Lazarides M, Arvanitis D, Papayanopoulos G, Exarchou E, Dayantas J. Iatrogenic arterial trauma associated with hip fracture surgery. *Acta Chir Belg* 1993;93(06):284-286
- 2 Klinger HM, Baums MH, Eckert M, Neugebauer R. [A comparative study of unstable per- and intertrochanteric femoral fractures treated with dynamic hip screw (DHS) and trochanteric buttress plate vs. proximal femoral nail (PFN)]. *Zentralbl Chir* 2005; 130(04):301-306
- 3 Garrido-Gómez J, Garrido-Gómez MN, Arrabal-Polo MA, Garrido-Pareja F, Linares-Palomino JP. Iatrogenic false aneurysms. A rare complication of hip surgery. *Hip Int* 2012;22(04):397-402
- 4 Barquet A, Gelink A, Giannoudis PV. Proximal femoral fractures and vascular injuries in adults: Incidence, aetiology and outcomes. *Injury* 2015;46(12):2297-2313
- 5 Hamoui M, Larbi A, Bommart S, Fauré P, Largey A, Canovas F. False aneurysm of perforating branch of the profunda femoris artery following intertrochanteric fracture, a rare vascular complication: clinical, radiological features and management: case report and review of the literature. *Eur J Orthop Surg Traumatol* 2010; 20:59-65
- 6 Neubauer T, Grechenig S, Leitner L, Auffarth A, Plecko M. Vascular complications in plating of the proximal femur: review. *Arch Orthop Trauma Surg* 2016;136(04):539-551
- 7 Keel JD, Eyres KS. Vascular injury by an intertrochanteric fracture fragment. *Injury* 1993;24(05):350-352
- 8 Entwisle JJ, De Nunzio M, Hinwood D. Case report: Transcatheter embolization of pseudoaneurysm of the profunda femoris artery complicating fracture of the femoral neck. *Clin Radiol* 2001;56 (05):424-427
- 9 Pradhan DJ, Juanteguy JM, Wilder RJ, Michelson E. Arterial injuries of the extremities associated with fractures. *Arch Surg* 1972;105 (04):582-585
- 10 Hanna GB, Holdsworth RJ, McCollum PT. Profunda femoris artery pseudoaneurysm following orthopaedic procedures. *Injury* 1994; 25(07):477-479