



Acetabularization as a Protective Factor in Rotator Cuff Arthropathy*

A acetabularização como fator protetor na artropatia do manguito rotador

Leonardo Roure Esteves¹  Carlos Vicente Andreoli¹  Eduardo Antonio de Figueiredo¹ 
 Paulo Santoro Belangero¹  Alberto de Castro Pochini¹  Benno Ejnisman¹ 

¹Department of Orthopedics and Traumatology, Universidade Federal de São Paulo (Unifesp), São Paulo, SP, Brazil.

Address for correspondence Leonardo Roure Esteves, Departamento de Ortopedia e Traumatologia, Universidade Federal de São Paulo (Unifesp), Rua Borges Lagoa 570, Vila Clementino, São Paulo, SP, 04038-000, Brazil (e-mail: leo_esteves@hotmail.com).

Rev Bras Ortop 2020;55(4):476–482.

Abstract

Objective To check if shoulders with acetabularization have better functional results in cases of rotator cuff arthropathy.

Methods A clinical and radiological cross-sectional evaluation of 65 shoulders with rotator cuff arthropathy by measuring the range of motion (RoM) of the shoulder, the Constant-Murley score, and the radiological classifications of Hamada and Seebauer. The clinical findings were compared with the radiographic findings.

Results According to the classification of Seebauer, we observed better results regarding the RoM in type-A shoulders. There was a statistically significant difference regarding anterior elevation and medial rotation between types A and B ($p < 0.05$). Lateral rotation did not show a statistically significant difference between types A and B. The Constant-Murley score presented better results in type A, and there was a statistically significant difference between groups A and B ($p < 0.05$). According to the classification of Hamada, we observed that the RoM had better results in types 3, 2 and 1, and there was a statistically significant difference regarding anterior elevation and medial rotation ($p < 0.05$) compared with groups 4A, 4B and 5. There was no statistically significant difference between the Hamada groups regarding lateral rotation. According to Hamada, the Constant-Murley score showed better results in types 3, 1 and 2, and there was a statistically significant difference between groups 3 and 5.

Conclusion The RoM and shoulder function were better in patients with acetabularization (Seebauer 1A and Hamada 3), and worse in those with glenohumeral arthrosis (Seebauer 1B, 2B and Hamada 4A, 4B and 5).

Keywords

- ▶ rotator cuff tear arthropathy
- ▶ shoulder joint
- ▶ rotator cuff injuries

Resumo

Objetivo Verificar se os ombros com acetabularização têm melhores resultados funcionais nos casos de artropatia do manguito rotador.

* Work performed at the Center of Sports Traumatology (CETE), Department of Orthopedics and Traumatology, Universidade Federal de São Paulo (Unifesp), São Paulo, SP, Brazil.

Métodos Avaliação transversal clínica e radiológica de 65 ombros com artropatia do manguito rotador por meio da mensuração da amplitude de movimento (ADM) do ombro, do escore de Constant-Murley, e das classificações radiológicas de Hamada e Seebauer. Os achados clínicos foram comparados com os radiográficos.

Resultados Segundo a classificação de Seebauer, com relação à ADM, observamos melhores resultados nos tipos A. Houve diferença estatística significativa na elevação anterior, e rotação medial entre os tipos A e B ($p < 0.05$). A rotação lateral não demonstrou diferença estatística significativa entre os tipos A e B. O escore de Constant-Murley apresentou melhores resultados nos tipos A, e houve diferença estatística significativa entre os grupos A e B ($p < 0,05$). Segundo a classificação de Hamada, observamos que a ADM teve melhores resultados nos tipos 3, 2 e 1, e houve diferença estatística significativa para a elevação anterior e a rotação medial ($p < 0,05$) quando comparadas com os grupos 4A, 4B e 5. Não houve diferença estatística significativa entre os grupos de Hamada em relação à rotação lateral. Ainda segundo Hamada, o escore de Constant-Murley apresentou melhores resultados nos tipos 3, 1 e 2, e houve diferença estatística significativa entre os grupos 3 e 5.

Conclusão A ADM e a função do ombro apresentavam-se melhores nos pacientes com acetabularização (Seebauer 1A e Hamada 3), e piores naqueles com artrose glenoumeral (Seebauer 1B, 2B e Hamada 4A, 4B e 5).

Palavras-chave

- ▶ artropatia de ruptura do manguito rotador
- ▶ articulação do ombro
- ▶ lesões do manguito rotador

Introduction

Rotator cuff arthropathy (RCA) is a possible evolution for rotator cuff chronic lesions.¹⁻³ It is usually associated with mobility deficit and an important shoulder pain scenario. However, we observed varying degrees of pain and range of motion (RoM),^{4,5} including asymptomatic patients.

Rotator cuff arthropathy can develop with shoulder arthritis, bone erosion, osteopenia, decreased RoM and pain. Its pathophysiology is not fully understood, and there are mechanical theories (due to muscle imbalance), and theories involving nutrition and the deposition of calcium phosphate crystals. It mainly affects the female gender, the dominant limb and the elderly.⁶⁻⁸ Its clinical picture involves pain mainly related to movement and nocturnal pain, joint effusion, muscular weakness and decreased RoM in varying degrees.⁹⁻¹¹

In order to perform the present work, we assumed that, within the group of patients with RCA, there are those with intense pain and impaired shoulder mobility, and those who have controlled pain and satisfactory mobility to carry out their daily tasks. We also think that there is an adaptive phase in RCA, in which the shoulder should stabilize and consequently present satisfactory mobility and controlled pain.

In our clinical practice, we perceive that there could be a clinico-radiographic incompatibility, and that the radiographs do not always have a direct relationship with pain and shoulder function.

The objective of the present study was to functionally evaluate patients with RCA, correlating function and shoulder pain with the radiographic findings according to the Seebauer and the Hamada classifications, which are the two main radiographic classifications for this pathology (► **Figures 1** and **2**). More specifically, we seek to verify whether acetabularization

(concave deformity in the inferior surface of the acromion⁹) influences the functional results.

Materials and methods

The present is a cross-sectional descriptive study performed from December 2016 to January 2019 with patients with RCA. The inclusion criteria were: patients with rotator cuff arthropathy submitted to anteroposterior radiography of the shoulder, magnetic resonance imaging of the shoulder, and physical examination directed with evaluation of anterior elevation, lateral rotation, medial rotation and filling out the Constant-Murley score. The exclusion criteria were: previous neurological lesions with involvement of the studied shoulder, previous fracture of the shoulder, previous surgery, agenesis, and malformations of the shoulder. The present study was approved by the Ethics in Research Committee and by the Plataforma Brazil database under CAAE 79222017.0.0000.5505.

A total of 65 shoulders were studied. The mean age of the patients was 73 years old (range: 60 years to 88 years), and there were 11 men (16.9%) and 54 women (83.1%). There were 41 dominant (63.1%) and 23 non-dominant limbs (35.4%), in addition to 1 ambidextrous patient (1.5%) and 7 cases of bilateral impairment (10.8%). The duration of the pain ranged from 3 months to 30 years, with an average of 5 years.

The physical examination and the classification of the shoulders were performed by a single observer, an orthopedist and shoulder and elbow surgeon. Separating patients according to the Seebauer classification, there were 27 type-1A cases, 8 type-1B cases, 24 type-2A cases, and 6 type-2B cases. Taking into account the Hamada classification, there were 11 type-1 cases, 12 type-2 cases, 18 type-3 cases, 8 type-4A cases, 9 type-4B cases, and 7 type-5 cases.

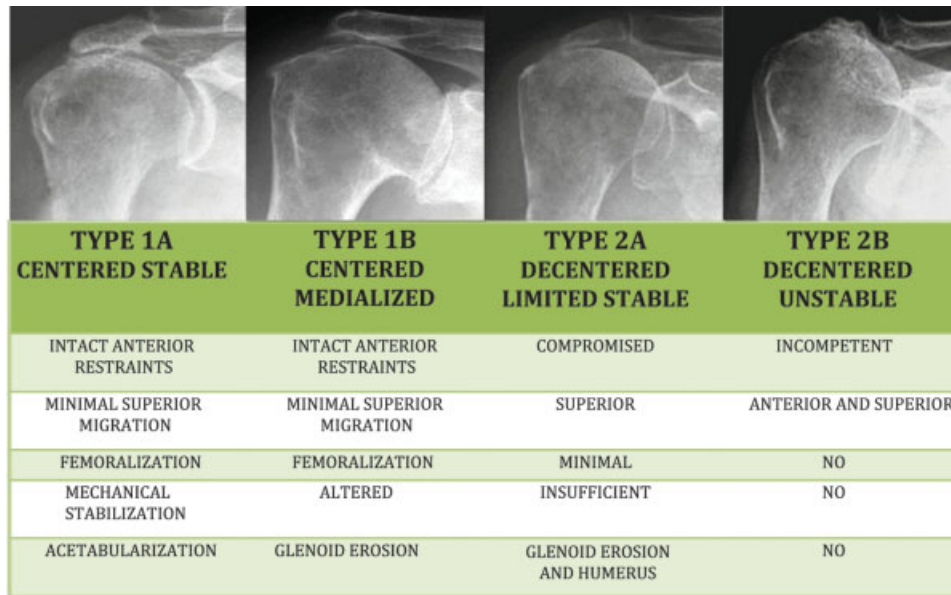


Fig. 1 Anteroposterior radiographs of the shoulder and Seebauer classification.

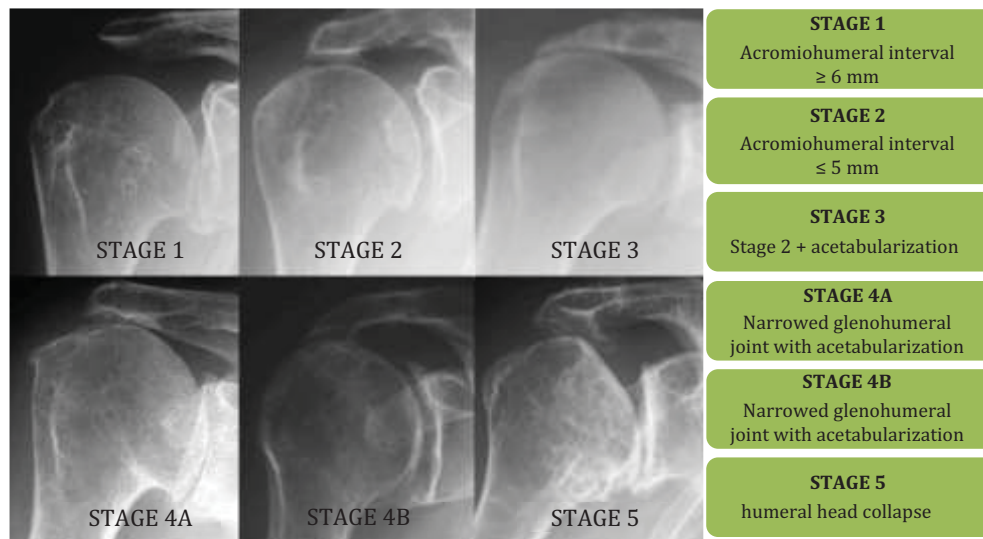


Fig. 2 Anteroposterior radiographs of the shoulder and Hamada classification.

In total, 6 patients reported having no pain (according to the Seebauer classification, 3 type-1A cases and 3 type-2A cases; according to the Hamada classification, 4 type-3 cases, 1 type-1 case, and 1 type-2 case), and 6 patients reported not having shoulder mobility deficit (according to the Seebauer classification, 5 type-1A cases, 1 type-2A case; according to the Hamada classification, 3 type-3 cases, 2 type-1 cases, and 1 type-4a case).

For the statistical analysis, a significance level of 0.05 and confidence intervals of 95% were established. Parametric tests were used for the quantitative and continuous variables. The distribution of the data was normal, and we used the following software: the Statistical Package for the Social Sciences (SPSS, IBM Corp., Armonk, NY, US), version 20.0, Minitab (Minitab, LLC, State College, PA, US), version 16, and Excel 2010 (Microsoft Corp. Redmond, WA, US). We also used

analysis of variance (ANOVA) and Tukey multiple comparison tests.

Results

All of the patients presented complete lesion of the supraspinatus and infraspinatus tendons. The subscapular tendon had a distribution of 27.7% with complete lesion (the entire extension of the tendon), 47.7% with partial lesion (part of the tendon extension), 1.5% normal, and 23.1% with tendinopathy. In relation to the long head of the biceps, 47.7% were absent, and 52.3% were present.

According to the Seebauer classification, regarding RoM, we observed better results in cases of type A (the best results were found among group 1A, with averages of 147.41 degrees of anterior elevation, 37.59 degrees of lateral rotation, and 49.59

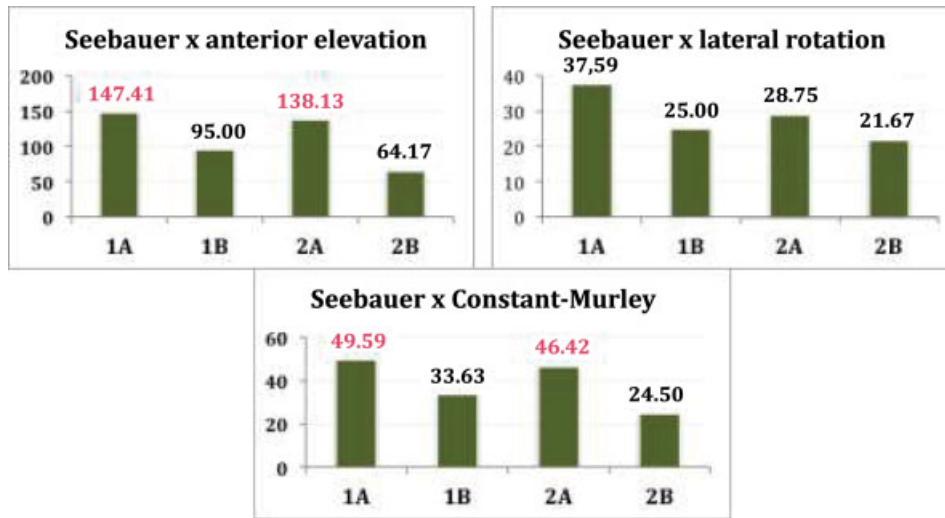


Fig. 3 Charts of the existing relationships between the Seebauer classification types and the values of the averages of the anterior elevation, lateral rotation (with their averages in degrees) and Constant-Murley score (with the average in points).

points in the Constant-Murley score). There was statistically significant difference in anterior elevation and medial rotation between types A and B ($p < 0.05$). Lateral rotation showed no statistically significant difference between types A and B ($P > 0.05$). The Constant-Murley score presented better results in cases of type A, and there was a statistically significant difference between groups A and B ($p < 0.05$) (► **Figures 3 and 4**).

According to the classification of Hamada, we observed that RoM had better results in cases of types 3, 2 and 1 (type 3 presented the best results for anterior elevation and Constant-Murley score averages, with 162.22 degrees and 59.50 points respectively. Regarding the lateral rotation, the best result was the mean of 40 degrees found in cases of type 1 followed by 36.11 degrees in cases of type 3). There was a statistically significant difference regarding anterior elevation and medial rotation ($p < 0.05$) when those groups were compared with groups 4a, 4b and 5. There was no statistically significant difference between the Hamada groups in rela-

tion to lateral rotation ($p > 0.05$). Still according to the Hamada classification, the Constant-Murley score presented better results in cases of types 3, 1 and 2, and there was a statistically significant difference ($p < 0.05$) between groups 3 and 5 (► **Figures 5 and 6**).

Discussion

In our literature search, we perceived that RCA is regarded as a single group. There are studies comparing pre- and post-operative function and pain in the case of treatment of RCA with shoulder prostheses,¹¹⁻¹³ but no studies that report the great clinical variation that exists within the RCA group in relation to pain and RoM have been found.

We evidenced that RCA patients had varying degrees of mobility deficit and different intensities of pain, and some patients even report feeling no pain. In the literature, we did not find studies that attempted to divide the large group of patients with RCA into subgroups to try to understand the

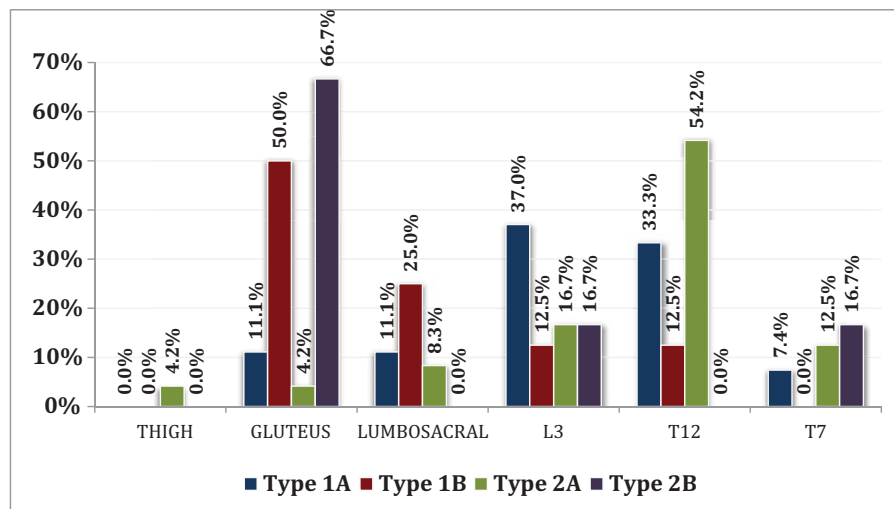


Fig. 4 Graph of the relationship between the Seebauer classification types and the distribution of the medial rotation.

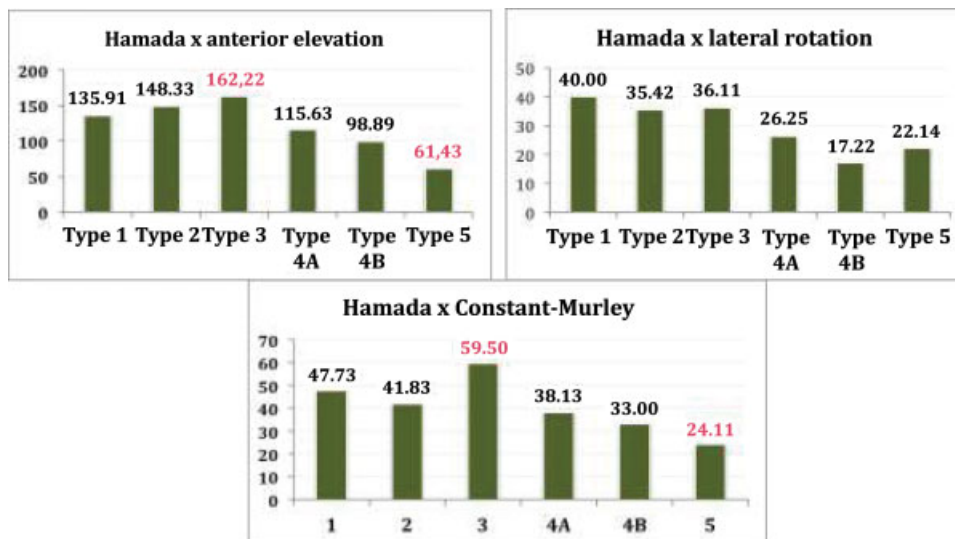


Fig. 5 Charts of the existing relationships between the Hamada classification types and the values of the averages of the anterior elevation, lateral rotation (with its averages in degrees) and Constant-Murley score (with the average in points).

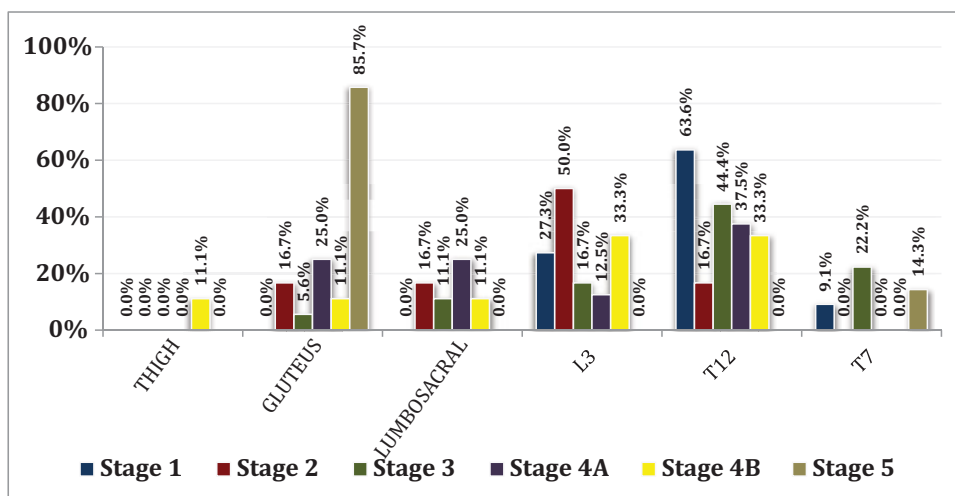


Fig. 6 Graph of the relationship between the Hamada classification types and the distribution of the medial rotation.

heterogeneity of these patients, nor the factors that could contribute to this clinical difference.

The use of the Seebauer and Hamada classifications enabled us to evidence the factors that may contribute for this clinical difference. In our study, we showed a correlation between worse function and worse RoM (medial rotation and elevation) in the type-B groups (1b and 2b) of Seebauer and in types 4a, 4b and 5 of Hamada. We can then consider that these potentially are the groups that benefited the most from the surgical treatment, either by hemiarthroplasty or by reverse shoulder arthroplasty.

On the other hand, patients who presented better mobility and better function were those of type A (1A and 2A) of Seebauer and Hamada types 1, 2 and 3. Within this group, we could still divide types 1A of Seebauer and 3 of Hamada as the ones that would have a better chance of achieving good results with the conservative treatment, because they presented the best functional outcomes among all groups studied.

Acetabularization probably acts as a stabilizing factor for the shoulder. Amaral et al.¹³ demonstrated, in their 2014 study, postoperative results with reverse arthroplasty of the shoulder for RCA treatment, with a mean elevation of 150 degrees and mean Constant-Murley score of 60 points, a similar score found in our study on the shoulders that presented acetabularization without glenohumeral arthrosis (Seebauer 1A, with an average anterior elevation of 147.41 degrees and a mean Constant-Murley score of 49.59 points. Hamada 3 with average anterior elevation of 162.22 degrees, and a mean Constant-Murley score of 59.50 points). This radiographic finding is, therefore, a potential indicator of conservative treatment for RCA.

In the present study, the highest incidence of patients without pain complaints and patients without complaints regarding RoM was observed in the groups who presented acetabularization.

The condition of the long head of the biceps and the subscapular tendon are factors that could interfere in the RoM of the shoulder. According to the Seebauer

Table 1 Distribution of the long head of the biceps and subscapular in the Seebauer classification types

Seebauer		Type 1A		Type 1B		Type 2A		Type 2B		Total		p-value
		n	%	n	%	n	%	n	%	n	%	
Long head of the biceps	Absent	9	33.3%	5	62.5%	12	50.0%	5	83.3%	31	47.7%	0.110
	Present	18	66.7%	3	37.5%	12	50.0%	1	16.7%	34	52.3%	
Subscapular	Complete injury	6	22.2%	3	37.5%	5	20.8%	4	66.7%	18	27.7%	0.489
	Partial injury	15	55.6%	4	50.0%	11	45.8%	1	16.7%	31	47.7%	
	Normal	0	0.0%	0	0.0%	1	4.2%	0	0.0%	1	1.5%	
	Tendinopathy	6	22.2%	1	12.5%	7	29.2%	1	16.7%	15	23.1%	

Table 2 Distribution of the long head of the biceps and subscapular in the Hamada classification types

HAMADA		Type 1		Type 2		Type 3		Type 4A		Type 4B		Type 5		Total		p-value
		n	%	n	%	n	%	n	%	n	%	n	%	n	%	
Long head of the biceps	Absent	4	36.4%	2	16.7%	8	44.4%	6	75.0%	7	77.8%	4	57.1%	31	47.7%	0.048
	Present	7	63.6%	10	83.3%	10	55.6%	2	25.0%	2	22.2%	3	42.9%	34	52.3%	
Subscapular	Complete injury	0	0.0%	4	33.3%	3	16.7%	4	50.0%	4	44.4%	3	42.9%	18	27.7%	0.427
	Partial injury	9	81.8%	4	33.3%	9	50.0%	3	37.5%	4	44.4%	2	28.6%	31	47.7%	
	Normal	0	0.0%	0	0.0%	1	5.6%	0	0.0%	0	0.0%	0	0.0%	1	1.5%	
	Tendinopathy	2	18.2%	4	33.3%	5	27.8%	1	12.5%	1	11.1%	2	28.6%	15	23.1%	

classification, the distribution of absence or presence of the long head of the biceps did not present a statistical significance, but was more present in cases of type A. The presence or absence of the subscapular tendon also did not present a statistical significance among the Seebauer groups (► **Table 1**). Therefore, no positive or negative interference could be attributed to the results found in the present study regarding these parameters.

According to the Hamada classification, the statistical difference between groups 1, 2 and 3 was evident, with predominance of the presence of the long head of the biceps, and groups 4a, 4b and 5 with predominance of its absence. This result may have contributed to the best functional outcomes of groups 1, 2 and 3; therefore, considering the evolutionary aspect of the Hamada classification, the long head of the biceps could act as a humeral head depressor and prevent the progression of arthropathy, as evidenced by Garcia et al.¹⁴ in their 2018 study. Regarding the subscapular tendon, there was no statistically significant difference among the groups (► **Table 2**), which leads to the belief that this parameter did not influence the functional results in the studied shoulders.

Because the present is a cross-sectional study, there is doubt whether the Seebauer and Hamada classifications follow an evolutionary pattern or if there are groups that evolve differently. A group could evolve with stability, muscular balance of the shoulder, without arthrosis, with a favorable clinical scenario, and another group, with instability, muscular imbalance, glenohumeral arthrosis and unfavorable clinical scenario. A longitudinal study could help clarify this issue.

Conclusion

Acetabularization, without glenohumeral arthrosis, has been shown to be associated with cases with better shoulder functional results in patients with RCA diagnosis, which can be considered a protective factor.

Conflict of Interests

The authors have no conflict of interests to declare.

References

- Constant CR, Murley AH. A clinical method of functional assessment of the shoulder. *Clin Orthop Relat Res* 1987;(214):160-164
- Gerber C. Integrated scoring systems for the functional assessment of the shoulder. In: Matsen FA 3rd, Fu FH, Hawkins RJ, editors. *The shoulder: a balance of mobility and stability*. Rosemont, IL: American Academy of Orthopaedic Surgeons; 1993: 531-550
- Jensen KL, Williams GR Jr, Russell IJ, Rockwood CA Jr. Rotator cuff tear arthropathy. *J Bone Joint Surg Am* 1999;81(09):1312-1324
- Neer CS II, Craig EV, Fukuda H. Cuff-tear arthropathy. *J Bone Joint Surg Am* 1983;65(09):1232-1244
- Kirkley A. Scoring systems for the functional assessment of the shoulder. *Tech Shoulder Elbow Surg* 2002;3(04):220-233
- Visotsky JL, Basamania C, Seebauer L, Rockwood CA, Jensen KL. Cuff tear arthropathy: pathogenesis, classification, and algorithm for treatment. *J Bone Joint Surg Am* 2004;86-A(Suppl 2):35-40
- Wall B, Nové-Josserand L, O'Connor DP, Edwards TB, Walch G. Reverse total shoulder arthroplasty: a review of results according to etiology. *J Bone Joint Surg Am* 2007;89(07):1476-1485
- Bedi A, Dines J, Warren RF, Dines DM. Massive tears of the rotator cuff. *J Bone Joint Surg Am* 2010;92(09):1894-1908

- 9 Hamada K, Yamanaka K, Uchiyama Y, Mikasa T, Mikasa M. A radiographic classification of massive rotator cuff tear arthritis. *Clin Orthop Relat Res* 2011;469(09):2452–2460
- 10 Kappe T, Cakir B, Reichel H, Elsharkawi M. Reliability of radiologic classification for cuff tear arthropathy. *J Shoulder Elbow Surg* 2011;20(04):543–547
- 11 Nam D, Maak TG, Raphael BS, Kepler CK, Cross MB, Warren RF. Rotator cuff tear arthropathy: evaluation, diagnosis, and treatment: AAOS exhibit selection. *J Bone Joint Surg Am* 2012;94(06):e34
- 12 Paxton ES, Teefey SA, Dahiya N, Keener JD, Yamaguchi K, Galatz LM. Clinical and radiographic outcomes of failed repairs of large or massive rotator cuff tears: minimum ten-year follow-up. *J Bone Joint Surg Am* 2013;95(07):627–632
- 13 Amaral MVG, Faria JLR, Siqueira G, et al. Artroplastia reversa do ombro no tratamento da artropatia do manguito rotador. *Rev Bras Ortop* 2014;49(03):279–285
- 14 García-Rellán JE, Sánchez-Alepuz E, Mudarra-García J. Increased fatigue of the biceps after tenotomy of the long head of biceps tendon. *Knee Surg Sports Traumatol Arthrosc* 2018;26(12):3826–3831