


# Surgical Treatment of Post-traumatic Elbow Stiffness by Wide Posterior Approach\*

## *Tratamento cirúrgico da rigidez pós-traumática do cotovelo por via posterior ampla*

Mauro E.C. Gracitelli<sup>1</sup>  César L.B. Guglielmetti<sup>1</sup> Caio A.S. Botelho<sup>1</sup> Eduardo A. Malavolta<sup>1</sup>  
Jorge H. Assunção<sup>1</sup> Arnaldo A. Ferreira Neto<sup>1</sup>

<sup>1</sup> Shoulder and Elbow Group, Instituto de Ortopedia e Traumatologia, Hospital das Clínicas, Faculty of Medicine, Universidade de São Paulo, São Paulo, SP, Brazil

Address for correspondence Mauro E. C. Gracitelli, PhD, Rua Dr. Ovídio Pires de Campos, 333, 3° andar, Cerqueira Cesar, São Paulo, SP, 05403-010, Brazil (e-mail: mgracitelli@gmail.com).

Rev Bras Ortop 2020;55(5):570–578.

### Abstract

**Objective** To demonstrate the clinical outcomes and complication rates of the surgical release with a single posterior approach in the treatment of post-traumatic elbow stiffness.

**Methods** A prospective study with patients submitted to surgery between May 2013 and June 2018 in a single center. The access to the elbow was made through the posterior approach. The patients were followed up by an occupational therapy team, and were submitted to a standardized rehabilitation protocol, with static progressive orthoses and dynamic orthoses. The primary outcome was the range of flexion-extension of the elbow after 6 months.

**Results** A total of 26 patients completed the minimum follow-up of 6-months. The mean range of flexion-extension of the elbow at the end of 6 months was of  $98.3 \pm 22.0^\circ$ , with an amplitude gain of  $40.0 \pm 14.0^\circ$  in relation to the pre-operative period ( $p < 0.001$ ). The average flexion-extension gain at the end of 6 months was of  $51.7\% \pm 17.1\%$  ( $p < 0.001$ ). The mean pronosupination at the end of 6 months was of  $129.0 \pm 42.7^\circ$  ( $p < 0.001$ ). Half of the cases had moderate and severe stiffness in the pre-operative period, compared with 7.7% at 6 months post-operatively ( $p < 0.001$ ). The mean score for the Mayo Elbow Performance Score (MEPS) and Disabilities of the Arm, Shoulder and Hand (DASH) instruments was  $74.4 \pm 16.8$  points and  $31.7 \pm 21.9$  points respectively ( $p < 0.001$  for both). The visual analogue scale (VAS) score presented no statistically significant difference compared to the pre-operative period ( $p = 0.096$ ). Complications were observed in 6 (23%) patients, and no new surgical procedures were necessary.

**Conclusions** The surgical release of the elbow associated with a rehabilitation protocol is a safe technique, with satisfactory results and low rate of complications.

### Keywords

- ▶ elbow joint
- ▶ contracture
- ▶ post-traumatic stiffness
- ▶ joint capsule release
- ▶ treatment outcome

\* Study developed at Shoulder and Elbow Group, Instituto de Ortopedia e Traumatologia, Hospital Das Clínicas, Faculty of Medicine, Universidade de São Paulo (HCFMUSP), São Paulo, SP, Brazil.

## Resumo

**Objetivo** Demonstrar os resultados clínicos e a taxa de complicações da liberação cirúrgica por via única posterior no tratamento da rigidez pós-traumática de cotovelo.

**Métodos** Estudo prospectivo, com pacientes submetidos a cirurgia entre maio de 2013 e junho de 2018 em um único centro. Foi realizado acesso ao cotovelo por via posterior. O seguimento dos pacientes foi feito por uma equipe de terapia ocupacional, e eles foram submetidos a um protocolo de reabilitação padronizado, com órteses estáticas progressivas e dinâmicas. O desfecho primário foi a amplitude de flexoextensão do cotovelo após 6 meses.

**Resultados** Um total de 26 pacientes completaram o seguimento mínimo de 6 meses. A média de flexoextensão do cotovelo, ao final de 6 meses, foi de  $98,3^\circ \pm 22,0^\circ$ , com um ganho de amplitude de  $40,0^\circ \pm 14,0^\circ$  em relação ao pré-operatório ( $p < 0,001$ ). A média de ganho relativo de flexoextensão, ao final de 6 meses, foi de  $51,7\% \pm 17,1\%$  ( $p < 0,001$ ). A média de pronosupinação, ao final de 6 meses, foi de  $129,0^\circ \pm 42,7^\circ$  ( $p < 0,001$ ). Metade dos casos apresentava rigidez moderada e grave no pré-operatório, contra 7,7% aos 6 meses de pós-operatório ( $p < 0,001$ ). A pontuação pelos instrumentos Mayo Elbow Performance Score (MEPS) e Disabilities of the Arm, Shoulder and Hand (DASH) apresentou melhora estatisticamente significativa em relação ao pré-operatório, atingindo  $74,4 \pm 16,8$  pontos e  $31,7 \pm 21,9$  pontos, respectivamente. A escala visual analógica (EVA) não apresentou diferença estatisticamente significativa em relação ao pré-operatório ( $p = 0,096$ ). Complicações foram observadas em 6 (23%) pacientes, não sendo necessária nova abordagem cirúrgica em nenhum paciente.

**Conclusões** A liberação cirúrgica do cotovelo associada a protocolo de reabilitação é técnica segura, com resultados satisfatórios e baixa taxa de complicações.

## Palavras-chave

- ▶ articulação do cotovelo
- ▶ contratura
- ▶ rigidez pós-traumática
- ▶ liberação da cápsula articular
- ▶ resultado do tratamento

## Introduction

The elbow has the function of moving and positioning the hand in space.<sup>1</sup> Its range of motion (ROM) is essential for most daily activities. It is accepted that the functional elbow ROM is between  $-30^\circ$  of extension to  $130^\circ$  of flexion, and  $100^\circ$  of pronosupination, with  $50^\circ$  in each direction.<sup>2</sup> Modern-day activities, such as using computers and mobile phones, apparently require higher pronation and flexion respectively than defined in functional ROM.<sup>3</sup>

Post-traumatic elbow stiffness is defined as the loss of any degree of movement after trauma, but most authors consider referral for treatment only when there is loss of functional ROM.<sup>4-6</sup> The true incidence of post-traumatic elbow stiffness is not known. Approximately 12% of elbow injuries result in contractures that require some type of surgical release.<sup>7,8</sup>

The treatment of post-traumatic elbow stiffness presents numerous challenges. Due to the variability of lesions, causes and symptoms, there are great difficulties in the homogenization of the protocols and in the comparison of results between different treatments. Patients with different levels of severity, stiffness time, pain and arthrosis, evolve in different ways under similar treatments.<sup>9-12</sup>

Considering the post-traumatic elbow stiffness patients without vicious consolidation, pseudarthrosis, intra-articular synthesis material or heterotopic ossification (HO) and no

improvement with conventional physical therapy, there are two treatment options:<sup>13,14</sup> surgical release or rehabilitation protocols with occupational therapy, with mild and progressive mobilization associated with the use of orthoses.

Several surgical techniques have been described for the treatment of post-traumatic elbow stiffness, from the most aggressive, with extensive release associated with an external fixator,<sup>15</sup> to the minimally-invasive<sup>5</sup> and those by arthroscopic approach.<sup>16</sup> The authors report good results with significant gains both in function and elbow ROM, with complication rates ranging from 0% to 88%.<sup>6</sup> However, there are few studies with a good level of evidence, with only two prospective case series.<sup>14,17</sup>

Our goal is to demonstrate the clinical outcomes and complication rates of an open release technique, by single posterior approach, without the use of external fixator, followed by a standardized rehabilitation protocol. The primary outcome of the present study is to evaluate the flexion-extension ROM of the patients. The secondary outcomes are to evaluate the clinical outcome according to the Mayo Elbow Performance Score (MEPS) scale,<sup>18</sup> the Disability of the Arm, Shoulder and Hand (DASH) questionnaire,<sup>19</sup> and the Visual Analog Scale (VAS) for pain, the absolute and relative gain of flexion ROM,<sup>20</sup> the maximum flexion and extension, the pronosupination ROM, and the complication rate.

## Materials and Methods

### Study Design

We conducted a prospective study involving 33 patients with post-traumatic elbow stiffness. The patients underwent surgery between May 2013 and June 2018 in a single center. The surgeries were performed by two surgeons following the same surgical technique. The protocol was approved by Ethics Committee of our service and registered in the Plataforma Brasil database.

### Participants

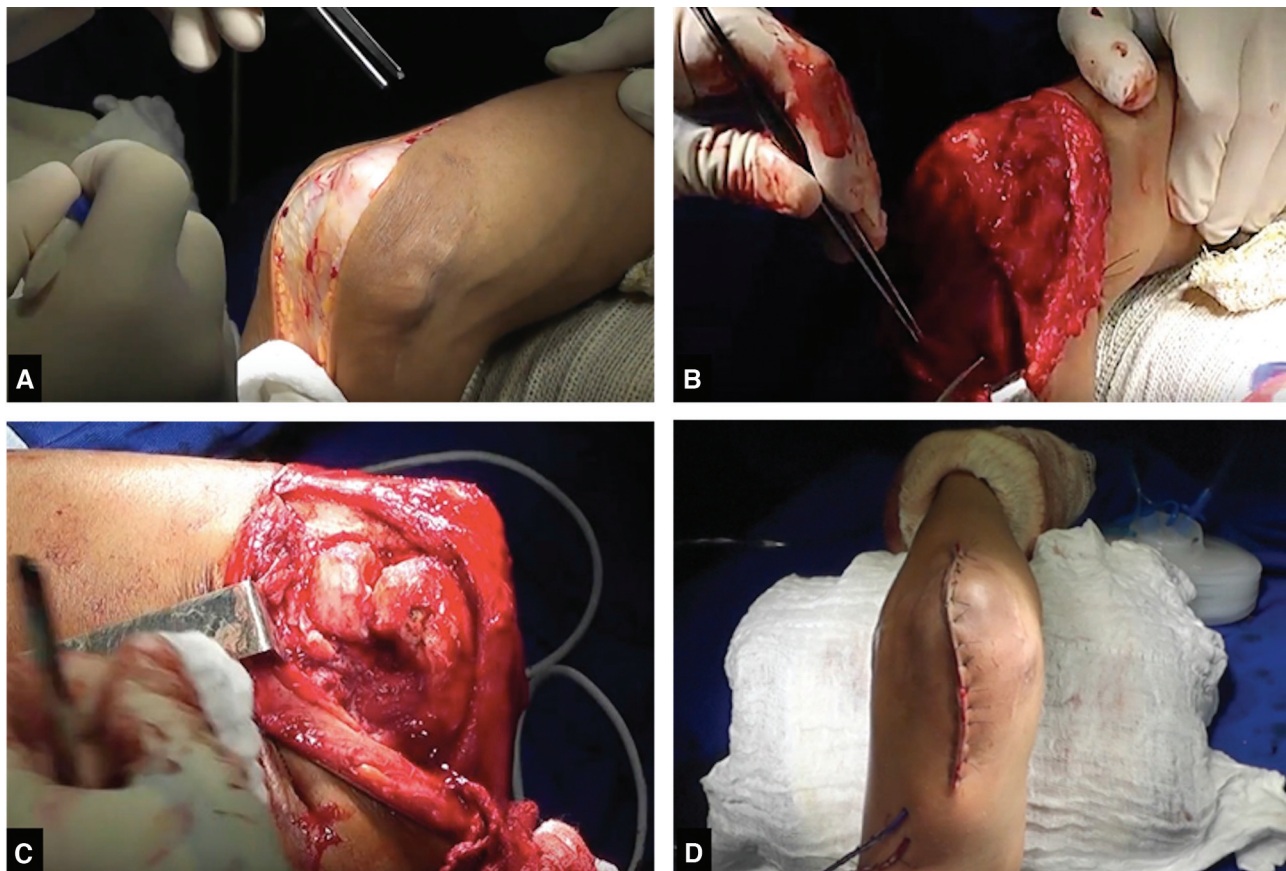
The inclusion criteria were age between 18 and 65 years, previous history of trauma that evolved with elbow joint stiffness, elbow flexion-extension ROM lower than 100°, or maximum range lower than -30°, or maximal flexion lower than 130°, more than 6 months after the initial trauma. Patients with joint block (range of motion equal to 0°), neurological injury in the affected upper limb, mental illness or inability to understand the questionnaires, previous elbow infection and HO, were not included.

### Intervention

The surgeries started after interscalene brachial plexus block associated with general anesthesia without tourniquet placement. The patients were positioned in the supine position. All patients received prophylactic antibiotic treat-

ment with 1 g of cefazolin intravenously every 8 hours for a period of 24 hours, with the first dose administered 30 minutes before the beginning of the surgery.

A wide posterior access to the elbow with 12 cm to 15 cm was performed, deviating laterally from the tip of the olecranon. The ulnar nerve was identified, released and protected, followed by lateral and medial dissection of the triceps brachii muscle to the humerus, without disinsertion of the triceps tendon. The forearm extensor mass was elevated from the anterior capsule, followed by the release of its humeral insertion together with the lateral collateral ligament. The posterior portion of the medial collateral ligament was released. We performed the release of joint adhesions between the triceps brachii and humerus muscles, excision of periarticular osteophytes, debridement and cleaning of the olecranon fossa, and release of the anterior capsule of the distal portion of the humerus. After complete release and full ROM gain, the lateral and medial collateral ligaments were reinserted with non-absorbable transosseous Ethibond Excel 2-0 (Johnson&Johnson, New Brunswick, NJ, US) sutures. Prior to closure by planes, the maintenance of the ROM was checked, and a vacuum drain was placed in all cases around the joint in order not to be lodged into it. Anterior subcutaneous transposition of the ulnar nerve was performed. The dressing was performed with gauze and bandage followed by immobilization to the maximum extent with an anterior plaster cast. The technique used is demonstrated in the supplementary video to the article and in **Figure 1**.



**Fig. 1** Image of the surgical technique. (A) Wide posterior approach; (B) medial dissection and ulnar nerve location; (C) lateral dissection and visualization of the radio head and capitulum; (D) closing and final aspect with vacuum drain placement.



The patients were hospitalized for three days for pain control, edema control (keeping the limb raised) and early mobilization. They were followed up by the occupational therapy team, and underwent a standardized rehabilitation protocol. On the first post-operative day, the occupational therapy team performed the attachment of a full-length polyethylene orthosis, which was used full time, being removed only for cleaning and for exercise. The patients underwent daily continuous passive motion (CPM) for one hour during hospitalization and twice a week after hospital discharge, during occupational therapy sessions. They performed free and assisted active exercises during the day (extension, flexion, pronation and supination), and were encouraged to perform daily activities without load on the limb. The patients learned during occupational therapy sessions to perform home exercises, aiming not to overcome four pain points according to the VAS. They were instructed to perform daily home exercises every 2 hours for 5 to 10 minutes. The vacuum drain was removed 48 hours after surgery, and the CPM was performed using the drain. In the first week, they used the static orthosis for extension, removing it for cleaning and home exercises. After this period, they used it only during sleep. One month after surgery, they began using the dynamic orthosis, to gain flexion, 3 times a day for 30-minute periods. The orthoses were readjusted as needed during the occupational therapy sessions, and they are shown in **Figure 2**.

### Outcomes

The primary outcome of the study was elbow flexion-extension ROM after 6 months of surgery.

The secondary outcomes were the MEPS and VAS scales, the DASH questionnaire, pronosupination ROM, the relative gain of ROM, the incidence of clinical and radiographic complications, and need for a new surgical approach. The results of the MEPS scale were categorized as excellent (> 90 points), good (between 75 and 89 points), regular (between 60 and 74) and poor (< 60).

### Analyzed Variables

The elbow flexion-extension ROM was evaluated in degrees, with the help of a hand goniometer used by a trained

evaluator (who was not part of the rehabilitation team), with the patient standing upright and with shoulder raised to 90°. Regarding pronosupination, the patient was evaluated with the shoulder in adduction and neutral rotation and with the elbow flexed at 90°. With his/her hand, the patient held a stick.

Other clinical variables were evaluated, such as general characteristics (gender, age, hand dominance and affected side); habits (smoking); pre-existing diseases (diabetes, high blood pressure and hypothyroidism); and presence of previous fractures or previous treatment performed (surgical or conservative).

Prior to treatment, all patients were submitted to frontal and profile computed tomography and radiographs of the elbow. The presence of loose bodies and osteophytes, the degree of joint degeneration,<sup>21</sup> and the presence of synthesis material were evaluated.

Complications were recorded according to their occurrence, and their total, as well as the number of patients, were recorded separately. The surgical approach and the type of surgery performed were also recorded.

### Statistical Analysis

We evaluated data normality through the Shapiro-Wilk test, and homogeneity through the Levene test. We present the continuous variables as means and standard deviation. The categorical variables were presented as absolute and percentage values.

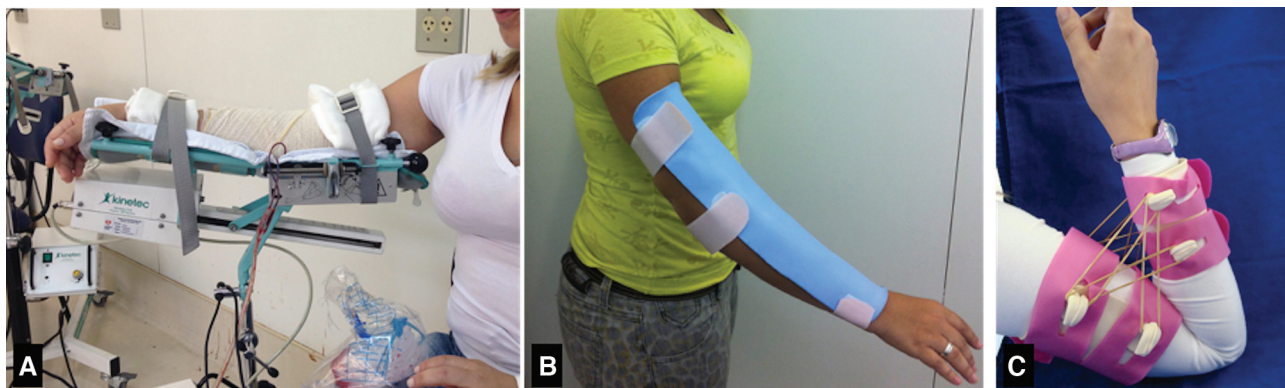
To analyze the evolution of the clinical outcomes over time, the Friedman test was performed. The categorical data analysis was performed with the Fischer exact test or the Chi-squared test.

Values of  $p < 0.05$  were considered statistically significant.

The Statistical Package for the Social Sciences (SPSS, IBM Corp., Armonk, NY, US) software, version 21.0, was used for the data analysis.

### Results

A total of 33 patients with post-traumatic elbow stiffness were operated. Of these, six were excluded due to loss of



**Fig. 2** Case illustrating the (A) continuous passive motion (CPM) device; (B) static orthosis for extension gain; and (C) dynamic orthosis for flexion gain.

**Table 1** Clinical characteristics of the patients undergoing surgical treatment for elbow release

Clinical characteristics	Cases
Gender, n (%)	
Male	17 (65.4)
Female	9 (34.6)
Age, years	
Mean (standard deviation)	37.3 (11.3)
Smoking, n (%)	
Yes	2 (7.7)
Former smoker	3 (11.5)
No	21 (80.8)
Diabetes, n (%)	
Yes	2 (7.7)
No	24 (92.3)
Problems at work, n (%)	
Yes	7 (26.9)
No	19 (73.1)
Affected side, n (%)	
Right	14 (53.8)
Left	12 (46.2)
Dominant side affected, n (%)	
Yes	14 (53.8)
No	12 (46.2)
Previous fracture, n (%)	
Yes	19 (73.1)
No	7 (26.9)
Previous surgery, n (%)	
Yes	8 (30.8)
No	18 (69.2)

Note: \*The continuous data are presented as mean and standard deviation, and the categorical data are presented as absolute numbers with percentages.

follow-up. In total, 26 patients were analyzed, with 6 months of follow-up. The general sample data can be seen on the ►Table 1. The radiographic data are shown in the ►Table 2.

The causes that led to post-traumatic elbow stiffness were: seven cases of distal humerus fracture; five patients with isolated radial head fracture; four cases of terrible triad injury; four due to coronoid fracture; two patients with isolated elbow dislocation; and four due to other causes (one case of cut-contusion injury, two due to prolonged immobilization contusion, and one elbow bruise associated with traumatic brain injury).

The average elbow flexion-extension ROM after 6 months of follow-up was of  $98.3^\circ \pm 22.0^\circ$ , with an elbow flexion-extension ROM gain of  $40.0^\circ \pm 14.0^\circ$  compared to the pre-operative period, with statistically significant difference

**Table 2** Radiographic characteristics of patients undergoing surgical treatment for elbow release

Radiographic characteristics	Cases
Presence of synthesis material, n (%)	
Yes	8 (30.8)
No	18 (69.2)
Radial head, n (%)	
Without deformity	16 (61.5)
With deformity	7 (26.9)
Absent	2 (7.7)
Prosthesis	1 (3.8)
Loose bodies, n (%)	
Yes	10 (38.5)
No	16 (61.5)
Osteophytes, n (%)	
Yes	13 (50.0)
No	13 (50.0)

Note: \*The categorical data presented as absolute numbers with percentages.

( $p < 0.001$ ). The mean gain in elbow flexion extension ROM at the end of 6 months of follow-up was of  $51.7^\circ \pm 17.1^\circ$ , with a statistically significant difference in the temporal analysis ( $p < 0.001$ ).

The mean elbow pronosupination ROM in the pre-operative period was of  $115.2^\circ \pm 52.3^\circ$ , and, after 6 months of follow-up, it was of  $129.0^\circ \pm 42.7^\circ$ , with a statistically significant difference in the temporal analysis ( $p < 0.001$ ).

Half of the cases presented moderate and severe pre-operative stiffness, compared to only 7.7% at 6 months post-operatively ( $p < 0.001$ ). The categorical results are presented in the ►Table 3. The mean values of the elbow ROM and the ROM gain are presented in ►Table 4 and in ►Figures 3 and 4.

All final ROM values (flexion, extension, pronation and supination) presented statistically significant improvement in the temporal analysis, and are shown in ►Table 5.

The mean score on the MEPS and DASH scales, at the end of 6 months of follow-up, was of  $74.4 \pm 16.8$  points and  $31.7 \pm 21.9$  points respectively. Both presented statistically significant differences in the temporal analysis ( $p < 0.001$  for both). The VAS scale did not present a statistically significant difference in the temporal analysis ( $p = 0.096$ ). The mean values are shown in ►Table 6 and in ►Figure 5.

obtained total of 15 patients had excellent or good results, and 11 had regular or poor results, according to the MEPS scale, with a statistically significant difference compared to the pre-operative period ( $p = 0.011$ ). The data are presented in the ►Table 3.

Resection of the radial head was performed in two cases due to deformities, and, in one patient, a radial head arthroplasty was removed. Two patients had undergone previous resection of the radial head, amounting to a total of five patients with post-operative absence of the radial head. These patients had

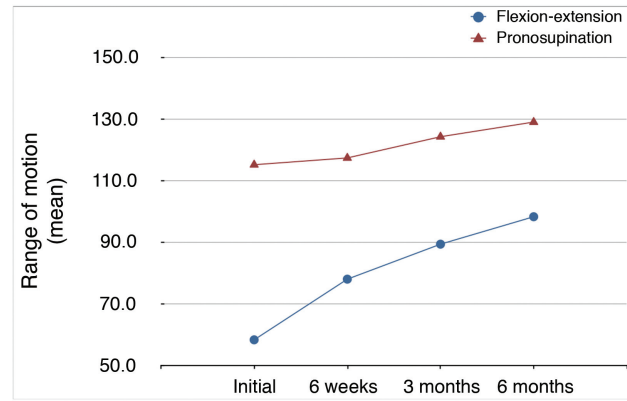
**Table 3** Radiographic characteristics of patients undergoing surgical treatment for elbow release

	Pre-operative	6 months	p-value
<b>Degree of stiffness</b>			
I	1 (3.8)	18 (69.2)	
II	12 (46.2)	6 (23.1)	
III	9 (34.6)	2 (7.7)	
IV	4 (15.4)	0 (0)	< 0.0001
<b>Degree of arthrosis</b>			
0	5 (19.2)	4 (16.0)	
1	8 (30.8)	8 (32.0)	
2	11 (42.3)	9 (36.0)	
3	2 (7.7)	4 (16.0)	0.811
<b>Categorical Mayo Elbow Performance Score (MEPS)</b>			
Excellent	0 (0)	4 (15.4)	
Good	5 (19.2)	11 (42.3)	
Regular	8 (30.8)	7 (26.9)	
Poor	13 (50.0)	4 (15.4)	0.011

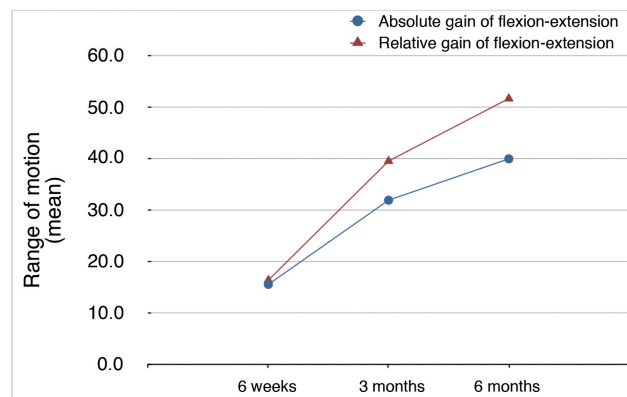
Note: \*The categorical data are presented as absolute numbers with percentages.

**Table 4** Results of flexion-extension range of motion (ROM), absolute and relative gain of flexion-extension ROM, and pronosupination ROM over follow-up

	Cases		p-value
	Mean	Standard deviation	
<i>Flexion-extension ROM (°)</i>			
Initial	58.4	22.7	
6 weeks	78.0	22.5	
3 months	89.4	26.0	
6 months	98.3	22.0	< 0.001
<i>ROM gain (°)</i>			
6 weeks	15.6	23.2	
3 months	31.9	20.9	
6 months	40.0	14.0	< 0.001
<i>ROM relative gain (%)</i>			
6 weeks	16.4	28.9	
3 months	39.5	24.0	
6 months	51.7	17.1	< 0.001
<i>Pronosupination ROM (°)</i>			
Initial	115.2	52.3	
6 weeks	117.4	42.7	
3 months	124.3	43.8	
6 months	129.0	42.7	< 0.001



**Fig. 3** Results of flexion-extension and pronosupination range of motion during follow-up.



**Fig. 4** Results of the absolute and relative range of motion gain for flexion-extension during follow-up.

an average of 66 points on the MEPS scale ( $\pm 18.8$  points), a score lower than that of the patients without radial head deformity ( $81 \pm 11.9$  points), but without statistically significant difference. There were no differences in the univariate subgroup analysis for the other clinical variables and the characteristics of the lesion. The presence of osteophytes (in the coronoid, trochlea or olecranon) also showed no statistically significant difference in the post-operative period, although the group without osteophytes had better scores in the MEPS scale and in the flexion-extension ROM ( $78.1 \pm 17.0$  versus  $70.8 \pm 16.3$ , and  $100.1 \pm 20.2$  versus  $95.7 \pm 24.3$  respectively).

The following complications were observed in 6 (23%) patients: transient ulnar nerve neuropraxia (4 cases); subluxation of the radio head (1 case); superficial infection (1 case); and OH (1 case). Heterotopic ossification occurred in the distal triceps tendon, and the patient presented a final flexion of  $90^\circ$  and extension of  $-15^\circ$ , and did not wish a new surgical procedure. The four cases of transient ulnar nerve neuropraxia showed complete improvement up to five months post-operatively, not needing a new approach. The patient with superficial infection showed improvement with oral antibiotic therapy.

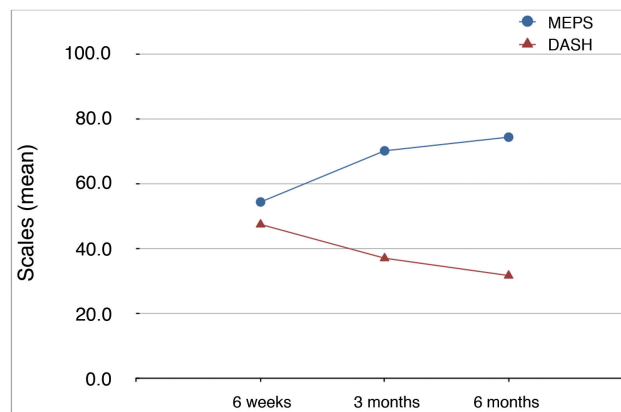
No patient developed severe soft-tissue injury or deep infection. No patient required a new surgical procedure due to complications.

**Table 5** Results of flexion, extension, pronation and supination means throughout the follow-up

	Cases		p-value
	Mean	Standard deviation	
<i>Flexion (°)</i>			
Initial	99.3	24.8	
6 weeks	101.7	20.3	
3 months	108.8	21.0	
6 months	116.0	17.6	< 0.001
<i>Extension (°)</i>			
Initial	-40.9	20.9	
6 weeks	-30.2	17.7	
3 months	-19.4	11.1	
6 months	-17.7	10.6	<0.001
<i>Pronation (°)</i>			
Initial	58.1	27.6	
6 weeks	55.4	24.7	
3 months	59.0	24.0	
6 months	62.5	24.1	0.017
<i>Supination (°)</i>			
Initial	57.5	29.4	
6 weeks	62.4	26.3	
3 months	66.1	26.6	
6 months	67.5	26.0	<0.001

**Table 6** Scores on the functional scales of patients undergoing surgical release during follow-up

	Cases		p-value
	Mean	Standard deviation	
<i>Mayo Elbow Performance Score (MEPS)</i>			
Initial	54.4	20.1	
3 months	70.2	20.1	
6 months	74.4	16.8	< 0.001
<i>Disabilities of the Arm, Shoulder and Hand (DASH)</i>			
Initial	47.5	19.2	
3 months	37.1	23.4	
6 months	31.7	21.9	< 0.001
<i>Visual Analogue Scale (VAS) for pain</i>			
Initial	5.1	3.1	
6 weeks	4.4	3.0	
3 months	4.0	2.9	
6 months	4.1	2.5	0.096

**Fig. 5** Results of the Mayo Elbow Performance Score (MEPS) and Disabilities of the Arm, Shoulder and Hand (DASH) functional scales during follow-up.

## Discussion

The present study aimed to evaluate the surgical release of the elbow followed by a standardized rehabilitation protocol for patients with post-traumatic elbow stiffness who had already been subjected to conventional physical therapy without success. The treatment of elbow stiffness is technically complex, with a moderate risk of complications. The indication of surgical treatment is still controversial, mainly due to the absence of comparative studies for post-traumatic elbow stiffness. In our recommendation criteria, we take into consideration the patient's desire and motivation to improve the range of motion, and a minimum limit of flexion-extension ROM of the elbow lower than 100°, or maximum extension lower than -30°, or maximal flexion less than 130°, more than 6 months after the initial trauma.

The technique studied presented good and excellent results in more than half of the operated patients, with a mean flexion-extension ROM of 98.3°, which is similar to the mean found in the systematic review by Kodde et al.<sup>6</sup>, which was of 103° for open releases.

Regarding the elbow flexion-extension ROM gain after 6 months of treatment, we observed a 40° gain, similar to those reported by Higgs et al.,<sup>14</sup> Koh et al.<sup>22</sup> and Miyazaki et al.<sup>23</sup> Ayadi et al.<sup>24</sup> observed a 51° gain in flexion-extension ROM in a series of patients undergoing open surgical release, but only 18% of the patients reached functional ROM, while in our study we observed that 42% of patients acquired functional ROM at 6 months of follow-up. Due to this finding, it is important to highlight that when comparing the ROM gain results between studies, it is inversely proportional to pre-operative ROM.<sup>22</sup> Thus, in studies in which the initial ROM is lower, the patients will have a tendency toward greater post-treatment ROM gain. This fact makes the comparison between the results of studies difficult to perform and interpret, and may lead to mistaken conclusions. Attempting to work around this issue, Cauchois and Deburge<sup>20</sup> created a formula taking into consideration the possible pre-treatment gain and the gain achieved after



treatment, with the results in percentages; they called this the relative gain of ROM. Our study achieved 51.7% relative ROM gain, which is close to the 57% observed by Boerboom et al.<sup>25</sup>

The rehabilitation protocol applied to the patients was based on service experience and available resources. Like Lindenhovius et al.,<sup>9</sup> the patients underwent active and passive light stretching exercises during occupational therapy sessions, and were instructed to perform them daily at home. Unlike Tan et al.,<sup>26</sup> forced manipulation was never performed, because it increases the risk of bruising, HO, worsening of pain and stiffness.<sup>11</sup>

The surgical technique was the same for all patients, and was performed by two surgeons. Like Koh et al.,<sup>22</sup> the route used was the posterior route, due to the versatility of access to all elbow compartments. No patient experienced instability at the end of surgery, or need to use the external fixator. Like Higgs et al.,<sup>14</sup> joint mobilization began on the first post-operative day with the use of CPM, but without the use of a catheter for continuous brachial plexus block. The patients tolerated the pain only with the use of analgesics and anti-inflammatory, managing to make the use of the CPM uneventful.

Although some surgeons avoid posterior surgical release, claiming a higher risk of wound complications such as dehiscence, in a systematic review of complications, Cai et al.<sup>27</sup> did not observe such a relationship. We observed only 1 (6.7%) case of complication of the wound, a superficial infection treated with oral antibiotic therapy for 7 days. Tan et al.,<sup>26</sup> performing medial and/or lateral approaches, reported 3 (5.8%) cases of wound complications, but with deep infection and need for surgical cleaning, debridement and intravenous antibiotic therapy.

Neurolysis and anterior transposition of the ulnar nerve were performed in all cases of the surgical group in order to avoid ulnar nerve injury or eventual compression syndrome in the post-operative period. Our study presented four cases of transient ulnar nerve neuropraxia with complete improvement of the symptoms. There is no consensus in the literature as to which ulnar nerve approach is best for post-traumatic elbow stiffness.

Our study has, as its main advantages, the description of a standardized technique and low-cost rehabilitation, using scales and clinical questionnaires in standardized times. We also evaluated elbow flexion-extension ROM in several ways, with ROM, ROM gain, relative ROM gain, maximum extension and flexion, which enables a better comparison with other studies.

Among the limitations of the present study, the 6-month follow-up period may be considered short; however, studies show no statistically significant differences in elbow ROM after that that period in the treatment of post-traumatic elbow stiffness.<sup>17,28,29</sup> Patient follow-up will continue until five years from the start of the treatment to further understand the relationship of post-treatment time with elbow ROM and functional scales. Another limitation is that the sample size was relatively small, which limited the analysis of secondary outcomes.

## Conclusion

Surgical elbow release associated with a rehabilitation protocol is a safe technique, with satisfactory results, an absolute gain of flexion-extension ROM of 40°, and a relative gain of ROM of 51.7%, with a low complication rate.

### Conflict of Interests

The authors have none to declare.

## References

- Morrey BF, An K-N. Functional Evaluation of the Elbow [Internet]. *Morrey's The Elbow and Its Disorders*, 2009:80–91. Available from: <http://dx.doi.org/10.1016/b978-1-4160-2902-1.50010-3>
- Morrey BF, Askew LJ, Chao EY. A biomechanical study of normal functional elbow motion. *J Bone Joint Surg Am* 1981;63(06):872–877
- Sardelli M, Tashjian RZ, MacWilliams BA. Functional elbow range of motion for contemporary tasks. *J Bone Joint Surg Am* 2011;93(05):471–477
- Cefo I, Eygendaal D. Arthroscopic arthrolysis for posttraumatic elbow stiffness. *J Shoulder Elbow Surg* 2011;20(03):434–439
- Gundlach U, Eygendaal D. Surgical treatment of posttraumatic stiffness of the elbow: 2-year outcome in 21 patients after a column procedure. *Acta Orthop* 2008;79(01):74–77
- Kodde IF, van Rijn J, van den Bekerom MPJ, Eygendaal D. Surgical treatment of post-traumatic elbow stiffness: a systematic review. *J Shoulder Elbow Surg* 2013;22(04):574–580
- Chen HW, Liu GD, Wu LJ. Complications of treating terrible triad injury of the elbow: a systematic review. *PLoS One* 2014;9(05):e97476
- Myden C, Hildebrand K. Elbow joint contracture after traumatic injury. *J Shoulder Elbow Surg* 2011;20(01):39–44
- Lindenhovius AL, Doornberg JN, Ring D, Jupiter JB. Health status after open elbow contracture release. *J Bone Joint Surg Am* 2010;92(12):2187–2195
- Urbaniak JR, Hansen PE, Beissinger SF, Aitken MS. Correction of post-traumatic flexion contracture of the elbow by anterior capsulotomy. *J Bone Joint Surg Am* 1985;67(08):1160–1164
- Itoh Y, Saegusa K, Ishiguro T, Horiuchi Y, Sasaki T, Uchinishi K. Operation for the stiff elbow. *Int Orthop* 1989;13(04):263–268
- Søjbjerg JO, Kjærsgaard-Andersen P, Johansen HV, Sneppen O. Release of the stiff elbow followed by continuous passive motion and indomethacin treatment. *J Shoulder Elbow Surg* 1995;4:520
- Müller AM, Sadoghi P, Lucas R, et al. Effectiveness of bracing in the treatment of nonosseous restriction of elbow mobility: a systematic review and meta-analysis of 13 studies. *J Shoulder Elbow Surg* 2013;22(08):1146–1152
- Higgs ZCJ, Danks BA, Sibinski M, Rymaszewski LA. Outcomes of open arthrolysis of the elbow without post-operative passive stretching. *J Bone Joint Surg Br* 2012;94(03):348–352
- Morrey BF. Distraction arthroplasty. Clinical applications. *Clin Orthop Relat Res* 1993;(293):46–54
- Júnior JC, Zabeu JLA, Junior IA, Mattos CA, Myrrha JP. Arthroscopic treatment of post-traumatic elbow stiffness. *Rev Bras Ortop* 2015;47(03):325–329
- Park MJ, Chang MJ, Lee YB, Kang HJ. Surgical release for posttraumatic loss of elbow flexion. *J Bone Joint Surg Am* 2010;92(16):2692–2699
- Morrey BF, Adams RA. Semiconstrained arthroplasty for the treatment of rheumatoid arthritis of the elbow. *J Bone Joint Surg Am* 1992;74(04):479–490
- Orfale AG, Araújo PM, Ferraz MB, Natour J. Translation into Brazilian Portuguese, cultural adaptation and evaluation of the reliability of the Disabilities of the Arm, Shoulder and Hand Questionnaire. *Braz J Med Biol Res* 2005;38(02):293–302
- Cauchoux J, Deburge A. [Elbow arthrolysis in post-traumatic rigidities]. *Acta Orthop Belg* 1975;41(04):385–392



- 21 Rettig LA, Hastings H II, Feinberg JR. Primary osteoarthritis of the elbow: lack of radiographic evidence for morphologic predisposition, results of operative debridement at intermediate follow-up, and basis for a new radiographic classification system. *J Shoulder Elbow Surg* 2008;17(01):97–105
- 22 Koh KH, Lim TK, Lee HI, Park MJ. Surgical release of elbow stiffness after internal fixation of intercondylar fracture of the distal humerus. *J Shoulder Elbow Surg* 2013;22(02):268–274
- 23 Miyazaki AN, Fregoneze M, Santos PD, et al. Avaliação dos resultados do tratamento cirúrgico da rigidez pós-traumática do cotovelo de pacientes esqueleticamente maduros. *Rev Bras Ortop* 2010;45(06):529–537
- 24 Ayadi D, Etienne P, Burny F, Schuind F. Results of open arthrolysis for elbow stiffness. A series of 22 cases. *Acta Orthop Belg* 2011;77(04):453–457
- 25 Boerboom AL, de Meyier HE, Verburg AD, Verhaar JA. Arthrolysis for post-traumatic stiffness of the elbow. *Int Orthop* 1993;17(06):346–349
- 26 Tan V, Daluiski A, Simic P, Hotchkiss RN. Outcome of open release for post-traumatic elbow stiffness. *J Trauma* 2006;61(03):673–678
- 27 Cai J, Wang W, Yan H, et al. Complications of Open Elbow Arthrolysis in Post-Traumatic Elbow Stiffness: A Systematic Review. *PLoS One* 2015;10(09):e0138547
- 28 Aldridge JM III, Atkins TA, Gunneson EE, Urbaniak JR. Anterior release of the elbow for extension loss. *J Bone Joint Surg Am* 2004;86(09):1955–1960
- 29 Stans AA, Maritz NG, O'Driscoll SW, Morrey BF. Operative treatment of elbow contracture in patients twenty-one years of age or younger. *J Bone Joint Surg Am* 2002;84(03):382–387