






Radiographic Evaluation of Patients Submitted to Percutaneous Fixation With Solid Screw for Distal Radius Fracture Treatment*

Avaliação radiográfica dos pacientes submetidos à fixação percutânea com parafuso maciço para tratamento de fraturas da extremidade distal do rádio

Gonzalo Guamán Gaibor¹  Leonardo Dalla Giacomassa Rocha Thomaz¹  Cristian Stein Borges¹ 
Paulo Henrique Ruschel¹  Milton Bernardes Pignataro¹ 

¹ Orthopedics and Traumatology Service, Santa Casa de Porto Alegre, Porto Alegre, RS, Brazil

Address for correspondence Leonardo Dalla Giacomassa Rocha Thomaz, MD, Santa Casa de Misericórdia de Porto Alegre, Av. Independência, 75, Independência, Porto Alegre, RS, 90035-072, Brazil (e-mail: leorochat@hotmail.com).

Rev Bras Ortop 2020;55(5):605–611.

Abstract

Objective The present paper aims to present results from radiographic evaluations of patients with extra-articular distal radius fractures submitted to percutaneous fixation with a 3.5 mm solid screw.

Methods Analytical, descriptive and retrospective case series of 16 patients with evaluation of the radiographic parameters.

Results The average age of the study population was 46.5 years old (25–60 years old); 81.25% of the sample was female. The average time until surgery was 8.8 days (4–14 days). The mean preprocedural volar tilt was -7.41° (-23.48° – -5.29° , standard deviation [SD] $\pm 6.59^\circ$). The mean volar tilt immediately after surgery was 5.93° (SD $\pm 6.23^\circ$, $p < 0.001$). There was no statistical difference in volar tilt values after 6 months of follow-up. The mean preprocedural radial height was 4.13 mm (-7.8 mm– 9.5 mm, SD ± 5.06 mm). There was a statistically significant increase at the immediate postoperative period to 10.04 mm ($p = 0.002$), and a significant reduction at 6 months to 9.55 mm ($p = 0.012$). The consolidation rate was 100% with the technique used, with a minimal complication rate. No patient had infection or required a reoperation.

Conclusion The technique was effective for the treatment of distal radial extra-articular fractures at 6 months, with a low complication rate; radiographic parameters values were acceptable and close to the anatomical ones.

Keywords

- ▶ radial fractures
- ▶ minimally invasive surgical procedures
- ▶ radiology

Resumo

Objetivo Apresentar o resultado das avaliações radiográficas dos pacientes com fraturas extra-articulares do rádio distal submetidos a fixação percutânea com parafuso maciço de 3.5mm.

* Study developed at the Orthopedics and Traumatology Service, Santa Casa de Porto Alegre, Porto Alegre, RS, Brazil.

Palavras-chave

- ▶ fraturas do rádio
- ▶ procedimentos cirúrgicos minimamente invasivos
- ▶ radiologia

Métodos Série de casos, analítica, descritiva e retrospectiva de 16 pacientes com avaliação dos parâmetros radiográficos da técnica utilizada.

Resultados A média de idade da população estudada foi de 46,5 anos (25–60 anos), sendo 81,25% do sexo feminino. O tempo de espera até a cirurgia foi de 8,8 dias (4–14 dias). O tilt volar médio pré-procedimento foi $-7,41^\circ$ ($-23,48^\circ$ – $-5,29^\circ$, desvio padrão [DP] $\pm 6,59^\circ$). O tilt volar imediatamente após o procedimento cirúrgico foi de $+5,93^\circ$ (DP $\pm 6,23^\circ$, $p < 0,001$). Sem diferença estatística nos valores de tilt volar ao final de 6 meses de evolução. A altura radial pré-procedimento foi de 4,13 mm ($-7,8^\circ$ – $9,5^\circ$, DP $\pm 5,06^\circ$). Aumento estatisticamente significativo no pós-operatório imediato para 10,04 mm ($p = 0,002$). Redução significativa ao final de 6 meses para 9,55 mm ($p = 0,012$). Atingimos 100% de consolidação com a técnica utilizada, com índice mínimo de complicações. Nenhum paciente apresentou infecção ou precisou ser reoperado.

Conclusão A técnica mostrou-se eficaz para o tratamento de fraturas extra-articulares da extremidade distal do rádio ao final de 6 meses, com baixo índice de complicações e parâmetros radiográficos aceitáveis e próximos dos valores anatômicos.

Introduction

Distal radius fractures are among the main extremity injuries, accounting for $\sim 17\%$ of total limb fractures.¹ It is estimated that 640,000 cases occur annually in the United States,² but there are no demographic studies in Brazil showing the real magnitude of these lesions. High-speed accidents and falls from height are among the most common causes of these fractures; their main mechanisms involve trauma to the hyper-extended or flexed wrist.^{3,4}

Treatment options for distal radius fracture include conservative therapy, which is indicated whenever possible to reduce it, keeping it stable with cast immobilization, or when the patient has no clinical conditions for surgical correction. Surgical treatment is indicated for unstable, intra-articular and comminuted fractures.^{1,4}

Despite the advancement and diversity of surgical options in recent years, distal radius fracture treatment remains a controversial subject.^{4,5} Closed reduction with percutaneous Kirschner wires fixation has been the most common treatment method for unstable extra-articular distal radius fractures.^{4,5} However, specific limitations and complications diminished its indication. Lack of stability, the need for restrictive immobilization, skin irritation, wire pathway infection, and even nerve damage are complications that may limit postoperative rehabilitation success. In addition, up to 44% of the cases evolve with late complications, such as material migration or fracture, and vicious fracture healing.^{1,6}

In the last 10 years, new technological therapeutic options have been gaining prominence. Among them, the surgical treatment with open reduction and volar locking plate fixation has become a popular method for most fracture patterns, as it can provide rigid stabilization, early movement and faster functional recovery. However, despite these advantages, this treatment is associated with significant soft tissue dissection, moderate complication rates and longer surgical time.^{7–14}

Nevertheless, there are different ways for distal radius fracture fixation, especially for extra-articular injuries, without the risks involved in open surgery. The replacement of Kirschner wires with cannulated and solid screws in percutaneous surgery has shown superior outcomes, less surgical aggression, shorter postoperative rigid immobilization time and fewer late complications; in addition, its results are similar to those obtained with volar block plates.^{2–15} Unlike other percutaneous techniques reported in the literature, we describe a fixation technique using a single 3.5 mm solid screw to treat extra-articular fractures of the distal radius.

Materials and Methods

The present study was approved by the Research Ethics Committee of the institution, under the number CAAE 00854018.3.0000.5335. Inclusion and exclusion criteria are presented in ▶ **Table 1**. All of the patients who underwent fixation of a distal radius extra-articular fracture with a solid, 3.5-mm screw from October 2016 to December 2018 were included. The total valid sample consisted of 16 patients. One patient was excluded for not completing the required minimum follow-up of 6 months. Radiographic evaluations were performed preoperatively, immediately postoperatively, and 6 months postoperatively. Radiographic data collected included volar tilt (in degrees) and radial height (in mm).

Statistical analysis was performed in PASW Statistics for Windows, Version 17 (SPSS Inc. Chicago, IL, EUA) software, and the Friedman test with Bonferroni correction was used for multiple comparisons. Findings were confirmed by a repeated measures analysis of variance (ANOVA) with Bonferroni post-hoc test.

Surgical technique

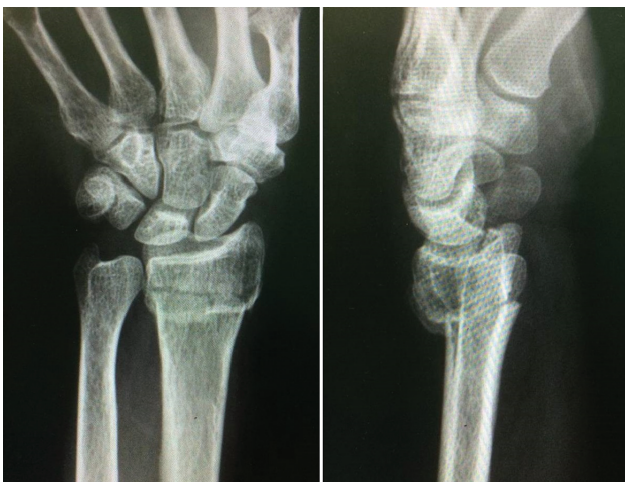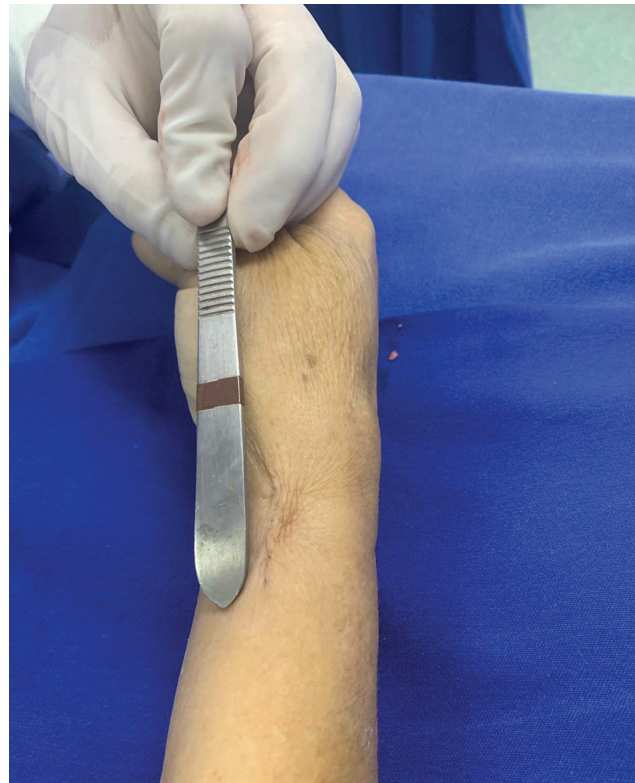All of the patients had extra-articular distal radius fractures (▶ **Figure 1**) and underwent the procedure in the operating

Table 1 Inclusion and exclusion criteria

Inclusion Criteria	Exclusion Criteria
Age ranging from 18 to 60 years old	Extra- and intra-articular complex fractures
Good bone quality	Lesions operated > 14 days after the initial trauma
Up to 14 days between trauma and surgery	Previous surgery for the same fracture
	Osteopenia or osteoporosis signs
	Patients > 60 years old
	Concurrent lesions at ipsilateral upper limb
	Open fractures
	Associated neurovascular lesions

room. Anesthesia consisted in sedation and peripheral block. After adequate antisepsis, sterile fields were positioned, and a pneumatic tourniquet was activated at the root of the operated limb. After gross reduction of the fracture and acceptable alignment under radioscopy control, a single 1 to 2 cm incision was made in the distal portion of the radial styloid process (→ **Figure 2**), between the first and second extensor compartments. Tissue dissection was performed until visualization of the bony screw insertion point. Radial and ulnar cortical perforation were performed, respectively, with a 3.5 mm and a 2.5 mm drill, using soft tissue protector and great care not to damage regional neurovascular structures. The drilled path was confirmed by fluoroscopy.

After proper measurement and preparation, a 3.5 mm solid screw was inserted into the radial medial cortex. Screw positioning and fracture stability were fluoroscopically checked (→ **Figure 3**). Plane closure and sterile dressing placement were performed. Patients were kept with a short arm cast for 14 days.

**Fig. 1** Anteroposterior (AP) and lateral (L) radiographs from an extra-articular fracture of the distal radius.**Fig. 2** Incision for percutaneous approach to the fracture.

Postoperative and follow-up

After 14 days of immobilization, the surgical sutures were removed, and the patients were allowed to initiate motor physical therapy for range of motion gain, analgesia and local edema control. Radiographic control was performed on outpatient return visits (→ **Figure 4**).

Results

Demographic data are shown in → **Table 2**. The initial study group included 16 patients (81.25% women), with an average age of 46.5 years old (25–60 years old). The average time from

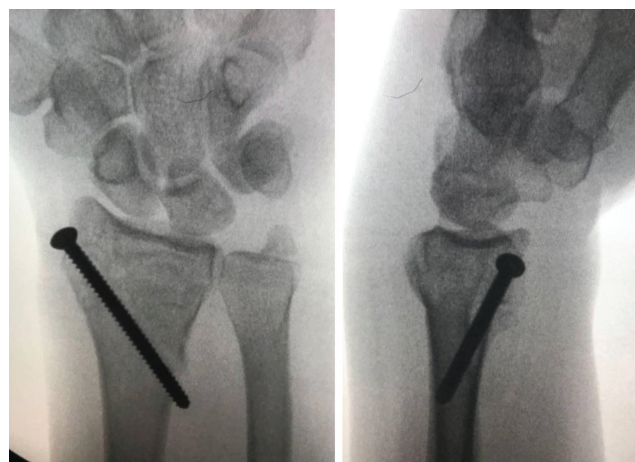
**Fig. 3** Fluoroscopic control of fracture reduction and alignment after solid screw fixation.

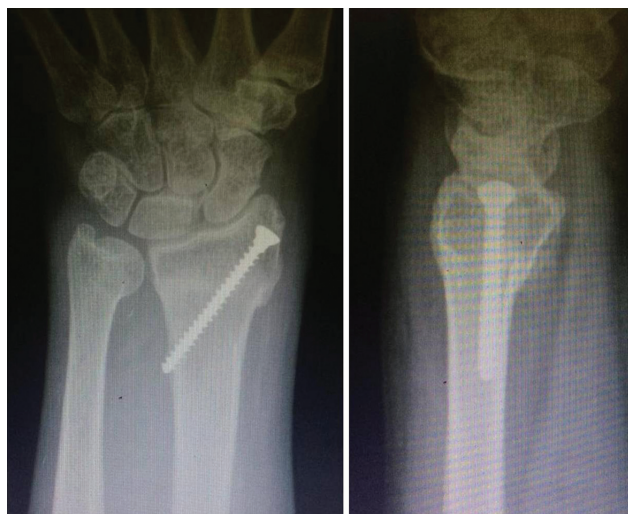

Fig. 4 Anteroposterior (AP) and lateral (L) radiographs for postoperative outpatient control of an apparently consolidated fracture treated according to the presented technique.

trauma to surgery was 8.8 days (4–14 days). The main mechanism of trauma was fall from own height (75% cases; $n = 13$), followed by trauma from heights ≥ 1 meter ($n = 2$) and during sports activity ($n = 1$).

Radiographic parameters and volar tilt analyses are shown in ►Table 3. The mean preprocedural volar tilt was -7.41° (-23.48° – 5.29° , standard deviation [SD], 6.59°). The mean value immediately after fracture reduction and fixation was 5.93° (SD 6.23° , $p < 0.001$). At 6 months, the mean final value decreased to 5.68° , but this reduction had no statistical significance ($p = 0.095$).

Radiographic parameters and radial height analyses are shown in ►Table 4. The mean preprocedural radial height was 4.13 mm (-7.8 mm– 9.5 mm, SD 5.06 mm). The mean immediate postoperative radial height was 10.04 mm, representing a statistically significant increase ($p = 0.002$). At 6 months, the mean value decreased to 9.55 mm, with a statistically significant reduction between the 2 time points ($p = 0.012$).

Three months after the surgery, the fracture consolidation rate was 100% (►Figures 5, 6 and 7), and all of the patients presented satisfactory range of motion (►Figure 8). One patient still presented chronic postoperative pain, most likely caused by ulnar styloid process pseudarthrosis. There

Table 2 Demographic Data

Sample (n)	16 patients
Age	46.5 years old (25-60)
Gender	Female, $n = 13$ // Male, $n = 3$
Time until procedure (days)	8.8 (4-14)
Trauma Mechanism	Fall from own height ($n = 13$), fall from 1 meter or more height ($n = 2$), playing sports ($n = 1$)

Table 3 Volar tilts (in degrees) comparisons at the three time points

	Preoperative Volar Tilt	Immediate Postoperative Volar Tilt	<i>p</i> -value
Mean value	-7.41 (-23.48 – 5.29)	$+5.94$ (-11.46 – 12.00)	< 0.001
Standard Deviation	± 6.59	± 6.24	–
	Preoperative Volar Tilt	Volar Tilt in 6 months	<i>p</i>
Mean value	-7.41 (-23.48 – 5.29)	$+5.68$ (-11.40 – 12.00)	< 0.001
Standard Deviation	$+6.59$	± 6.27	–
	Immediate Postoperative Volar Tilt	Volar Tilt in 6 months	<i>p</i>
Mean value	$+5.94$ (-11.46 – 12.00)	$+5.68$ (-11.40 – 12.00)	0.095
Standard Deviation	± 6.24	± 6.27	

were no infectious conditions and no patient needed to be reoperated.

At 6 months, the radiographic parameters were close to anatomical values. One patient had an unsatisfactory radiographic result, with -11.4° volar tilt. We believe this result was due to a technical failure during fracture reduction.

Table 4 Radial height (in mm) comparisons at the three time points

	Preoperative Radial Height	Immediate Postoperative Radial Height	<i>p</i>
Mean value	4.13 (-7.8 – 9.5)	10.04 (6.6 – 11.30)	0.002
Standard Deviation	± 5.06	± 1.26	–
	Preoperative Radial Height	Radial Height in 6 months	<i>p</i>
Mean value	4.13 (-7.8 – 9.5)	9.55 (5.70 – 11.00)	0.007
Standard Deviation	± 5.06	± 1.51	–
	Immediate Postoperative Radial Height	Radial Height in 6 months	<i>p</i>
Mean value	10.04 (6.6 – 11.30)	9.55 (5.70 – 11.00)	0.012
Standard Deviation	± 1.26	± 1.51	

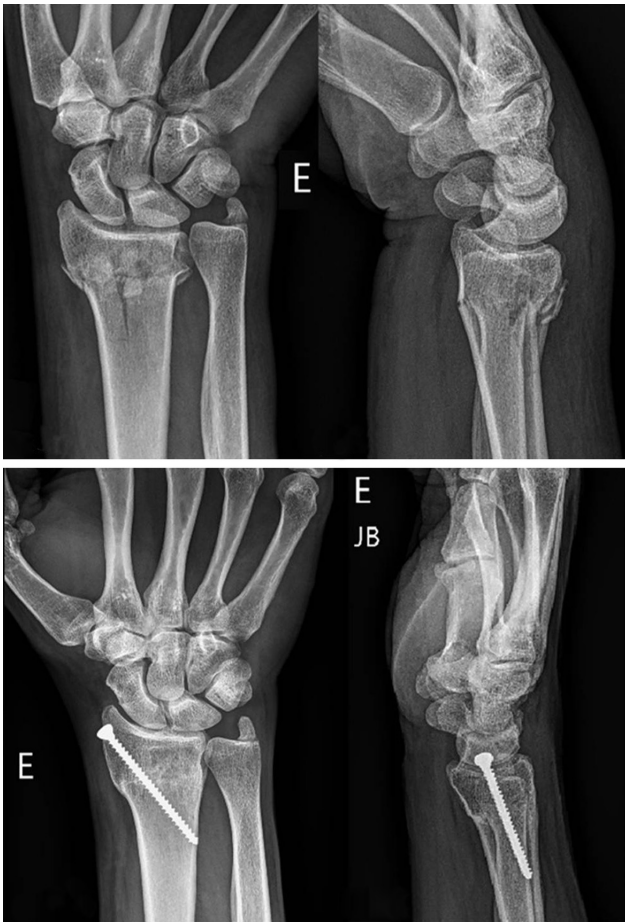

Fig. 5 Pre- and postoperative radiographs of fractures treated according to the presented technique.

Discussion

Interest in minimally invasive osteosynthesis has been growing worldwide.¹⁶ The development of imaging and fixation devices enabled the treatment of different types of fractures with minor dissection and less surgical aggression. Minimally invasive surgery is usually associated with smaller incisions, minimal blood loss, shorter hospital stays and faster return to daily activities.¹⁷

Although historically percutaneous fixation with Kirschner wires has been widely used to treat extra-articular distal radius fractures, the trend to use volar locking plates is increasing. The lack of stability of the wire fixation, in addition to potential vicious consolidation and pin path infection, are some of the main reasons for this decrease in popularity.

A study from Gereli et al.¹⁵ compared results from percutaneous fixation with two cannulated screws and fixation with a volar locking plate. The average surgical time was 53 minutes (40–80 minutes) in the cannulated screws group and 77.7 minutes (60–90 minutes) in the volar locking plate group, with $p = 0.001$. At the 2-month follow-up, patients from the percutaneous fixation group had greater range of motion in pronation (66° versus 58° , $p = 0.005$) and supination (59° versus 51° , $p = 0.025$), but both groups had equal range of motion at the end of the study. The study also

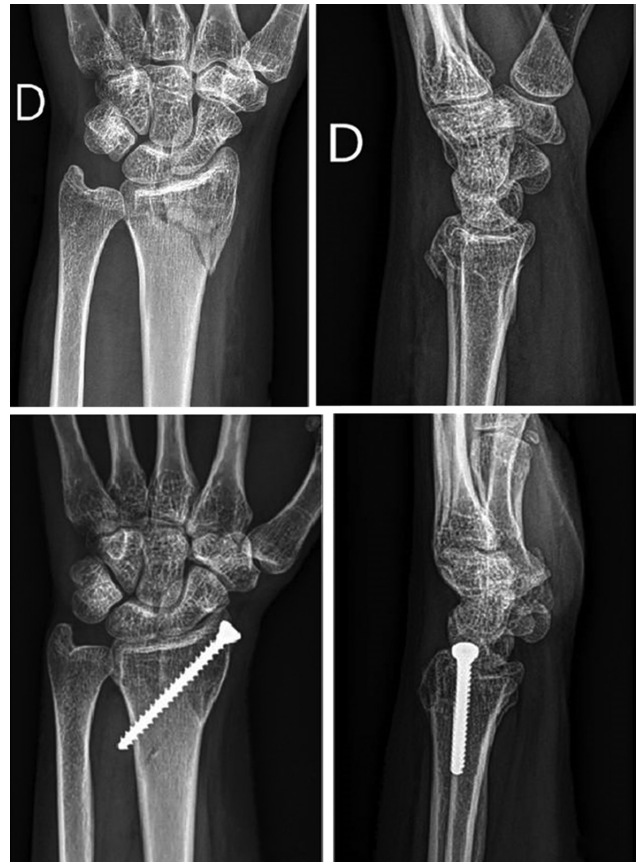

Fig. 6 Pre- and postoperative radiographs of fractures treated according to the presented technique.

suggested that there is no significant difference between groups regarding early return to daily activities.

A recent meta-analysis¹⁷ comparing open reduction and internal fixation (ORIF) to external fixation treatment showed significantly higher results in the Disabilities of the Arm, Shoulder and Hand (DASH) questionnaire favoring the ORIF group, which used volar locking plates. The questionnaire assesses the ability of the patient to perform their daily activities using the upper limb and sets up an important validated method for postoperative functional assessment. In addition, the study concludes that the ORIF group had better volar tilt restoration and forearm supination, but lower grip strength when compared with the external fixation group.

Jupiter et al.¹⁹ and Zhang et al.²⁰ state that early mobility allowed by volar locking plates would be a critical factor for significant clinical improvement. However, Handoll et al.,²¹ in a systematic Cochrane review, concluded that evidence from randomized trials on rehabilitation of adult distal radius fractures is insufficient to establish the effectiveness between immobilization time and different postoperative interventions. Handoll et al.²¹ also suggest that large centers should identify priority issues for patient rehabilitation to improve scientific evidence quality.

Stinton et al.²² performed a state-of-the-art longitudinal meta-analysis to assess recovery during the first 2 postoperative years following a distal radius fracture treated with a volar locking plate. These authors concluded that significant

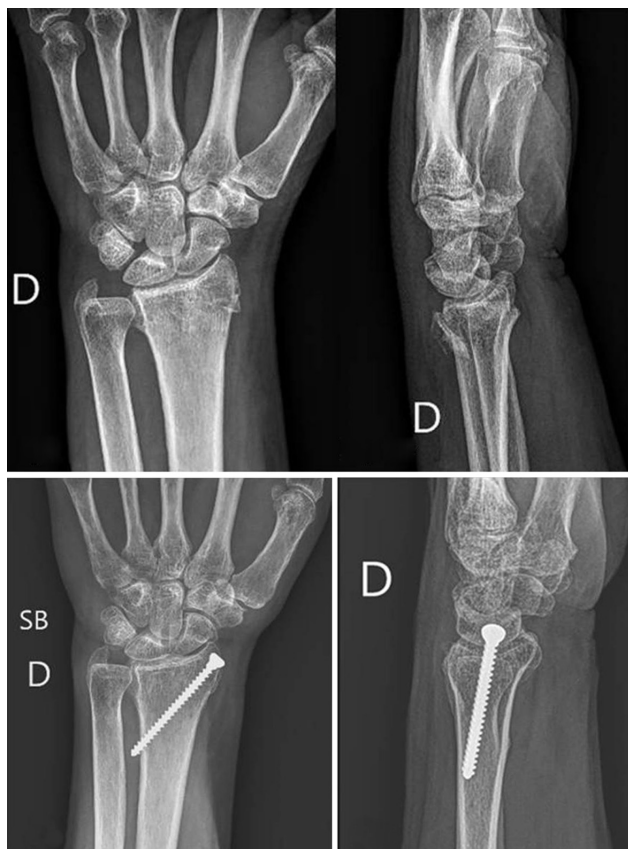

Fig. 7 Pre- and postoperative radiographs of fractures treated according to the presented technique.

clinical improvement can be achieved within 12 months; next, there is a “stable plateau”, with levels normalization.

In Brazil, Pardini Júnior et al.²³ evaluated radiographical results from 34 patients undergoing percutaneous treatment for distal radius fractures with Kirschner wires. Even though the mean fracture volar tilt worsened (from -2.03° in the immediate postoperative period to -3.82° at the end of the study), no statistical significance was found ($p = 0.511$).

Piva Neto et al.²⁴ also analyzed percutaneous treatment radiographical results at 6 weeks. This study did not compare

radiographic parameters from the immediate postoperative period and the end of evaluation period, precluding the assessment of a potential fracture reduction loss during the consolidation process.

Comparing the present study with the aforementioned Brazilian researches, we obtained superior results regarding average volar tilt restoration (5.68° versus -3.82° and 3.3°) and similar height restoration (9.55 mm versus 9.47 mm) as Piva Neto et al.²⁴ In addition, our technique was associated with a lower number of complications and no infection.

The technique presented in the present article can be used as a low-cost option for extra-articular distal radius fracture treatment. Countries with lower monetary power need alternatives to circumvent the low availability of volar locking plates.

Percutaneous fracture treatment with a solid, 3.5-mm screw allowed stable fixation and early onset of motor physical therapy, maintaining radiographic parameters similar to anatomical values at the end of a 6-month period. In addition, the minimal incision for osteosynthesis and minimal soft tissue dissection also resulted in minimal pain at the immediate postoperative period. There were no cases of infection throughout the follow-up period.

The present study has some limitations. The specific type of fracture, the type of fixation used, and the various inclusion and exclusion criteria significantly restrict the study sample number and power. In addition, we believe the average time from trauma to surgery was high (average of 8.8 days). As this is a study conducted in the public health system, its bureaucracy and hierarchy usually lead to a longer waiting time, a factor that may be directly related to inferior results. Another limitation was the impossibility to standardize postoperative motor physical therapy protocols.

Conclusion

Percutaneous fixation with a 3.5 mm cortical screw is a useful and inexpensive option for the treatment of extra-articular distal radial fractures. The technique was very effective, with acceptable maintenance of radiographic

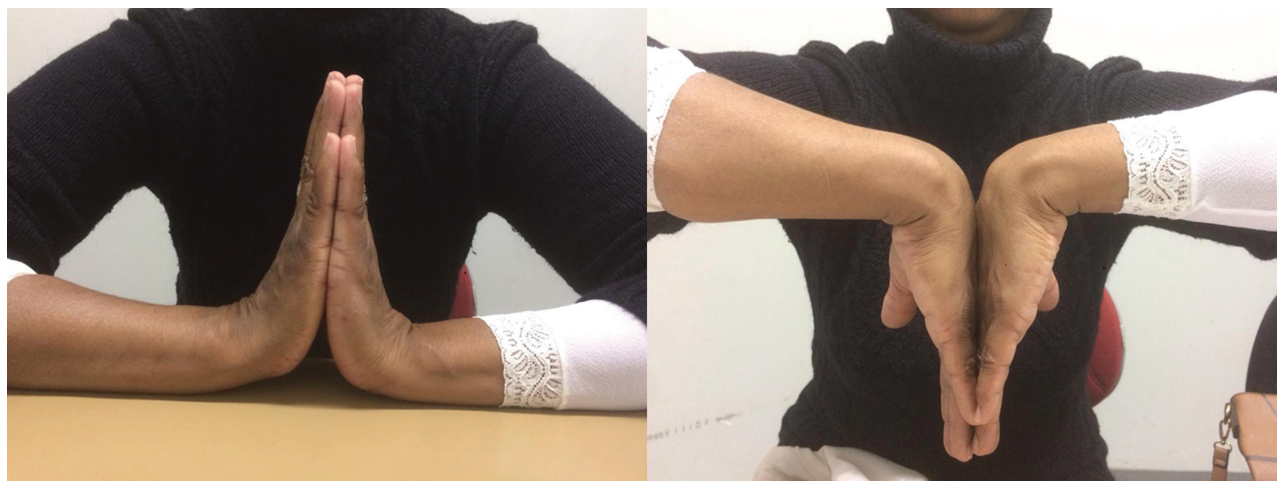

Fig. 8 Range of motion six months after surgery.

parameters, allowing early wrist mobilization, and a low complication rate.

Conflict of Interests

The authors declare that there are no conflict of interests.

References

- Jakubietz MG, Gruenert JG, Jakubietz RG. Palmar and dorsal fixed-angle plates in AO C-type fractures of the distal radius: is there an advantage of palmar plates in the long term? *J Orthop Surg Res* 2012;7(01):8
- Taras JS, Saillant JC, Goljan P, McCabe LA. Distal Radius Fracture Fixation With the Specialized Threaded Pin Device. *Orthopedics* 2016;39(01):e98–e103
- Clé P, Tasso L, Barbosa R, et al. Estudo retrospectivo do estado funcional de pacientes com fratura do rádio distal submetidos à osteossíntese com placa LCP. *Acta Fisiátrica* 2011;18(04):163–168
- Fernandez DL, Wolfe SW. Distal radius fractures. In: Green DP, Hotchkiss RN, Pederson WC, Scott WW, editors. *Green's operative hand surgery*. Philadelphia: Churchill Livingstone; 2005:656
- Tang JB. Distal radius fracture: diagnosis, treatment, and controversies. *Clin Plast Surg* 2014;41(03):481–499
- Taras JS, Ladd AL, Kalainov DM, Ruch DS, Ring DC. New concepts in the treatment of distal radius fractures. *Instr Course Lect* 2010;59:313–332
- Hsu LP, Schwartz EG, Kalainov DM, Chen F, Makowiec RL. Complications of K-wire fixation in procedures involving the hand and wrist. *J Hand Surg Am* 2011;36(04):610–616
- Rozental TD, Blazar PE. Functional outcome and complications after volar plating for dorsally displaced, unstable fractures of the distal radius. *J Hand Surg Am* 2006;31(03):359–365
- Orbay JL, Fernandez DL. Volar fixation for dorsally displaced fractures of the distal radius: a preliminary report. *J Hand Surg Am* 2002;27(02):205–215
- Lichtman DM, Bindra RR, Boyer MI, et al. Treatment of distal radius fractures. *J Am Acad Orthop Surg* 2010;18(03):180–189
- Arora R, Lutz M, Hennerbichler A, Krappinger D, Espen D, Gabl M. Complications following internal fixation of unstable distal radius fracture with a palmar locking-plate. *J Orthop Trauma* 2007;21(05):316–322
- Shyamalan G, Theokli C, Pearse Y, Tennent D. Volar locking plates versus Kirschner wires for distal radial fractures—a cost analysis study. *Injury* 2009;40(12):1279–1281
- Koval KJ, Harrast JJ, Anglen JO, Weinstein JN. Fractures of the distal part of the radius. The evolution of practice over time. Where's the evidence? *J Bone Joint Surg Am* 2008;90(09):1855–1861
- Prommersberger KJ, Pillukat T, Mühldorfer M, van Schoonhoven J. Malunion of the distal radius. *Arch Orthop Trauma Surg* 2012;132(05):693–702
- Gereli A, Nalbantoglu U, Kocaoglu B, Turkmen M. Comparative study of the closed reduction percutaneous cannulated screw fixation and open reduction palmar locking plate fixation in the treatment of AO type A2 distal radius fractures. *Arch Orthop Trauma Surg* 2014;134(01):121–129
- Nalbantoglu U, Gereli A, Kocaoglu B, Turkmen M. Percutaneous cannulated screw fixation in the treatment of distal radius fractures. *Arch Orthop Trauma Surg* 2012;132(09):1335–1341
- Yeung SH. Minimally invasive surgery in orthopaedics. Small is beautiful? *Hong Kong Med J* 2008;14(04):303–307
- Wei DH, Poolman RW, Bhandari M, Wolfe VM, Rosenwasser MP. External fixation versus internal fixation for unstable distal radius fractures: a systematic review and meta-analysis of comparative clinical trials. *J Orthop Trauma* 2012;26(07):386–394
- Jupiter JB, Marent-Huber M; LCP Study Group. Operative management of distal radial fractures with 2.4-millimeter locking plates. A multicenter prospective case series. *J Bone Joint Surg Am* 2009;91(01):55–65
- Zhang Q, Liu F, Xiao Z, et al. Internal Versus External Fixation for the Treatment of Distal Radial Fractures: A Systematic Review of Overlapping Meta-Analyses. *Medicine (Baltimore)* 2016;95(09):e2945
- Handoll HH, Elliott J. Rehabilitation for distal radial fractures in adults. *Cochrane Database Syst Rev* 2015;(09):CD003324
- Stinton SB, Graham PL, Moloney NA, Maclachlan LR, Edgar DW, Pappas E. Longitudinal recovery following distal radial fractures managed with volar plate fixation. *Bone Joint J* 2017;99-B(12):1665–1676
- Pardini AG Junior, Bufaical HGF, Freitas AD, Chaves AB. Resultados funcionais e radiológicos a longo prazo da fixação percutânea das fraturas da extremidade distal do rádio. *Rev Bras Ortop* 2012;47(01):31–36
- Piva Neto A, Lhamby FC. Fixação das fraturas da extremidade distal do rádio pela técnica de kapandji modificada: avaliação dos resultados radiológicos. *Rev Bras Ortop* 2011;46(04):368–373