






Achilles Tendon Lesions – Part 1: Tendinopathies

Lesões do Aquiles – Parte 1: Tendinopatias

Nacime Salomão Barbachan Mansur¹  Lucas Furtado Fonseca¹  Fábio Teruo Matsunaga¹ 
Daniel Soares Baumfeld²  Caio Augusto de Souza Nery¹  Marcel Jun Sugawara Tamaoki¹ 

¹ Department of Orthopedics and Traumatology, Escola Paulista de Medicina, Universidade Federal de São Paulo, São Paulo, SP, Brazil
² Department of Orthopedics and Traumatology, Universidade Federal de Minas Gerais, Belo Horizonte, MG, Brazil

Address for correspondence Nacime Salomão Barbachan Mansur, PhD, Departamento de Ortopedia e Traumatologia, Escola Paulista de Medicina, Universidade Federal de São Paulo, Rua Napoleão de Barros, 715, 1° andar, Vila Clementino, São Paulo, SP, Brazil (e-mail: nacime@uol.com.br).

Rev Bras Ortop 2020;55(6):657–664.

Abstract

Calcaneal tendon injuries are extremely common in the general population and in orthopedics routine care. Its increasing incidence, which is motivated by an aging population, improved access to the health care system, increased prescription of continuous-use medication, erratic participation in sports and other factors, has had a direct impact on society. Consolidated treatment options for tendinopathies lack quality scientific support for many modalities. New therapies have emerged to enhance nonsurgical approach outcomes and to reduce the number of patients requiring surgery. Although these operative procedures provide good pain relief and functional outcomes, they are costly and may lead to complications.

Keywords

- ▶ tendinopathy
- ▶ calcaneus tendon/surgery
- ▶ insertional
- ▶ non-insertional

Resumo

As afecções que acometem o tendão calcâneo são extremamente comuns na população geral e no cotidiano da atenção ortopédica. Sua crescente incidência, motivada pelo envelhecimento da população, pela melhora no acesso à saúde, pelo aumento na utilização de drogas de uso contínuo, pela errática participação esportiva e outros fatores, tem causado impacto direto na sociedade. As tendinopatias, ainda que hoje respaldadas por tratamentos consolidados, carecem de suporte científico de qualidade para muitas das suas recomendações. Novas terapêuticas têm surgido com o objetivo de potencializar o resultado da abordagem não-operatória e diminuir a quantidade de pacientes que necessitam de uma cirurgia. Esses procedimentos operatórios apresentam uma boa resposta algica e funcional dos pacientes, no entanto não são livres de complicações e dos altos custos que os cercam.

Palavras-chave

- ▶ tendinopatia
- ▶ tendão do calcâneo/cirurgia
- ▶ insercional
- ▶ não insercional

Introduction

Achilles Tendinopathies

The calcaneal tendon is the strongest and thickest tendon in the human body.^{1,2} It originates from the confluence of the soleus and gastrocnemius muscles (which has two bellies); the whole unit is referred to as triceps surae.³ These bellies form the tendon about six centimeters (proximal) from its attachment into the calcaneal bone posterior tuberosity. In its path,

this structure rotates about 180 degrees, and the soleus fibers form the medial portion and the lateral gastrocnemius fibers form the distal portion of the tendon. This rotation provides greater tendinous strength and resistance by decreasing the friction between the fibers and their distortions. However, it may compromise local vascularization.⁴

The area two to six centimeters proximal to the insertion is designated the non-insertional region. It has low vascularization due to its distance from the myotendinous and bony

received
September 10, 2019
accepted
November 29, 2019

DOI <https://doi.org/10.1055/s-0040-1702953>.
ISSN 0102-3616.

Copyright © 2020 by Sociedade Brasileira de Ortopedia e Traumatologia. Published by Thieme Revinter Publicações Ltda, Rio de Janeiro, Brazil

License terms



portions, which account for additional nutritional support. These anatomical features predispose this region to degenerative diseases and ruptures. Distally, the tendon has a particular anatomy, which also favors tendinopathies. The insertional region refers to the two distal centimeters of the tendon until its attachment in the *os calcis*. In this location, the Achilles tendon has an adjoining anterior (retrocalcaneal) bursa and an also adjoining posterior (pre-Achillean or subcutaneous) bursa. Its insertion into the tuberosity is specialized, spread out as a fan, with fibers extending to the lateral, medial, and distal planes.¹

This enthesis is extremely particular, and some authors consider it a particular organ. It is formed by the osteotendinous junction, covered by a sesamoid fibrocartilage adjacent to the tendon, the dorsal periosteum of the tuberosity, and the apex of the Kager fat pad. The bursas are distal in this topography.^{2,5} The calcaneal tendon microanatomy respects the organization of other human tendons. Up to 95% of its cellular component is formed by tenocytes and tenoblasts. These cells have different sizes and shapes and dispose themselves in long, parallel chains. Ninety percent of the extracellular element is composed of collagen tissue, predominantly type I (95%), organized in parallel bands bound by small proteoglycan molecules. About 2% of this element is formed by elastin, which accounts for the tendon deformation capacity of up to 200% before failure. Aging and the inability to provide optimal tissue healing modify this configuration, promoting the accumulation of mucin, fibrin, and types III and VII collagen.^{2,6}

Calcaneal tendinopathy is classified according to its anatomical site as insertional and non-insertional. Achilles insertional tendinopathy (AIT) occurs when the disease occurs from the insertion up to two centimeters proximally. It is usually associated with traction enthesophytes (upper spurs), Haglund deformity (pump bump) and pre- and retro-Achillean bursopathies. The differentiation between the two injury sites is not merely topographic, and this is consensual in the literature. The epidemiology of the two conditions is different, and there are disparate etiological theories, although with some similarities. Although they can coexist both asymptotically and symptomatically (mixed calcaneal tendinopathy), they are considered distinct disorders regarding clinical presentation and treatment.^{7,8}

Pathophysiology

Calcaneal tendinopathy is characterized by intratendinous degenerations secondary to low-grade inflammatory responses and poor biological healing. There are multiple hypotheses for the etiology of this disease, including overuse, muscle imbalance, misalignment and aging-related blood supply and tensile strength decrease. Currently, the etiology is believed to be multifactorial, with mechanical, vascular, neural, and genetic factors playing different roles in the disease process. Systemic diseases and some medications also influence the development of this condition.⁹

Overload is the extrinsic factor most traditionally associated with tendinopathies, particularly in the Achilles tendinopathy. Activity-induced microlesions that exceed the tissue regener-

ative capacity explain the bimodal incidence of these diseases. Young patients practicing high-demand physical activities and middle-aged people with compromised healing potential are the populations most affected by this condition.^{4,9-11}

Pes cavus, flatfoot, ankle instability, gender, and overweight are also related to intratendinous degeneration. Some authors consider them risk factors for the disease, despite the mechanical overload inherent to them. In the non-insertional form of the disease, the presence of a plantaris tendon in close contact with the Achilles tendon, with a different kinematics, was indicated as a disease inducer. Genetic inheritance, in addition to the clear relationship with some collagen metabolism diseases, plays a relevant part in tendinopathy as the condition is identified in relatives and in studied populations with combined polymorphisms and genotypes.^{12,13}

In the last decades, comorbidities, including rheumatoid arthritis, reactive arthritis, spondyloarthropathies, lupus, deposition disorders (gout and pseudogout), diabetes mellitus, amyloidosis, hypercholesterolemia, nephropathies, Marfan syndrome, Ehlers-Danlos disease, hemochromatosis and osteogenesis imperfecta, have been related to tendinopathies. Quinolone, statins, steroids (including anabolic steroids) and non-hormonal antiinflammatory drugs have also been reported as tendinopathy promoters due to the inhibition of natural collagen synthesis. However, a recent systematic review pointed only to alcohol abuse and the use of ciprofloxacin as systemic risk factors with strong evidence for the development of Achilles tendinopathies.^{14,15}

Non-insertional Achilles Tendinopathy

Epidemiology

Achilles non insertional tendinopathy (ANIT) have an incidence of about 1.85 per 1,000 inhabitants, accounting for 6 to 17% of injuries in runners.^{4,16} The prevalence of this condition is estimated at 0.2% in sedentary individuals and 9% in athletes, with an increasing aspect in recent decades. The treatment costs average around € 2,500 per patient for conservative treatment, with a 6-fold increase when surgical resolution is considered.^{17,18}

Clinical Presentation

Patients commonly seek care complaining of tendon-related body pain (2–6 cm proximal to the insertion) after activities; over time, pain may occur during sports or work. Regional stiffness is not uncommon, and it may even precede pain onset. Swelling is mainly noted in individuals with more chronic conditions.^{4,19}

Physical examination must include alignment assessment for deformities (pes cavus, flat foot, congenital diseases). The diagnosis is clinical and established by a painful tendon body palpation; tendon may also be hypertrophic. Medial tendon pain is highly suggestive of a plantaris tendon presence. Some patients also demonstrate pain on Kager fat pad palpation. Tests such as the Painful Arch Test (moving edema on ankle mobilization) and the Royal London Hospital test (painful edema at dorsiflexion) are described, but they are not required for diagnosis or therapeutic planning.¹⁹

Subsidiary Exams

Ancillary tests are not required for diagnosis but may be useful for therapeutic planning and prognosis. Plain radiographs may show intratendinous calcifications suggestive of long-standing disease. Intrastubstantial signs alterations at the ultrasound confirm the disease. Elastography has shown promising results in the potential identification of disease-susceptible populations and negative outcomes.^{4,20}

Nuclear magnetic resonance (MRi) completely characterizes tendinopathy and the presence or absence of a plantaris tendon. Lower limb MRi has been studied in patients with this disease. Changes in the bipennation angle of the triceps surae muscle and fatty infiltration occur in patients with chronic Achilles conditions. Since these changes are irreversible, advanced conditions result in functional muscular unit disability. Muscles with grade 0 and grade 1 fatty infiltration per the Goutallier classification can receive salvage procedures. Grade 2, 3 or 4 degenerations reflect muscles with high biological and mechanical impairment, and any attempt to reconstruct its tendon will be innocuous.^{21,22}

Nonsurgical Treatment

Conservative treatment for non-insertional Achilles tendinopathies had disappointing results until the end of the last century. The unsatisfactory results (29–52%) of numerous strategies endured for decades until Alfredson et al.²³ established a protocol for calcaneal tendon eccentric exercises (EE) for the non-insertional disease. This protocol consists of sets of exercises with 180 repetitions per day, performed on the edge of a step, every day of the week for 3 months (► **Figure 1**). These authors obtained up to 82% of good outcomes. Therefore, corroborated by clinical and imaging studies, they were able to demonstrate a direct effect on tendon neovascularization and its macroscopic structure. In the beginning of the 21st century, the Alfredson protocol of eccentric strengthening was considered the gold standard for non-insertional Achilles tendinopathy treatment. This protocol still holds an a grade of recommendation “A” (good evidence based on level I studies with consistent results) for initial treatment of the condition.^{24,25}

Some articles compared the original protocol with modifications (once a day, three times a week), with concentric strengthening and with resistance training. The results, although similar, were supported by very few moderate-quality studies.^{24,26}

The correction of associated etiologic factors, such as sporting gesture, overload, and tendon-toxic drug use, must be implemented, if possible. Infiltrations with platelet-rich plasma (PRP), autologous blood or sclerosing agents are not supported by the current literature, according to moderate-quality studies.^{27,28} Steroid use remains contraindicated due to the risk of Achilles tendon rupture.²⁹

Shockwave therapy (SWT) holds a a grade of recommendation “B” (reasonable evidence based on level II and III studies) for non-insertional Achilles tendinopathy. Recent systematic reviews have shown good results with radial shockwaves, presenting it as a viable alternative when strengthening fails.^{30,31}



Fig. 1 Example of an original eccentric exercise for non-insertional Achilles tendinopathy treatment, as described by Alfredson.

Surgical Treatment

Approximately 25 to 30% of patients with non-insertional Achilles tendinopathy progress to surgical treatment due to conservative therapy failure, which is commonly established after at least 6 months of good non-operative approach. All proposed techniques have, at most, a grade of recommendation “C” (poor or conflicting evidence based on level IV and V studies) and support positive (self-reported) results in about 83% of cases. However, they are not immune from potential complications, rates that approach an average of 6.3% and might reach 42% in some case series. Patients with severe comorbidities and diseases that compromises the local vasculature have clear contraindications to surgery.^{18,32}

Like many non-surgical modalities, surgery attempts to induce an organized healing response in result of local tissue

manipulation. In addition, it removes new vessels and nerves established in the anterior portion of the tendon that contribute to pain and degeneration. Open tenoplasty is the classical procedure, as it allows intratendinous stricken tissue resection. Success rates from 36 to 100% (average of 78.9%) have been reported.³³

Excessive removal of degenerated tissue can weaken the tendon and increase its susceptibility to rupture. The traditional recommendation to reinforce, rebuild, or transfer tendons in case of Achilles degeneration superior of 50% or removal of more than 50% is extremely empirical and not supported by the literature.^{34,35} The subjective presence of a large portion of tendinopathy must be managed with tendon salvage procedures depending on the quality of the triceps surae muscle. Grade-0 and grade-1 fatty infiltrations allow the Achilles to be reconstructed with a free graft, such as the semitendinosus tendon. Goutallier grade 2, 3, or 4 muscles (or tendons with extreme proximal stump adherence) should be abandoned, and a tendon transfer, such as from the flexor hallucis longus (in an open or endoscopic procedure), must be performed.^{21,22,36}

Less invasive procedures are indicated in earlier stages and mild conditions. Achilles tenoscopy with anterior tendon debridement has been reported successful, though the limited published papers.³⁷ Plantaris tenotomy, whether or not associated with a tenoscopic procedure (► **Figure 2**), has also shown encouraging results despite the lack of good studies to support it³⁸ Proximal gastrocnemius stretching, intends to alleviate posterior calf tightness and presents with 92% of positive outcomes according to few specific studies.³⁹ Percutaneous Achilles tenotomies in diseased areas focus in stimulating local healing and have shown a success rate of up to 75%.⁴⁰ Minimally invasive anterior tendon detachment using a large suture line was reported as both short- and long-term effective.⁴¹ The indicated treatment modalities based on currently available scientific evidence are summarized in ► **Table 1**.

Insertional Achilles Tendinopathy

Epidemiology

The populational incidence of insertional tendinopathy is 3.7%; this condition accounts for 25% of all diseases of the Achilles. Its prevalence in athletic runners ranges between 5 and 18%. Insertional tendinopathy occurs in sedentary patients, profoundly impacting their functions and quality of life, as it does for professional sportsmen (women), resulting in loss of performance. It is estimated that 50% of runners will have at least one episode of insertional tendinopathy during their lifetime. Treatment-related costs may be around £ 14,000 per patient, considering only the non-surgical management. However, this value may increase sevenfold when the operative outcome is included in the analysis.⁴²⁻⁴⁴

Clinical Presentations

Patients often seek care complaining of pain, swelling, loss of strength, and local stiffness. They refer to progressive diffi-

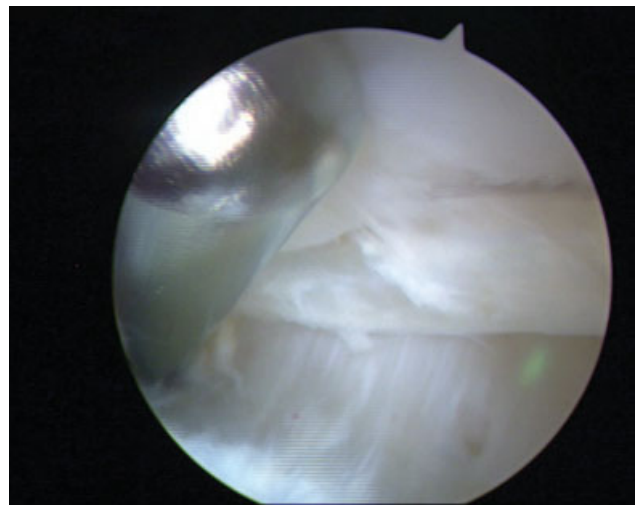


Fig. 2 An Achilles tenoscopy for anterior Achilles debridement and plantaris tenotomy.

Table 1 Recommendation grade for non-insertional Achilles tendinopathy treatments

Modality	Recommendation grade
Eccentric exercises	A
Shockwave therapy	B
Platelet-rich plasma	I
Open tenoplasty	B
Endoscopic tenoplasty	I
Tendon transfer	I
Percutaneous procedures	I
Gastrocnemius recession	I

culties in athletic training, simple walks and even daily activities. This local hypersensitivity is exacerbated by the use of shoes with tight buttresses (which directly compress the diseased region) or by increased physical demand. Diagnosis is essentially clinical, so ancillary tests, including radiography (RX), ultrasound (US) and MRi are performed only to confirm the lesion, exclude differential diagnoses and possibly aid in operative planning.⁴⁵

The diagnosis of Achilles insertional tendinopathy (AIT) is established by pain during palpation of the tendon attachment region in the calcaneal bone (and up to two centimeters proximal to it). The presence of local edema, which may be associated with low-grade inflammation of the pre-Achillean bursa, supports the hypothesis. The two-fingers test evaluates the occurrence of retrocalcaneal bursitis and Haglund deformity. It is deemed positive when the patient reports pain after compression of the anterior tendon region, just proximal to the attachment site. The Silfverskiöld test evaluates the structure(s) responsible for posterior calf tightness, a condition often associated with Achilles tendinopathy. It is performed with the patient in prone position, by observing the improvement or not of the ankle extension (and muscles tightness) during passive knee flexion.

Although these last two tests are not required for insertional Achilles tendinopathy diagnosis, they may be helpful when choosing the treatment.^{9,45,46}

Subsidiary Exams

Subsidiary exams may provide some information for prognosis and therapeutic planning of patients with AIT. Radiographs may demonstrate the increased local soft-tissue volume, a traction enthesophyte (upper spur) and Haglund disease (pump bump), a bone neoformation on the upper surface of the calcaneal bone tuberosity, anterior to the retrocalcaneal bursa. Eventually, intratendinous calcifications are observed. Ultrasound can identify areas of degeneration, calcium and bone tissue formation through their respective acoustic shadows. MRI best defines the so-called “insertional tendinopathy pentad” as it clearly shows both bursopathies, the degenerative tendon disease, Haglund deformity, and the traction enthesophyte. All these findings usually persist after the natural course of the disease or even after a successful treatment; as such, they are not considered criteria for discharge or success in the AIT approach. Some asymptomatic patients may present such findings in a routine examination.^{47,48}

Non-surgical Treatment

The traditional initial therapeutic approach is non-surgical. The search for a better outcome in patients with insertional tendinopathy led several authors to establish the same Alfredson eccentric protocol for this group.²³ However, even with the modifications described by Jonsson et al.⁴⁹ (exercises performed at ground level, without the negative ankle dorsiflexion phase on the step that may be painful for insertional Achilles tendinopathy patients), the good outcomes associated with the non-insertional disease were not replicated in this population. Studies have reported positive outcomes in only 32 to 67% of the patients. In addition, several conservative treatment modalities have been disappointing in recent decades, with results even lower than the eccentric exercises (EE). As such, even under these negative circumstances, the modified Alfredson protocol was considered the standard for the non-operative approach to the insertional condition, currently holding a grade B (reasonable evidence based on level II and III studies) for therapeutic recommendation.^{9,49-51}

Shockwave therapy uses energy waves (→ **Figure 3**) that propagates in three dimensions to induce an abrupt increase (in nanoseconds) in intrasubstantial pressure.⁵² Its use is directed to the induction of interstitial and extracellular responses that may lead to tissue regeneration. Studies show that SWT direct effects the stimulation of healing factors.^{53,54} For Achilles tendinopathies, moderate-quality studies showed that this procedure has reliable results and very low risks. Clinical trials from Costa et al.,³⁰ Furia,⁵⁵ Rompe et al.⁵⁶ and Rasmussen et al.⁵⁷ presented good results (80–88 points) and superiority over traditional therapies (stretching, manipulation, ultrasound), eccentric strengthening and placebo. Shockwave therapy holds a grade “B” recommendation ... for AIT. More recently, new studies tried to exacerbate the positive response to non-surgical treat-

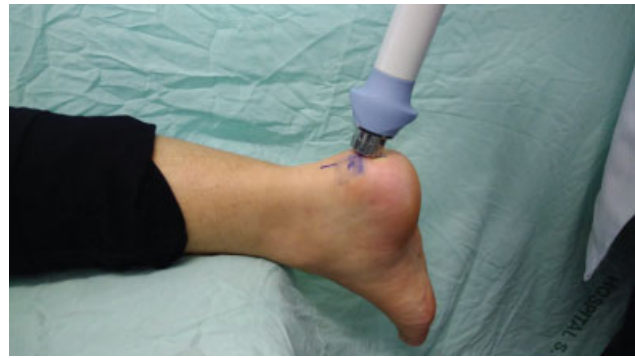

Fig. 3 Positioning and application of radial shockwave therapy for Achilles insertional tendinopathy.

ment by combining modalities or introducing new alternatives. However, their outcomes are premature and have no external validity.^{30,56,58}

Systematic reviews and review articles published in recent decades displayed the harsh scenario regarding current Achilles insertion tendinopathy treatments. Traditional non-surgical therapies (physical therapy, infiltrations) have inconsistent and discouraging results. There is a clear recommendation for eccentric exercises in the initial management of the disease, even though studies supporting them are poorly designed. Kearney and Costa⁴⁶ found a single article⁵⁵ showing the effectiveness of SWT in insertional Achilles tendinopathy, but with several criticisms to its methodology and outcome assessments. Al-Abbad and Simon⁵⁹ stated that, despite the paucity of studies, EE must be used as conservative treatment, and SWT must fail before surgery is indicated.^{10,46,60}

Surgical Treatment

The unfavorable results drove many patients with AIT for surgical intervention, with studies reporting this approach in 53 to 89% of the cases. Different techniques have been described for this condition, from the simplest ones, such as percutaneous ablation, gastrocnemius recession and arthroscopic debridement, to more traditional procedures, such as open resection of degenerated tissue, free-graft tendon reconstruction and tendon transfers. The satisfactory outcome rate of these approaches, although supported by low-level evidence, ranges from 75 to 95%. However, there were complications, with rates reaching 21% in some studies and with a considerable proportion (about 5%) evolving to new interventions and continued treatments. In addition, the high cost of surgery for insertional Achilles tendinopathy, including hospitalization and medical fees, consumables and implants costs, must be considered.^{61,62}

Among the surgical treatment modalities, only open resection with tendon reinsertion holds a a grade “B” recommendation (based on case series), with up to showing up to 96% of good outcomes.³⁵ Tendon transfers, percutaneous ablation, endoscopic debridement, and gastrocnemius lengthening still hold an grade “I” recommendation grade (insufficient studies for any recommendation).¹⁰

Open resection is commonly performed through a wide longitudinal incision, bursal resection, tendon opening,

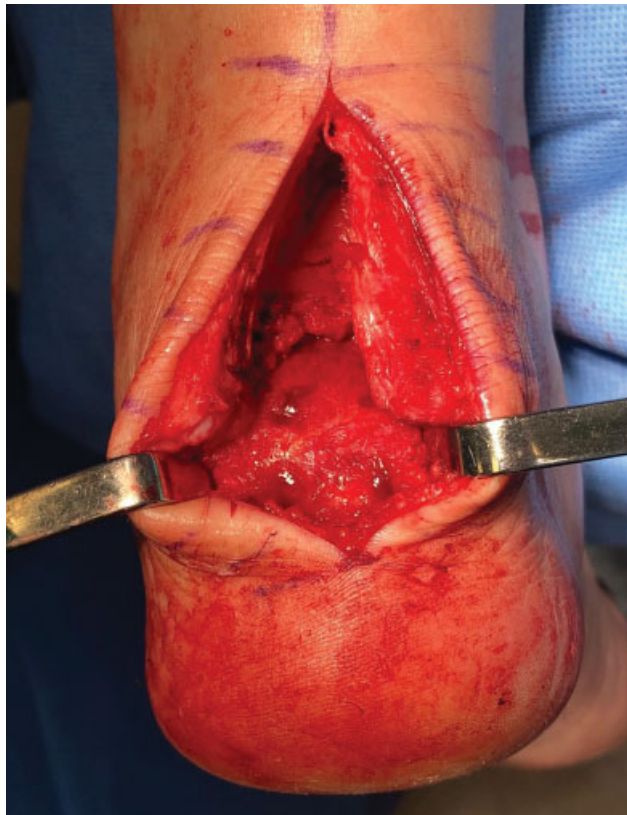

Fig. 4 Open calcaneal insertional tenoplasty with resection of enthesophyte, Haglund and bursae for subsequent reinsertion with a double-row anchor system.

Haglund removal, enthesophyte resection, and reinsertion with bones anchors (► **Figure 4**). The analysis of the tendon amount that can be resected remains empirical, although the 50% rule is usually ignored by many authors. In advanced tendinopathies, a free graft or local tendon transfers can be used according to the quality of the triceps surae muscle, as discussed for non-insertional tendinopathies. The semitendinosus and flexor hallucis longus are, respectively, preferred donors due proximity and biomechanical characteristics.^{8,21}

An attempt to reduce morbidity and complications resulting from traditional procedures has led to the development of less invasive and aggressive techniques. The endoscopic or percutaneous debridement of Haglund deformity, pre-Achilles bursa and anterior tendon has emerged as an option, despite its inability in accessing a potential enthesophyte or intratendinous calcification. Proximal gastrocnemius recession also had incipient results in the treatment of insertional Achilles tendinopathy. Other approaches, such as percutaneous ablation and percutaneous calcaneal osteotomy (Zadek) are supported only by small case series.⁶³ The summary of treatment indications based on current scientific evidence is summarized in ► **Table 2**.

Final Considerations

Achilles tendinopathies are challenging for patients and for the entire health care system since treatments are long, costly, and often ineffective. The non-insertional form of

Table 2 Recommendation grade for insertional Achilles tendinopathy treatments

Modality	Recommendation grade
Eccentric exercises	B
Shockwave therapy	B
Stretching	I
Platelet-rich plasma	I
Sclerotic agents	I
Open tenoplasty	B
Endoscopic tenoplasty	I
Tendon transfer	I
Gastrocnemius recession	I

the disease is best supported by good-quality studies showing that eccentric exercises are an excellent modality in the initial approach, with a grade “A” recommendation. Failure of this non-operative treatment is backed by SWT and open tenoplasty, both holding a grade “B” recommendation. Infiltration techniques have no scientific substrate for their use and least invasive methods are still incipient, despite the good outcomes reported.

Treatment for the insertional form of the disorder is still surrounded by controversies, ranging from conservative to surgical. The modified eccentric strengthening protocol did not achieve the same results as in non-insertional tendinopathy, receiving a grade “B” recommendation. This same grade is held by extracorporeal SWT and open tendon debridement. Modalities attempting to enhance the positive outcomes of nonoperative treatment and less aggressive surgeries have been proposed to increase success rates and decrease complications. However, there are few studies, most lacking validation. This scenario of uncertainty has received attention from the scientific community, which has been trying to produce quality data that may help with treatment choices for this condition.

Conflict of Interests

The authors declare that have no conflict of interests.

References

- Cohen JC. Anatomy and biomechanical aspects of the gastro-soleus complex. *Foot Ankle Clin* 2009;14(04):617–626
- Doral MN, Alam M, Bozkurt M, et al. Functional anatomy of the Achilles tendon. *Knee Surg Sports Traumatol Arthrosc* 2010;18(05):638–643
- Dalmau-Pastor M, Fargues-Polo B Jr, Casanova-Martínez D Jr, Vega J, Golanó P. Anatomy of the triceps surae: a pictorial essay. *Foot Ankle Clin* 2014;19(04):603–635
- Longo UG, Ronga M, Maffulli N. Achilles tendinopathy. *Sports Med Arthrosc Rev* 2009;17(02):112–126
- Shaw HM, Vázquez OT, McGonagle D, Bydder G, Santer RM, Benjamin M. Development of the human Achilles tendon enthesis organ. *J Anat* 2008;213(06):718–724
- Maffulli N, Barras V, Ewen SWB. Light microscopic histology of achilles tendon ruptures. A comparison with unruptured tendons. *Am J Sports Med* 2000;28(06):857–863

- 7 Bernstein DN, Anderson MR, Baumhauer JF, et al. A Comparative Analysis of Clinical Outcomes in Noninsertional Versus Insertional Tendinopathy Using PROMIS. *Foot Ankle Spec* 2018;12(04):350–356
- 8 Roche AJ, Calder JD. Achilles tendinopathy: A review of the current concepts of treatment. *Bone Joint J* 2013;95-B(10):1299–1307
- 9 Magnan B, Bondi M, Pierantoni S, Samaila E. The pathogenesis of Achilles tendinopathy: a systematic review. *Foot Ankle Surg* 2014;20(03):154–159
- 10 Chimenti RL, Cychosz CC, Hall MM, Phisitkul P. Current Concepts Review Update: Insertional Achilles Tendinopathy. *Foot Ankle Int* 2017;38(10):1160–1169
- 11 Vieira CP, Guerra FR, Oliveira LP, Almeida MS, Pimentel ER. Alterações no tendão de Aquiles após inflamação em tecido adjacente. *Acta Ortop Bras* 2012;20(05):266–269
- 12 Magra M, Maffulli N. Genetic aspects of tendinopathy. *J Sci Med Sport* 2008;11(03):243–247
- 13 Ribbans WJ, Collins M. Pathology of the tendo Achillis: do our genes contribute? *Bone Joint J* 2013;95-B(03):305–313
- 14 van der Vlist AC, Breda SJ, Oei EHG, Verhaar JAN, de Vos RJ. Clinical risk factors for Achilles tendinopathy: a systematic review. *Br J Sports Med* 2019;pii: bjsports-2018-099991
- 15 Marie I, Delafenêtre H, Massy N, Thuillez C, Noblet C; Network of the French Pharmacovigilance Centers. Tendinous disorders attributed to statins: a study on ninety-six spontaneous reports in the period 1990-2005 and review of the literature. *Arthritis Rheum* 2008;59(03):367–372
- 16 de Jonge S, van den Berg C, de Vos RJ, et al. Incidence of midportion Achilles tendinopathy in the general population. *Br J Sports Med* 2011;45(13):1026–1028
- 17 Yelland MJ, Sweeting KR, Lyftogt JA, Ng SK, Scuffham PA, Evans KA. Prolotherapy injections and eccentric loading exercises for painful Achilles tendinosis: a randomised trial. *Br J Sports Med* 2011;45(05):421–428
- 18 Baltes TPA, Zwiers R, Wiegerinck JI, van Dijk CN. Surgical treatment for midportion Achilles tendinopathy: a systematic review. *Knee Surg Sports Traumatol Arthrosc* 2017;25(06):1817–1838
- 19 Singh A, Calafi A, Diefenbach C, Kreulen C, Giza E. Noninsertional Tendinopathy of the Achilles. *Foot Ankle Clin* 2017;22(04):745–760
- 20 Maffulli N, Via AG, Oliva F. Chronic Achilles Tendon Disorders: Tendinopathy and Chronic Rupture. *Clin Sports Med* 2015;34(04):607–624
- 21 Hoffmann A, Mamisch N, Buck FM, Espinosa N, Pfirrmann CWA, Zanetti M. Oedema and fatty degeneration of the soleus and gastrocnemius muscles on MR images in patients with Achilles tendon abnormalities. *Eur Radiol* 2011;21(09):1996–2003
- 22 Fischer MA, Pfirrmann CWA, Espinosa N, Raptis DA, Buck FM. Dixon-based MRI for assessment of muscle-fat content in phantoms, healthy volunteers and patients with achillobodynia: comparison to visual assessment of calf muscle quality. *Eur Radiol* 2014;24(06):1366–1375
- 23 Alfredson H, Pietilä T, Jonsson P, Lorentzon R. Heavy-load eccentric calf muscle training for the treatment of chronic Achilles tendinosis. *Am J Sports Med* 1998;26(03):360–366
- 24 Sussmilch-Leitch SP, Collins NJ, Bialocerkowski AE, Warden SJ, Crossley KM. Physical therapies for Achilles tendinopathy: systematic review and meta-analysis. *J Foot Ankle Res* 2012;5(01):15
- 25 Alfredson H. Clinical commentary of the evolution of the treatment for chronic painful mid-portion Achilles tendinopathy. *Braz J Phys Ther* 2015;19(05):429–432
- 26 Silbernagel KG, Thomeé R, Thomeé P, Karlsson J. Eccentric overload training for patients with chronic Achilles tendon pain—a randomised controlled study with reliability testing of the evaluation methods. *Scand J Med Sci Sports* 2001;11(04):197–206
- 27 de Jonge S, de Vos RJ, Weir A, et al. One-year follow-up of platelet-rich plasma treatment in chronic Achilles tendinopathy: a double-blind randomised placebo-controlled trial. *Am J Sports Med* 2011;39(08):1623–1629
- 28 Alfredson H, Öhberg L. Sclerosing injections to areas of neo-vascularisation reduce pain in chronic Achilles tendinopathy: a double-blind randomised controlled trial. *Knee Surg Sports Traumatol Arthrosc* 2005;13(04):338–344
- 29 Coombes BK, Bisset L, Vicenzino B. Efficacy and safety of corticosteroid injections and other injections for management of tendinopathy: a systematic review of randomised controlled trials. *Lancet* 2010;376(9754):1751–1767
- 30 Costa ML, Shepstone L, Donell ST, Thomas TL. Shock wave therapy for chronic Achilles tendon pain: a randomized placebo-controlled trial. *Clin Orthop Relat Res* 2005;440(440):199–204
- 31 Korakakis V, Whiteley R, Tzavara A, Malliaropoulos N. The effectiveness of extracorporeal shockwave therapy in common lower limb conditions: a systematic review including quantification of patient-rated pain reduction. *Br J Sports Med* 2018;52(06):387–407
- 32 Zwiers R, Wiegerinck JI, van Dijk CN. Treatment of midportion Achilles tendinopathy: an evidence-based overview. *Knee Surg Sports Traumatol Arthrosc* 2016;24(07):2103–2111
- 33 Tallon C, Coleman BD, Khan KM, Maffulli N. Outcome of surgery for chronic Achilles tendinopathy. A critical review. *Am J Sports Med* 2001;29(03):315–320
- 34 Kolodziej P, Glisson RR, Nunley JA. Risk of avulsion of the Achilles tendon after partial excision for treatment of insertional tendinitis and Haglund's deformity: a biomechanical study. *Foot Ankle Int* 1999;20(07):433–437
- 35 Nunley JA, Ruskin G, Horst F. Long-term clinical outcomes following the central incision technique for insertional Achilles tendinopathy. *Foot Ankle Int* 2011;32(09):850–855
- 36 Rahm S, Spross C, Gerber F, Farshad M, Buck FM, Espinosa N. Operative treatment of chronic irreparable Achilles tendon ruptures with large flexor hallucis longus tendon transfers. *Foot Ankle Int* 2013;34(08):1100–1110
- 37 Pearce CJ, Carmichael J, Calder JD. Achilles tendinosis and plantaris tendon release and division in the treatment of non-insertional Achilles tendinopathy. *Foot Ankle Surg* 2012;18(02):124–127
- 38 van Sterkenburg MN, Kerkhoffs GM, van Dijk CN. Good outcome after stripping the plantaris tendon in patients with chronic mid-portion Achilles tendinopathy. *Knee Surg Sports Traumatol Arthrosc* 2011;19(08):1362–1366
- 39 Duthon VB, Lübbecke A, Duc SR, Stern R, Assal M. Noninsertional Achilles tendinopathy treated with gastrocnemius lengthening. *Foot Ankle Int* 2011;32(04):375–379
- 40 Maffulli N, Oliva F, Testa V, Capasso G, Del Buono A. Multiple percutaneous longitudinal tenotomies for chronic Achilles tendinopathy in runners: a long-term study. *Am J Sports Med* 2013;41(09):2151–2157
- 41 Longo UG, Ramamurthy C, Denaro V, Maffulli N. Minimally invasive stripping for chronic Achilles tendinopathy. *Disabil Rehabil* 2008;30(20-22):1709–1713
- 42 Amin NH, McCullough KC, Mills GL, Jones MH. The Impact and Functional Outcomes of Achilles Tendon Pathology in National Basketball Association Players. *Clin Res Foot Ankle* 2016;4(03):205
- 43 Hutchison A-M, Laing H, Williams P, Bodger O, Topliss C. The effects of a new Tendo-Achilles Pathway (TAP) on an orthopaedic department— A quality improvement study. *Musculoskelet Sci Pract* 2019;39:67–72
- 44 Waldecker U, Hofmann G, Drewitz S. Epidemiologic investigation of 1394 feet: coincidence of hindfoot malalignment and Achilles tendon disorders. *Foot Ankle Surg* 2012;18(02):119–123
- 45 Den Hartog BD. Insertional Achilles tendinosis: pathogenesis and treatment. *Foot Ankle Clin* 2009;14(04):639–650
- 46 Kearney R, Costa ML, Tr F. Insertional achilles tendinopathy management: a systematic review. *Foot Ankle Int* 2010;31(08):689–694
- 47 Stenson JF, Reb CW, Daniel JN, Saini SS, Albana MF. Predicting Failure of Nonoperative Treatment for Insertional Achilles Tendinosis. *Foot Ankle Spec* 2018;11(03):252–255

- 48 Krishna Sayana M, Maffulli N. Insertional Achilles tendinopathy. *Foot Ankle Clin* 2005;10(02):309–320
- 49 Jonsson P, Alfredson H, Sunding K, Fahlström M, Cook J. New regimen for eccentric calf-muscle training in patients with chronic insertional Achilles tendinopathy: results of a pilot study. *Br J Sports Med* 2008;42(09):746–749
- 50 Fahlström M, Jonsson P, Lorentzon R, Alfredson H. Chronic Achilles tendon pain treated with eccentric calf-muscle training. *Knee Surg Sports Traumatol Arthrosc* 2003;11(05):327–333
- 51 Kearney RS, Costa ML. Collagen-matrix allograft augmentation of bilateral rupture of the achilles tendon. *Foot Ankle Int* 2010;31(06):556–559
- 52 Notarnicola A, Moretti B. The biological effects of extracorporeal shock wave therapy (eswt) on tendon tissue. *Muscles Ligaments Tendons J* 2012;2(01):33–37
- 53 Wang CJ. Extracorporeal shockwave therapy in musculoskeletal disorders. *J Orthop Surg Res* 2012;7(01):11
- 54 Kertzman P, Lenza M, Pedrinelli A, Ejnisman B. Shockwave treatment for musculoskeletal diseases and bone consolidation: qualitative analysis of the literature. *Rev Bras Ortop* 2015;50(01):3–8
- 55 Furia JP. [Extracorporeal shockwave therapy in the treatment of chronic insertional Achilles tendinopathy]. *Orthopade* 2005;34(06):571–578
- 56 Rompe JD, Furia J, Maffulli N. Eccentric loading compared with shock wave treatment for chronic insertional achilles tendinopathy. A randomized, controlled trial. *J Bone Joint Surg Am* 2008;90(01):52–61
- 57 Rasmussen S, Christensen M, Mathiesen I, Simonson O. Shock-wave therapy for chronic Achilles tendinopathy: a double-blind, randomized clinical trial of efficacy. *Acta Orthop* 2008;79(02):249–256
- 58 Mansur NSB, Baumfeld T, Villalon F, et al. Shockwave Therapy Associated With Eccentric Strengthening for Achilles Insertional Tendinopathy: A Prospective Study. *Foot Ankle Spec* 2019;••:1938640019826673
- 59 Al-Abbad H, Simon JV. The effectiveness of extracorporeal shock wave therapy on chronic achilles tendinopathy: a systematic review. *Foot Ankle Int* 2013;34(01):33–41
- 60 Mani-Babu S, Morrissey D, Waugh C, Screen H, Barton C. The effectiveness of extracorporeal shock wave therapy in lower limb tendinopathy: a systematic review. *Am J Sports Med* 2015;43(03):752–761
- 61 Shakked RJ, Raikin SM. Insertional Tendinopathy of the Achilles: Debridement, Primary Repair, and When to Augment. *Foot Ankle Clin* 2017;22(04):761–780
- 62 Traina F, Perna F, Ruffilli A, et al. Surgical treatment of insertional Achilles tendinopathy: a systematic review. *J Biol Regul Homeost Agents* 2016;30(04, Suppl 1):131–138
- 63 Syed TA, Perera A. A Proposed Staging Classification for Minimally Invasive Management of Haglund's Syndrome with Percutaneous and Endoscopic Surgery. *Foot Ankle Clin* 2016;21(03):641–664