

# Osteosynthesis of Fractures of the Metacarpal Neck with Self-Compressing Screw - Preliminary Analysis of 21 Cases\*

## *Osteossíntese de fraturas do colo do metacarpo com parafuso autocompressivo - Análise preliminar de 21 casos*

Celso Ricardo Folberg<sup>1</sup> Jairo André de Oliveira Alves<sup>1</sup> Otávio Pereira Cadore<sup>2</sup>   
Fernando Maurenre Sirena<sup>1</sup>

<sup>1</sup>Hand Surgery Group, Orthopedics and Traumatology Service, Hospital de Clínicas de Porto Alegre, Porto Alegre, RS, Brazil

<sup>2</sup>Orthopedics and Traumatology Service, Hospital de Clínicas de Porto Alegre, Porto Alegre, RS, Brazil

Address for correspondence Celso Ricardo Folberg, MSc, Rua Sinke, 236, casa 45, Porto Alegre, RS, 90840-150, Brazil (e-mail: cfolberg@hcpa.edu.br).

Rev Bras Ortop 2021;56(2):198–204.

### Abstract

**Objective** The present study aims to analyze the clinical results of the surgical treatment of metacarpal neck fractures with retrograde intramedullary fixation using cannulated headless screws (Herbert type).

**Methods** Retrospective study of 21 closed fractures deviated from the metacarpal neck in 21 patients operated between April 2015 and November 2018.

**Results** The sample included 19 men and 2 women. The mechanisms that caused the trauma were punching, falling to the ground and motor vehicle accident (n = 14, 5 and 2). The affected metacarpals were the 5<sup>th</sup>, 3<sup>rd</sup>, and 2<sup>nd</sup> (n = 19, 1 and 1). Surgical indications were neck-shaft diaphysis of the metacarpal > 30° for the 2<sup>nd</sup> and 3<sup>rd</sup> metacarpals and > 40° for the 5<sup>th</sup> metacarpal, shortening ≥ 5mm, rotational deviation, and the desire of the patient not to use plaster cast. In the immediate postoperative period, patients remained without immobilization and were instructed to mobilize their fingers according to tolerance. All patients had total active mobility > 240° and returned to their former occupations. All fractures consolidated and there were no reinterventions.

**Discussion** The great advantages of the headless screw technique are its low morbidity, sufficient stability to avoid external immobilization, and reproducibility at low cost.

**Conclusion** This is an easy, fast technique that has excellent results for the surgical treatment of displaced fractures of the neck of the metacarpals.

### Keywords

- ▶ fractures, bone
- ▶ hand
- ▶ metacarpus

\* Work developed at the Hand Surgery Group, Orthopedics and Traumatology Service, Hospital de Clínicas de Porto Alegre (HCPA), Porto Alegre, RS, Brazil.

received  
January 17, 2020  
accepted  
May 5, 2020

DOI <https://doi.org/10.1055/s-0040-1714229>.  
ISSN 0102-3616.

© 2021. Sociedade Brasileira de Ortopedia e Traumatologia. All rights reserved.

This is an open access article published by Thieme under the terms of the Creative Commons Attribution-NonDerivative-NonCommercial-License, permitting copying and reproduction so long as the original work is given appropriate credit. Contents may not be used for commercial purposes, or adapted, remixed, transformed or built upon. (<https://creativecommons.org/licenses/by-nc-nd/4.0/>)

Thieme Revinter Publicações Ltda., Rua do Matoso 170, Rio de Janeiro, RJ, CEP 20270-135, Brazil

**Resumo**

**Objetivo** O presente estudo visa analisar os resultados clínicos do tratamento cirúrgico das fraturas de colo do metacarpo com fixação intramedular retrógrada utilizando parafusos canulados sem cabeça (tipo Herbert).

**Métodos** Estudo retrospectivo de 21 fraturas fechadas desviadas do colo do metacarpo em 21 pacientes operados entre abril de 2015 e novembro de 2018.

**Resultados** A casuística incluiu 19 homens e 2 mulheres. Os mecanismos causadores do trauma foram soco, queda ao solo e acidente com veículo motorizado (n = 14, 5 e 2). Os metacarpos acometidos foram o V, III e II (n = 19, 1 e 1). As indicações cirúrgicas foram angulação colo-diáfise do metacarpo > 30° para os II e III metacarpos e > 40° para o V metacarpo, encurtamento ≥ 5mm, desvio rotacional e o desejo do paciente de não utilizar imobilização gessada. No pós-operatório imediato, os pacientes permaneceram sem imobilização e orientados a mobilizar os dedos conforme tolerância. Todos os pacientes ficaram com mobilidade ativa total > 240° e retornaram às suas antigas ocupações. Todas fraturas consolidaram e não houve reintervenções.

**Discussão** As grandes vantagens da técnica com parafuso sem cabeça são sua baixa morbidade, estabilidade suficiente para não precisar de imobilização externa e reprodutibilidade com baixo custo.

**Conclusão** Esta é uma técnica fácil, rápida, e que apresenta ótimos resultados para o tratamento cirúrgico das fraturas deslocadas do colo dos metacarpos.

**Palavras-chave**

- ▶ fraturas ósseas
- ▶ mãos
- ▶ metacarpo

**Introduction**

Metacarpal and phalangeal fractures account for 18% of all fractures below the elbow<sup>1</sup> and can be treated in several ways. Fractures of the neck of the metacarpals may have surgical indication when presenting rotational deviation, angulation or shortening, and the exact parameters of acceptable alignment are still controversial.<sup>2</sup>

Among the methods of internal fixation, we can highlight Kirschner wires, plates, and screws. The former usually require postoperative immobilization, promoting joint stiffness as it does not allow early mobility.<sup>3</sup> Plates and screws usually require extensive soft tissue dissection, which can cause tendon stiffness and adhesions. Although there is still no consensus on the best method, surgical treatment covers an overall complication rate of up to 36%. Of these, the most common are tendon injury, pseudoarthrosis, vicious consolidation, avascular necrosis, stiffness, and adhesions.<sup>4-6</sup>

In 2010, Boulton et al described a fixation technique for subcapital metacarpal fractures in order to minimize these complications and also promote early mobility, using a cannulated headless screw with retrograde fixation.<sup>7</sup> Later, Del Piñal et al<sup>8</sup> improved the technique, adding different reduction and fixation methods for comminuted fractures and for those fractures more likely to lose reduction or shortening, increasing the range of indications for complex fractures. In this study, the authors described 69 fractures in 59 patients, including 17 open fractures, being treated in just one time. He concluded that this is his method of choice for transverse and short oblique diaphyseal fractures, in addition to metaphyseal metacarpal and phalangeal fractures,

being contraindicated only in cases of open physis and current infection.

Our work describes the surgical technique and clinical results of retrograde intramedullary percutaneous fixation of the metacarpal neck fractures. In all cases, a cannulated headless screw was used in a series of cases operated between 2015 and 2018.

**Methods**

After approval by the Research Ethics Committee, a retrospective evaluation of clinical and radiographic data of 24 patients with closed metacarpal neck fractures surgically treated with retrograde headless screws (Herbert) was performed between April 2015 and November 2018. Three patients were lost follow-up and were excluded from the assessment. All patients were operated on and followed by the senior author (Folberg C. R.).

Standard radiographs in anteroposterior and oblique views of the hand were obtained to assess fracture deviation and angulation. The measure of angulation in degrees was measured in oblique views. The surgical indications were neck-diaphysis metacarpal angle > 30° for the 2<sup>nd</sup> and 3<sup>rd</sup> metacarpals, and > 40° for the 5<sup>th</sup> metacarpal, shortening ≥ 5 mm, rotational deviation, and patient's wish not to use cast immobilization. All patients were evaluated by the senior author both before and after surgery, discussing the risks and benefits of surgery. Before signing the informed consent form, in addition to the guidelines on the surgical procedure, the postoperative instructions were widely discussed, explaining the importance of early mobilization without load so that they could achieve complete joint mobility as soon as possible.

## Surgical Technique

All patients were operated under sedation and axillary anesthetic block of the brachial plexus, except for the last two patients. In these, wide awake local anesthesia no tourniquet (WALANT) was the technique used, when local anesthesia with adrenaline is used and the patient remains awake during the procedure.

Fractures were reduced in a closed manner with manual traction, manipulation of the proximal and distal fragments and flexion of the metacarpophalangeal joint. In three cases it was necessary to use a Kirschner wire to reduce the fracture, which was introduced into the focus of the fracture leveraging and maintaining the reduction temporarily until the Herbert screw was introduced.

A 16-gauge needle was positioned, with the aid of an image intensifier, in the center of the metacarpal head in both anteroposterior and lateral views and directed to the intramedullary canal. This needle was inserted manually into the intramedullary canal of the metacarpal until it crossed the focus of the fracture in the proximal fragment. The guidewire of the Herbert screw was introduced through the needle to the base of the metacarpal, where it was then fixed (► **Figure 1**). The needle was removed and an incision (stab-type incision with a scalpel in the longitudinal direction of the tendon) of ~ 3 mm adjacent to the guidewire was made through the skin, the extensor tendon and the joint capsule. Afterwards, the 1.6 mm long and 2.0 mm short drills were used to prepare for the insertion of the 3.0 mm Herbert screw. In all cases, the longest available screw (30 mm) was used, always remaining below the joint surface under radioscopic control.

In 2 patients with unstable comminuted fractures, in whom the compression of the fragments would not be beneficial for the fixation – the objective would only be to stabilize the fracture – a 1.5 mm Kirschner wire was passed, transfixing and stabilizing the distal fragment to the adjacent metacarpal. After stabilizing the fracture with the screw, maintaining the height of the metacarpal, the Kirschner wire was removed. In other cases, the rotational deviation was controlled by viewing the fluoroscopy, and when the procedure was completed, with active or passive mobility of the fingers. There was no need for temporary fixation of the distal fragment for rotational control, since during fixation there did not appear to be significant rotational deviation. Rotational deviations and osteosynthesis stability were tested right after fixation. In patients in whom local anesthesia was used (WALANT) the test was performed with active mobility, and the others with passive mobility of the fingers and wrist.

After skin suture and dressing, an elastic band was applied and the patient was instructed to mobilize the fingers according to tolerance for 5 to 7 days until the first postoperative review, when control radiographs were obtained. With the decrease in pain and edema, patients were encouraged to mobilize their fingers for a full range of motion. At the next consultation, about 3 weeks after the operation, new radiographs were taken. If the range of

motion was improving very slowly, the patient was referred to a physiotherapy clinic. Otherwise, he was encouraged to keep the exercises at home. Patients were reevaluated at 6 and 12 weeks postoperatively, when most patients had their final evaluation if they had ample mobility and no complaints.

## Results

The sample included 19 men and 2 women, with a mean age of 33.4 years old (18–75 years old). The fracture occurred in the right hand in 15 patients and in the left hand in 6 patients. The mechanisms causing the trauma were punching against a wall/table/other people (n = 14), falling to the ground (n = 5) and traffic accident (n = 2). Fractures occurred in the neck of the 5<sup>th</sup> metacarpal (n = 19), the 3<sup>rd</sup> metacarpal (n = 1) and the 2<sup>nd</sup> metacarpal (n = 1).

The mean time from fracture to surgery was 9 ± 6 days.

Patient data are summarized in ► **Table 1**.

The operative time in all cases was < 45 minutes (interval between 10–42 minutes). There were no transoperative complications.

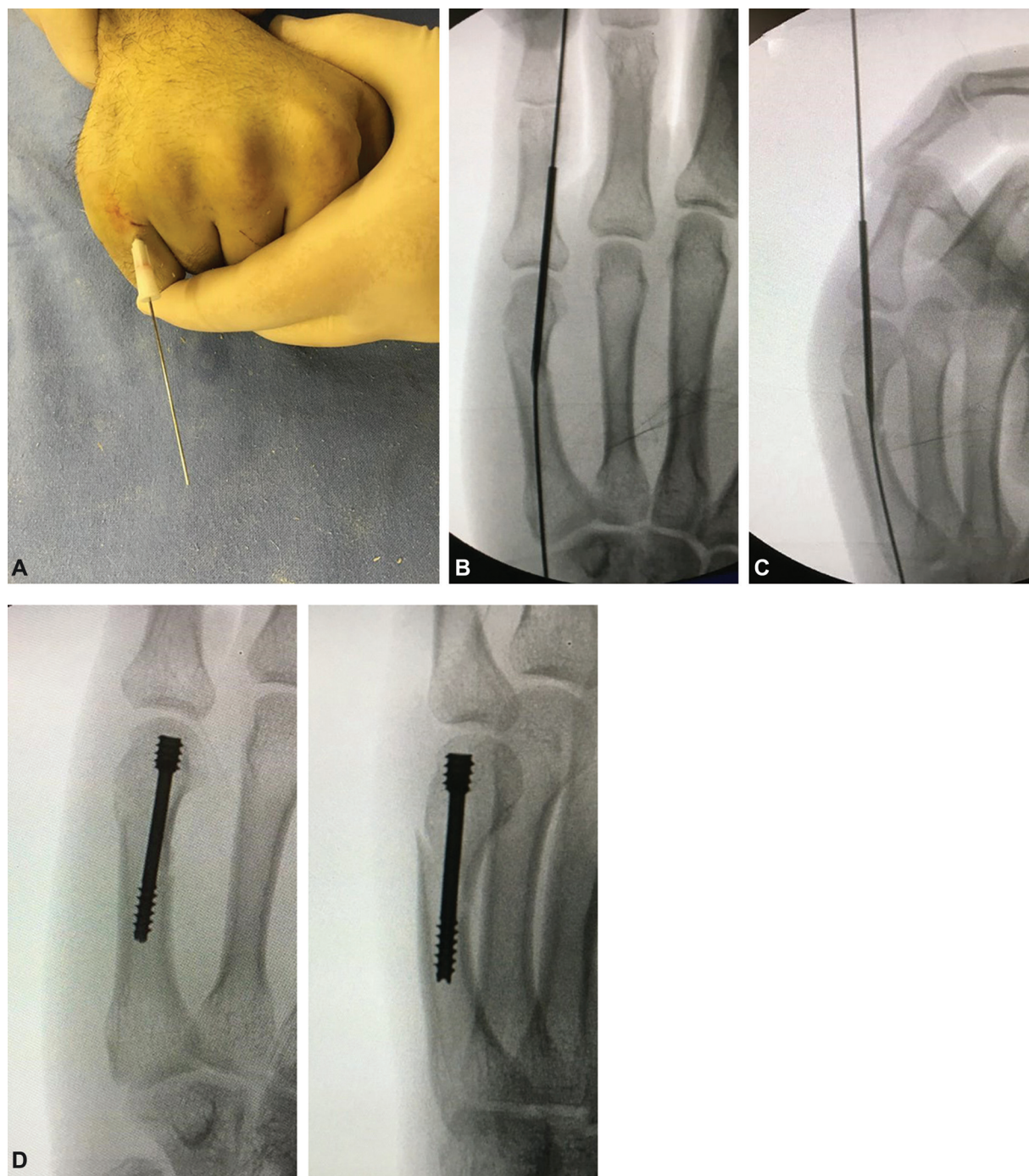
All fractures showed clinical and radiological consolidation. There was no case of vicious consolidation (no significant angular or rotational deviation). The last radiographs obtained with a longer follow-up did not show degenerative changes in any patient.

No patient had postoperative infection, tendon or capsular adhesions or complications related to the screw that required reoperation. All 21 patients had an excellent functional result, with an active total finger range of motion > 240°. Only one patient (second metacarpal fracture) had a 10° extensor lag and 10° less flexion of the metacarpophalangeal joint than the contralateral side (► **Figure 2**), without functional repercussions. Two patients had to remain undergoing physiotherapy and occupational therapy after 12 weeks postoperatively until complete range of motion was achieved, 1 at 16 and the other at 20 weeks. All patients returned to their previous activities, both laboral and sportive, as well as recreational ones, with no complaints regarding hand function.

## Discussion

The use of Kirschner wires in the surgical treatment of isolated fractures deviated from the metacarpals was, for a long time, the method of choice. Based on the flexible fastening concepts proposed by Ender et al<sup>9</sup> and subsequently by Foucher,<sup>10</sup> with anterograde intramedullary osteosynthesis, or stabilizing the fracture with crossed wires, presents good results.<sup>11</sup> However, complications such as infection, early loss of fixation, stiffness and nonconsolidation can reach 16% of cases.<sup>12,13</sup>

The choice for headless cannulated self-compressing screws introduced by Herbert et al to treat wrist and carpal fractures,<sup>14</sup> and more recently in the treatment of metacarpal and phalangeal fractures,<sup>8,15–18</sup> is an alternative to conventional treatments and brings some advantages: it



**Fig. 1** Details of the surgical technique: A) Introduction of the needle and guidewire after fracture reduction; B and C) Radioscopic control; D and E) Immediate postoperative result of fixation.

does not violate the focus of the fracture, it does not need plaster cast, and it allows early mobility. In addition, several studies have shown biomechanical superiority of intramedullary screws over intramedullary Kirschner wires.<sup>19,20</sup> The stability in the fracture focus can be given by fixing the screw thread in the endosteal canal, or as an intramedullary tutor, and it can even be a mixture of both, as suggested by Del Piñal et al.<sup>8</sup>

Our technique proposes the placement of the guidewire without a previous incision, and only a minimal incision

(stab-type incision with the scalpel blade in the longitudinal direction of the tendon), with no direct view of the tendon, of the joint capsule and of the articular surface of the metacarpal. Ruchelsman et al<sup>16</sup> described a small approach with longitudinal opening of the extensor tendon and dorsal arthrotomy, but, as well as in the work of Jann et al,<sup>17</sup> we believe that fluoroscopy provides a good view of the screw entry point. Lesion of the extensor tendon, as well as chondral lesion of the metacarpal head, caused by the entrance of the screw head, were not considered



**Table 1** Sample Characterization

Variables	n = 21
Age (years old) - mean ± SD	33.5 ± 14.3
Affected side - n (%)	
Right	15 (71.4)
Left	6 (28.6)
Bone - n (%)	
2 <sup>nd</sup> Metacarpal	1 (4.8)
3 <sup>rd</sup> Metacarpal	1 (4.8)
5 <sup>th</sup> Metacarpal	19 (90.5)
Angulation (degrees) - mean ± SD	
2 <sup>nd</sup> Metacarpal	32.0 ± 0.0
3 <sup>rd</sup> Metacarpal	35.0 ± 0.0
5 <sup>th</sup> Metacarpal	49.8 ± 11.4
Mechanism - n (%)	
Punch	14 (66.7)
Falling to the ground (football, cycling, falling from one's own height)	5 (23.8)
Motorcycle/car accident	2 (9.5)
Injury time to surgery (days) - mean ± SD	9.14 ± 6.17

Abbreviation: SD, standard deviation.

significant.<sup>18,21</sup> The request for active hand mobilization, with complete finger extension just after the screw was inserted, demonstrated functionality of the extensor mechanism during the operation. This was maintained in this way in all cases. The fixation of these fractures with local anesthesia with adrenaline and without the use of a tourniquet (WALANT), as described by Lalonde et al,<sup>22</sup> allows the awake patient to have active mobility during the operation. This makes it possible to test the extensor mechanism and visualize the stability of osteosynthesis under fluoroscopy, reinforcing for the patient the idea of being able to mobilize the finger safely and early. The protection of the affected finger, syndactylizing it with the adjacent finger for 30 days postoperatively as performed in the work by Jann et al<sup>17</sup> was not necessary in our cases.

Some authors claim that there is no compression at the fracture site, as the screw would only function as an internal stabilizer.<sup>23</sup> However, in the most comminuted fractures, compression of the screw may cause the fracture to become unstable and cause fracture deviation and shortening. In these cases, the use of a second screw (usually of smaller diameter) for stabilization is indicated, as it is well described by Del Piñal et al,<sup>8</sup> but it requires greater skill from the surgeon as the space is often small for placing two screws. The placement of a 1.5 mm Kirchner wire between the heads of the fractured metacarpal and the adjacent one, volarly to the screw already partially

penetrated, seemed to be easy and practical. This maneuver prevents the screw from compressing the fracture focus but allows for excellent stability when fixing the screw to the head. In the two cases in which we used this technique, we removed the wire immediately after passing the screw, confirming the stability of the fracture focus, and obtaining good results.

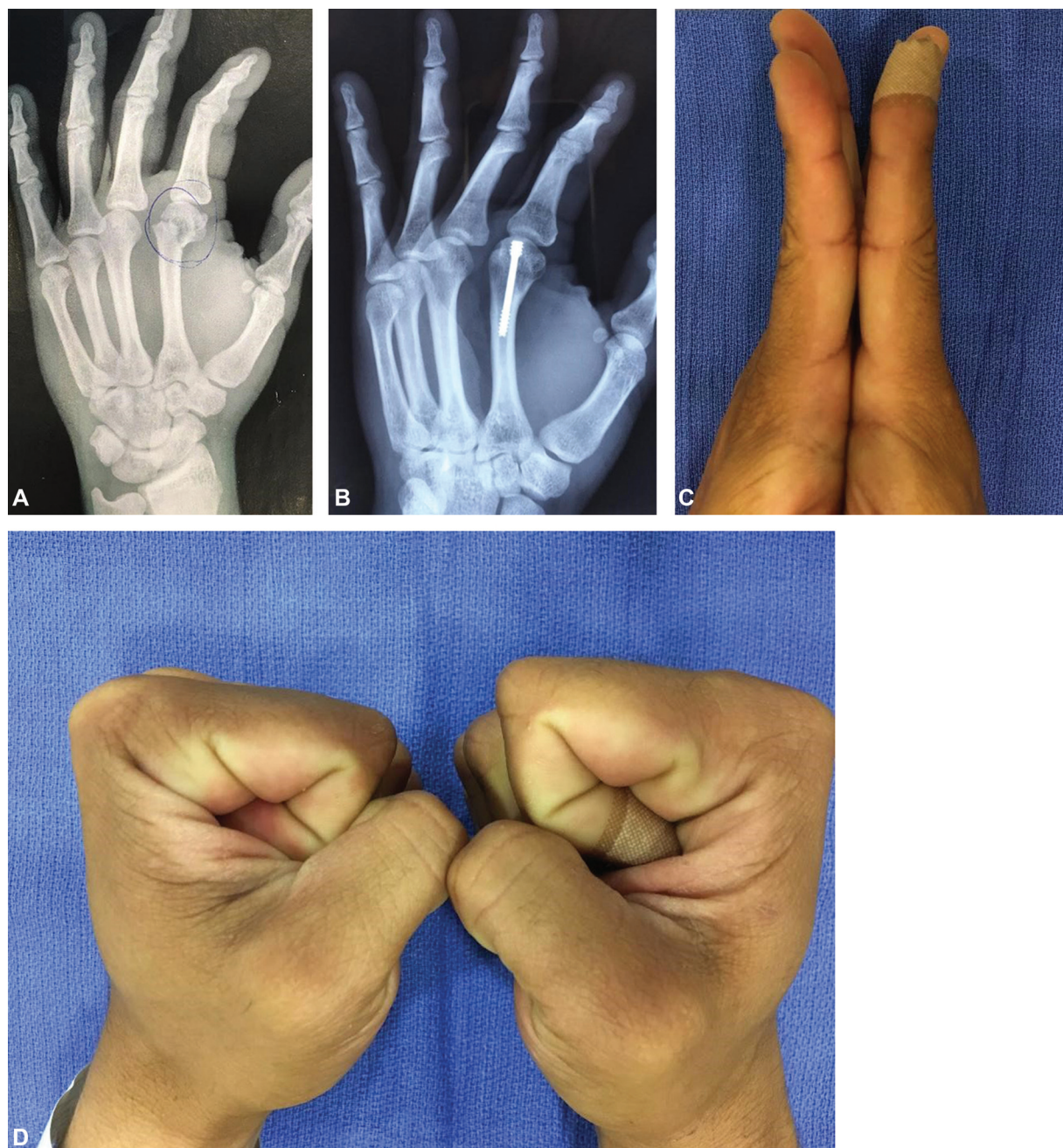
The results of our series of patients are consistent with those in the literature, especially with the work of Del Piñal et al,<sup>8</sup> Ruchelsman et al,<sup>16</sup> Tobert et al,<sup>23</sup> Doarn et al,<sup>24</sup> and Romo-Rodriguez et al,<sup>25</sup> all presenting excellent functional results and no case of pseudoarthrosis or vicious consolidation. More recently, Beck et al reinforced these findings in their review of the literature on the topic.<sup>26</sup> In a patient in our series, a small extensor lag (10°) remained, but this change was not significant in relation to the total range of motion (240°), not preventing an optimal functional result.

This is a technique that violates the articular cartilage of the metacarpal head and is open to criticism. However, a three-dimensional quantitative analysis by computed tomography (CT) performed by ten Berg et al<sup>21</sup> demonstrated that the dorsal entry point of the screw in the metacarpal head is only reached by the base of the proximal phalanx after 87% of the 120° extension arch performed in the sagittal plane. This analysis also shows that the occupied surface area of the metacarpal head and of the subchondral head volume are minimal. A study shows that in the medium term, no changes were found in the metacarpal head with the use of intramedullary devices up to 5 mm in diameter.<sup>27</sup> In addition, it is always worth remembering the already established use of this screw in scaphoid, radial head, capitellum and other articular surfaces. There is no report in the literature of complications due to chondral alteration in the metacarpal head after osteosynthesis with headless intramedullary screw in the short and medium term. Although the current evidence points to a future without chondral changes with the use of this technique, long-term studies are needed to prove it.

Our work has some limitations: it is a retrospective study with a limited number of patients. In addition, the follow-up time for some patients was relatively short, so that definitive conclusions cannot be reached about degenerative joint changes or some other complication that may arise with a longer follow-up. Even so, due to the good results presented here, which reproduce the findings in the literature, this technique confirms to be very effective, safe, and reproducible for metacarpal neck osteosynthesis.

## Conclusion

Retrograde intramedullary osteosynthesis with a headless screw (Herbert type) in fractures of the metacarpal neck has shown excellent radiological and functional results in all patients in this series of 21 cases presented and has proven to be an excellent minimally invasive option for the treatment of these hand fractures.



**Fig. 2** A) Fracture of the neck of the second metacarpal; B) Late postoperative radiography; C) Minimum extensor lag; D) Slight deficit of flexion of the metacarpophalangeal joint.

#### Conflict of Interests

The authors have no conflict of interests to declare.

#### References

- 1 Chung KC, Spilson SV. The frequency and epidemiology of hand and forearm fractures in the United States. *J Hand Surg Am* 2001; 26(05):908–915
- 2 Strub B, Schindele S, Sonderegger J, Sproedt J, von Campe A, Gruenert JG. Intramedullary splinting or conservative treatment for displaced fractures of the little finger metacarpal neck? A prospective study. *J Hand Surg Eur Vol* 2010;35(09):725–729
- 3 Johnson KA. Posterior tibial tendon. In: Weiss AP, Goldfarb CA, Hentz VR, Raven RB, Slutsky DJ, Steinmann SP, Budoff JE, Calfee RP, eds. *Textbook of hand and upper extremity surgery*. Chicago: American Society for the Surgery of the Hand; 2013:76–90
- 4 Creighton JJ Jr, Steichen JB. Complications in phalangeal and metacarpal fracture management. Results of extensor tenolysis. *Hand Clin* 1994;10(01):111–116
- 5 Kollitz KM, Hammert WC, Vedder NB, Huang JI. Metacarpal fractures: treatment and complications. *Hand (N Y)* 2014;9(01):16–23
- 6 Page SM, Stern PJ. Complications and range of motion following plate fixation of metacarpal and phalangeal fractures. *J Hand Surg Am* 1998;23(05):827–832
- 7 Boulton CL, Salzler M, Mudgal CS. Intramedullary cannulated headless screw fixation of a comminuted subcapital metacarpal fracture: case report. *J Hand Surg Am* 2010;35(08):1260–1263

- 8 del Piñal F, Moraleda E, Rúas JS, de Piero GH, Cerezal L. Minimally invasive fixation of fractures of the phalanges and metacarpals with intramedullary cannulated headless compression screws. *J Hand Surg Am* 2015;40(04):692–700
- 9 Ender J, Simon-Weidner R. Die Fixierung der trochanteren Brüche mit runden elastischen Condylennageln. *Acta Chir Austriaca* 1970;2(01):40–42
- 10 Foucher G. “Bouquet” osteosynthesis in metacarpal neck fractures: a series of 66 patients. *J Hand Surg Am* 1995;20(3 Pt 2):S86–S90
- 11 Schädel-Höpfner M, Wild M, Windolf J, Linhart W. Antegrade intramedullary splinting or percutaneous retrograde crossed pinning for displaced neck fractures of the fifth metacarpal? *Arch Orthop Trauma Surg* 2007;127(06):435–440
- 12 Hsu LP, Schwartz EG, Kalainov DM, Chen F, Makowiec RL. Complications of K-wire fixation in procedures involving the hand and wrist. *J Hand Surg Am* 2011;36(04):610–616
- 13 Stahl S, Schwartz O. Complications of K-wire fixation of fractures and dislocations in the hand and wrist. *Arch Orthop Trauma Surg* 2001;121(09):527–530
- 14 Herbert TJ, Fisher WE. Management of the fractured scaphoid using a new bone screw. *J Bone Joint Surg Br* 1984;66(01):114–123
- 15 Geissler WB. Cannulated percutaneous fixation of intra-articular hand fractures. *Hand Clin* 2006;22(03):297–305, vi
- 16 Ruchelsman DE, Puri S, Feinberg-Zadek N, Leibman MI, Belsky MR. Clinical outcomes of limited-open retrograde intramedullary headless screw fixation of metacarpal fractures. *J Hand Surg Am* 2014;39(12):2390–2395
- 17 Jann D, Calcagni M, Giovanoli P, Giesen T. Retrograde fixation of metacarpal fractures with intramedullary cannulated headless compression screws. *Hand Surg Rehabil* 2018;37(02):99–103
- 18 Borbas P, Dreu M, Poggetti A, Calcagni M, Giesen T. Treatment of proximal phalangeal fractures with an antegrade intramedullary screw: a cadaver study. *J Hand Surg Eur Vol* 2016;41(07):683–687
- 19 Avery DM 3rd, Klinge S, Dyrna F, et al. Headless compression screw versus Kirschner wire fixation for metacarpal neck fractures: a biomechanical study. *J Hand Surg Am* 2017;42(05):392.e1–392.e6
- 20 Jones CM, Padegimas EM, Weikert N, Greulich S, Ilyas AM, Siegler S. Headless screw fixation of metacarpal neck fractures: a mechanical comparative analysis. *Hand (N Y)* 2019;14(02):187–192
- 21 ten Berg PW, Mudgal CS, Leibman MI, Belsky MR, Ruchelsman DE. Quantitative 3-dimensional CT analyses of intramedullary headless screw fixation for metacarpal neck fractures. *J Hand Surg Am* 2013;38(02):322–330.e2
- 22 Lalonde D, Eaton C, Amadio P, Jupiter J. Wide-awake hand and wrist surgery: a new horizon in outpatient surgery. *Instr Course Lect* 2015;64:249–259
- 23 Tobert DG, Klausmeyer M, Mudgal CS. Intramedullary Fixation of Metacarpal Fractures Using Headless Compression Screws. *J Hand Microsurg* 2016;8(03):134–139
- 24 Doarn MC, Nydick JA, Williams BD, Garcia MJ. Retrograde headless intramedullary screw fixation for displaced fifth metacarpal neck and shaft fractures: short term results. *Hand (N Y)* 2015;10(02):314–318
- 25 Romo-Rodríguez R, Arroyo-Berezowsky C. Osteosíntesis mínimamente invasiva con tornillos centromedulares canulados para fracturas de metacarpianos. *Acta Ortop Mex* 2017;31(02):75–81
- 26 Beck CM, Horesh E, Taub PJ. Intramedullary screw fixation of metacarpal fractures results in excellent functional outcomes: a literature review. *Plast Reconstr Surg* 2019;143(04):1111–1118
- 27 Evrard H, Nokerman B. [Centromedullary nailing in metacarpal fractures]. *Acta Orthop Belg* 1973;39(06):1035–1044