

# Osteonecrosis of the Intermediate Cuneiform: A Case Report\*

## *Osteonecrose do cuneiforme intermédio: Relato de caso*

Gustavo Araujo Nunes<sup>1,2,3</sup> Matheus Levy Almeida Taveira de Souza<sup>4</sup> Bruno Maciel Braga<sup>5</sup>   
Mateus Martins Marcatti<sup>1,2</sup> Fabrício Melo Bertolini<sup>2</sup> Otaviano de Oliveira Junior<sup>1,2</sup>

<sup>1</sup> Department of Orthopedics, Instituto Orizonti, Belo Horizonte, MG, Brazil

<sup>2</sup> Foot and Ankle Surgery Group, Hospital Universitário Ciências Médicas (FCMMG), Belo Horizonte, MG, Brazil

<sup>3</sup> Department of Orthopedics, Hospital da Baleia, Belo Horizonte, MG, Brazil

<sup>4</sup> Department of Orthopedics, Hospital Mater Dei, Belo Horizonte, MG, Brazil

<sup>5</sup> Department of Orthopedics, Hospital São José, Conselheiro Lafaiete, MG, Brazil

Address for correspondence Gustavo Araujo Nunes, MD, Rua Prof. Otavio Coelho de Magalhaes, 111, Mangabeiras, Belo Horizonte, MG, 30210-300, Brazil (e-mail: gustavoanunes@hotmail.com).

Rev Bras Ortop 2021;56(3):394–398.

### Abstract

Osteonecrosis is a disease that rarely affects the bones of the foot. When present, it is more common in the talus and in the navicular. Cases of osteonecrosis of the intermediate cuneiform are extremely rare, and after a thorough bibliographic review, we found only five reports in the literature, all of them in pediatric patients. Below, we present the case of an adult patient with osteonecrosis of the intermediate cuneiform that was resistant to conservative treatment. Thus, we proposed a surgical approach with good results. *Level of Evidence V; Therapeutic Studies; Expert Opinion.*

### Keywords

- ▶ osteonecrosis
- ▶ cuneiform bones
- ▶ adult

### Resumo

A osteonecrose é uma doença que raramente afeta os ossos do pé. Quando presente, ela é mais comum no tálus e no navicular. Casos de osteonecrose do cuneiforme intermédio são extremamente raros, e após uma revisão bibliográfica minuciosa encontramos apenas cinco relatos na literatura, sendo todos eles em pacientes pediátricos. A seguir, apresentamos o caso de um paciente adulto com osteonecrose do cuneiforme intermédio em resistente ao tratamento conservador. Portanto, propusemos uma abordagem cirúrgica com bom resultado. *Nível de Evidência V; Estudos Terapêuticos; Opinião de Especialista.*

### Palavras-chave

- ▶ osteonecrose
- ▶ ossos cuneiformes
- ▶ adulto

\* Study conducted at the University Hospital of Medical Sciences (FCMMG), Belo Horizonte, MG, Brazil.

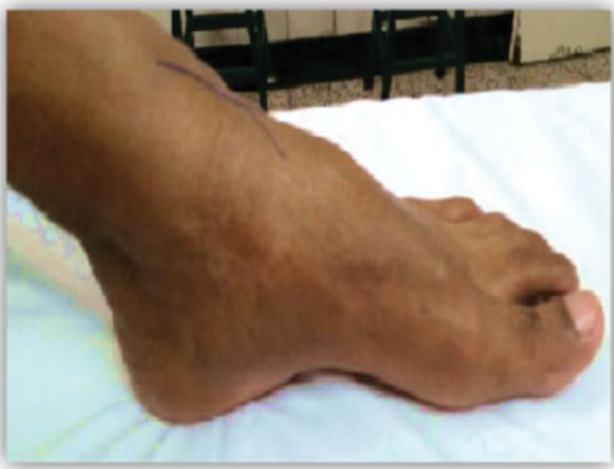received  
March 27, 2020  
accepted  
June 1, 2020  
published online  
September 25, 2020

DOI <https://doi.org/10.1055/s-0040-1715513>.  
ISSN 0102-3616.

© 2021. Sociedade Brasileira de Ortopedia e Traumatologia. All rights reserved.

This is an open access article published by Thieme under the terms of the Creative Commons Attribution-NonDerivative-NonCommercial-License, permitting copying and reproduction so long as the original work is given appropriate credit. Contents may not be used for commercial purposes, or adapted, remixed, transformed or built upon. (<https://creativecommons.org/licenses/by-nc-nd/4.0/>)

Thieme Revinter Publicações Ltda., Rua do Matoso 170, Rio de Janeiro, RJ, CEP 20270-135, Brazil



**Fig. 1** Foot photograph in profile. Edema is noted in the dorsal region of the midfoot associated with an increase in the medial plantar arch. Source: Author's personal archive.

## Introduction

Osteonecrosis, also known as avascular necrosis, is caused by the reduction of blood supply to the bones, which leads to failure of the bone replacement mechanism. If not diagnosed and treated correctly, it can evolve with collapse and joint degeneration.<sup>1</sup> It is not common in the bones of the foot, and, when it occurs, it is more prevalent in the talus and navicular.<sup>1,2</sup> Affection of the intermediate cuneiform is extremely rare, with only five case reports described in the literature,<sup>3</sup> all in pediatric patients.

This pathology usually affects athletes and/or military personnel subject to repetitive microtrauma and stress fractures, or those with rheumatological diseases in chronic use of corticosteroids. Other associated risk factors are radiation therapy, chemotherapy, organ transplantation, and alcohol abuse.<sup>2</sup> The initial treatment is conservative, with non-weight-bearing, use of orthoses, and physical therapy. In cases in which there is no pain relief, surgical intervention is indicated. There are some techniques

reported in the literature, but due to the rarity and scarcity of studies of this pathology in the cuneiform bone, the treatment remains controversial and challenging.<sup>1,2</sup>

The aim of the present article is to report a rare case of osteonecrosis of the intermediate cuneiform bone in an adult patient treated using the surgical approach proposed by the authors.

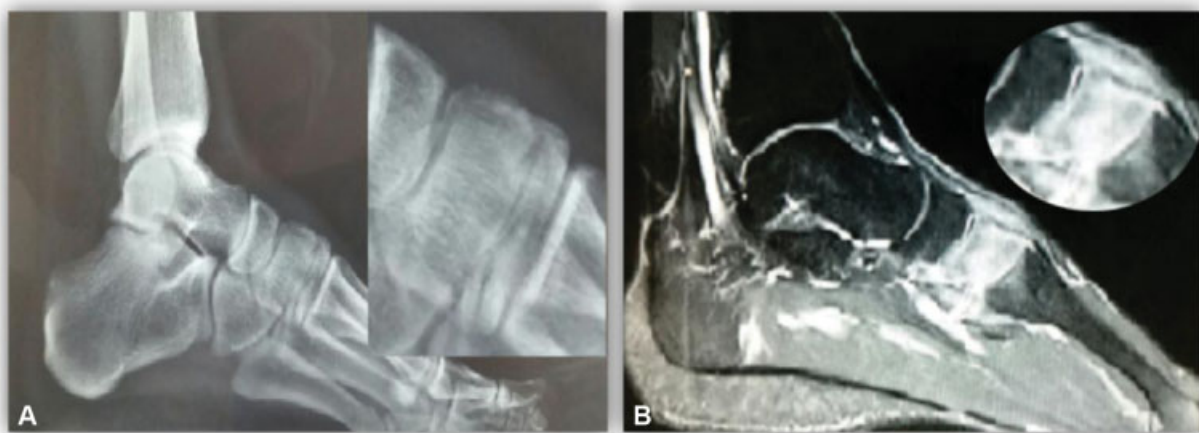
## Case Report

The present work was submitted to the ethics committee with registration at Plataforma Brasil under the CAAE number: 99919318.6.0000.5122.

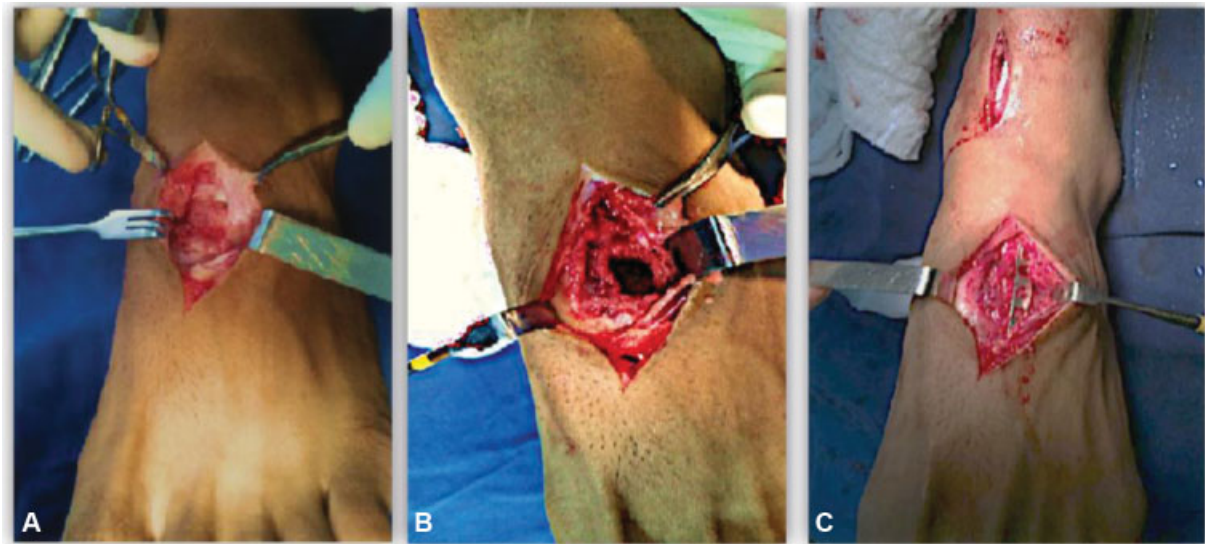
The patient DL, male, 24 years old, military, without comorbidities, presented pain and edema in the dorsal region of the foot, with no history of trauma, associated with limited sports activities, with progressive worsening for approximately 6 months.

On physical examination, a subtle, flexible cavovarus foot was observed that corrected itself in the first stage of the Coleman block test, associated with a shortening of the gastrocnemius muscle demonstrated by the Silverskiold test, in addition to edema and pain on palpation on the midfoot. (► **Figure 1**). There were no signs of ligament instability and associated tendinopathies. On the radiographic examination (► **Figure 2A**), a radiolucent line was noted in the dorsal cortex of the cuneiform bone, the angle formed between the ground and the lower edge of the calcaneus (pitch of the calcaneus) showed a slight increase, with a value of 27°, and a normal angle between the axis of the talus and the first metatarsal (Meary angle). In T2-weighted sequences, the magnetic resonance imaging (MRI) showed diffuse areas with hypersignal (bone edema), associated with vertical lines with hyposignal, suggesting areas of bone necrosis. (► **Figure 2B**).

The patient was initially submitted to conservative treatment performed with non-weight-bearing restrictions and using an orthosis until the pain decreased, followed by physiotherapy rehabilitation and an attempt to gradually return to daily activities. There was no satisfactory evolution



**Fig. 2** (A) Radiographic examination in profile view. A radiolucent line can be seen in the dorsal cortex of the cuneiform. (B) T1-weighted sagittal magnetic resonance imaging demonstrating a mixed pattern of a diffuse hypersignal alternating with areas of hyposignal.



**Fig. 3** (A) Dorsal surgical access to the intermediate cuneiform. Necrotic bone with ill-defined edges is observed. (B) Dorsal bone window followed by bone curettage and resection of devitalized and necrotic tissue. (C) Bone filling with autologous graft fixed with bridge plate. Source: Author's personal archive.

with conservative treatment and due to this, the evolution time, and the findings in the image examination (MRI), surgical treatment was chosen.

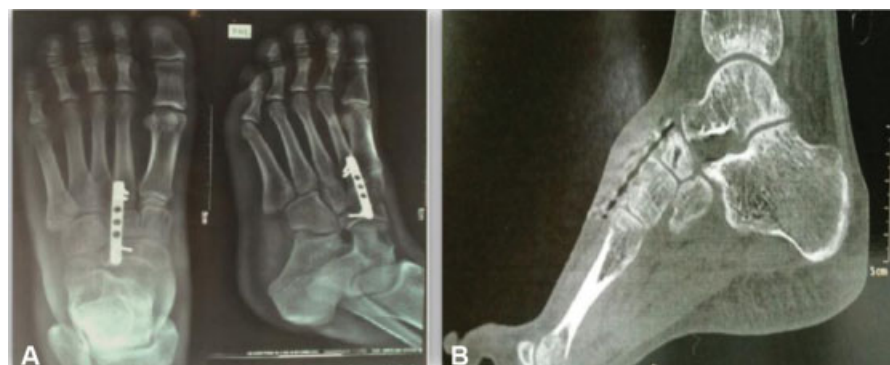The first surgery was performed through dorsal surgical access to the intermediate cuneiform bone, in which we visualized a necrotic bone with an extensive resorption zone, preserving only the joint surfaces. A bone opening was made with a dorsal window, debridement, and curettage, to remove necrotic and devitalized tissue. After this stage, we performed the filling of the medial cuneiform medullary cavity with autologous spongy bone graft, removed from the distal tibia. The cortical bone window removed at the beginning of the procedure was repositioned, and a 2.8-mm bridge plate was fixed (to the navicular and 2<sup>nd</sup> metatarsal bones) in order to stabilize the graft and dissipate forces from the midfoot. The sequence of the surgical technique is demonstrated in ► **Figure 3**. The necrotic and devitalized bone tissue removed from the cuneiform bone was sent for anatomopathological examination, which confirmed the diagnosis of osteonecrosis.

Weight-bearing was not allowed for 8 weeks, followed by 3 months of physical rehabilitation. At that time, the

patient already had significant clinical improvement. During follow-up, control imaging tests showed incorporation of the bone graft into the intermediate cuneiform (► **Figure 4**).

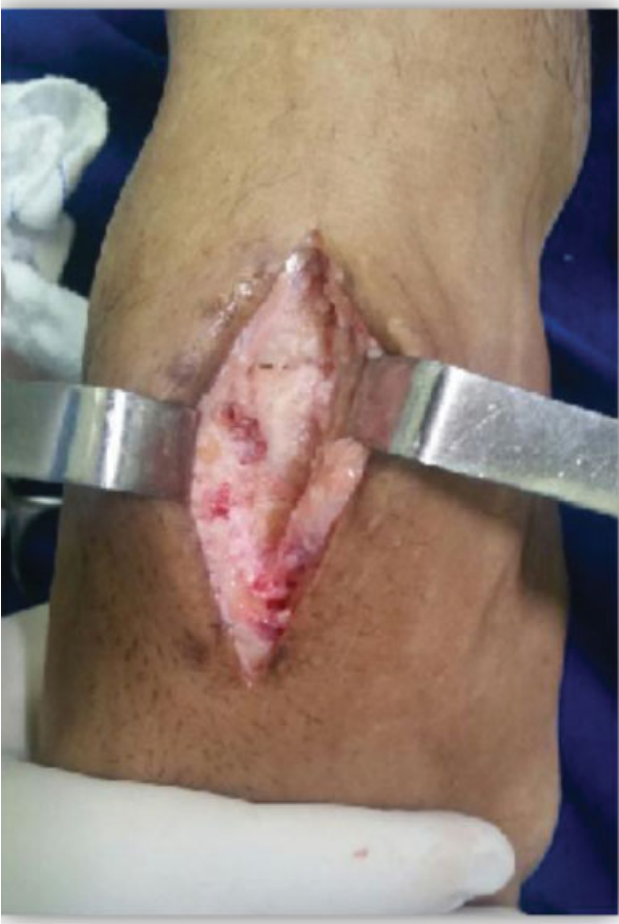After total consolidation, we proceeded to the second treatment period, which occurred 6 months after the first surgery. In this second intervention, the removal of the synthesis material and correction of the subtle cavovarus foot deformity were performed. Through previous dorsal access, the plate was removed, and a biologically viable, stable intermediate cuneiform was visualized with incorporation of the bone graft (► **Figure 5**). After removing the plaque and releasing the joint, we performed the treatment of the subtle cavovarus foot with osteotomy extending the 1<sup>st</sup> metatarsus, releasing the plantar fascia, and stretching the medial gastrocnemius.

The patient showed excellent evolution, underwent physical rehabilitation with return to sports activities without complications. Three months after the second surgery, the patient was already practicing light running and exercises without impact at the gym.



**Fig. 4** Imaging tests performed six months after surgery. We evidenced incorporation of the bone graft. (A) Radiography. (B) Computed tomography.





**Fig. 5** Dorsal view of the midfoot showing the intraoperative appearance of the intermediate cuneiform bone after plaque removal. Source: Author's personal archive.

In the last evaluation, 16 months after the 2<sup>nd</sup> surgery, the patient reported that he performed running and impact activities without limitations or pain complaints. He classified the result as excellent and reports that he would perform the procedure again.

## Discussion

There are different forms of approach for the treatment of osteonecrosis, but most publications address the treatment of necrosis of the femoral head. In the foot and in the ankle joint, the literature makes reference with greater emphasis to the involvement of the talus and the navicular.<sup>1,2</sup> After reviewing the literature, only five articles were found reporting cases of osteonecrosis of the intermediate cuneiform bone in pediatric patients treated conservatively.<sup>3-5</sup> No report of this pathology was found in the national literature.

The treatment of avascular necrosis of the tarsal bones is still controversial and does not have specific protocols, so it is possible to state that the first choice should be conservative with rest, weight-bearing restrictions, orthoses, and physical therapy.<sup>1,2</sup> In several reports of this pathology in other anatomical sites, patients showed clinical improvement with this conduct.<sup>2-4</sup>

Regarding surgical treatment, in the earliest cases without joint degeneration, surgeries that preserve the joint are indicated. This approach can be achieved by some surgical techniques, such as intramedullary bone decompression, performed alone or associated with the use of bone graft that can be vascularized or not. The vascularized bone graft of the cuboid is a surgery described to treat initial cases of talus osteonecrosis with minimal subchondral collapse.<sup>6</sup> Some authors have shown excellent results from patients with talus osteonecrosis treated with this technique.<sup>6</sup> In contrast, Chew et al.<sup>7</sup> showed medial cuneiform osteonecrosis treated only through microperforations with good clinical and radiographic results. Considering the rarity and heterogeneity of this pathology, there are no comparative studies that contemplate a superior technique for the treatment of osteonecrosis in the early stages.<sup>6</sup> What we can actually say is that in advanced cases with joint degeneration, arthrodesis is the ideal procedure that allows the maintenance of bone length and architecture.<sup>3</sup> Although the patient in the study did not present any degenerative signs, it was an advanced osteonecrosis because during the surgical approach, bone involvement of the entire length of the intermediate cuneiform was observed, associated with subchondral involvement, and, because of this, the authors opted for the use of non-vascularized bone graft in large quantity for complete filling of the medullary canal.

Another treatment variant is the way to fix the graft. McLeod et al.<sup>2</sup> showed a case of tibial osteonecrosis in which the lesion was opened with an anterior bone window, curettage, and removal of necrotic tissues, followed by filling with bone graft and fixation with a plate to stabilize the graft. This approach was used in the present study when performing a fixation with a bridge plate, which was fixed to the navicular and the second metatarsal. The authors believe that graft stabilization is essential for a successful treatment. Fixation with a plate, in addition to stabilizing the graft, helps to reduce mechanical stress by dissipating energy in that region, favoring the process of bone reintegration.

Osteonecrosis can be secondary to stress fractures caused by recurrent microtrauma and intrinsic factors represented by muscle deformities and imbalances that alter biomechanics and the load distribution in the lower limbs. In their study, Li et al.<sup>9</sup> observed the relationship between hindfoot alignment and navicular osteonecrosis. They treated 14 feet with necrosis of the navicular only with realignment of the hindfoot, performed through the valgus osteotomy of the calcaneus, without directly addressing the navicular. They observed excellent clinical and radiographic results, reinforcing the relationship of alignment and biomechanical overload that occurs in the midfoot through lower limb deformities.<sup>9</sup> According to Bui-Mansfield et al.,<sup>10</sup> cuneiforms, due to their anatomical location, are susceptible to compression forces, which can be exacerbated by changes in the mechanical axis, muscle imbalances and specifically by pathologies of the plantar fascia. The patient in this study had a subtle cavovarus foot as an intrinsic factor associated with a shortening of the gastrocnemius, and, due to this, after removing the plaque, the cavovarus foot correction was

achieved with the first metatarsal extension osteotomy, plantar fasciotomy, and gastrocnemius elongation. The authors emphasize that the restoration of biomechanics must be a complementary stage of treatment, since it corrects an intrinsic factor related to the genesis of the pathology in question, improving the functional results and reducing the chance of recurrence. Regarding the correction of the deformity, as it is a subtle, flexible cavovarus foot, originating from an increased equinus deformity of the first ray, which was corrected in the first stage of the Coleman blocks, the treatment occurred through an osteotomy of extension of the first metatarsus associated to the soft tissue procedures already described.

The authors present a rare case of osteonecrosis of the intermediate cuneiform in an adult patient treated surgically with decompression and bone grafting temporarily fixed with a bridge plate, followed by realignment of the mechanical axis, with excellent clinical result.

#### Financial Support

There was no financial support from public, commercial, or non-profit sources.

#### Conflicts of Interest

The authors declare that there are no conflicts of interest.

## References

- 1 DiGiovanni CW, Patel A, Calfee R, Nickisch F. Osteonecrosis in the foot. *J Am Acad Orthop Surg* 2007;15(04):208–217
- 2 McLeod JM, Ng A, Kruse DL, Stone PA. Nontraumatic Osteonecrosis of the Distal Tibia: A Case Presentation and Review of the Literature. *J Foot Ankle Surg* 2017;56(01):158–166
- 3 García-Mata S. Avascular necrosis of the intermediate cuneiform bone in a child: a very rare cause of limp in a child. A variant of the normality? *J Pediatr Orthop B* 2013;22(03):255–258
- 4 Kose O, Demiralp B, Oto M, Sehrioglu A. An unusual cause of foot pain in a child: osteochondrosis of the intermediate cuneiform. *J Foot Ankle Surg* 2009;48(04):474–476
- 5 Watmough PJ, Tselentakis G, Day JB. Avascular necrosis of the intermediate cuneiform bone. *J Pediatr Orthop B* 2003;12(06):402–405
- 6 Cody EA, Nunley JA. Vascularized Pedicle Graft for Talar Osteonecrosis. *Foot Ankle Clin* 2019;24(01):121–129
- 7 Chew JT, Low CK, Mitra AK. A case report on bilateral avascular necrosis of the medial cuneiforms. *Ann Acad Med Singapore* 1995;24(03):453–454
- 8 Gangji V, De Maertelaer V, Hauzeur JP. Autologous bone marrow cell implantation in the treatment of non-traumatic osteonecrosis of the femoral head: Five year follow-up of a prospective controlled study. *Bone* 2011;49(05):1005–1009
- 9 Li SY, Myerson MS, Monteagudo M, Maceira E. Efficacy of Calcaneus Osteotomy for Treatment of Symptomatic Müller-Weiss Disease. *Foot Ankle Int* 2017;38(03):261–269
- 10 Bui-Mansfield LT, Thomas WR. Magnetic resonance imaging of stress injury of the cuneiform bones in patients with plantar fasciitis. *J Comput Assist Tomogr* 2009;33(04):593–596