

# Radiographic Study in Patients Submitted to Cementless Total Knee Arthroplasties: Minimum Follow-Up of 2 Years\*

## *Estudo radiográfico em pacientes submetidos à artroplastia total de joelho não cimentada: Segmento mínimo de 2 anos*

Sérgio Mainine<sup>1</sup> José Antônio Marinho<sup>1</sup> Bruna Gabriela Passarini de Oliveira<sup>2</sup>  
 Enrico Montorsi Zanon<sup>1</sup> Bruno Machado Pereira<sup>1</sup> Rafael Fonseca Rodrigues de Souza<sup>1</sup>

<sup>1</sup>Knee Surgery Group, Instituto de Fraturas, Ortopedia e Reabilitação (IFOR), São Bernardo do Campo, SP, Brazil

<sup>2</sup>Instituto de Fraturas, Ortopedia e Reabilitação (IFOR), São Bernardo do Campo, SP, Brazil

Address for correspondence Sergio Mainine, Chefe de Equipe da Cirurgia do Joelho, Rua Bela Vista, 426. São Bernardo do Campo, SP, Brazil. CEP 09715-030 (e-mail: sergiomainine@gmail.com).

Rev Bras Ortop 2021;56(5):628–633.

### Abstract

**Objective** Radiographic evaluate if there are signs of early loosening of the cementless total knee arthroplasties Amplitude-Score® (Amplitude Surgical SAS, Valence, France), checking with a follow-up time ranging from 2 to 5.75 years (mean of 3.75 years).

**Methods** Descriptive longitudinal investigation of observational nature, non-comparative, through a static radiographic study of annual control, of a case series, in a single center, all operated on by the same surgeon (S.M.). All cementless arthroplasties that met the inclusion and exclusion criteria performed from March 2012 to October 2014 were included.

**Results** Among the 46 cementless knee arthroplasties evaluated in 40 patients, no radiographic signs of early loosening were verified.

**Conclusion** Cementless arthroplasty promotes optimal osteointegration, with no early release, and it is essential that the surgical technique is perfectly respected.

### Keywords

- ▶ arthroplasty, replacement, knee
- ▶ arthrosis
- ▶ knee prosthesis
- ▶ cementation

\* Study carried out at the Knee Surgery Service of the Instituto de Fraturas, Ortopedia e Reabilitação (IFOR), São Bernardo do Campo, SP, Brazil.

received  
 April 3, 2020  
 accepted after revision  
 December 1, 2020

DOI <https://doi.org/10.1055/s-0041-1731355>.  
 ISSN 0102-3616.

© 2021. Sociedade Brasileira de Ortopedia e Traumatologia. All rights reserved.

This is an open access article published by Thieme under the terms of the Creative Commons Attribution-NonDerivative-NonCommercial-License, permitting copying and reproduction so long as the original work is given appropriate credit. Contents may not be used for commercial purposes, or adapted, remixed, transformed or built upon. (<https://creativecommons.org/licenses/by-nc-nd/4.0/>)

Thieme Revinter Publicações Ltda., Rua do Matoso 170, Rio de Janeiro, RJ, CEP 20270-135, Brazil

**Resumo**

**Objetivo** Avaliar radiograficamente a existência de sinais de soltura precoce das artroplastias totais de joelho não cimentadas Score (Amplitude Surgical SAS, Valence, France), verificadas com um tempo de seguimento que variou de 2 a 5,75 anos (média de 3,75 anos).

**Métodos** Investigação longitudinal descritiva de caráter observacional, não comparativa, realizada através de estudo radiográfico estático de controle anual, de uma série de casos, em um único centro, todos operados pelo mesmo cirurgião (S.M.). Foram incluídas todas as artroplastias não cimentadas que se enquadraram nos critérios de inclusão e exclusão realizadas no período de março de 2012 a outubro de 2014.

**Resultados** Dentre as 46 artroplastias de joelho não cimentadas avaliadas em 40 pacientes, não foram verificados sinais radiográficos de soltura precoce.

**Conclusão** A artroplastia não cimentada promove ótima osteointegração, não havendo soltura precoce, sendo fundamental que a técnica cirúrgica seja perfeitamente respeitada.

**Palavras-chave**

- ▶ artroplastia do joelho
- ▶ artrose
- ▶ prótese do joelho
- ▶ cimentação

**Introduction**

Osteoarthritis (OA) is a degenerative joint disease that evolves with chronic inflammatory process, causing joint degeneration. It is characterized by pain, morning stiffness, crackling, muscular atrophy and, regarding radiographic aspects, narrowing of joint space, formations of osteophytes, sclerosis of the subcondral bone, and cystic formations are observed.<sup>1</sup>

The etiology may be idiopathic or posttraumatic. Posttraumatic etiology can affect patients of any age. Idiopathic etiology, with strong genetic indications, mainly affects older individuals, although it also occurs in middle-aged adults, especially women between the 5th and 6th decades of life and in the postmenopausal period. It is interesting that presentation in patients younger than 40 years of age is practically the same in both genders. It is estimated that the majority of the population over 65 years of age will suffer from some degree of OA, which is, in aging, the main cause of functional disability when compared to any other disease. And in this age group, about 50% of the individuals will have arthritis of the knee.<sup>1,2</sup>

In the failure of conservative treatment, total knee arthroplasty (TKA) has been well established in restoring function, relieving pain, and correcting deformities and instabilities, becoming an option even for younger patients with severe knee arthritis.<sup>1</sup>

The annual rates of TKA are increasing progressively due to the longevity of the population, tied to the fact that surgeries have been performed in increasingly younger patients. A major study showed that TKA reviews in the United States doubled in 2015 and will increase by 600% by the year 2030.<sup>2</sup>

Younger patients, with longer life expectancy, increased activity and implant requirement, require safe fixation to ensure component longevity and reduction of revisions. However, the use of cemented fixation has been reexamined, although it demonstrates excellent results.<sup>3,4</sup>

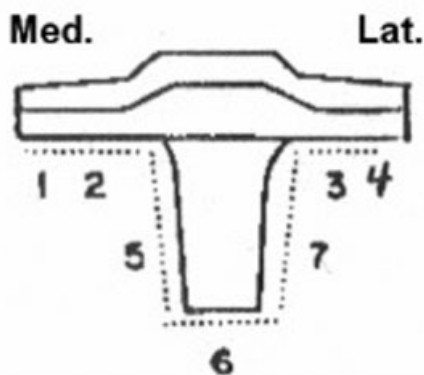
The optimal fixation of a TKA is still debated. The main question is whether the use of cement is more efficient than

press-fit fixation in terms of ensuring durable stability. The use of cement in TKA has been associated with excellent clinical results and low aseptic loosening rates in the long term of follow-up, being the most common method of fixation. However, changes in the cement-bone interface, considered a critical zone of stress and loosening, encouraged the search for new methods of fixation of the components.<sup>5-8</sup>

The potential benefits of uncemented fixation include bone preservation, shorter surgery time, ease of review and elimination of complications associated with cemented fixation, including wear and retention of loose cement fragments, extrusion of the bone, biological response to polymethylmethacrylate, deep vein thrombosis, shock, and thermal necrosis due to its polymerization. Finally, reviews of cemented arthroplasties are technically more complicated in relation to cementless implants, particularly due to frequent bone loss after removal of components and residual cement.<sup>9-11</sup>

Cemented fixation is known to provide good initial fixation and not migrate in the immediate postoperative period, although it may present micromovement in 60 months. The cementless interface may migrate earlier, that is, in the first 3 months postoperatively, usually reaching stability after this interval; however, after osteointegration between bone and metal, there is formation of a biological bond that tends to provide better long-term results.<sup>12,13</sup> Early tibial loosening is still the main problem pointed out by critics of the technique without cement.

The main parameter to evaluate the loosening of arthroplasty components is the presence of radiolucency lines on postoperative radiographs, located on the periphery of the components described by The Knee Society<sup>14</sup> (► **Figures 1 and 2**). Radiolucency showing more than 1 mm in increased width in the evolution and migration of components is significant. Radiolucency lines may be present from the immediate postoperative period and will only become a concern when their pattern changes throughout the



**Fig. 1** Zones around the prosthesis components where radiolucency should be observed in the tibial component. 1 and 2 - medial plateau; 3 and 4 - lateral plateau; 5, 6 and 7 - around the nail.

follow-up, which may mean the loosening of the components and the need for revision arthroplasty.

Thus, in the present study, the objective was to evaluate, in the short term, whether there was early release of components of the Score cementless knee prosthesis (Amplitude Surgical SAS, Valence, France).

### Casist and Method

The study was submitted for evaluation by the research ethics committee of this institution and approved for execution according to the *certificado de apresentação de apreciação ética* (CAAE) number - 27786119.2.0000.5625, opinion: 3,814,869.

This is a descriptive, longitudinal, observational study, non-comparative, case series, in a single center, all operated by the same surgeon (S. M.), evaluating early release of the components of cementless prostheses through a static radiographic study of annual control.

Inclusion criteria were:

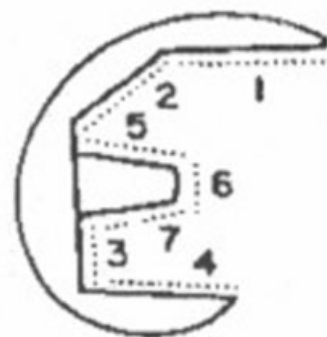
- Total cementless arthroplasty;
- Body mass index (BMI) < 35 kg/m<sup>2</sup>;
- Minimum postoperative follow-up time of 2 years;
- Patients must have read and signed the free and informed consent form (formulated in accordance with the recommendations of Resolution No. 466 of December 12, 2012 of the National Health Council), stating that they understood all the explanations and fully agreed with the research.

Excluding patients:

- Who had arthroplasty prior to this surgery;
- Metabolic and rheumatological diseases;
- Infection or active malignancy.

All cementless arthroplasties that met the inclusion and exclusion criteria performed from March 2012 to October 2014 were included.

All surgeries were performed through medial parapatellar access route, sacrificing the posterior cruciate ligament using the Score cementless total knee prosthesis with rotational



**Fig. 2** Zones around the prosthesis components where radiolucency should be observed in the femoral component. 1 and 2 - anterior region; 3 and 4 - posterior area; 5, 6 and 7 - stem and central part.

platform, with ultra-congruous stabilization, in which the femoral and tibial components are chromium-cobalt with double titanium coating and 80 micrometers of hydroxyapatite porous coating. The patellar component of polyethylene, in dome, with three fixation pins, cemented, was not used in only two patients, three knees. A vacuum drain was placed in all cases, being removed when the flow was lower than 50 mL in 24 hours, not exceeding 48 hours, regardless of the flow.

The patients were discharged from the hospital on the 3<sup>rd</sup> postoperative day, with full load allowed with the aid of a walker for balance and initiating outpatient physiotherapy to gain range of motion. They were evaluated at 1, 3, 6 and 12 and 24 weeks. After this initial phase, they had outpatient return every 6 months until 1 year, when routine radiographic control was performed.

The radiographs of the operated knee, in the orthostatic front position and in absolute profile with 30 degrees of flexion, were analyzed by two surgeons with experience in arthroplasty, blind to each other, with emphasis on the pattern of possible radiolucency lines in the femur and tibia, using the parameters of The Knee Society for evaluation of implants and progression of radiolucency<sup>15</sup> (►Table 1; ►Figures 1 and 2).

### Results

Forty-six cementless arthroplasties with the rotational platform Score were evaluated in 40 patients (6 bilateral), having been performed from March 2012 to October 2014. The characteristics of this population are presented in ►Table 2.

In the analysis of the radiographs, we did not find radiolucency lines around the femur. In the tibial component

**Table 1** Interpretation of images on radiographs

Radiolucency line	Interpretation
≤ 0.4 mm	Normal
From 0.5–0.9 mm	Track every 3 months if there is progression
≥ 1 mm	Possible or imminent failure

**Table 2** Distribution of the studied population

	Age (years)	Sex	Side	Follow-up time
40 patients	Low: 46.9	F: 30	R: 26	Minimum: 2 years
46 arthroplasties	Maximum: 83.0	M: 10	L: 20	Maximum: 5.75 years
(6 bilateral)	Average: 60.8			Average: 3.75 years

Abbreviations: F, female; L, left; M, male; R, right.

**Table 3** Results of the analysis of radiographs performed at the last visit of patients

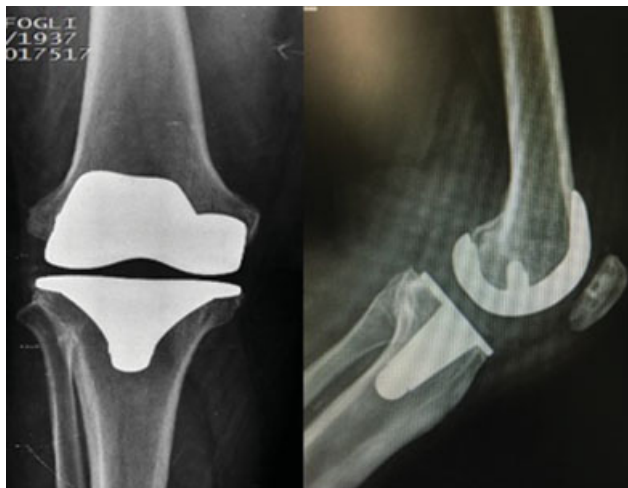
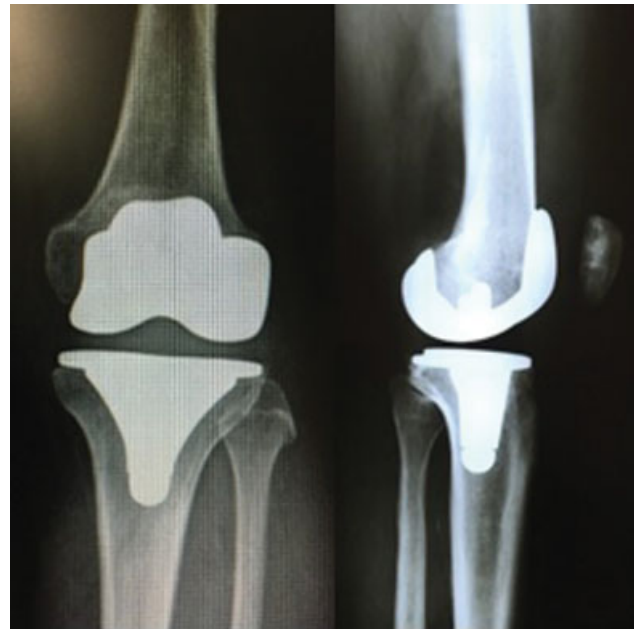	Radiolucency lines (AP)	Radiolucency lines (P)	Total
Femur	0	0	0
Tibia	5 (10.8%)	1 (2.2%)	6 (13.0%)

Abbreviations: AP, anteroposterior; P, profile.

analysis, radiolucency lines were observed in 6 (13.0%) arthroplasties, 5 of which (10.8%) were in anteroposterior view (AP) and 1 (2.2%) in profile view (P), occurring mainly in zones 1 and 4, with an average thickness of 1 mm, present from the beginning and non-progressive (► **Table 3**, ► **Figures 1–3**).

Therefore, no case presented suspicion of loosening or instability of the components, and no revision arthroplasty due to mechanical failure was performed.

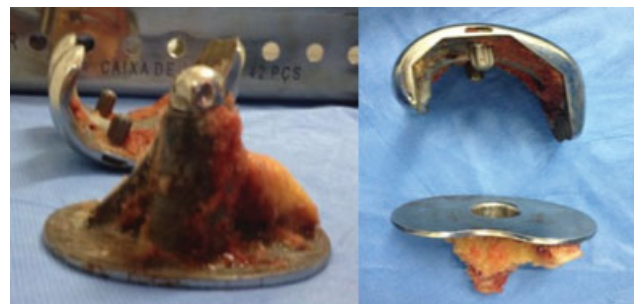There was a need for a prosthesis review, after 7 months, in a patient with heart valve using oral anticoagulant and uncontrolled coagulation, evolving with repeated hemarthroses and hematogenous infection, because at no time was joint puncture performed. After failure to clean and preserve the implant, it was decided to remove it, when an optimal osteointegration of the femoral and tibial components was observed, and they were, therefore, fixed (► **Figures 4 and 5**).

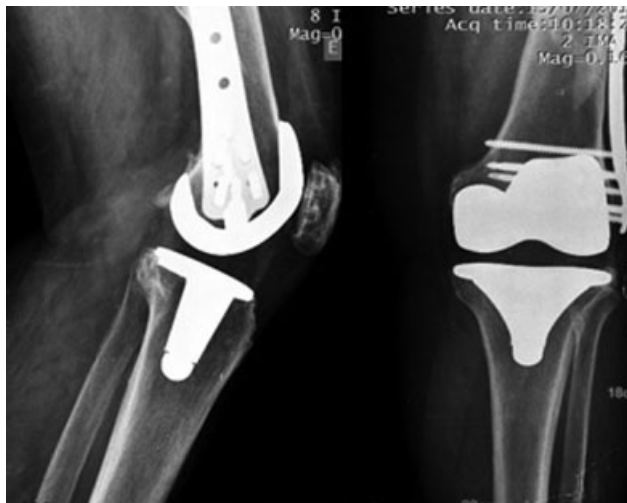**Fig. 3** Radiographs showing total knee prosthesis without cementation and without radiolucent lines around the components.**Fig. 4** Components of the patient n°20's prosthesis removed due to infection. Bone integration is observed in the porous surfaces of the prosthesis.

Another patient, 3 years postoperative, suffered trauma with periprosthetic femoral fracture and underwent reduction and internal fixation with blocked plate, maintaining component fixation and good evolution (► **Figure 6**).

## Discussion

The study of cement-free fixation in knee arthroplasty began to be used in the mid-1980s after laboratory studies showed that bone growth for the stability of the implant-bone interface interferes with the durability of the fixed component.<sup>16,17</sup>

**Fig. 5** Radiography of patient no. 22, demonstrating total prosthesis of the left knee and osteosynthesis in the ipsilateral femur.



**Fig. 6** This demonstrates a slight line of radiolucency around the tibial component of the prosthesis, which was not progressive; therefore, it does not constitute a case of implant loosening.

In studies that analyzed the migration of implants without cement, it was demonstrated that there was some degree of migration of the components in the first 6 months until osteointegration and occurrence of its stabilization. Cemented implants present lower initial migration, but it is constant over 5 years.<sup>12</sup>

The presence of radiolucency around the implant without cement does not necessarily mean the loosening of the component (► **Figure 6**), possibly due to the initial migration of the implants,<sup>13</sup> or even radiolucency in a region of eburnean bone present before surgery, which happens both in cemented and cementless prosthesis.<sup>18</sup>

There are numerous parameters for evaluation and quantification of radiolucency lines and loosening of arthroplasty components. Currently, the most commonly used is the classification of The Knee Society based on frontal and profile radiographs of the knee, in which the radiolucency lines are quantified according to their location around the tibial and femoral components.<sup>14</sup> Generally, this evaluation is performed by experienced surgeons who determine whether the components are stable or unstable. Studies with radiostereography or dynamic radiographs may sensitize the diagnosis of instability and loosening of prosthesis components.<sup>10,11,13,15,19,20</sup>

In the literature, there is an average of 1.4 mm of radiolucency in the femur, especially in segments 1 and 2, in long-term follow-ups. We did not observe these lines in the femur in our cases evaluated in a short postoperative period. In the tibia, the literature shows these radiolucent lines of 1.4 mm mainly in zones 1 and 4, that is, in the medial and lateral periphery of the implant, in a mean follow-up of 10 years. A similar result was found in our series, and we obtained an average of 1 mm in the same locations.

Over decades, *in vitro* studies have shown that the use of rotational platforms in cementless TKAs are associated with better physiological performance and implant survival, as well as with reduced tensions at the bone-metal interface. Several studies in the clinical setting have also shown long-

term survival of press-fit with rotating platforms, increasing from 83 to 99.4%.<sup>21</sup> In our series, we used the Score cementless prosthesis with rotational platform in all cases. We have no experience to compare it with cement-free prostheses with fixed platform.

It is essential for adequate osteointegration that the bone cuts are very precise, and the test prosthesis presents a great press-fit. If this does not occur, it is better to change the planning and put the cemented prosthesis. That is why it is important to have both types of implants in the operating room.

Finally, another important point for good results in arthroplasties without cement is the bioactive coating of the components, especially the tibial component, thus providing less migration. Radiostereographic analysis studies have shown different results when evaluating cementless tibia components coated with hydroxyapatite compared to cemented tibial components.<sup>10</sup> In a prospective study of young and active patients, Tai and Cross evaluated 118 knees with non-cement implants coated with hydroxyapatite (Active; DJ Ortho, Sydney, Australia) for a period of 5 to 12 years.<sup>16</sup> Two revisions of the tibia by aseptic loosening and exchange of a polyethylene were performed. The cumulative survival rate was 92.1% (including polyethylene exchange).<sup>14</sup>

Although cementless knee arthroplasty was developed for young people with higher level of physical activity, recent studies have shown similar results regarding the survival of this type of implant in the population over 75 years of age.<sup>22</sup> And in morbidly obese patients, the results were better than those of surgeries with cemented implants.<sup>23</sup>

Therefore, it is necessary to further investigate this line of arthroplasties, which may be a trend in knee prostheses, especially in young, active patients with high demand, with the possibility of extending this indication in the near future.

## Conclusion

Nevertheless, the current generation of cementless implants presents excellent results not only in relation to the press-fit, but also in providing initial stability to the components and allowing a more biological implant-bone interface.

Despite the limitations of our study, the short follow-up, non-randomization of the sample, and the fact that a single surgeon performed all the surgeries, the relevant point evidenced in the study was the absence of loosening of the prostheses in the follow-up period.

### Financial Support

There was no financial support from public, commercial, or non-profit sources.

### Conflict of Interests

The authors declare that there is no conflict of interests.

## References

- 1 Silva PMGO. Prótese total do joelho – a história da arte: revisão bibliográfica [dissertação]. Covilhã: Universidade da Beira Interior; 2010



- 2 Kurtz S, Ong K, Lau E, Mowat F, Halpern M. Projections of primary and revision hip and knee arthroplasty in the United States from 2005 to 2030. *J Bone Joint Surg Am* 2007;89(04):780–785
- 3 Harwin SF, Elmallah RK, Jauregui JJ, Cherian JJ, Mont MA. Outcomes of a newer-generation cementless total knee arthroplasty design. *Orthopedics* 2015;38(10):620–624
- 4 Harwin SF, Kester MA, Malkani AL, Manley MT. Excellent fixation achieved with cementless posteriorly stabilized total knee arthroplasty. *J Arthroplasty* 2013;28(01):7–13
- 5 Lombardi AV Jr, Berasi CC Jr, Berend KR. Evolution of tibial fixation in total knee arthroplasty. *J Arthroplasty* 2007;22(04, Suppl 1):25–29
- 6 Naudie DD, Ammeen DJ, Engh GA, Rorabeck CH. Wear and osteolysis around total knee arthroplasty. *J Am Acad Orthop Surg* 2007;15(01):53–64
- 7 O'Rourke MR, Callaghan JJ, Goetz DD, Sullivan PM, Johnston RC. Osteolysis associated with a cemented modular posterior-cruciate-substituting total knee design : five to eight-year follow-up. *J Bone Joint Surg Am* 2002;84(08):1362–1371
- 8 Noble PC, Conditt MA, Thompson MT, et al. Extraarticular abrasive wear in cemented and cementless total knee arthroplasty. *Clin Orthop Relat Res* 2003;(416):120–128
- 9 Bert JM, McShane M. Is it necessary to cement the tibial stem in cemented total knee arthroplasty? *Clin Orthop Relat Res* 1998;(356):73–78
- 10 Clarke MT, Green JS, Harper WM, Gregg PJ. Cement as a risk factor for deep-vein thrombosis. Comparison of cemented TKR, uncemented TKR and cemented THR. *J Bone Joint Surg Br* 1998;80(04):611–613
- 11 Nilsson KG, Kärrholm J, Carlsson L, Dalén T. Hydroxyapatite coating versus cemented fixation of the tibial component in total knee arthroplasty: prospective randomized comparison of hydroxyapatite-coated and cemented tibial components with 5-year follow-up using radiostereometry. *J Arthroplasty* 1999;14(01):9–20
- 12 Gao F, Henricson A, Nilsson KG. Cemented versus uncemented fixation of the femoral component of the NexGen CR total knee replacement in patients younger than 60 years: a prospective randomised controlled RSA study. *Knee* 2009;16(03):200–206
- 13 Nakama GY, Peccin MS, Almeida GJ, Lira Neto OdeA, Queiroz AA, Navarro RD. Cemented, cementless or hybrid fixation options in total knee arthroplasty for osteoarthritis and other non-traumatic diseases. *Cochrane Database Syst Rev* 2012;10(10):CD006193
- 14 Aebli N, Krebs J, Schwenke D, Hii T, Wehrli U. Progression of radiolucent lines in cementless twin-bearing low-contact-stress knee prostheses: a retrospective study. *J Arthroplasty* 2004;19(06):783–789
- 15 Ewald FC. The Knee Society total knee arthroplasty roentgenographic evaluation and scoring system. *Clin Orthop Relat Res* 1989;(248):9–12
- 16 Tai CC, Cross MJ. Five- to 12-year follow-up of a hydroxyapatite-coated, cementless total knee replacement in young, active patients. *J Bone Joint Surg Br* 2006;88(09):1158–1163
- 17 Hungerford DS, Kenna RV, Krackow KA. The porous-coated anatomic total knee. *Orthop Clin North Am* 1982;13(01):103–122
- 18 Rorabeck CH, Bourne RB, Lewis PL, Nott L. The Miller-Galante knee prosthesis for the treatment of osteoarthrosis. A comparison of the results of partial fixation with cement and fixation without any cement. *J Bone Joint Surg Am* 1993;75(03):402–408
- 19 Regnér L, Carlsson L, Kärrholm J, Herberts P. Ceramic coating improves tibial component fixation in total knee arthroplasty. *J Arthroplasty* 1998;13(08):882–889
- 20 Tírigo LEP, Pasqualin T, Pécora JO, Gobbi RG, Pécora JR, Demange MK. Study on implant stability in cementless total knee arthroplasty. *Acta Ortop Bras* 2012;20(04):230–234
- 21 Brown TE, Harper BL, Bjorgul K. Comparison of cemented and uncemented fixation in total knee arthroplasty. *Orthopedics* 2013;36(05):380–387
- 22 Bagsby DT, Issa K, Smith LS, et al. Cemented vs Cementless Total Knee Arthroplasty in Morbidly Obese Patients. *J Arthroplasty* 2016;31(08):1727–1731
- 23 Stähelin T, Kessler O, Pfirrmann C, Jacob HA, Romero J. Fluoroscopically assisted stress radiography for varus-valgus stability assessment in flexion after total knee arthroplasty. *J Arthroplasty* 2003;18(04):513–515