







# Evaluation of the Glenoid Track Tomographic Method in Magnetic Resonance Imaging/Arthro-MRI

## *A avaliação do método tomográfico glenoid track na ressonância magnética/artro RM*

Andre Couto Godinho<sup>1</sup> Pedro Couto Godinho<sup>1</sup> Flávio de Oliveira França<sup>2</sup>  
Elísio José Salgado Ribeiro<sup>3</sup> Daniel Carvalho de Toledo<sup>2</sup> Guilherme Henrique Franco<sup>2</sup>

<sup>1</sup>Hospital Ortopédico, Belo Horizonte, MG, Brazil

<sup>2</sup>Ortopédico BH, Belo Horizonte, MG, Brazil

<sup>3</sup>Axial Medicina Diagnóstica, Belo Horizonte, MG, Brazil

**Address for correspondence** Daniel Carvalho de Toledo, MD, Ortopédico BH, Belo Horizonte, Minas Gerais, Brazil (e-mail: danieltoledo@me.com).

Rev Bras Ortop 2021;56(6):733–740.

### Abstract

**Objective** To evaluate and compare the glenoid track method in 3D-reconstructed computed tomography (3D-CT) scans with magnetic resonance imaging (MRI) and/or arthro-MRI.

**Methods** Forty-four shoulders with clinical and radiographic diagnosis of traumatic anterior instability were assessed using 3D-CT, MRI, and/or arthro-MRI scans. Glenoid track (GT), Hill-Sachs interval (HSI), and glenoid bone loss (GBL) were determined by a radiologist using 3D-CT images, and classified as on-track/off-track. Three surgeons, blinded to the radiologist's evaluation, performed the same determinations using MRI/arthro-MRI. Descriptive analysis, variance analysis, results disagreement analysis, and receiver operating characteristic (ROC) curves were performed.

**Results** Results from the 4 examiners were fully consistent in 61.4% of the cases. Magnetic resonance imaging/arthro-MRI diagnosed off-track injuries with 35 to 65% sensitivity and on-track injuries, with 91.67 to 95.83% specificity. Accuracy ranged from 68.1 to 79.5%. The greatest data divergence occurred for off-track injuries diagnosed by MRI/arthro-MRI. The greatest data variability referred to HSI calculation. Higher HSI and GBL values were associated with greater disagreement among examiners. Hill-Sachs interval values were lower at MRI/arthro-MRI when compared to 3D-CT. Agreement between CT and MRI/arthro-MRI for the GT method was only moderate (kappa value, 0.325–0.579).

**Conclusion** Magnetic resonance imaging/arthro-MRI showed low accuracy and moderate agreement for the GT method; as such, it should be used with caution by surgeons.

### Keywords

- ▶ glenoid cavity
- ▶ anterior shoulder instability
- ▶ shoulder dislocation

received  
December 9, 2019  
accepted  
July 6, 2020  
published online  
October 29, 2020

DOI <https://doi.org/10.1055/s-0040-1716766>.  
ISSN 0102-3616.

© 2020. Sociedade Brasileira de Ortopedia e Traumatologia. All rights reserved.

This is an open access article published by Thieme under the terms of the Creative Commons Attribution-NonDerivative-NonCommercial-License, permitting copying and reproduction so long as the original work is given appropriate credit. Contents may not be used for commercial purposes, or adapted, remixed, transformed or built upon. (<https://creativecommons.org/licenses/by-nc-nd/4.0/>)

Thieme Revinter Publicações Ltda., Rua do Matoso 170, Rio de Janeiro, RJ, CEP 20270-135, Brazil

## Resumo

**Objetivo** Comparar a avaliação do método *glenoid-track* (GT) em exames de tomografia computadorizada com reconstrução 3-D (TC-3D) com a avaliação realizada em exames de ressonância magnética (RM) e/ou arthro-ressonância magnética (ARM).

**Métodos** Quarenta e quatro ombros com diagnóstico clínico e radiográfico de instabilidade anterior traumática foram avaliados por meio de exames de TC-3D, RM e/ou ARM. As variáveis GT, intervalo de Hill-Sachs (IHS) e a perda óssea da glenoide (POG) foram realizadas por um médico radiologista, utilizando imagens de TC-3D, e classificadas em *on-track/off-track*. Três cirurgiões cegos à avaliação do radiologista realizaram o mesmo método utilizando RM/ARM. O estudo realizou análise descritiva, de variância, de associação da discordância de resultados, de concordância e curva característica de operação do receptor.

**Resultados** Os resultados dos 4 examinadores foram totalmente concordantes em 61,4%. A RM/ARM diagnosticou lesões *off-track* com a sensibilidade variando de 35 a 65%, e lesões *on-track* com a especificidade variando de 91,67 a 95,83%. A acurácia variou de 68,1 a 79,5%. A maior divergência de dados ocorreu para o diagnóstico por RM/ARM de lesões *off-track*. A maior variabilidade dos dados ocorreu para o cálculo do IHS. Valores maiores de IHS e de POG foram associados a maior discordância entre os examinadores. A RM/ARM apresentou menor medida de valores de IHS quando comparado com a TC-3D. Ocorreu apenas moderada concordância no método GT entre a TC e a RM/ARM (Kappa 0,325–0,579).

**Conclusão** A RM/ARM apresentou baixa acurácia e moderada concordância para o método GT, devendo ser utilizada com cautela por cirurgiões.

## Palavras-chave

- ▶ cavidade glenoide
- ▶ instabilidade anterior do ombro
- ▶ luxação do ombro

## Introduction

Proper assessment of patients with traumatic anterior shoulder instability is still a challenge for orthopedists.<sup>1</sup> A precise, detailed study of soft tissue and bone lesions in glenohumeral instability requires three-dimensional-reconstructed computed tomography (3D-CT), magnetic resonance imaging (MRI) or arthro-MRI scans, which can increase propaedeutic costs, delay and bureaucratize treatment.<sup>2</sup>

The dynamic interaction between bone losses at the proximal humerus and the glenoid in traumatic anterior shoulder dislocation, the so-called lesion bipolarity, was described in 3D-CT using the glenoid track (GT) concept. This concept has gained prominence in the scientific community for its prognostic ability and role in guiding the appropriate treatment according to the Hill-Sachs lesion (HSL) classification and the glenoid bone loss (GBL) size.<sup>3</sup>

Considering this method as optimal and in an attempt to reduce costs by the simultaneous evaluation of soft and bone lesions in a single scan, the orthopedic literature tried to replace 3D-CT with MRI/arthro-MRI.<sup>3–5</sup> As such, this study aims to compare the GT method performed by shoulder surgeons using MRI/arthro-MRI with the evaluation performed by a radiologist using 3D-CT. Our hypothesis is that GT measurement by MRI/arthro-MRI can be performed accurately and reliably by surgeons in their clinical practice.

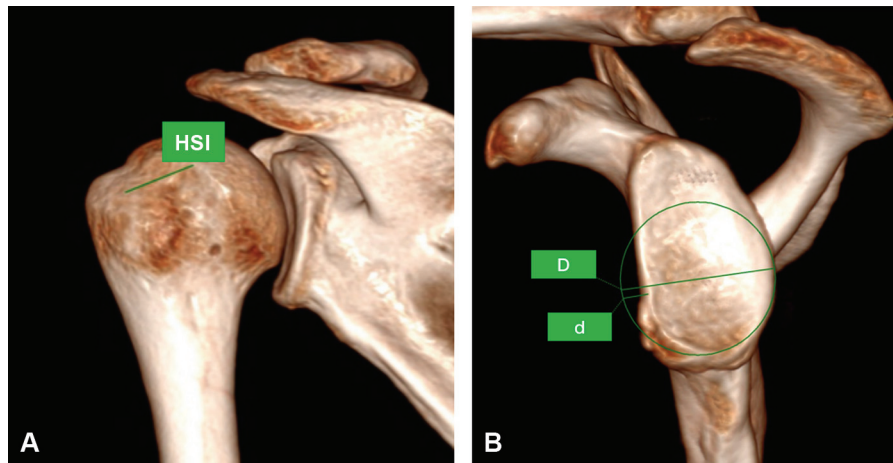
## Material

This is a cross-sectional, analytical study with 43 patients and 44 shoulders, selected using a non-probabilistic method (i.e., a convenience sampling), diagnosed with traumatic anterior shoulder instability from March 2015 to September 2018. All patients underwent 3D-CT, MRI, and/or arthro-MRI scans at a single radiology clinic.

Glenoid track, HSI, and GBL calculations, as well as lesion classification as *on-track/off-track*, were performed in all 3D-CT scans by a single radiologist (R) with more than 10 years of experience in the musculoskeletal system. This analysis was considered the reference standard.

Three shoulder surgeons (C1, C2, and C3) trained in the GT method performed the same calculations in MRI or arthro-MRI scans. All of them were blinded to the results obtained by R or the remaining evaluators. All calculations were performed in a single moment and recorded by 2 4-year residents (R4) in shoulder surgery.

Gender, age, and dominance were not considered. Patients with clinical and radiological diagnosis of traumatic anterior shoulder instability, with complete, documented 3D-CT, MRI, and/or arthro-MRI scans and no previous surgical treatment until the time of data analysis were included. Patients evaluated by another radiologist, whose scans were performed at other radiological facilities, and with incomplete information or associated lesions, such as fractures, rotator cuff injuries or glenohumeral arthrosis, were excluded.



**Fig. 1** Three-dimensional computed tomographic images showing the glenoid track (GT) calculation. (1A) The Hill-Sachs interval (HSI) corresponds to the distance between the inner margin of the rotator cuff footprint and the medial border of the bone defect. (1B) A virtual circle drawn in the lower two thirds of the intact glenoid borders shows the potential diameter in the absence of a bone defect (D) and the bone defect width (d). The GT corresponds to 83% of the glenoid diameter minus the bone defect diameter.

## Methods

All CT-3D were performed in a 64- or 128-channel scanner, Siemens Somatom Sensation or Siemens Somatom Definition AS, respectively, (Siemens AG, Munich, Germany) in supine position and with limbs in neutral rotation.

Magnetic resonance imaging and arthro-MRI scans (Magnetom Essenza 1.5 T - Siemens Healthcare, Erlangen, Germany) were performed in supine position, with the shoulder in neutral rotation, using T2-weighted sequences with or without fat suppression (TR/TE 2280/42, field of view  $160 \times 100$  mm, matrix  $384 \times 70$ , 3-mm thickness) in postprocessed axial, sagittal, and coronal views (Kodak Carestream PACS, Belo Horizonte, Minas Gerais, Brazil).

Glenoid track, HSI, GBL calculations, and on-track/off-track classifications were performed in 3D-CT scans as described by Di Giacomo et al.<sup>3</sup> (►Figure 1A and 1B). The same calculations were performed in MRI/arthro-MRI scans as reported by

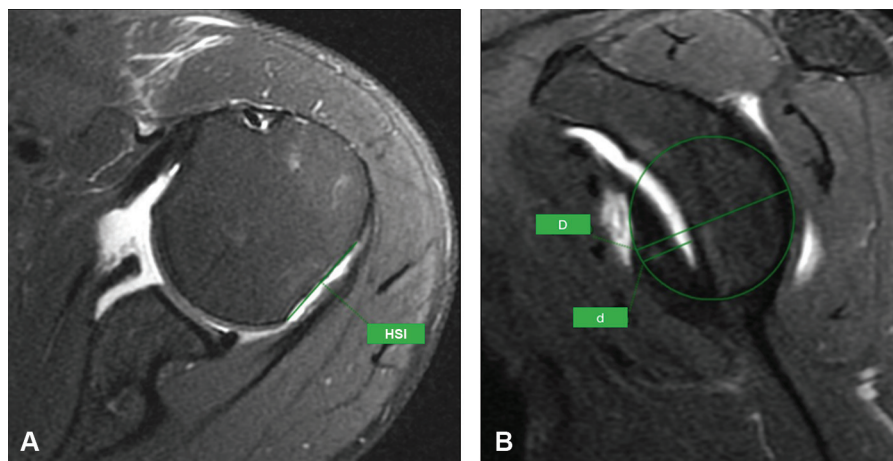
Guyftopoulos et al.<sup>4</sup> (►Figure 2A and 2B). Glenoid track was determined using the formula  $GT = 0.83D - d$ .

Data was analyzed with the IBM SPSS software 23.0. (IBM Corp., Armonk, NY, USA). The level of significance was 5% for the entire study. This study was approved by the institutional research ethics committee.

## Results

### Descriptive analysis

None of the 44 shoulders from the sample was excluded from the study. All shoulders were submitted to 3D-CT scans; in addition, 19 (43.2%) and 25 (56.8%) of them also underwent MRI and arthro-MRI scans, respectively. Twenty-four shoulders (65.9%) were classified as on-track, and 20 (45.5%) were deemed off-track by examiner R in 3D-CT scans. Results of the four evaluators were completely consistent in 61.4% of the cases (►Table 1).



**Fig. 2** Arthro-resonance magnetic imaging (arthro-MRI) showing the glenoid track (GT) measurement. The lower glenoid diameter (D) was determined with a circle drawn along it for GT calculation. The length of glenoid bone loss (d) was then measured. The glenoid track was calculated using the formula  $GT = 0.83D - d$ . (2A) Hill-Sachs interval (HSI) measurement using a posterior view of the humeral head. (2B) GT calculation similar to the one performed in computed tomography images.

**Table 1** Descriptive analysis of qualitative variables: imaging test, on-track/off-track classification, and disagreement among examiners

Variable	Frequency	%
<b>Imaging test</b>		
Computed tomography	44	100.0
MRI	19	43.2
Arthro-MRI	25	56.8
<b>Result – R</b>		
On-track	24	54.5
Off-track	20	45.5
<b>Result – C1</b>		
On-track	29	65.9
Off-track	15	34.1
<b>Result – C2</b>		
On-track	31	70.5
Off-track	13	29.5
<b>Result – C3</b>		
On-track	36	81.8
Off-track	8	18.2
<b>Discordance</b>		
0	27	61.4
1	7	15.9
2	5	11.4
3	5	11.4
<b>Total</b>	44	100.0

Abbreviations: Arthro-MRI, Arthro-resonance magnetic imaging; MRI, magnetic resonance imaging.

**Table 2** Descriptive analysis of quantitative variables: glenoid track, Hill-Sachs interval and glenoid bone loss according to examiners R, C1, C2 and C3

	n	Mean	Median	Standard deviation	Minimum	Maximum	Interquartile range
Examiner R	44	20.30	20.27	2.50	12.98	27.39	3.13
GT							
HSI	44	19.64	20.21	3.61	11.32	29.01	4.17
GBL	44	8.68	9.50	7.65	0.00	33.00	14.00
Examiner C1	44	20.00	19.98	3.71	2.46	26.08	3.18
GT							
HSI	44	17.36	18.35	5.72	6.35	33.84	8.16
GBL	44	11.63	11.50	7.12	0.00	33.00	7.58
Examiner C2	44	20.60	20.68	2.73	12.08	25.04	4.00
GT							
HSI	44	16.62	16.10	5.39	3.78	29.82	5.70
GBL	44	7.83	0.00	9.19	0.00	30.53	15.43
Examiner C3	44	21.95	22.13	2.81	15.49	30.52	3.55
GT							
HSI	44	15.69	14.51	5.30	4.79	29.35	6.46
GBL	44	7.21	7.00	7.25	0.00	22.00	13.00

Abbreviations: GBL, glenoid bone loss; GT, glenoid track; HSI, Hill-Sachs interval.

### Variance analysis

Kolmogorov-Smirnov, Levene, *posthoc* Dunnett, and T3 Dunnett's tests assessed the variation in GT, HSI and GBL results among the four examiners.

There was a statistically significant difference for GT, HSI and GBL values when the results found by the four examiners were compared. The greatest data variability referred to HSI. Mean HSI values were lower at MRI/arthro-MRI when compared to 3D-CT (► **Tables 2** and **3**).

*Posthoc* tests showed a statistically significant difference in GT values between R and C3 ( $p = 0.027$ ) and C1 and C3 ( $p = 0.039$ ); C3 found significantly higher values than the two other examiners.

For HSI, there was a significant difference between R and C2 ( $p = 0.017$ ) and R and C3 ( $p = 0.001$ ), since R found significantly higher values.

As for GBL, there was a difference between C1 and C3 ( $p = 0.027$ ), since the former found significantly higher values compared to the latter.

### Analysis of results disagreement association

A non-parametric correlation analysis was performed to evaluate quantitative variables. To this end, results from R were considered always correct and the number of disagreements with these results was assessed (0–3 disagreements) with the Spearman correlation test.

There was a statistically significant correlation between HSI and GBL, both with a positive coefficient, indicating that higher HSI and GBL values were associated with more disagreements among examiners (► **Table 4**).

The Pearson chi-squared test assessed qualitative variables. Off-track injuries accounted for 88.24% of the disagreements. This finding demonstrates that the greatest difficulty

**Table 3** Descriptive glenoid track, Hill-Sachs interval, and glenoid bone loss measures for variance analysis according to examiners R, C1, C2 and C3

		n	Mean	Standard deviation	Standard error	95% Confidence interval for the mean		Minimum	Maximum
						Lower limit	Upper limit		
GT	R	44	20.30	2.50	0.38	19.54	21.06	12.98	27.39
	C1	44	20.00	3.71	0.56	18.87	21.13	2.46	26.08
	C2	44	20.60	2.73	0.41	19.76	21.43	12.08	25.04
	C3	44	21.95	2.81	0.42	21.10	22.81	15.49	30.52
	Total	176	20.71	3.04	0.23	20.26	21.17	2.46	30.52
HSI	R	44	19.64	3.61	0.54	18.55	20.74	11.32	29.01
	C1	44	17.36	5.72	0.86	15.62	19.10	6.35	33.84
	C2	44	16.62	5.39	0.81	14.98	18.26	3.78	29.82
	C3	44	15.69	5.30	0.80	14.08	17.30	4.79	29.35
	Total	176	17.33	5.24	0.39	16.55	18.11	3.78	33.84
GBL	R	44	8.68	7.65	1.15	6.36	11.01	0.00	33.00
	C1	44	11.63	7.12	1.07	9.46	13.79	0.00	33.00
	C2	44	7.83	9.19	1.39	5.03	10.62	0.00	30.53
	C3	44	7.21	7.25	1.09	5.01	9.41	0.00	22.00
	Total	176	8.84	7.96	0.60	7.65	10.02	0.00	33.00

Abbreviations: GBL, glenoid bone loss; GT, glenoid track; HSI, Hill-Sachs interval.

**Table 4** Correlation analysis for glenoid track, Hill-Sachs interval, glenoid bone loss, and disagreement among examiners

Correlations					
			HSI	GBL	Discordance
Spearman's $\rho$	GT	Correlation Coefficient	0.154	-0.565	-0.264
		P	0.320	0.000	0.084
		n	44	44	44
	HSI	Correlation Coefficient	1.000	0.177	0.434
		P		0.249	0.003
		n	44	44	44
	GBL	Correlation Coefficient			0.334
		P			0.027
		n			44

Abbreviations: GBL, glenoid bone loss; GT, glenoid track; HSI, Hill-Sachs interval.

occurred in the diagnosis by MRI/arthro-MRI of off-track injuries calculated by 3D-CT.

### Concordance analysis

Sensitivity values were not very high, ranging from 35 to 65% (**► Table 5**). The kappa coefficient was statistically significant for all cases. This coefficient describes the agreement between 2 or more tests, with values ranging from 0 to 1. Values close to 0 indicate low agreement, whereas values close to 1 reveal high agreement. The kappa index ranged from 0.325 to 0.579. This means that the GT method using MRI/arthro-MRI images presented only a moderate ability to identify patients with off-track injuries diagnosed at 3D-CT scans.

The positive predictive value (PPV) ranged from 86.67 to 92.31%. The negative predictive value (NPV) ranged from 63.89 to 75.86%. The diagnostic accuracy for off-track injuries ranged from 68.1 to 79.5% among examiners.

### Receiver operating characteristic (ROC) curve

The ROC curve revealed that C3 assessment was the only one with no statistical efficiency in off-track injuries diagnosis ( $p > 0.05$ ) (**► Figure 3**). The best classification was performed by C1, which obtained the largest area under the curve. Better test results reflect in an area under the ROC curve closer to 1.



**Table 5** Kappa index, sensitivity, specificity, predictive value, likelihood ratio and accuracy of the examining surgeons (C1, C2 and C3) in the diagnosis of on-track/off-track injuries by MRI/arthro-MRI

	C1	C2	C3
Kappa index	0.579	0.575	0.325
Sensitivity (%)	65.00	60.00	35.00
Specificity (%)	91.67	95.83	95.83
Positive predictive value (%)	86.67	92.31	87.50
Negative predictive value (%)	75.86	74.19	63.89
Positive likelihood ratio	7.80	14.39	8.39
Negative likelihood ratio	0.38	0.42	0.68
Accuracy	79.5	79.5	68.1
p-value	< 0.001	< 0.001	0.014

Abbreviations: Arthro-MRI, Arthro-resonance magnetic imaging; MRI, magnetic resonance imaging.

## Discussion

Historically, studies on anterior shoulder instability have focused on GBL, which occurs during shoulder dislocation and is also called bony Bankart lesion (BBL).<sup>6,7</sup> It is widely accepted that this structural damage alters glenoid biomechanics by impairing its function as a static stabilizer.<sup>8</sup> Defects greater than 20 to 25% deserve special attention because of their worse prognosis with arthroscopic repair.<sup>6,9</sup>

In an anterior dislocation, the shoulder may suffer an impaction fracture at the posterosuperior and lateral portion of the humeral head. This injury is defined as a Hill-Sachs lesion, and it is observed in up to 70% primary shoulder dislocation cases.<sup>10,11</sup> Studies reveal that bone defects as small as 5/8 of the humeral head radius may result in shoulder instability.<sup>12</sup>

Although the importance of HSL and BBL in shoulder biomechanics was demonstrated, the description of the GT method allowed us to understand the dynamic interaction between these bone injuries.<sup>13</sup> Today, the GT method is part of the routine practice of most orthopedics services due to its prognostic ability in HSL evaluation and its role in guiding the treatment for anterior shoulder instability.<sup>3</sup>

Originally, GT and GBL measurements were described for 3D-CT scans to predict engage-type injuries.<sup>3,13</sup> However, to reduce costs and radiation exposure, the use of MRI/arthro-MRI have been studied for this purpose.<sup>1,4,14</sup>

The engagement concept was proposed initially by Burkhart and De Beer<sup>7</sup> to explain factors related to instability recurrence after an arthroscopic Bankart surgery. Patients bearing these injuries, with the shoulder in abduction and lateral rotation, would be predisposed to the “engagement” of HSL on the anterior edge of the glenoid, leading to joint instability. Engage lesions correspond to off-track injuries per the GT method.<sup>3</sup>

In an attempt to make the glenoid track method feasible for MRI, Gyftopoulos et al.<sup>4</sup> compared GT classification in 75

shoulders with the engagement observed during arthroscopy. They concluded that MRI has 72.2% sensitivity to diagnose engage (off-track) injuries, 87.9% specificity for non-engage injuries (on-track), and a general accuracy of 84.2%. Positive predictive value was 65% and NPV was 91.1%.

In the present study, MRI/arthro-MRI diagnosed off-track injuries with 35 to 65% sensitivity, and on-track injuries with 91.67 to 95.83% specificity. The accuracy for off-track injuries diagnosis ranged from 68.1 to 79.5%. Positive predictive value revealed a chance of identifying truly off-track patients of at least 86.67%, while NPV showed a chance of identifying truly positive on-track injuries of at least 63.89%. The kappa coefficient was significant in all cases. These results are inferior to those demonstrated by Gyftopoulos et al.<sup>4</sup>

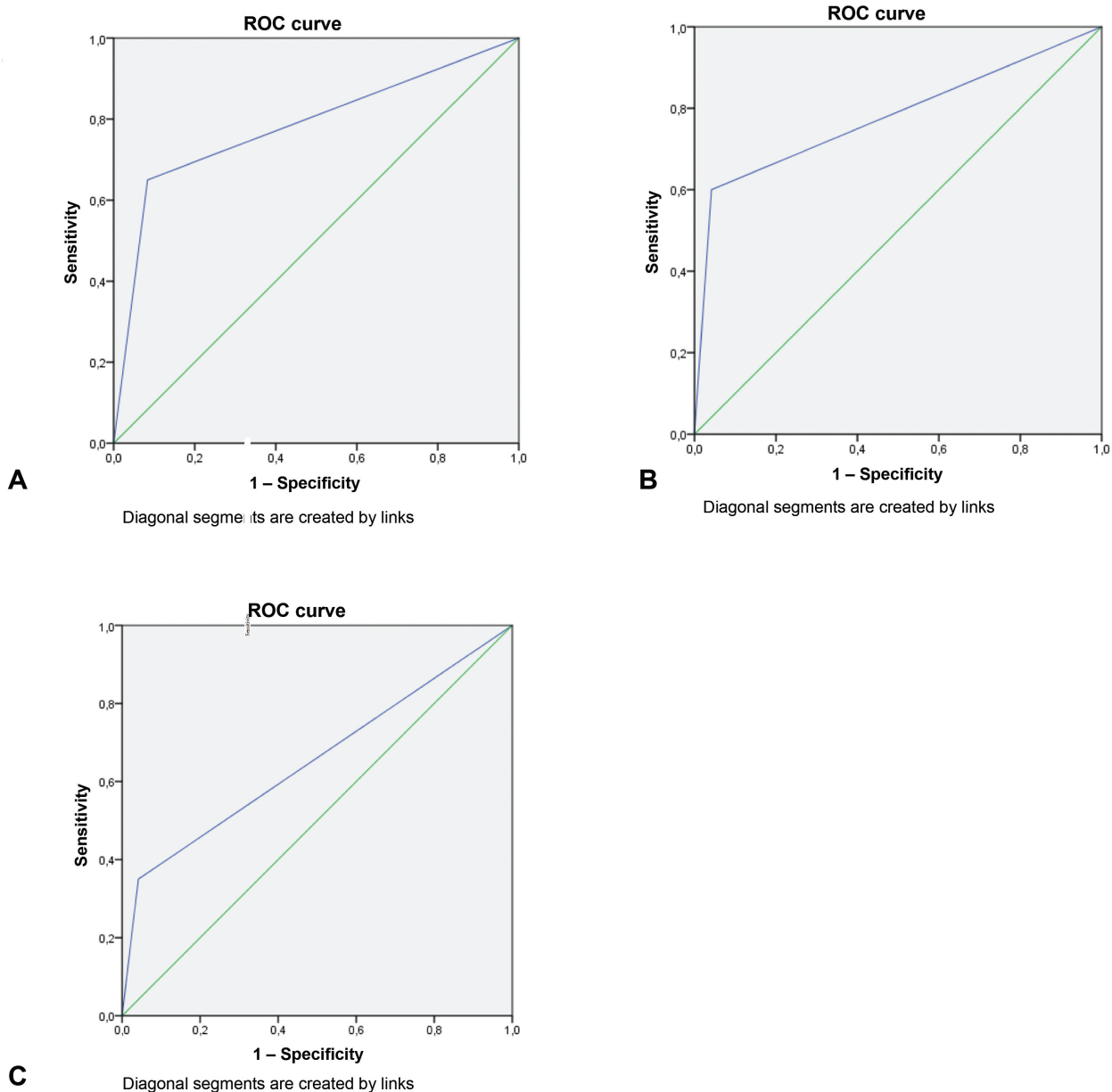
Schneider et al.<sup>15</sup> evaluated intra and interobserver variation in GT measurement in 71 patients submitted to 3D-CT scans. They demonstrated that GBL assessment had good intra and interobserver agreement (94% and 96%, respectively). However, the level of reliability among examiners for on-track and off-track classification was only 72%, which was considered low by the authors. They concluded that GBL assessment had better reproducibility and reliability levels compared to HSL.

Our findings demonstrated that the greatest data variability occurred for HSI calculation in MRI/arthro-MRI scans, consistent with the findings of Schneider et al.<sup>15</sup> with 3D-CT. In addition, we concluded that MRI/arthro-MRI tends to yield lower HSI values when compared to 3D-CT. The proper evaluation of HSL requires several steps and, in our opinion, each one of them presents a potential for error, leading to the low reliability and reproducibility reported in the literature.

Funakoshi et al.<sup>16</sup> assessed the GT classification agreement between 3D-CT scans and intraoperative arthroscopic measurements. Of 16 shoulders classified as on- or off-track, agreement between both methods was achieved in only 10 shoulders (63%, kappa value = 0.16). All cases with disagreement were calculated as on-track by 3D-CT and off-track by arthroscopy. The authors concluded that 3D-CT yields higher GT values compared with arthroscopy, accounting for all discrepancies and the low agreement between methods observed in the study.

Our results revealed a moderate agreement for on-track/off-track classification between 3D-CT and MRI/arthro-MRI scans (kappa values, 0.325 to 0.579). In our study, most of the discordant results (15 out of 17, or 88.24%) were classified as off-track by 3D-CT and on-track by MRI/arthro-MRI, which may be inadequate to HSL, increasing the risk of instability recurrence. Results from the four examiners were fully consistent in 27 of the 44 shoulders (61.4%) for on-track/off-track classification. Interestingly, higher HSI and GBL values were associated with greater discrepancy among examiners. We believe that this discrepancy can be explained by the evaluators' difficulty in selecting the most representative bone lesions images, especially in MRI/arthro-MRI, which allows image analysis in only two dimensions, unlike CT.

The evaluator C3 obtained the highest average GT and was the only one not to show statistical efficiency according to



**Fig. 3** Receiver operating characteristic (ROC) curves from the three surgeon examiners (C1, C2 and C3) diagnosing on-track/off-track injuries using MRI/arthro-MRI. Areas under the ROC curve and  $p$ -values were the following: area = 0.783,  $p = 0.001$  for examiner C1; area = 0.779,  $p = 0.002$  for examiner C2; and area = 0.654,  $p = 0.081$  for examiner C3.

the ROC curve. Perhaps, this is why C3 presented the lowest agreement among the examiners (kappa value = 0.325).

To our knowledge, this is the first study to compare the GT method using 3D-CT and MRI/arthro-MRI. Although the available studies use different modalities to compare the GT method, our results are very close to those published in the literature.

Obviously, MRI/arthro-MRI scans for GT classification do not constitute a perfect technique. Our results show that MRI/arthro-MRI tends to yield lower HSI values. In this case, we believe that 3D-CT evaluation overestimates the results because it is unable to identify the exact attachment point of the infraspinatus tendon, used as a reference for measurement. This may explain the difficulty of MRI/arthro-MRI in identifying off-track injuries diagnosed using 3D-CT in our

study. This data is highly relevant because, as previously described, these injuries must be addressed using the remplissage technique to reduce the chances of anterior shoulder dislocation recurrence.<sup>3</sup>

The reasons for GT classification diagnostic failure have been discussed in the literature and may be related to inter and intraobserver variations and to the lack of identification of the attachment point of the rotator cuff for HSI calculation, the medial HSL border and the GBL limit. The GT estimate (the most important component of the technique) has been reported as technically difficult and challenging.<sup>4,5</sup>

The limitations of this study include its cross-sectional nature, as well as the limited sampling using a non-probabilistic method, which is attributed mainly to the cost of CT and MRI/arthro-MRI scans. The evaluation performed by surgeons,

and not just radiologists, and the absence of serial evaluations of the same images constitute measurement bias.

## Conclusion

The GT method performed in MRI/arthro-MRI revealed low accuracy and moderate agreement to diagnose on-track/off-track injuries when compared with 3D-CT. The medial border of the infraspinatus tendon and the medial border of the HSL must be carefully determined since the greatest data divergences referred to HSI calculation. Magnetic resonance imaging/arthro-MRI scans tend to yield lower HSI values. The greatest difficulty of the study involved the diagnosis by MRI/arthro-MRI of off-track injuries calculated by 3D-CT. Magnetic resonance imaging/arthro-MRI scans should be used cautiously by shoulder surgeons calculating the glenoid track.

### Financial Support

There was no financial support from public, commercial, or non-profit sources.

### Conflict of Interests

The authors declare that there is no conflict of interest.

## References

- Momaya AM, Tokish JM. Applying the Glenoid Track Concept in the Management of Patients with Anterior Shoulder Instability. *Curr Rev Musculoskelet Med* 2017;10(04):463–468
- França FO, Godinho A, Ribeiro E, Ranzzi A, Bittencourt BL, Barreto BB. Novo método quantitativo para medida da lesão de Hill-Sachs: validação do método radiográfico de Hardy para ressonância magnética/artro-RNM. *Rev Bras Ortop* 2018;53(05):589–594
- Di Giacomo G, Itoi E, Burkhart SS. Evolving concept of bipolar bone loss and the Hill-Sachs lesion: from “engaging/non-engaging” lesion to “on-track/off-track” lesion. *Arthroscopy* 2014;30(01):90–98
- Gyftopoulos S, Beltran LS, Bookman J, Rokito A. MRI Evaluation of Bipolar Bone Loss Using the On-Track Off-Track Method: A Feasibility Study. *AJR Am J Roentgenol* 2015;205(04):848–852
- Metzger PD, Barlow B, Leonardelli D, Peace W, Solomon DJ, Provencher MT. Clinical Application of the “Glenoid Track” Concept for Defining Humeral Head Engagement in Anterior Shoulder Instability: A Preliminary Report. *Orthop J Sports Med* 2013;1(02):2325967113496213
- Bigliani LU, Newton PM, Steinmann SP, Connor PM, McIlveen SJ. Glenoid rim lesions associated with recurrent anterior dislocation of the shoulder. *Am J Sports Med* 1998;26(01):41–45
- Burkhart SS, De Beer JF. Traumatic glenohumeral bone defects and their relationship to failure of arthroscopic Bankart repairs: significance of the inverted-pear glenoid and the humeral engaging Hill-Sachs lesion. *Arthroscopy* 2000;16(07):677–694
- Rabinowitz J, Friedman R, Eichinger JK. Management of Glenoid Bone Loss with Anterior Shoulder Instability: Indications and Outcomes. *Curr Rev Musculoskelet Med* 2017;10(04):452–462
- Itoi E, Lee SB, Berglund LJ, Berge LL, An KN. The effect of a glenoid defect on anteroinferior stability of the shoulder after Bankart repair: a cadaveric study. *J Bone Joint Surg Am* 2000;82(01):35–46
- Hill HA, Sachs MD. The grooved defect of the humeral head: a frequently unrecognized complication of dislocations of the shoulder joint. *Radiology* 1940;35:690–700
- Arciero RA, Parrino A, Bernhardtson AS, et al. The effect of a combined glenoid and Hill-Sachs defect on glenohumeral stability: a biomechanical cadaveric study using 3-dimensional modeling of 142 patients. *Am J Sports Med* 2015;43(06):1422–1429
- Kaar SG, Fening SD, Jones MH, Colbrunn RW, Miniaci A. Effect of humeral head defect size on glenohumeral stability: a cadaveric study of simulated Hill-Sachs defects. *Am J Sports Med* 2010;38(03):594–599
- Yamamoto N, Itoi E, Abe H, et al. Contact between the glenoid and the humeral head in abduction, external rotation, and horizontal extension: a new concept of glenoid track. *J Shoulder Elbow Surg* 2007;16(05):649–656
- Huijsmans PE, Haen PS, Kidd M, Dhert WJ, van der Hulst VP, Willems WJ. Quantification of a glenoid defect with three-dimensional computed tomography and magnetic resonance imaging: a cadaveric study. *J Shoulder Elbow Surg* 2007;16(06):803–809
- Schneider AK, Hoy GA, Ek ET, et al. Interobserver and intraobserver variability of glenoid track measurements. *J Shoulder Elbow Surg* 2017;26(04):573–579
- Funakoshi T, Hartzler RU, Stewien E, Burkhart SS. Hill-Sachs Lesion Classification by the Glenoid Track Paradigm in Shoulder Instability: Poor Agreement Between 3-Dimensional Computed Tomographic and Arthroscopic Methods. *Arthroscopy* 2019;35(06):1743–1749