

Evaluation of Intramedullary Methods with Polymethylmethacrylate for Fixation of Bone Lesions of the Extremities*

Avaliação de métodos intramedulares com polimetilmetacrilato para fixação em lesões ósseas de extremidades

Marcio Moura¹ Diego Pereira Sanches² Álvaro Ferreira Pinto² Sibebe Sauzem Milano¹
Marcella Maria Villela¹

¹Department of Surgery, Universidade Federal do Paraná, Curitiba, PR, Brazil

²Division of Orthopedic Oncology, Hospital do Trabalhador, Secretaria de Saúde do Estado do Paraná, Curitiba, PR, Brazil

Address for correspondence Dr. Márcio Moura, Rua General Carneiro, 181, Curitiba, PR, 80060-900, Brasil
(e-mail: mm.mm1966@gmail.com).

Rev Bras Ortop 2021;56(6):772–776.

Abstract

Objective To evaluate the better potential and functional results in pain control in the treatment of pathological fractures and prophylactic fixation with an intramedullary nail associated with polymethylmethacrylate, compared with the utilization of an intramedullary nail in long bone tumor lesions.

Methods From January 2012 to September 2017, 38 patients with 42 pathological lesions (fractures or impending fractures according to the Mirels criteria) were treated surgically. Sixteen patients allocated to the control group underwent a locked intramedullary nail fixation, and 22 patients with pathological lesions were allocated to treatment with an intramedullary nail associated with polymethylmethacrylate. Postoperatively, the patients were submitted to the Musculoskeletal Tumor Society (MSTS) rating scale, radiographic assessment, and to the assessment of events and complications related to the treatment.

Results The evaluation using the MSTS questionnaire showed better functional results in the group associated with polymethylmethacrylate, in comparison with the control group, which obtained an average score of 16.375 out of a maximum of 30 points (54.6%). The group studied with association with polymethylmethacrylate obtained a mean of 22.36 points (74.5%). The procedure proved to be safe, with similar complication and severity rates, and with no statistical difference in comparison with the standard treatment.

Keywords

- ▶ fractures, spontaneous
- ▶ polymethyl methacrylate
- ▶ bone neoplasms
- ▶ bone cements

* The present study was carried out at the Division of Orthopedic Oncology of the Hospital de Clínicas da Universidade Federal do Paraná and the Hospital do Trabalhador – SESA, Curitiba, PR, Brazil.

received
July 29, 2020
accepted
April 23, 2021
published online
November 4, 2021

DOI <https://doi.org/10.1055/s-0041-1735171>.
ISSN 0102-3616.

© 2021. Sociedade Brasileira de Ortopedia e Traumatologia. All rights reserved.

This is an open access article published by Thieme under the terms of the Creative Commons Attribution-NonDerivative-NonCommercial-License, permitting copying and reproduction so long as the original work is given appropriate credit. Contents may not be used for commercial purposes, or adapted, remixed, transformed or built upon. (<https://creativecommons.org/licenses/by-nc-nd/4.0/>)

Thieme Revinter Publicações Ltda., Rua do Matoso 170, Rio de Janeiro, RJ, CEP 20270-135, Brazil

Conclusion Stabilization of tumor lesions with an internal fixation associated with the polymethylmethacrylate demonstrated early rehabilitation and improved the quality of life, allowing rapid functional recovery. The use of polymethylmethacrylate has advantages such as reduced bleeding, tumor necrosis and higher mechanical stability.

Resumo

Objetivo Avaliar o potencial melhor resultado funcional e controle algico no tratamento de fraturas patológicas e fixações profiláticas tratadas com haste intramedular associada ao polimetilmetacrilato (PMMA) em comparação com o uso de haste intramedular em lesões tumorais em ossos longos.

Métodos De janeiro de 2012 a setembro de 2017, 38 pacientes com 42 lesões patológicas (fraturas ou iminência segundo os critérios de Mirels) foram tratados cirurgicamente. Dezesesseis pacientes submetidos a fixação com haste intramedular bloqueada foram alocados ao grupo controle e 22 pacientes com lesões patológicas foram alocados para tratamento com haste intramedular associada ao PMMA. No pós-operatório, foi realizada a submissão dos pacientes ao escore da Musculoskeletal Tumor Society (MSTS, na sigla em inglês) e à avaliação radiográfica do tratamento realizado, assim como à avaliação de intercorrências e complicações relacionadas ao tratamento.

Resultados A avaliação através do questionário MSTS demonstrou melhor resultado funcional do grupo associado com PMMA quando comparado com o grupo controle, o qual obteve uma pontuação média de 16,375 em um máximo de 30 pontos (54,6%), enquanto o grupo em estudo com associação do PMMA obteve uma média de 22,36 pontos (74,5%). O procedimento mostrou-se seguro, taxas de complicações e gravidade semelhantes e sem diferença estatística quando comparado com o tratamento padrão.

Conclusão A estabilização de lesões tumorais com fixação associada ao PMMA demonstrou reabilitação precoce e melhora na qualidade de vida, permitindo rápida recuperação funcional. A utilização do PMMA apresenta vantagens como diminuição do sangramento e da necrose tumoral e maior estabilidade mecânica.

Palavras-chave

- ▶ fraturas espontâneas
- ▶ polimetilmetacrilato
- ▶ neoplasias ósseas
- ▶ cimentos para ossos

Introduction

Advances in chemotherapy and radiotherapy treatment have increased the life expectancy of cancer patients, making them more susceptible to metastatic presentation.¹

Pathological fractures occur in between 11 and 29% of metastatic bone lesions.²⁻⁵ Surgical treatment allows for improved functional capacity, greater emotional acceptance, and care, as well as pain relief; therefore, early treatment provides a far better quality of life.⁶

Benign lesions such as simple and aneurysmal bone cyst, fibrous dysplasia, giant cell tumors, and Paget disease present an increased risk of fracture, especially in the proximal portion of long bones.⁷⁻⁹

Among the surgical methods, the foremost used is the intramedullary nail (IMN), due to its biomechanical properties^{5,10-13} and greater stability in the face of disease progression, where the stabilization of lesions with the utilization of plates and screws may fail and define the survival of the patient.

The IMN can be introduced through the open or percutaneous technique; therefore, the use of bone cement allows for greater stability and pain control.¹⁴⁻¹⁶ The association of

bone cement has already been shown to be efficient in the oncological treatment of the spine and flat bones.¹⁷

The present study aimed to evaluate the results of the treatment of pathological lesions in long bones with the use of IMN associated or not with polymethylmethacrylate (PMMA).

Materials and methods

Between January 2012 and September 2017, 38 patients with 42 pathological injuries were treated, meeting the objectives of this research, with fractures or bone injuries on the verge of a fracture according to the criteria of Mirels, who underwent surgical procedure, being divided into two groups.

The inclusion criteria were: long bone neoplasm (primary or secondary), meeting the criteria of Mirels with surgical indication, pathological fractures in long bones, intramedullary osteosynthesis associated or not with PMMA, absence of previous treatment of the lesion, acceptance of the written informed consent form (WICF).

Table 1 Epidemiological differentiation between groups

	Control	Intramedullary nail + PMMA
Gender (F:M)	11:5	15:7
Primary Injury		
Breast	6	8
Multiple myeloma	2	2
Prostate	1	4
Uterine	0	2
Pulmonary	0	1
Melanoma	0	1
Colon	1	0
COA	1	0
Lymphoma	1	0
Hepatic	1	0
Renal	1	2
Fibrous dysplasia	1	0
Fracture secondary to osteochondroma resection	1	0
Hyperparathyroidism	0	1
Fracture secondary to radiation	0	1

Abbreviations: F, female; M, male; PMMA, polymethylmethacrylate; COA, aneurysmal bone cyst.

The exclusion criteria were: previous fracture in the affected limb, non-intramedullary osteosynthesis, a previous infectious process in the affected limb, non-acceptance of the WICF.

Group 1, with 16 patients, received treatment with IMN. For Group 2, with 22 patients, the treatment was associated with PMMA. The surgical technique had similar surgical steps. After placing the nail and drilling the locking holes close to the insertion of the nail, the material was removed, and a hole was drilled in the metadiaphyseal region opposite to the entrance of the nail. The objective was to reduce intramedullary pressure during cementation and insertion of the intramedullary cement through the nail entry point, with continuous aspiration through the drilling point. Before the complete hardening of the cement, the nail is replaced and locked.

Among the patients allocated to Group 1, 11 females and 5 males, the primary disease is described in ►Table 1. The lesion site in eight cases was the proximal femur, five cases with involvement of the diaphyseal humerus, two cases in the diaphyseal portion of the femur, and one case in the distal femur (►Table 1).

In Group 2 patients, 15 females and 7 males, the primary disease is described in ►Table 1. The lesion site in 10 cases was the proximal femur, in 10 cases the diaphyseal humerus, 4 cases in the diaphyseal portion of the femur, 1 case in the distal femur, and 1 fracture of the diaphyseal tibia. In this group, there was one patient with a bilateral humeral fracture, one patient with bilateral transtrochanteric injury, and one patient with a bilateral femoral diaphyseal fracture and humeral diaphyseal fracture (►Table 1).

Table 2 Age evaluation and follow-up, according to the Student t test

	Control	Intramedullary nail + PMMA	
Age (years old)	51.5	64.8	$p = 0.05$
Follow-up (months)	11.7	8.4	$p = 0.48$

Abbreviation: PMMA, polymethylmethacrylate.

The mean follow-up time for the patients in Group 1 was 11.7 months (between 0 and 63 months), and in Group 2 it was 8.4 months (between 0 and 30 months). The functional assessment of the patients was performed through the analysis of the Musculoskeletal Tumor Society (MSTS) score. The postoperative radiographic assessments were carried out in order to verify the union of the fractures.

Results

A total of 38 patients, with a mean age of 59.24 years (between 14 and 85 years old), 26 females and 12 males, met the inclusion criteria. One patient had a bilateral femur fracture and a unilateral humerus fracture, 1 had a bilateral proximal femoral injury, and 1 had a bilateral humerus fracture, comprising 42 treated injuries.

The radiographic evaluation showed adequate alignment of the fractures and, in cases with a follow-up >1 year, no case of pseudarthrosis was evidenced by the radiographs. One patient with a fracture within the proximal femur had apparent cement leakage, but this patient did not wish to undergo to a replacement treatment, as she had sporadic pain.

The mean age in the control group was 51.5 years old (between 14 and 85 years old), whereas in the group treated with PMMA associated with IMN the mean age was 64.8 years old (between 27 and 84 years old). The mean follow-up time in the control group was 11.7 months (between 0 and 63 months), and in the PMMA-associated IMN group, it was 8.4 months (between 0 and 30 months). There was no statistical difference between ages in the groups ($p = 0.05$), as well as no statistical difference in the follow-up ($p = 0.48$) (►Table 2).

The functional assessment of patients using the MSTS questionnaire showed the superiority of the group that received the treatment linked to PMMA, with statistical significance ($p = 0.049$). The control group had an average score of 16.375 out of a maximum of 30 points, while the group with the PMMA association had an average score of 22.36 points (►Fig. 1).

In a comparative evaluation with new segmentation, this difference was not observed when we compared only the patients with injuries and treatments in the upper limbs, with a mean score of 20 ($n = 5$) in the MSTS questionnaire of patients treated with surgical synthesis material, and a score of 23.125 ($n = 8$) when associated with PMMA ($p = 0.60$). However, when this assessment was carried out comparing patients with injuries in the lower limbs, the control group ($n = 10$) had an average score of 13.6, and the group with

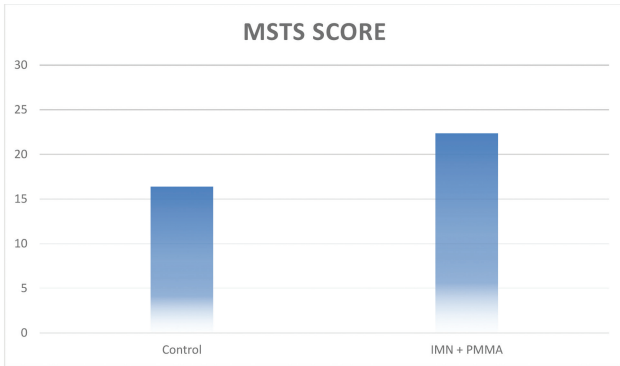


Fig. 1 MSTS rating scale for functional evaluation.

PMMA association ($n = 13$) had an average score of 21.46, with statistical significance ($p = 0.036$).

The comparison between the affected upper and lower limbs shows no difference within the group in the comparison between the control group and the group associated with PMMA. The patients in the control group with injury in the upper limbs, with a mean score of 20 ($n = 5$) versus patients with injuries in the lower limbs of the control group ($n = 10$), with a mean score of 13.6 ($p = 0.21$). In a comparison linked to PMMA, however, no statistical difference was observed: patients with injuries in the upper limbs treated with IMN + PMMA had a score of 23.125 ($n = 8$) versus the group of patients with injuries in the lower limbs ($n = 13$), with a mean score of 21.46 ($p = 0.69$).

Among the complications related to surgical treatment, we did not observe any statistical difference between the series. In the control group, there were three deaths (one after pulmonary thromboembolism [PE]), one deep surgical site infection, one superficial infection, and one case of decompensated heart failure. In the treatment group with association with PMMA, two deaths were observed (one case after PTE associated with stroke, and one after acute renal failure in a polytrauma patient), two cases of bone cement extravasation (one of these

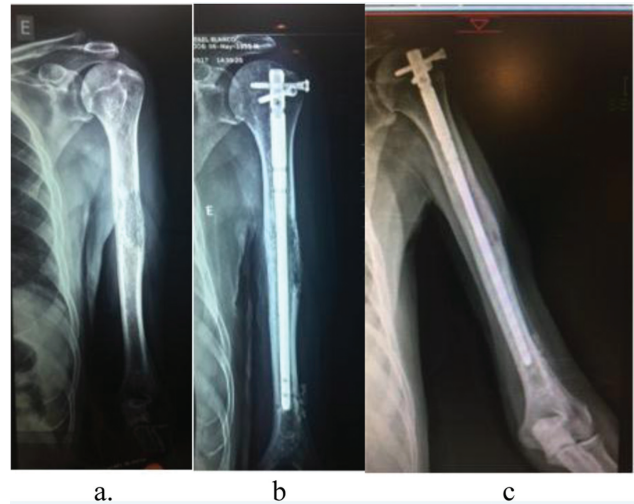

Fig. 3 Pathological fracture of the left humerus. Primary lung adenocarcinoma (A) pathological fracture; (B) fixation with nail and cement; (C) bone union 15 weeks.

cases was examined in the initial surgery, with the removal of extravasated cement), one case of hypokalemia, and two of delirium (→Figs. 2 and 3).

Discussion

The goal of treating pathological lesions is early mobilization, pain relief, and functional recovery as quickly as possible.¹⁸ The Mirels score proved to be an important tool to identify the precise timing of prophylactic fixation of the tumor lesions.¹⁹⁻²¹

Conservative treatment showed the worst results, with higher morbimortality; thus, surgical treatment is the standard treatment for pathological fractures.²² Osteosynthesis showed a lower rate of complications when compared with an endoprosthesis, as it allows immediate support.²³ The use of long nails is the most chosen and indicated method, as it prevents future injuries as the disease progresses. The

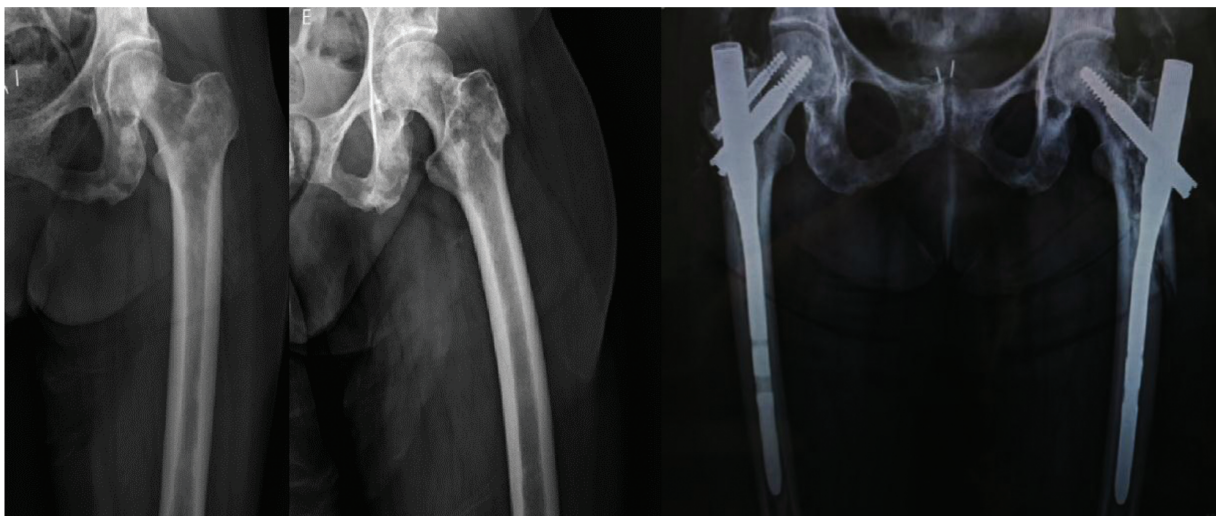

Fig. 2 Metastatic breast cancer lesion in the proximal femur in a 61-year-old patient with transtrochanteric fracture and impending contralateral fracture. The distal locking screw was not necessary due to stabilization with bone cement.

milling procedure of the medullary canal showed biomechanical advantages. The possibility of tumor cell dissemination has not been demonstrated.^{24–27}

The treatment with association with PMMA and IMN has advantages over the standard treatment only with the use of the implant. As the cement occupies the spinal space, bleeding from the lesion is reduced. The cement provides greater mechanical stability to the compound, reducing adjacent bone destruction, and, consequently, pain.^{17,28} Reports show that cement would lead to volume reduction and tumor necrosis caused by thermal injury, as well as to reduced blood supply to the tumor.^{29,30}

Conclusion

Surgical treatment for long bone injuries, especially in palliative cases, aims at rapid pain control and functional recovery. Thus, the association with the percutaneous method of fixation of long bone fractures, with the use of an intramedullary nail associated with cementation with PMMA, proved to be an efficient technique. It presented complication rates similar to those of the traditional method and better functional results, allowing the patient to recover quickly. These results are more prominent in patients with lower limb involvement when compared with patients with upper limb injuries.

Financial Support

There was no financial support from public, commercial, or non-profit sources.

Conflict of Interests

The authors have no conflict of interests to declare.

References

- Harrington KD. Orthopedic surgical management of skeletal complications of malignancy. *Cancer* 1997;80(8, Suppl):1614–1627
- Buggay D, Jaffe K. Metastatic bone tumors of the pelvis and lower extremity. *J Surg Orthop Adv* 2003;12(04):192–199
- Coleman RE. Skeletal complications of malignancy. *Cancer* 1997;80(8, Suppl):1588–1594
- Wedin R, Bauer HC, Wersäll P. Failures after operation for skeletal metastatic lesions of long bones. *Clin Orthop Relat Res* 1999;(358):128–139
- Wedin R, Bauer HC. Surgical treatment of skeletal metastatic lesions of the proximal femur: endoprosthesis or reconstruction nail? *J Bone Joint Surg Br* 2005;87(12):1653–1657
- Sarahrudi K, Hora K, Heinz T, Millington S, Vécsei V. Treatment results of pathological fractures of the long bones: a retrospective analysis of 88 patients. *Int Orthop* 2006;30(06):519–524
- Jaffe KA, Dunham WK. Treatment of benign lesions of the femoral head and neck. *Clin Orthop Relat Res* 1990;(257):134–137
- Shih HN, Chen YJ, Huang TJ, Hsu KY, Hsu RW. Treatment of fibrous dysplasia involving the proximal femur. *Orthopedics* 1998;21(12):1263–1266
- Shih HN, Cheng CY, Chen YJ, Huang TJ, Hsu RW. Treatment of the femoral neck and trochanteric benign lesions. *Clin Orthop Relat Res* 1996;(328):220–226
- van der Hulst RR, van den Wildenberg FA, Vroemen JP, Greve JW. Intramedullary nailing of (impending) pathologic fractures. *J Trauma* 1994;36(02):211–215
- Piccioli A, Maccauro G, Rossi B, Scaramuzzo L, Frenos F, Capanna R. Surgical treatment of pathologic fractures of humerus. *Injury* 2010;41(11):1112–1116
- Ruggieri P, Mavrogenis AF, Casadei R, et al. Protocol of surgical treatment of long bone pathological fractures. *Injury* 2010;41(11):1161–1167
- Sharma H, Bhagat S, McCaul J, Macdonald D, Rana B, Naik M. Intramedullary nailing for pathological femoral fractures. *J Orthop Surg (Hong Kong)* 2007;15(03):291–294
- Piccioli A, Rossi B, Scaramuzzo L, Spinelli MS, Yang Z, Maccauro G. Intramedullary nailing for treatment of pathologic femoral fractures due to metastases. *Injury* 2014;45(02):412–417
- Sun G, Jin P, Liu XW, Li M, Li L. Cementoplasty for managing painful bone metastases outside the spine. *Eur Radiol* 2014;24(03):731–737
- Iannessi A, Amoretti N, Marcy PY, Sedat J. Percutaneous cementoplasty for the treatment of extraspinal painful bone lesion, a prospective study. *Diagn Interv Imaging* 2012;93(11):859–870
- Anselmetti GC. Osteoplasty: Percutaneous Bone Cement Injection beyond the Spine. *Semin Intervent Radiol* 2010;27(02):199–208
- Böhm P, Huber J. The surgical treatment of bony metastases of the spine and limbs. *J Bone Joint Surg Br* 2002;84(04):521–529
- Mac Niocail RF, Quinlan JF, Stapleton RD, Hurson B, Dudeney S, O'Toole GC. Inter- and intra-observer variability associated with the use of the Mirels' scoring system for metastatic bone lesions. *Int Orthop* 2011;35(01):83–86
- Mirels H. Metastatic disease in long bones. A proposed scoring system for diagnosing impending pathologic fractures. *Clin Orthop Relat Res* 1989;(249):256–264
- Damron TA, Morgan H, Prakash D, Grant W, Aronowitz J, Heiner J. Critical evaluation of Mirels' rating system for impending pathologic fractures. *Clin Orthop Relat Res* 2003(415, Suppl):S201–S207
- Katzer A, Meenen NM, Grabbe F, Rueger JM. Surgery of skeletal metastases. *Arch Orthop Trauma Surg* 2002;122(05):251–258
- Laitinen M, Nieminen J, Pakarinen TK. Treatment of pathological humerus shaft fractures with intramedullary nails with or without cement fixation. *Arch Orthop Trauma Surg* 2011;131(04):503–508
- Cole AS, Hill GA, Theologis TN, Gibbons CL, Willett K. Femoral nailing for metastatic disease of the femur: a comparison of reamed and unreamed femoral nailing. *Injury* 2000;31(01):25–31
- Harrington KD, Sim FH, Enis JE, Johnston JO, Diok HM, Gristina AG. Methylmethacrylate as an adjunct in internal fixation of pathological fractures. Experience with three hundred and seventy-five cases. *J Bone Joint Surg Am* 1976;58(08):1047–1055
- Pongracz N, Zimmerman R, Kotz R. Orthopaedic management of bony metastases of renal cancer. *Semin Surg Oncol* 1988;4(02):139–142
- Windhager R, Ritschl P, Rokus U, Kicking W, Braun O, Kotz R. The incidence of recurrence of intra- and extra-lesional operated metastases of long tubular bones. *Z Orthop Ihre Grenzgeb* 1989;127(04):402–405
- Botton E, Edeline J, Rolland Y, et al. Cementoplasty for painful bone metastases: a series of 42 cases. *Med Oncol* 2012;29(02):1378–1383
- Uemura A, Matsusako M, Numaguchi Y, et al. Percutaneous sacroplasty for hemorrhagic metastases from hepatocellular carcinoma. *AJNR Am J Neuroradiol* 2005;26(03):493–495
- San Millán Ruíz D, Burkhardt K, Jean B, et al. Pathology findings with acrylic implants. *Bone* 1999;25(2, Suppl):85S–90S