

DUODENAL ANGIODYSPLASIA: CASE REPORT AND LITERATURE REVIEW

Angiodisplasia duodenal: relato de caso e revisão da literatura

Roberto Pelegrini CORAL, Fabiane P. MASTALIR, Eduardo T. MASTALIR

ABCDDV/542

Coral RP, Mastalir FP, Mastalir ET. Duodenal angiodysplasia: case report and literature review. ABCD Arq Bras Cir Dig 2007; 20(2):127-9.

ABSTRACT – Background - Angiodysplasia is a distinct mucosal vascular lesion associated with acute or chronic gastrointestinal bleeding. It occurs most frequently in the right colon and is extremely rare. Its etiology is unknown, but theories of its pathogenesis have evolved from its similarity to colonic angiodysplasia and the lesion appears to be associated with renal insufficiency. **Case report** - Sixty-five-year-old woman with repeated melena and severe anemia due to angiodysplasia in the first portion of the duodenum. The diagnosis was done by upper endoscopy. As the patient presented repeated gastrointestinal bleeding with hemodynamic instability and recurrent anemia, surgery was indicated. At laparotomy the lesion was identified and resected with an Y-en-Roux reconstruction. The patient went on well at the immediate and late (four years) postoperative periods with no more recurrent gastrointestinal bleeding. **Conclusion**- Although most of the patients suffering from gastrointestinal angiodysplasia goes on well with conservative management, there is a small portion of them that will need a more aggressive approach, as in this case.

HEADINGS - Angiodysplasia. Duodenum. Gastrointestinal bleeding.

INTRODUCTION

Angiodysplasia of the colon is one of the most common causes of the lower intestinal tract in the elderly¹. However, angiodysplasia of the small intestine is rare, but it is an important cause of gastrointestinal bleeding².

Detection of such lesions in the small intestine may be difficult in instances of intermittent or minimal bleeding³. Its etiology is unknown, but theories of its pathogenesis have evolved from its similarity to colonic angiodysplasia and the lesion appears to be associated with renal insufficiency⁴. It is one of the most important differential diagnosis to consider in patients with gastrointestinal bleeding of obscure cause.

CASE REPORT

A 65-year old woman was referred to our service for a surgical consultation because she was suffering of melena and severe anemia. Until that moment, she had presented three episodes of acute upper gastrointestinal bleeding with hemodinamic instability in a twenty days period. In her past medical history she had suffered from an acute myocardial infarction four months before. Furthermore, she has had high blood pressure of hard management.

Physical examination in the emergency room revealed that she was anemic. Laboratory examination revealed marked anemia (hemoglobin 8.5g/dL, hematocrit 25.7%). After she was stabilized by transfusion of two units of packed red cells, she underwent upper endoscopy to investigate the source of bleeding. Upper gastrointestinal endoscopy performed showed two lesions in the first part of the duodenum (Figure 1), from which the gastrointestinal bleeding could have originated, findings compatible with duodenal angiodysplasia. The bleeding was successfully controlled by electrocoagulation in the three episodes of hemorrhage.

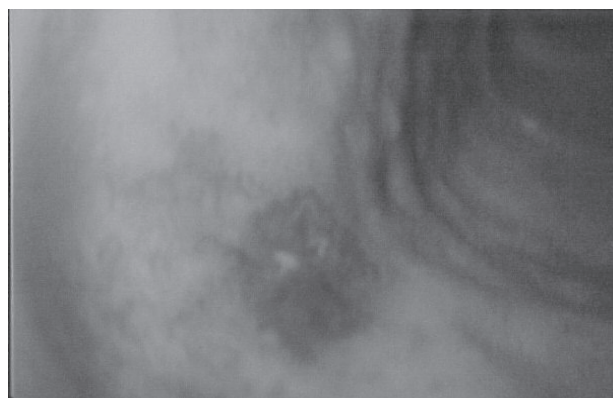


FIGURE 1 - Duodenal endoscopy shows a lesion in the duodenal anterior wall.

From the Department of General Surgery, Hospital Santa Casa de Porto Alegre, Porto Alegre, RS, Brazil
Correspondence: Eduardo T. Mastalir,
e-mail: edumastalir@via-rs.net

The abdominal ultrasound evidenced a small left kidney with no other abnormalities.

The selective arteriography disclosed an obstruction in the left renal artery; there were multiple non-significant stenosis in the mesenteric vessels as well as atherosclerotic plaques in the aorta. The selective arteriography was not possible for the celiac trunk due to severe atherosclerotic plaque, but there were not signs of aberrant circulation in the duodenal area.

With the diagnosis of duodenal angiodysplasia and three previous acute upper gastrointestinal bleeding and hemodynamic instability the patient was undergone to surgical exploration. At the laparotomy there were no significant alterations in the duodenal arterial circulation. After duodenotomy, it was found two spots in the anterior and posterior walls of the first portion of the duodenum, with correspondence to two small arterial branches of the gastroduodenal artery. In this way it was performed an antrectomy and duodenectomy of the first portion. The reconstruction was performed with an Y-en-Roux gastroenterostomy. The pathological examination was conclusive with duodenal angiodysplasia (Figure 2). The patient got on well in the postoperative period and was discharged from the hospital in the tenth day. The patient remains asymptomatic four years after the produce without anemia or melena.

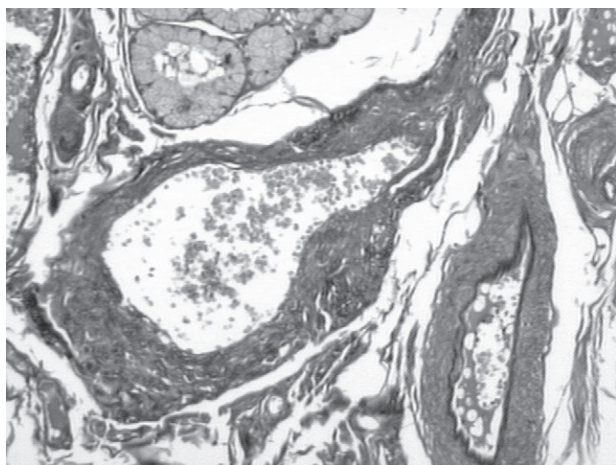


FIGURE 2 - VerHoeff 40X.JPG. Histological examination of the area reveals dilated and distorted vessels with thickened wall in the submucosa, which are typical findings of angiodysplasia

DISCUSSION

Angiodysplasia of the gastrointestinal tract is a major cause of hemorrhage in patients with gastrointestinal bleeding of unknown cause^{1,2,4}.

The lesions of angiodysplasia are generally small, 2-5 mm in diameter, single or multiple, and consist of dilated mucosal capillaries draining into a tortuous submucosal vein. At endoscopy the lesions appear as flat or raised, smooth or irregular, red areas on normal mucosa. They occur most frequently (up to 80%) in the proximal colon and less frequently in the small intestine or upper gastro-

intestinal tract⁵. The lesions can not be seen on barium studies, frequently pass unrecognized at endoscopy, and generally are undetectable at laparotomy⁶. Patients may be symptomless, or present with acute bleeding or iron deficiency anemia⁵.

Once angiodysplastic lesions have begun to bleed, recurrent hemorrhage and persistent iron-deficiency anemia – despite iron supplementation and/or requiring repeated transfusion – are not uncommon. Endoscopy and arteriography are the mainstays of diagnosis⁵. Angiographic findings, such as rapidly filling afferent arterioles, localized, berry-like vascular tufts, and the early filling of engorged veins, are highly suggestive of angiodysplasia^{2,5}. The review of the literature demonstrates that it is the most commonly used diagnostic procedure for this disorder, with rate of false negative results in 12% of the patients who underwent selective arteriography². In this case, angiography was not so effective in revealing these findings, because there were severe atherosclerotic plaque in the celiac trunk.

Precise intraoperative localization still remains a problem, because these lesions are very difficult to identify at operation as they are usually nonpalpable and nonvisible on the serosal surface^{3,7}.

The etiology for these lesions is unknown, but theories of its pathogenesis have evolved from its similarity to colonic angiodysplasia an association with renal failure^{4,8,9}. The pathogenesis of the lesion seemed to be a congenital process in patients younger than 20 years of age. The number of cases increase with every year in people older than 20 years of age, suggesting a degenerative process, then angiodysplasia is presumably an acquired lesion^{2,4}. Supporting this point, the mean age of patients with the finding in either the upper or lower intestinal tract is greater than 60 years-old in most series^{4,9}.

Angiodysplasia has been purposed to occur with higher frequency in patients with renal failure^{8,9}. Several retrospective reports^{4,8}, but not all, show that bleeding from angiodysplasia in patients with renal failure is a common event (19-32%). Lesions are usually multiple and located in the stomach and duodenum, but the jejunum and colon can also be affected. Rebleeding occurs in 25-47% of patients. The degree of evidence indicates that angiodysplasia is an important cause of hemorrhage in patients with chronic renal failure, but it remains to be proved if the incidence of these lesions is higher in this unique subset of patients. It is not known from any study whether formation of angiodysplastic lesions precede or follow onset of renal dysfunction⁹.

The treatment of angiodysplastic lesions that are bleeding or thought to have bled is in principle straightforward, local ablation by endoscopic techniques or surgical resection⁵. Patients with bleeding angiodysplasia are occasionally treated with estrogen and progesterone or, more often, by endoscopic therapy such as endoscopic injection sclerotherapy, monopolar electrocoagulation, contact probes, lasers and endoscopic ligation. For most patients endoscopic treatment has generally replaced surgery as the first line of definitive treatment for angiodysplasias^{1,10}. The

least traumatic approach is endoscopy with plasma-argon photocoagulation, or laser or heat coagulation, for which effective hemostasis in 78% of cases has been reported². Conservative medical management is also reasonable for many patients with gastrointestinal bleeding due to angiodysplasia. Despite a history of significant gastrointestinal hemorrhage, a sustained spontaneous cessation of bleeding can occur in a high percentage of patients with angiodysplasia in the upper gastrointestinal tract¹. Surgery may be indicated if there are many lesions present or if endoscopic treatment is not possible^{5,9}.

At the present case, although the patient had been successfully treated by endoscopy in the acute episodes of bleeding, it was opted to operate her, because she was

persistently anemic and episodes of upper gastrointestinal bleeding were followed by circulatory shock. It would be too much dangerous to leave the lesion in the duodenum because she could suffer from a lethal hemorrhage. The left renal artery stenosis will be managed by the vascular surgery in a second moment.

CONCLUSION

Although most of the patients suffering from gastrointestinal angiodysplasia goes on well with conservative management, there is a small portion of them that will need a more aggressive approach, as in this case.

Coral RP, Mastalir FP, Mastalir ET. Angiodisplasia duodenal: relato de caso e revisão da literatura. ABCD Arq Bras Cir Dig 2007; 20(2):127-9.

RESUMO – Racional - Angiodisplasia duodenal é uma lesão vascular distinta da mucosa intestinal associada com sangramento agudo ou crônico. Embora seja extremamente rara no duodeno, ocorre com maior frequência no cólon direito. Tem etiologia desconhecida, mas sua patogênese parece semelhante com a do cólon. Em alguns casos está associada à insuficiência renal. **Relato do caso** - Paciente de 65 anos de idade com episódios repetidos de melena e anemia severa devido à presença de lesão angiodisplásica na primeira porção do duodeno, cujo diagnóstico fôra estabelecido por endoscopia digestiva alta. Como ela apresentara-se com episódios repetidos de hemorragia digestiva alta acompanhados de instabilidade hemodinâmica, foi-lhe indicada cirurgia. À laparotomia, identificou-se a lesão, que foi ressecada, sendo realizada reconstrução em Y-de-Roux. Evoluiu bem no período pós-operatório imediato e encontra-se sem novos episódios de sangramento 4 anos após a cirurgia. **Conclusão** - Embora a maioria dos pacientes com angiodisplasia gastrintestinal evolua satisfatoriamente com manejo conservador, existe pequena fração que necessitará de abordagem mais agressiva. Neste caso, a paciente apresentou claro benefício da conduta cirúrgica proposta, visto que não apresentou mais episódios de hemorragia digestiva alta.

DESCRIPTORIOS - Angiodisplasia. Duodeno. Hemorragia gastrointestinal.

REFERENCES

1. Aalders GJ, Baeten CG, Loffeld RJ. Suturing angiodysplastic lesions of the small intestine. *Surg Gynecol Obstet.* 1991;173:323-4.
2. Allison D, Hemingway AP. Angiodysplasia: does old age begin at nineteen? *Lancet.* 1981;2:979-80.
3. Clouse RE, Costigan DJ, Mills BA, Zuckerman GR. Angiodysplasia as a cause of upper gastrointestinal bleeding. *Arch Intern Med.* 1985;145:458-61.
4. Foutch PG. Angiodysplasia of the gastrointestinal tract. *Am J Gastroenterol.* 1993;88:807-18.
5. Gilmore PR. Angiodysplasia of the upper gastrointestinal tract. *J Clin Gastroenterol.* 1988;10:386-94.
6. Gunsar F, Yildiz C, Aydin A, Ozutemiz OA. Angiodysplasia in a duodenal diverticulum as an unusual cause of upper gastrointestinal bleeding. *Eur J Gastroenterol Hepatol.* 2001;13:717-9.
7. Hodgson H. Hormonal therapy for gastrointestinal angiodysplasia. *Lancet.* 2002;359:1630-1.
8. Koga H, Lida M, Nagai E, Aoyagi K, Matsumoto T, Takesue M, et al. Jejunal angiodysplasia confirmed by intravascular injection technique in vitro. Report of a case and review of the literature. *J Clin Gastroenterol.* 1996;23:139-44.
9. Lau WY, Won SY, Yuen WK, Wong KK. Intraoperative enteroscopy for bleeding angiodysplasias of small intestine. *Surg Gynecol Obstet.* 1989;168:341-4.
10. Milei J, Bolomo NJ, Pattin M, Pardo R, Lemus JD. Aging jejunal vascular ectasia as a cause of persistent intestinal bleeding. *Arq Gastroenterol.* 1985;22:74-8.

Conflito de interesse: não há

Fonte financiadora: não há

Recebido para publicação em: 19/01/2007

Aceito para publicação em: 02/04/2007