

# THE MODIFIED ROSANOV TECHNIQUE IN THE RECONSTRUCTION OF DIGESTIVE TRACT AFTER TOTAL GASTRECTOMY

*Técnica de Rosanov modificada na reconstrução do trato digestivo após gastrectomia total*

Luiz Roberto **LOPES**, Danielle Menezes **CESCONETTO**,  
João de Souza **COELHO-NETO**, Nelson Adami **ANDREOLLO**

From Department of Surgery and Gastrocentro, Medical Sciences Faculty, State University of Campinas - UNICAMP, Campinas, SP, Brazil.

**ABSTRACT – Background** - Total gastrectomy in gastric cancer is a procedure not without early and late complications and type of reconstruction of the digestive tract to be used is still a controversial issue in literature. **Aim** – To describe a modified Rosanov technique after total gastrectomy, employed with the aim of minimizing the intestinal malabsorption and other complications following this procedure. **Method** - Technical modification is not to hold distal ligature on jejunum-duodenal anastomosis, thereby offering to the food transit two routes by the duodenum and by the jejunum. **Results** – There were no complications and the initial series showed a benefit in the nutritional aspects after six months of postoperative follow-up. **Conclusion** – It is a simple technique and preliminary results with its use were very satisfactory, although other clinical studies must be conducted to demonstrate the advantages of the technique in the long term.

**HEADINGS** - Gastric neoplasm. Surgery. Malabsorption.

## Correspondence:

Luiz Roberto Lopes,  
e-mail: lopes@fcm.unicamp.br

Source of funding: none  
Conflict of interest: none

Received: 29/04/2011  
Accepted for publication: 25/05/2011

**DESCRITORES** - Neoplasia gástrica. Cirurgia. Má absorção.

**RESUMO – Racional** – A gastrectomia total nas neoplasias gástricas é um procedimento não isento de complicações precoces e tardias e o tipo de reconstrução do trato digestivo a ser utilizado é ainda questão controversa na literatura. **Objetivo** - Descrever a técnica de Rosanov modificada, após a gastrectomia total, empregada com o objetivo de minimizar a má absorção intestinal e outras complicações após este tipo de procedimento. **Métodos** – A modificação técnica consiste de não realizar a ligadura distal à anastomose jejunum-duodenal, fazendo assim com que o trânsito alimentar tenha duas vias de passagens, pelo duodeno e pelo jejunum. **Resultados** – Não foram registradas complicações e a casuística inicial mostrou vantagens sob os aspectos nutricionais após seis meses de seguimento pós-operatório. **Conclusão** – É técnica de fácil execução e os resultados preliminares com o seu emprego foram muito satisfatórios, no entanto outros estudos clínicos devem ser realizados para demonstrar as vantagens da técnica a longo prazo.

## INTRODUCTION

A total gastrectomy is indicated in patients who have gastric cancer located in the body, fundus, cardia, linitis and cancer of the gastric stump. The first successful operation is assigned to Schlatter in Zurich - Germany, in 1897, which carried out the reconstruction of digestive transit in the jejunum using omega-esophageal anastomosis with jejunal termino-lateral<sup>16</sup>. In Brazil, was first performed by Arnaldo Vieira de Carvalho in São Paulo in February 1900<sup>19</sup>.

Since then the surgeons had more than one therapeutic method for gastric cancer, albeit with few encouraging results, since the operative complication rate was very high. In the 40s and 50s, Lahey et al.<sup>7</sup> in Boston

popularized the procedure, recommending total gastrectomy as a routine treatment. In Brazil it was broadcast by Fernando Paulino<sup>12</sup>. However, mortality remained high and was not registered a significant increase in long-term survival.

Currently, the technique of total gastrectomy most used is the result of studies of the Japanese Society for Gastric Cancer Research, which has standardized the limits and the possible variations for the resection extended to surrounding organs of the stomach, as well as levels of lymphadenectomy<sup>10</sup>.

Over the years have been proposed by several authors over 50 models of digestive tract reconstruction after total excision of the stomach, indicating in one hand the rich imagination of surgeons; however, on the other hand, there is no technique with universal acceptance. Deserves merit Cesar Roux in 1893 that created the loop in Y<sup>13</sup>; Brigham in 1898, who rebuilt the transit with esophageal-duodenal anastomosis<sup>1</sup>; Longmire-Beal in 1952 began to perform anastomosis esophageal-jejunal termino-lateral<sup>5</sup> and Lefèvre<sup>8</sup>. In Brazil, Safatle propose the technique in a duodenal-jejunal anisoperistaltic pouch<sup>14</sup>.

Thus, if the reconstruction after total gastrectomy for gastric cancer should be done with or without some kind of reservoir or supply of the duodenum in transit is a controversial issue in clinical research, ie, still was no consensus on the reconstruction technique of choice<sup>2</sup>.

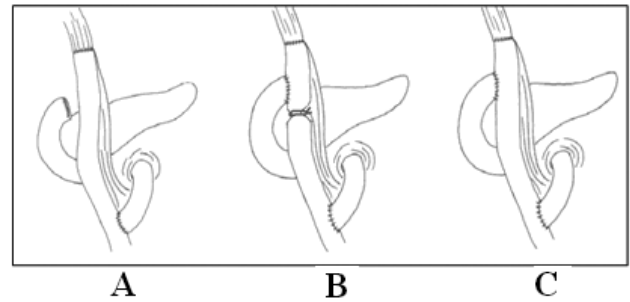
However, a technique described by Rosanov in 1958 does the reconstruction in Roux-en-Y with jejuno-duodenal anastomosis latero-terminal<sup>4</sup>. The references in the literature on this technique are not numerous<sup>6,15,18</sup>.

The aim of this paper is to describe a modified technique of Rosanov after total gastrectomy, combined with the objective of minimizing the intestinal malabsorption after this procedure.

## TECHNIC

The original technique described by Rosanov after total gastrectomy was to make the esophagus-jejunal anastomosis and jejuno-jejunal the manner of Roux-en-Y classic (Figure 1A). However, also performed a duodenal-jejunal anastomosis latero-terminal, introducing the duodenum in gastric transit, and after this a last anastomosis introducing a distal ligation, according to Figure 1B.

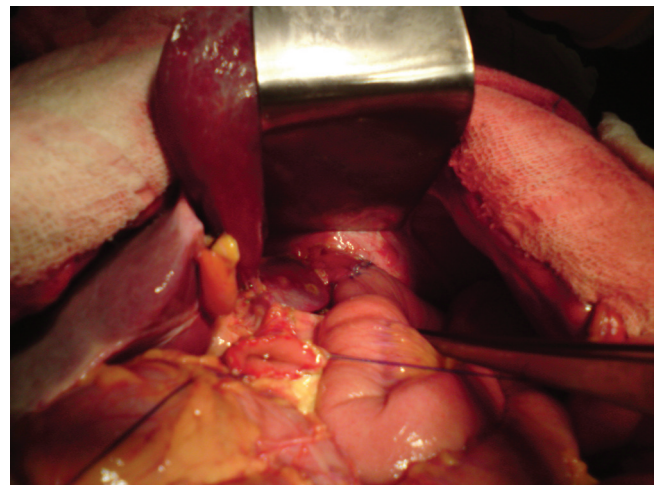
The change that these authors have introduced is to perform the same technique, however, without performing the ligation of distal duodenal-jejunal anastomosis, thereby making the food transit routes pass through two ways, the duodenum and the



**FIGURE 1** –Techniques for reconstruction of intestinal transit after total gastrectomy (A - Roux-en-Y; B - Rosanov Technic; C - Modified Rosanov technic)

jejunum (Figure 1C).

The reconstruction technique that is called Rosanov changed after total gastrectomy, consists of the following technical steps: 1. perform the usual total gastrectomy, and in this procedure, the duodenal stump cut is held open, well vascularized and prepared to be anastomosed with the jejunum; 2. intersects transversally the proximal jejunum, about 20 to 25 cm after the duodenojejunal angle, preserving the vascular arcades of both segments and then the distal segment is closed with sutures of 3-0 polypropylene sutures; 3. proceeds to the esophagus-jejunal anastomosis termino-lateral way of Roscoe-Graham, with the option presented here is to implement pre-colic jejunal loop (Figure 2); 4. jejunal-duodenal anastomosis, about 30 cm distal to the anastomosis above, with separate nonabsorbable suture (Figures 3 and 4); 5. reconstruction of the transit is completed, performing jejuno-jejunal termino-lateral Roux-en-Y classic anastomosis.



**FIGURE 2** – Esophagus-jejunal anastomosis termino-lateral ended and duodenal stump open and prepared for jejunum anastomosis

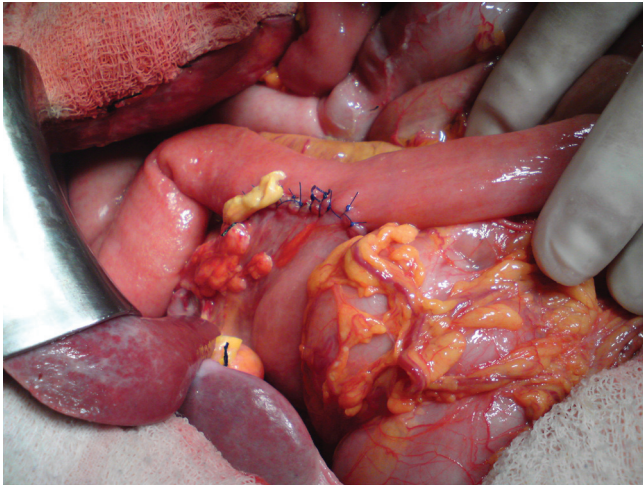


FIGURE 3 – Ended jejunoduodenal anastomosis latero-terminal

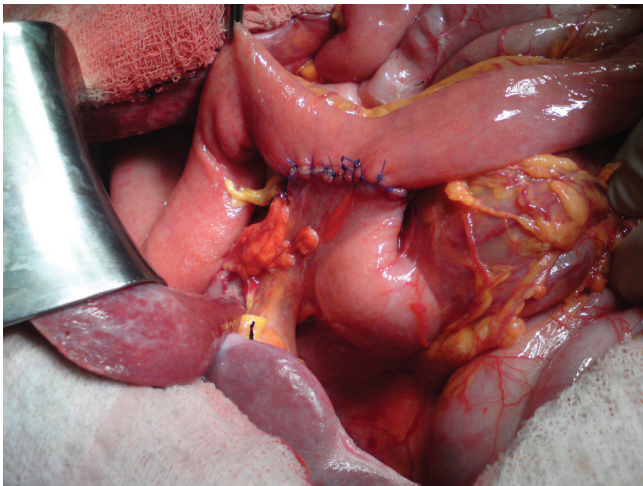


FIGURE 4 – Ended jejunoduodenal anastomosis latero-terminal

## DISCUSSION

Total gastrectomy is a procedure with early complications such as fistulas and abscesses, and late ones such as diarrhea, anemia and malnutrition. The type of reconstruction of the digestive tract to be used is still a controversial issue in literature. Morbidity and mortality are not negligible, requiring surgical team and an improved surgical technique.

The steatorrhea after total gastrectomy can occur in significant numbers of patients, and its pathogenesis depends on many possible combinations of techniques and reconstruction of traffic that could alter the anatomy and physiology of the digestive tract. In this sense, there are many factors that contribute to aggravate this complication: intestinal bacterial overgrowth, intestinal transit time fast due to the loss of the gastric pouch and pylorus ineffective mixture of enzymes and bile salts to food, inadequate stimulus

for neurohormonal pancreas and a lower surface of absorption, as a result of the excluded segment of small intestine. Anemia is another complication that affects patients who underwent total gastrectomy due to lack of intrinsic factor and difficulty in absorbing this mineral<sup>2,6,11</sup>.

The most commonly used technique for reconstruction of transit after total gastrectomy is still the Roux-en-Y due to its simplicity and low risk of duodenal stump fistulas, and good quality of life in long-term<sup>11</sup>. The Rosanov technique is similar to it, and instead of burying the duodenal stump, takes place latero-terminal anastomosis between the jejunum and duodenum, followed by ligation of the distal jejunum, hoping in this way that malabsorption of nutrients and steatorrhea would be minimized due to take place food transit through the duodenum. However, there are few reports about this alternative technique, published in 1958. It is among the few techniques in which all the food bolus passes through the digestive tract without duodenal exclusion, without the need to build a reservoir and without esophageal-duodenal anastomosis. It is believed that this type of reconstruction is a modality that should contribute to better nutritional status in the postoperative period. The change made by the authors in the technique was originally described to suppress the external jejunal ligation (Figure 1C).

Experimental research developed in Brazil by Seva-Pereira et al.<sup>17</sup> in rats, using steatocrit as simple method for measuring the fat in the stool after total gastrectomy with reconstruction of the transit with modified technique Rosanov compared with Roux-en-Y classical; control animals showed lower levels of steatorrhea with Rosanov technique, very similar to those of non-operated animals.

This technique is easier to be performed compared to pouch techniques. Furthermore, it was conducted laboratory and clinical evaluation in 43 patients undergoing total gastrectomy for over six months, 32 of them with reconstruction by Roux-en-Y and 11 by Rosanov technique, with 22 individuals in the control group who were not operated. Measurements of hematocrit and hemoglobin, serum iron, ferritin, and serum albumin steatocrit were done. There were no leaks and no postoperative complications in this series. In the clinical evaluation were investigated body mass index, nausea and vomiting, heartburn, reflux, postprandial bloating, anorexia and the daily number of evacuations.

This study signalizes that the preservation of duodenal transit offers advantages such as better mixing food with enzymes, increased fat absorption, lower prevalence of symptoms such as bloating, diarrhea, heartburn, and anorexia, and a better standard of laboratory tests<sup>9</sup>.

## CONCLUSION

Preliminary results with this technique were satisfactory, although other clinical studies must be conducted to demonstrate the advantages of it in long term follow-up.

## REFERENCES

1. Brigham CB. Case of removal of the entire stomach for carcinoma. Philadelphia Med J 1900; 5:247.
2. Freitas ACT, Dias JM, Okawa L, Coelho JCU. Análise da margem cirúrgica proximal do estômago em pacientes submetidos à gastrectomia subtotal por adenocarcinoma. ABCD Arq Bras Cir Dig. 2008; 21(3):106-109.
3. Graham RR. A technique for total gastrectomy. Surgery, 1940;8(2) 257-264.
4. Hepp J, Pernod R. - Conservation du transit duodenal après gastrectomie par interposition jejunaie. Le procédé de Rosanov. Presse Medicale 1958; 29: 65-6.
5. Hokschi B, Muller JM. Complication rate after gastrectomy and pouch reconstruction with Longmire interposition. Zentralbl Chir 2000; 125(11):875-9.
6. Huguier M, Lancret JM, Bernard PF, Baschet C, Le Henand F. Functional results of different reconstructive procedures after total gastrectomy. Br J Surg. 1976;63(9):704-8.
7. Lahey FH, Marshall SF. Should total gastrectomy be employed in early carcinoma of the stomach; experience with 139 total gastrectomies. Ann Surg. 1950;132(3):540-65.
8. Lopes F, Reis AF, Côrtes BJW, Fabrini DS, Lima HR, Rocha LCG. Esofagojejunosomia após gastrectomia total: anastomose mecânica ou manual? Rev Col Bras Cir. 2008; 35(5):298-230.
9. Lopes LR, Cesconetto DM, Ribeiro F, Coelho Neto JS, Andreollo NA. Clinical and laboratorial evaluation of the steatorrhea using the steatocrit in patients submitted to Roux-en-Y and modified Rosanov technique after total gastrectomy. The 8th International Gastric Cancer Congress, Krakow, Poland, 2009.
10. Maruyama, K.; Okabayashi, K. & Kinoshita, T. – Progress in Gastric Cancer Surgery in Japan and its limits of radicality. World J Surg 1987; 11:418-425.
11. Murawa D, Murawa P, Oszkini G, Biczysko W Long-term consequences of total gastrectomy: quality of life, nutritional status, bacterial overgrowth and adaptive changes in esophagojejunosomatic mucosa. Tumori. 2006;92(1):26-33.
12. Paulino F, Roselli A. Carcinoma of the stomach. With special reference to total gastrectomy. Curr Probl Surg. 1973:3-72.
13. Roux C. De la gastroenterostomie. Revue de chirurgie, 1893;13: 402-403
14. Safatle NF. Bolsa duodenojejunal antiperistáltica na reconstrução do trânsito digestivo após gastrectomia subtotal e na síndrome pós-gastrectomia: técnica. Arq Gastroenterol. 1984, 21(2): 59-67.
15. Scarabelli L, Bonandrini L. Rosanov's procedure after total gastrectomy for cancer. Minerva Med. 1975;66(68):3589-91.
16. Schlatter C. Vollständige entfernung des magens, oesophagoenterostomie beim Mensch. Beitr Klin Chir 1897; 19:757
17. Seva-Pereira G, Lopes LR, Brandalise NA, Andreollo NA. - Fat absorption after total gastrectomy in rats submitted to Roux-en-Y or Rosanov-like double-transit technique. Acta Cir Bras 2006;21(6):380-4.
18. Vernhet J, Bonnel F. Apropos of the recovery of digestive continuity after total gastrectomy. Critical study of the Rosanov method. Arch Fr Mal App Dig. 1971;60(3):158.
19. Vieira de Carvalho A. A case of total gastrectomy. Lancet 1900; 2:798-9.