

## INCREASE IN SPLEEN VOLUME OF RATS ON EXPERIMENTAL MODEL OF PRE-HEPATIC PORTAL HYPERTENSION

*Aumento do volume do baço em modelo experimental de hipertensão portal pré-hepática em ratos*

Aline Riquena da **SILVA**, Ricardo José **KRIGUER-JÚNIOR**, Leonardo Carvalho **SERIGIOLLE**, Helbert Minuncio Pereira **GOMES**, Daren Athiê Boy **RODRIGUES**, Pedro Luiz Squilacci **LEME**

From the Advanced Surgical Skills Laboratory, Integrated Simulation Nucleus Doctor Luiz Roberto Barradas Barata (NIS), University Nove de Julho, São Paulo, SP, Brazil.

**ABSTRACT - Background:** Pressure increase in the portal venous system, caused by reduction of blood supply to the liver, develops collateral circulation of splanchnic vessel that reaches the venous system of superior vena cava. The spleen works as an auxiliary capacitance system which compensates the increase in portal pressure that may cause splenomegaly. **Aim:** To reproduce experimental model of pre-hepatic portal hypertension by reducing the caliber of the vein, allowing the study of alterations in the rat's spleen in this situation. **Methods:** Fifteen Wistar rats were divided into three groups of five. All animals were operated, being the first five used as control (group 1) and reoperated after 15 days (sham-operated), along with five other animals had portal hypertension induced (group 2). The last five animals, also with portal hypertension were reoperated after 30 days (group 3). Prehepatic portal hypertension was caused in experimental animals by partial ligation of portal vein in hepatic hilum. The spleen was measured during the first and second operations, allowing the calculation of its volume in the three groups studied using specific mathematical formula. **Results:** No macroscopic changes in spleen were significant when compared the animals reoperated after 15 days (group 2) to the ones after 30 days (group 3), being 15 days considered enough for the evaluation of effects on spleen after partial ligation. Although the volume of spleens studied in groups 2 and 3 have increased after the first operation - ranging on average from 0.5417 cm<sup>3</sup> to 0.6345 cm<sup>3</sup> at reoperation with increase of approximately 17% in volume between the first and second phase - the results were not statistically significant ( $p > 0.05$ ). **Conclusion:** There was no statistically significant increase in the spleen volume after partial ligation of the portal vein when comparing the calculated volume in the first operation to the volume found at reoperation. There was no difference when comparing the spleen volumes of the animals reoperated after 15 days and the ones reoperated after 30 days.

**HEADINGS** - Hypertension, portal. Portal vein. Portal system. Splenomegaly. Models, animal.

### Correspondence:

Aline Riquena da Silva,  
E-mail: alineriquena@hotmail.com

Financial source: none  
Conflicts of interest: none

Received for publication: 15/01/2013  
Accepted for publication: 16/04/2013

**RESUMO - Racional:** O aumento da pressão no sistema venoso portal, induzido pela redução do aporte sanguíneo ao fígado, provoca o desenvolvimento de circulação colateral para que o sangue dos vasos esplâncnicos alcance o sistema venoso da veia cava superior. O baço funciona como um sistema de capacitância que auxilia a compensação do aumento da pressão portal, podendo ocorrer esplenomegalia. **Objetivo:** Reproduzir modelo experimental de hipertensão portal pré-hepática por meio da redução do calibre da veia porta do rato, permitindo o estudo das alterações de volume do baço nesta situação. **Método:** Foram utilizados 15 ratos da linhagem Wistar, divididos em três grupos de cinco. Todos os animais foram operados; os primeiros cinco foram utilizados como controle (grupo 1), e reoperados após 15 dias (sham-operated), assim como cinco animais onde foi induzida a hipertensão portal (grupo 2). Os cinco últimos animais, também com hipertensão portal, foram reoperados após 30 dias (grupo 3). A hipertensão portal do tipo pré-hepática foi provocada através da ligadura parcial da veia porta no hilo hepático. O baço foi medido durante a primeira e a segunda operação, permitindo o cálculo de seu volume nos três grupos estudados através de fórmula matemática específica. **Resultados:** Não foram encontradas diferenças macroscópicas significativas ou alterações maiores do volume do baço quando foram comparados os animais que foram reoperados após 15 dias (grupo 2) e os reoperados após 30 dias (grupo 3), sendo considerado o prazo menor (15 dias), suficiente para avaliação das repercussões no volume após a ligadura parcial da veia porta. Embora o volume

dos baços estudados tanto no grupo 2 quanto no grupo 3 tenha aumentado após a primeira operação - variando em média de 0,5417 cm<sup>3</sup> para 0,6345 cm<sup>3</sup> na reoperação, com aumento de aproximadamente 17% entre a primeira e a segunda fase do estudo -, estes resultados não apresentaram significância estatística ( $p > 0,05$ ).

**Conclusão:** Não houve aumento com significância estatística do volume do baço após a ligadura parcial da veia porta quando se comparou o volume calculado na primeira operação com o volume encontrado na reoperação. Também não houve diferença quando foram comparados os volumes dos baços dos animais do grupo de reoperados após 15 dias, com o grupo reoperado após 30 dias.

**DESCRITORES** - Hipertensão portal. Veia porta. Sistema porta. Esplenomegalia. Modelos animais

## INTRODUCTION

Vascular resistance in the portal vein and its tributaries is increased in portal hypertension with dilated veins in the splanchnic region and develop collateral circulation, to permit the blood flow to reach the superior cava vein. This may be associated with pre, intra or post-hepatic diseases<sup>1,6,17</sup>.

Although there are other locations for the communication of collateral blood vessels to the systemic circulation, one important route for drainage of the portal venous system occurs with the reversal of blood flow in the left gastric vein, by the vessels of the submucosa of the stomach and esophagus; with this way, the blood reaches the azygos vein. In order to decrease the venous pressure in the system, dilatation and tortuosity of the veins occur and the changes in this blood flow lead to a hyperdynamic circulatory state with release of vasoactive substances by the endothelium, both vasodilator and vasoconstrictor, acting on vessels musculature<sup>17</sup>. For the increase of the amount in this collateral circulation, angiogenesis occurs and the development of new blood vessels contributes to the decompression of portal flow<sup>1</sup>. The portal pressure of small rodents may be measured in millimeters of mercury<sup>17</sup> (mmHg) or centimeters of water<sup>3</sup>, in a way that it is possible to have values between 3 and 6 cm of water in the control groups of animals with small weight. In the rat, Wen et al.<sup>22</sup> found portal pressure of approximately 9 cm of water. Yokoyama et al.<sup>24</sup>, evaluating this pressure in mmHg, also in rats, found portal pressure close to 5 mmHg and when they underwent partial ligation of this vein, pressure increased to approximately 13 mmHg.

The experimental model that employs partial portal vein ligation can be developed quickly, it has a low cost and does not compromise the hepatic function<sup>17,22</sup>. It also allows the evaluation of the interaction between the flow and the resistance of the portal venous system, as well as the relationship between the development of hyperdynamic circulation with an increase in the flow of the studied system<sup>17</sup>. After this partial ligation, portal pressure reaches a peak within the first 24 hours, increasing about four times and stabilizing twice at the baseline after 15 days with splanchnic vessels dilatation, keeping stable at these levels for prolonged periods, as

six to ten weeks, even after the appearance of these collateral vessels<sup>22</sup>.

When the partial ligation of the portal vein is performed, there is an increasing cardiac output and plasma volume; a decrease in the systemic vascular resistance and in the vascular response to vasopressors, proving repercussions both in splanchnic and systemic circulation. Though not significant impairment of its function, the circulation of the liver has to adapt to prolonged reduction of blood flow through the portal vein, since the blood supply through the hepatic artery and the portal vein is independently regulated<sup>24</sup>.

The portal blood flow is determined by the resistance of the splanchnic vessels and by the drained blood from organs of this area<sup>9</sup> without control of this venous blood input to the liver. Changes in organ perfusion are made by the hepatic artery, which results in increased arterial flow when there is a decrease of portal flow. This is attributed to compensatory mechanism to decreased clearance of liver adenosine, leading to hepatic artery dilatation. The effects of persistent decrease of blood supply, such as in this model of decreased portal vein caliber, have still been studied, stating that hepatic structural and functional changes occur in vessels of both, mesentery and abdominal cavity, as well as the occurrence of angiogenesis and adaptations of the microcirculation. The large neovascularization that appears on hepatic hilum, near the hepatic artery, acquire similar characteristics to arterioles, making it an important via of blood supply to the liver. The diameter of these vessels may differ from 8 to 60  $\mu\text{m}$ <sup>13,19,22</sup>.

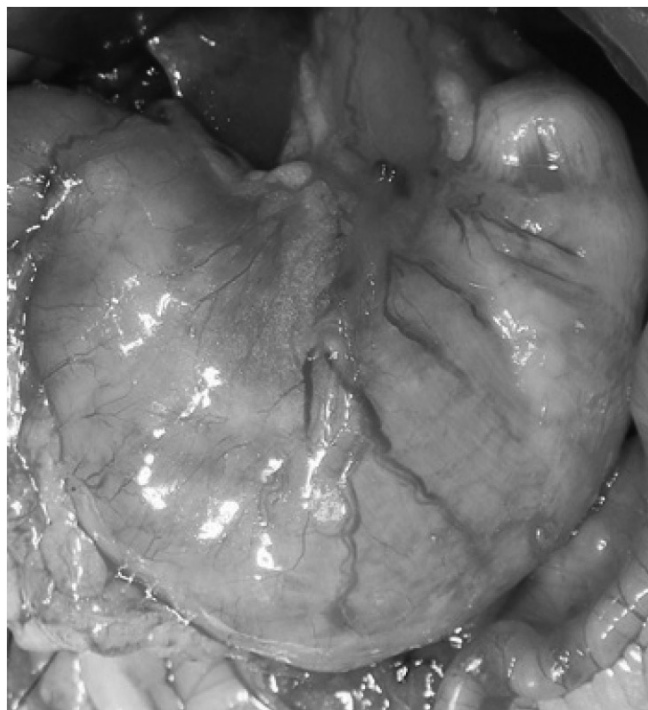This experimental model aims at inducing the appearance of pre-hepatic portal hypertension in rats by reducing the caliber of the animal's portal vein, in order to evaluate changes in the spleen volume.

## METHODS

This study was conducted at the Advanced Surgical Skills Laboratory, Integrated Simulation Nucleus Doctor Luiz Roberto Barradas Barata (NIS), University Nove de Julho, São Paulo, SP, Brazil, being conducted in accordance with the Federal Law 6.638 of May 1979 and assessed by the Ethics Commission on Animal Use (CEUA) of the University (protocol 0040 / 2012).

A total of 15 animals (*Rattus Norvegicus Albinus*),

Wistar, female, young adult, weighing on average 250-300 g, in good nutritional status, were divided into three groups of five animals each, classified according to type of surgery and time to reoperation. Thus, was obtained the group 1 (sham-operated), used as control, and two other groups that were pre-hepatic portal hypertension induced by reduction of portal vein caliber. Five animals were reoperated after 15 days (group 2) (Figure 1) and another five after 30 days (group 3).



**FIGURE 1** - Effect of portal hypertension induced by partial portal vein ligation in rats 15 days after the first operation (group 2)

Before and after the completion of the operative procedures, the animals were kept in individual cages with access to water and standardized ration ad libitum, at 25 °C, cycles of light and dark every 12 hours and fasted for 12 hours before the experiment. Prior to operative procedures the animals were weighed.


The rats were anesthetized with intraperitoneal injection of ketamine (50 mg/kg) and xylazine (10 mg/kg). Laparotomy was performed, the intestinal loops were retracted and the hepatic hilum exposed. Portal vein was dissected near the confluence of the superior mesenteric vein and splenic vein (Figure 2). With a caliper rule, diameter and length of portal vein, width and thickness of the spleen were measured using as reference the splenic vein, for later comparison of values. In the control group (sham-operated), the procedure was terminated at this stage and the anterior abdominal wall sutured in layers with 4-0 nylon sutures. The animals were maintained in a vivarium for 15 days to undergo a second operation to evaluate the appearance of abdominal viscera and

to, once again, perform the steps of the spleen and the portal vein measurement. In group 2 (15 days) and group 3 (30 days), partial ligation of portal vein was performed at the first operation with silk thread for ophthalmic use numbers 6-0. This partial ligation was possible by means of a fluoretilenpropilen catheter 22G (Jelco®), which has an internal diameter of 0.9 mm (Figure 3A). With the silk thread, partial ligation of vein was performed (Figure 3B) and after quick and efficient surgical knot, in order to prevent the formation of thrombus, the catheter was removed, allowing the reduction of the venous flow to the liver. After removal of the catheter, the efficacy of partial ligation of the vein was confirmed by observing the increase in the diameter of the vessel prior to ligation (Figure 4A and 4B). The abdominal wall was sutured as described above and the animals returned to the vivarium, where group 2 remained for 15 days and group 3 for 30 days, when they were reoperated.

After these periods of 15 or 30 days, all rats were weighed, anesthetized and underwent surgery to assess macroscopic changes of the abdominal organs. Length, width and thickness of the spleen (Figures 5A, 5B, 5C) were measured once more as well as the diameter of the vein below the ligation carried out during the first operation. The portal vein was cut above the ligation for evidence of blood flow, demonstrating the absence of a complete obstruction.

The evaluation of the percentage of reduction in the diameter of the portal vein can be done with mathematical formula that defines the rate of the vessel constriction  $(1 - \pi r^2/\pi R^2) \times 100\%$ , where the smallest radius ( $r$ ) corresponds to the catheter and the largest ( $R$ ) to the animal portal vein<sup>22</sup>.

The spleens volume were calculated from specific mathematical formula:  $V=4/3 \times \pi \times (r1 \times r2 \times r3)$ , wherein the variables  $V$ ,  $r1$ ,  $r2$ ,  $r3$  represent the volume and the radius length, width and the thickness, since the body may be compared to a three-dimensional elliptical geometric figure (ellipsoid)<sup>21</sup>, shown in Figure 6. Groups 1, 2 and 3 were compared and the results found in operative procedures were divided into two subgroups, designated A, the result of the first operation, and B, results of reoperation.



**FIGURE 2** - Dissection of the hepatic hilum performed in three groups of animals

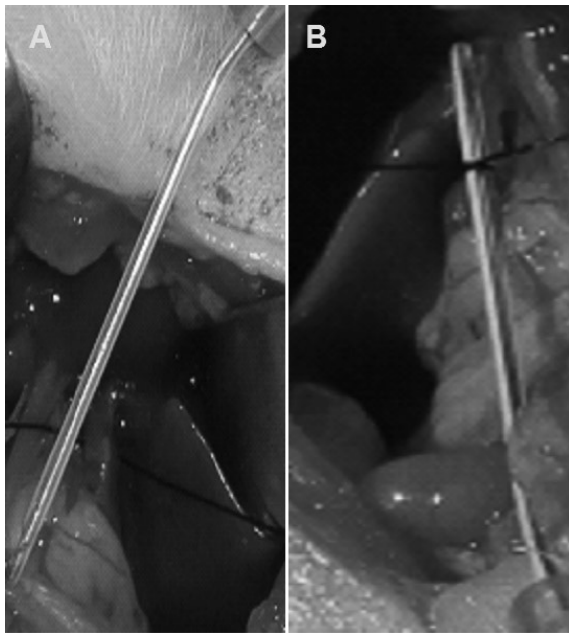


FIGURE 3 - Fluoretilenpropilen 22G catheter (Jelco®) with an internal diameter of 0.9 mm (A) and transverse vein ligature with 6-0 silk thread on the catheter (B)

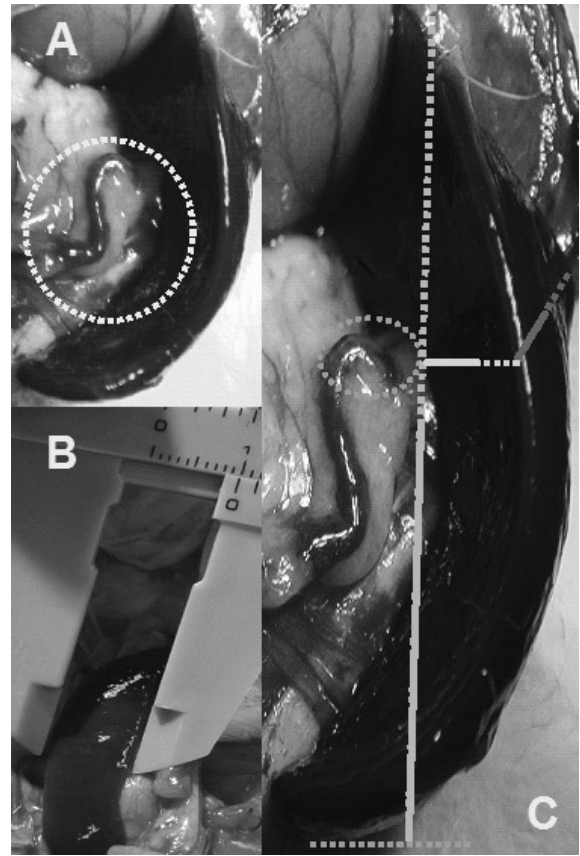


FIGURE 5 - Splenic vein (A) serving as a reference for the measurements (B) and the scheme for calculating the radius measures of the length, width and thickness of the spleen (C) fifteen days after the first operation (Group 2)

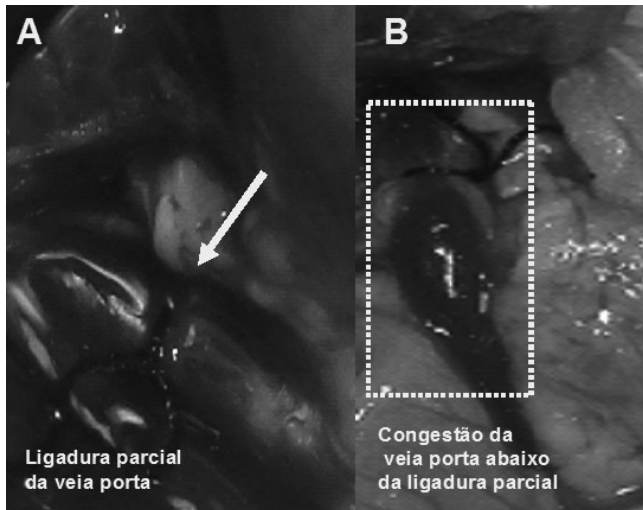


FIGURE 4 - Partial ligation of vein (A) and vessel diameter increased before ligation (B)

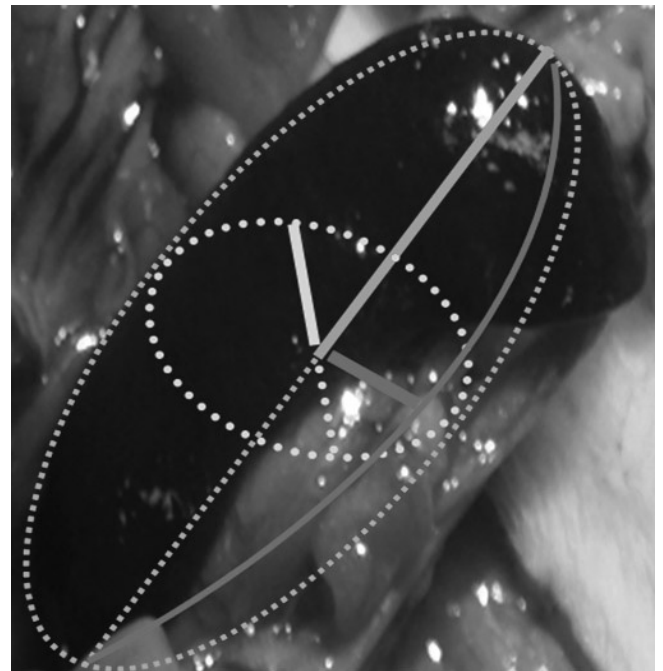


FIGURE 6 - Scheme of the ellipsoid shape of the spleen that allows the calculation of its volume through specific mathematical formula

For each subgroup arithmetic mean was calculated, and results later compared through statistical analysis by Student's t test, considering significant  $p < 0.05$  (equivalent to an  $\alpha$  error of 0.05), to prove the occurrence or not of statistically significant difference in spleen volume.

## RESULTS

Comparing the animals reoperated after 15 days (group 2) and the reoperated ones after 30 days (group 3), no significant macroscopic differences or major changes in spleen volume were found. The shorter period (15 days) was considered enough to the assessment of the impact in the spleen volume after partial ligation of the animal's portal vein<sup>2</sup>. Although the spleens volume studied both in Group 2 and in Group 3 have increased after the first operation, ranging on average from 0.5417 cm<sup>3</sup> to 0.6345 cm<sup>3</sup> in reoperations, which an increase of approximately 17 % in volume between the first and second phase, the differences were not statistically significant ( $p > 0.05$ ).

## DISCUSSION

The collateral circulation established between the portal system and the systemic circulation can develop in several locations. Wen et al.<sup>22</sup> estimated a portal blood flow deviation of approximately 95% when partial ligation of portal vein is performed. Two weeks after this procedure, venous dilatation in the mesenteric vein was observed. Collateral vessels between the spleen and left kidney, between the mesenteric vein and the posterior peritoneum were found, as well as in the hepatic hilum whose vessels become more apparent six weeks after of the experiment. The left adrenal vein showed to be increased, representing an important collateral way between the splanchnic and systemic circulation<sup>22</sup>. Significant dilation of the superior mesenteric vein and its branches were found here, either in two or four weeks after portal constriction and numerous dilated vessels, tortuous and congested, were found in peritoneal cavity, mesentery, omentum and abdominal wall of the animals.

The experimental model of partial portal vein ligation in rats was developed by Sikuler et al. in 1985<sup>20</sup>. The study of pre-hepatic portal hypertension induced by partial portal vein ligation is important to the evaluation of hyperdynamic collateral circulation that develops in the splanchnic portion. Such results are generally evaluated two weeks after this partial ligation, when a certain balance of parameters occurs, since the dilation of the veins and spleen contributes to the stabilization of pressure which remains longer and yet with increased values. Wen et al. studied the importance of the pressure stability in this experimental model confirming the constancy of the parameters even after

longer periods of the animals' observation, not allowing the portal pressure to return to baseline, independently of the appearance of collateral circulation. In classical experiments, portal pressure is reduced by the second week after the initial operation, keeping increased and stable even over ten weeks after initial operation, confirming the effectiveness of the model for these evaluations<sup>22</sup>.

The increased portal pressure can be obtained by partial vessel constriction and increased resistance to blood flow in the vein<sup>22</sup>. The diameter of the portal vein in humans can be assessed with ultrasound and Doppler effect, automatically by the equipment's software program, based on the spectral trace Doppler<sup>23</sup>. Considering an average diameter of 2 mm for the portal vein of the studied animals, a value close to that described in the literature<sup>22</sup>, and the diameter of 22G catheter used in this experiment, that has a diameter of 0.9 mm, the mathematical formula which defines the veins rate of constriction<sup>22</sup> could be used. It was possible to reduce 55% on average the internal diameter of the portal vein, which produces an immediate increase in portal pressure estimated at four times the baseline value. After two weeks this pressure stabilizes in approximately twice the baseline value and remains at this level for longer periods, demonstrating that this model is reliable, keeping pressure stable even in the period when the tributary vessels of the portal vein have already developed. When catheters with a diameter of 1 mm are used, the mortality is low, but the changes in portal pressure are small and do not contribute adequately to the experimental model<sup>22</sup>.

The percentage of volume reduction in the portal vein is a critical factor for the animal's survival<sup>22</sup>. Its complete ligation causes death in about an hour. This study had acceptable mortality and, even aware that complete obstruction of the vein would be incompatible with survival, there was concern in assessing if portal vein was patent in reoperation, counting on the possibility of thrombosis after the establishment of collateral circulation. All animals that completed the study period had adequate portal blood flow. Wen et al.<sup>22</sup>, using catheter of diameter 0.7 mm (24G) got results of 80% animal mortality and 100% when smaller diameters were used. The mortality rate decreased between 20 to 30% when catheters with a diameter of 0.8 mm (21G) were used, corresponding to a decrease in the vein diameter of approximately 88.9%. In this study, with a catheter of 0.9 mm (22G), and reduction of approximately 55 % of the vein, satisfactory results were obtained in both, animals reoperated after two and after four weeks, with low mortality<sup>5,8,12</sup>.

Regarding the partial ligation of the portal vein technique, there are also some options available<sup>14</sup>. Fabián et al.<sup>7</sup>, Méndez-López et al.<sup>15</sup> described a tactic to increase this vein constriction and thus the initial resistance to blood flow, using three equidistant bands, considering this option more effective than single

ligation, which increased the development of collateral circulation. The use of an aneroid constrictor was also described<sup>4,22</sup>. This study showed that the single ligation is effective and can be applied in the right position, close to the hepatic hilum, above the confluence of the superior mesenteric vein with the splenic vein and near the left gastric vein, which is an extremely small vessel in the rat. A single ligation in this experiment also managed to develop a significant collateral circulation. During the pilot project an aneroid constrictor made with a fragment of the catheter 22G, to get obstruction in the vein and to be a support for the knot was used, but this option has proved technically difficult and unnecessary, since a single surgical knot achieved the expected results.

Among the various factors that interfere in the increased resistance of the portal venous system, the main one is the constriction rate of the vein. The thickness of the thread is also important. Wen et al.<sup>22</sup> used various kinds of silk thread but opted for 4-0, whereas with thinner threads the experimental model remained unstable and portal pressure low. Using very thin threads these authors reported difficulty making the knot, especially in small veins, with a diameter of approximately 1 mm. The characteristic of the knot is also important, as too tight can impair the vein with consequent thrombosis and too loose can compromise the results of the experiment. It was considered essential to standardize the dissection of all tissues, just isolating the portal vein from the structures of the hepatic hilum. Silk thread 6-0 for ophthalmic use was option here used and proved to be compatible with the tenderness needed for the experiment. Its pattern matched quite well the strength of the knot, enough to adjust the caliber of the vein to the catheter diameter and speed of maneuver, avoiding complete occlusion of the vein. A single surgeon knot was made and the catheter quickly removed to restore blood flow through the vein constriction point. During the pilot study was tried to introduce the polypropylene 5-0 thread, but the results were not suitable, having occurred the death of all animals with the use of it, attributed to a possible injury to the endothelium of the vein causing thrombosis. The difficulty in making the knot with this type of thread must also be considered, since the knot requires more tensile force to be applied by the surgeon. Technical difficulties represented by the delicacy of the structures dissected also justify the use of thin threads which, in this experiment, did not harm the results.

Orda and Ellis<sup>48</sup> reported that portal pressure can return to normal, but this controversy was undone in recent studies, confirming the stability of this pressure at close to twice the normal value for longer periods<sup>11,22</sup>. This model can be reversed if the constriction of the portal vein is undone, with disappearance of collateral circulation in most animals<sup>16</sup>.

Although it is reported that the experiment does not compromise the hepatic function<sup>17,22</sup>, Marques et

al.<sup>14</sup> confirmed that there are neither changes in the histological aspect of the liver nor in the activity of liver aminotransferases, but there is a temporary reduction in the metabolic activity of the liver, but without hepatocellular injury. Oxidative stress, resulting in the formation of radicals explains various pathophysiological changes regarding the study.

Histological changes that may occur in mouse spleen in this situation are basically blood congestion in the red pulp of the organ, hyperplasia of histiocytes, reticular fibers increased and, with disease progression, fibrosis diffuse<sup>5</sup>. Wen et al.<sup>22</sup> found thinning of the spleen capsule and vascular congestion but with no significant proliferation of endothelial cells, as well as atrophy of the white pulp and in the germinal centers of the organ<sup>10</sup>. The histological aspects found here will be reported in a specific publication.

Kountouras et al.<sup>11</sup>, using rats, evaluated the changes in spleen weight, relating tenths of a gram of organ weight per each hundred grams of body weight. The authors of this paper made the option for the use of a mathematical formula which calculates the volume of an elliptical form of a geometric figure, however tridimensional (ellipsoid) as recommended by Tanaka<sup>21</sup>, for the reason that the method can be carried out in the research laboratory. The spleen volume increased slightly with the growth of the animal in the control group (sham-operated), but showed a higher increase when were assessed the animals that underwent partial portal vein ligation, both after two and four weeks of study. Although with an average increase of 17 % in the spleen of animals with portal hypertension, such difference was not statistically significant. Wen et al.<sup>22</sup> found a two-fold increase in spleen volume, a result that shows statistical significance.

The obtained results were not significantly different when compared to animals reoperated after two or four weeks and, likewise, the macroscopic aspect of the peritoneal cavity of the animals was very similar. When comparing animals reoperated after 15 days (group 2), and after 30 days (group 3), no significant changes in the spleen volume were found. Therefore, a 15 day term was considered enough for the evaluation of effects of partial portal vein ligation in animals.

## CONCLUSIONS

There was no statistically significant increase in spleen volume after partial portal vein ligation when comparing the calculated volume in the first operation with the volume found in reoperation. There was also no difference when comparing the volumes of the spleens in the reoperated group after 15 days with the group after 30 days.

## REFERENCES

1. Al-Busafi SA, McNabb-Baltar J, Farag A, Hilzenrat N. Clinical manifestations of portal hypertension. *Int J Hepatol* 2012; 2012: 1-10
2. Andreollo NA, Santos EF, Araújo MR, Lopes LR. Idade dos ratos versus idade humana: qual é a relação? *Arq Bras Cir Dig* 2012; 25: 49-51
3. Assef AJ, Vieira ACPO, Saito HCG, Lancellotte CLP, Szutan LA, De Cápua AJr. Modelo experimental de formação de varizes esofágicas por hipertensão portal esquistossomótica em hamsters. *Rev Col Bras Cir* 2005; 32: 209-13
4. Canty TG, Jauregizar E, Fernandez-Cruz L. Experimental portal hypertension in the rat. *J Pediatr Surg* 1980; 15: 819-26
5. Coelho JCU, Matias JEF, Parolin MB, Martins EL, Salvalaggio PRO, Gonçalves CG. Complicações vasculares pós-transplante hepático. *Rev Col Bras Cir* 2000; 27: 378-82
6. Evangelista-Neto J, Pereira FF, França ST, Amaral FJ, Brandt CT, Fonseca-Neto OCL, et al. Esplenectomia e ligadura da veia gástrica esquerda na esquistossomose mansônica: efeitos sobre pressão das varizes do esôfago e indicadores endoscópicos de risco de sangramento por varizes esofagogástricas. *Arq Bras Cir Dig* 2012; 25: 41-8
7. Fabián GR, García GM, Fernández DB, Ravero MAA, Pérez AJ. Long-term portal hypertension in the rat by means of triple stenotic ligation of the portal vein. *An Med Interna*. 2000;17: 137-41
8. Ferraz AAB, Lopes EPA, Araújo Júnior JGC, Lima BA, Cantarelli F, Ferraz EM. Peso do baço como fator prognóstico do tratamento cirúrgico de pacientes portadores de esquistossomose mansônica. *Rev Col Bras Cir* 2002; 29: 29-35
9. Ferri PM, Ferreira AR, Fagundes EDT, Liu SM, Albuquerque NN, Botelho FC, et al. Trombose de veia porta em crianças e adolescentes: revisão de literatura. *Rev Med Minas Gerais* 2011; 21(4 Supl 1): S36-S44
10. Filicori F, Stock C, Schweitzer AD, Keutgen XM, Lagratta MD, Zarnegar R, et al. Three-dimensional CT volumetry predicts outcome of laparoscopic splenectomy for splenomegaly: retrospective clinical study. *World J Surg* 2013; 37: 52-8
11. Kountouras J, Billing BH, Scheuer PJ. Prolonged bile duct obstruction: a new experimental model for cirrhosis in the rat. *Br J exp Path* 1984; 65: 305-11
12. Makdissi FF, Herman P, Machado MAC, Pugliese V, D'Albuquerque LAC, Saad WA. Trombose de veia porta após desconexão ázigo-portal e esplenectomia em pacientes esquistossomóticos. Qual a real importância? *Arq Gastroenterol* 2009; 46: 50-4
13. Manenti A, Botticelli A, Gibertini G, Botticelli I. Experimental congestive splenomegaly: histological observations in the rat. *Pathologica* 1993; 85: 721-4
14. Marques C, Mauriz JL, Simonetto D, Marroni CA, Tuñón MA, González-Gallego J, et al. Glutamine prevents gastric oxidative stress in an animal model of portal hypertension gastropathy. *Ann Hepatol* 2011; 10: 531-9
15. Méndez-López M, Méndez M, Sánchez-Patán F, Casado I, Aller MA, López L, et al. Partial portal vein ligation plus thioacetamide: a method to obtain a new model of cirrhosis and chronic portal hypertension in the rat. *J Gastrointest Surg* 2007; 11: 187-94
16. Min YW, Bae SY, Gwak GY, Paik YH, Choi MS, Lee JH, et al. A clinical predictor of varices and portal hypertensive gastropathy in patients with chronic liver disease. *Clin Mol Hepatol* 2012; 18: 178-84
17. Morgan-Martins MI, Jaques SI, Hartmann RM, Marques CM, Marroni CA, Marroni NP. Protection of estrogen in portal hypertension gastropathy – an experimental model. *Arq Gastroenterol* 2011; 48: 211-6
18. Orda R, Ellis H. Self-established porto-caval and porto-pulmonary shunts in mechanically induced portal hypertension. An experimental study. *Eur Surg Res* 1978; 10: 172-83
19. Pinto RB, Silveira TR, Rosling L, Bandinelli E. Distúrbios trombofílicos em crianças e adolescentes com trombose da veia porta. *J Pediatr (Rio J)* 2003; 79: 165-72
20. Sikuler E, Kravetz D, Groszmann RJ. Evolution of portal hypertension and mechanisms involved in its maintenance in a rat model. *Am J Physiol* 1985; 248: G618-25
21. Tanaka EY. Análise de fatores preditivos de ressecção visceral no tratamento operatório de doentes portadores de hérnia incisional gigante com perda de domicílio submetidos a pneumoperitônio progressivo pré-operatório. Tese (Doutorado). São Paulo: Faculdade de Medicina da Universidade de São Paulo; 2009
22. Wen Z, Zhang JZ, Xia HM, Yang CX, Chen YJ. Stability of a rat model of prehepatic portal hypertension caused by partial ligation of the portal vein. *World J Gastroenterol* 2009; 15: 4049-54
23. Widman A, Oliveira IRS, Speranzini MB, Cerri GG, Saad WA, Gama-Rodrigues J. Hipertensão portal por esquistossomose mansônica hepatoesplênica: efeito da desconexão ázigo-portal com esplenectomia no diâmetro e na velocidade média de fluxo do sistema portal (estudo ultra-sonográfico com Doppler). *Arq Gastroenterol* 2001; 38: 19-23
24. Yokoyama Y, Baveja R, Sonin N, Clemens MG, Zhang JX. Hepatic neovascularization after partial portal vein ligation: novel mechanism of chronic regulation of blood flow. *Am J Physiol Gastrointest Liver Physiol* 2001; 280: G21-G31