

DISCUSSION

In a literature review, studies were presented that describe the close relationship between overweight and tendency to social isolation, stress, depression and worsening of functional capacity of the obese³. In contrast, it was found that grade III obese individuals when operated regained their self-esteem and quality of life for subsequent maintenance of weight below the levels regarded as morbid obesity¹⁴.

In the case of orofacial functions, oral motor disorder most referenced by the elderly is chewing change because, although indentations, the elderly do not prepare food for swallowing with the same young adult efficiency. The increase in oral transit time of the bolus, preceding the pharyngeal phase of swallowing is common in elderly¹⁰. It was also observed this aspect in this case. Furthermore, require significantly larger number of swallows for cleaning the pharynx¹³ and decrease in oropharyngeal sensitivity changes, so favoring microaspirations², which was observed in the studied patient.

The individual seeking for operation, as an alternative to improving his/her quality of life, should be reminded the existence of oral myofunctional changes that happen in the course of life associated with aging. This leads to make a conscious and functional way what was happening automatically and inappropriately. New posture is guided to the intake in order to facilitate the reintroduction of postoperatively food. Stand out from the information provided about the masticatory process and the changes that occur in it, throughout life, has great importance for the prevention of disorders⁵. The myofunctional speech therapy, in order to raise awareness and re-enable the individual performance of speech functions, breathing, sucking, chewing and swallowing, implies life modifications⁶.

This process increases the ability, which was confirmed considering the good performance of orofacial functions accompanied the elderly.

Thus, preventive action and/or rehabilitative aims to provide well-being, active permanence of the elderly in their social environment and satisfaction with life also to bariatric patients⁵.

You need to consider that the individual search operation, better quality physical, mental and social, also covers aesthetic and functional aspects related to food. This is critical at later ages because the permanence of social interactions is closely related to successful aging, also observed as the patient described in this paper, because before the operation had limitations, reducing social activities, also by virtue of comorbidities. Importantly it has been found relation between overweight and tendency to social isolation, stress, depression and worsening of functional capacity¹⁴.

Taking into account the influence of speech in bariatric surgery in orofacial characteristics related to aging, are more relevant, given that there will be major change in diet after surgery. The speech therapists will collaborate with patient undergoing gastroplasty on eating foods with different consistencies and textures, which can contribute to the prevention of health risks and better quality of life⁶.

REFERENCES

1. Amaral AKFJ, Regis RMFL. Sistema estomatognático no idoso. In: Hilton JS, Cunha DA, organizadores. O sistema estomatognático: anatomofisiologia e desenvolvimento. São Paulo: Pulso; 2011. p.129-44.
2. Aviv JE. Effects of aging on sensitivity of the pharyngeal and supraglottic áreas. Am J Med. 1997; 103 (5A): 74s-76s.

3. Brito CLS. Aspectos psiquiátricos nos cuidados pré e pós-operatórios na cirurgia da obesidade. In: Silva RS, Kawahara NT, organizadores. Cuidados pré e pós-operatórios na cirurgia da obesidade. Porto Alegre: AGE; 2005. p.114-29.
4. Canterji MB, Côrrea SPM. Fonoaudiologia e nutrição: trabalhando a qualidade de vida alimentar. In: Franques ARM, Loli MAS. Novos corpos, novas realidades: reflexões sobre o pós-operatório da cirurgia da obesidade. São Paulo: Vetor; 2011. p. 327-37.
5. Canterji MB, Nisa e Castro SAF. O envelhecimento da motricidade oral: aspectos da mastigação. In: Terra NL, Dornelles B, organizadores. Envelhecimento bem sucedido. Porto Alegre: EDIPUCRS; 2002. p. 355-60.
6. Canterji MB. Avaliação miofuncional orofacial em cirurgia bariátrica. In: Susanibar F, Parra D, Dioses A. Tratado de evaluación de motricidad orofacial, disfagia y voz. 2014.
7. Gonçalves RFM, Chehter EZ. Perfil mastigatório de obesos mórbidos submetidos à gastroplastia. Rev CEFAC 2012; 14(3): 489-497.
8. Jotz GP, Carrara-de Angelis E, Barros APB. (Org.). Tratado da deglutição e disfagia no adulto e na criança. Rio de Janeiro: Revinter. 2009; p. 364-368.
9. Kral JG, Otterbeck P, Touza MG. Preventing and treating the accelerated ageing of obesity. Maturitas 2010. 66: 223-230.
10. Logemann JA, Pauloski BR, Rademaker AW, Colangelo LA, Kahrilas PJ, Smith CH. Temporal and biomechanical characteristics of oropharyngeal swallow in younger and older men. J Speech Lang Hear Res. 2000;43:1264-74.
11. Pajeci D, Santo MA, Kanagi AL, Riccioppo D, Cleva R, Cecconello I. Functional assessment of older obese patients candidates for bariatric surgery. Arq Gastroenterol 2014;51(1):25-8.
12. Papaleo-Neto M. Gerontologia. São Paulo: Atheneu; 2002.
13. Plant RL. Anatomy and physiology of swallowing in adults and geriatrics. Otolaryngol Clin North Am. 1998; 31:477-88.
14. Tavares TB, Nunes SM, Santos MO. Obesidade e qualidade de vida: revisão da literatura. Rev Med Minas Gerais. 2010; 20: 359-66.

ABCDDV/1155

ABCD Arq Bras Cir Dig Letter to the Editor
2015;28(3):87-89

DOI: /10.1590/S0102-6720201500S100024

CUSHING'S SYNDROME CAUSED BY AN ADRENOCORTICAL CARCINOMA AFTER A BARIATRIC SURGERY: CASE REPORT

Síndrome de cushing causada por carcinoma adrenocortical após cirurgia bariátrica: relato de caso

Kátia Elisabete Pires **SOUTO**¹, Daniela Aline **PEREIRA**¹,
Maurício Jacques **RAMOS**², Alberto Salgueiro **MOLINARI**¹,
Daniel de Carvalho **DAMIN**³

From the Serviço de ¹Endocrinologia and ²Cirurgia Digestiva, Hospital Nossa Senhora da Conceição, and ³Programa de Pós-Graduação, Hospital de Clínicas, Universidade Federal do Rio Grande do Sul (¹Endocrinology and ²Digestive Surgery Services, Nossa Senhora da Conceição Hospital and ³Surgery Postgraduate Program, Hospital de Clínicas, Federal University of Rio Grande do Sul), Porto Alegre, RS, Brazil.

Fonte de financiamento: não há

Conflito de interesses: não há

Correspondência:

Kátia Souto,

E-mail: endocrino40@hotmail.com

Recebido para publicação: 25/11/2014

Aceito para publicação: 16/07/2015

INTRODUCTION

Interest in the study of adrenocortical carcinoma has greatly increased in the last 12 years. In the last decade, more medical articles about this subject have been published than in the last 50 years¹. Adrenal carcinoma is a rare and aggressive neoplasia and the affected patients have less than a 50% chance of survival in five years. In the metastatic disease, the survival rate is less than 15%². It has an incidence of 0.7 to 0.2 per 1 million people each year with bimodal distribution and it is predominant in females². The incidence is shown to be higher in children from the South of Brazil due to environmental and genetic factors^{3,4}. It represents 3-6% of all carcinomas³.

The purpose of this report is to relate a patient with morbid obesity that underwent bariatric surgery and after that developed the Cushing's syndrome caused by an adrenocortical carcinoma.

CASE REPORT

A 54 years old patient was admitted to the endocrinology unit in February 2012. She had a 3-month history of acne, hirsutism, muscle weakness in her lower limbs, increasing levels of hypertension and diabetes mellitus imbalance. The physical exam revealed a rounded face, clavicular fatness, a fatty hump, BP= 200X100 mmHg, BMI=32.4 kg/m². She had a gastric bypass due to morbid obesity in 2009, with BMI=52,47 kg/m². Hormonal data were consistent with CS- ACTH independent (Table 1).

TABLE 1 – Laboratorial and weight evolution during the patient's follow-up

	February 2012	May 2012	August 2012	March 2013	References
ACTH	<5.0	33.2	<5.0	<5.0	<46 pg/ml
DHEA-S	1410		248.6		19-205 u/dl
Androstenedione	>10	0.32	4.61	>10	0.40-3.0 ng/ml
17 -alpha-OH-progesterone	2.14		0.23	297ng/dl**	0.19 -1.0 ng/ml
SHBG	45.60	128.2	56.20		18-114 nmol/l
Free testosterone	6.78	0.05	0.48	23.75	0.19 – 2.06 ng/dl
Total testosterone	6.55		0.53		0.06-0.82 ng/ml
Urinary free cortisol	224.1	18.8	90.9		10-90 ug/24 h
LDDST* cortisol	31.87		9.75	15.23	
LH	<0.1		19.2		1.7 – 8.6mUI/ml

DHEA-S=plasma dehydroepiandrosterone sulfate; *LDDST=low dose dexamethasone suppression test; **change in the ng/dl method (VR: 59-344 ng/dl)

Abdominal computed tomography showed an expanding lesion in the left adrenal area of 13.0X9.0 cm, with irregular contour lines and heterogeneous caption of contrast (Figure 1).

She was submitted to a left adrenalectomy and partial nephrectomy in April 2012. Her anatomopathological exam result was 630 g, size 21X10X 5.0 cm (Figure 2).

The pathologic findings were: 15 mitosis in 50 high power fields and the nuclear pleomorphisms was present;

it showed the presence of confluent necrosis and capsular invasion; Ki-67 index was 20% positive according to the immunohistochemical criteria; TNM tumor stage was 3-0-0.

There was regression of clinical and laboratorial alterations related to the Cushing's syndrome. She had a follow-up as an outpatient and used mitotane 2 g per day. After seven months, abdominal and thoracic tomography showed recurrence of the tumor and metastasis in the lungs (Figure 3).

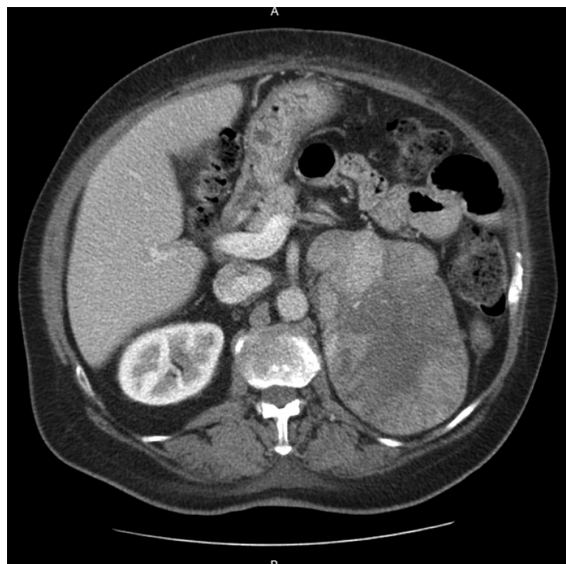


FIGURE 1 - Abdominal tomography showing adrenal tumor

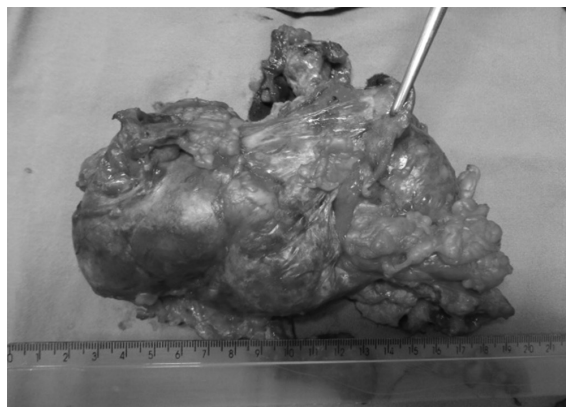

FIGURE 2 - Resected adrenal tumor

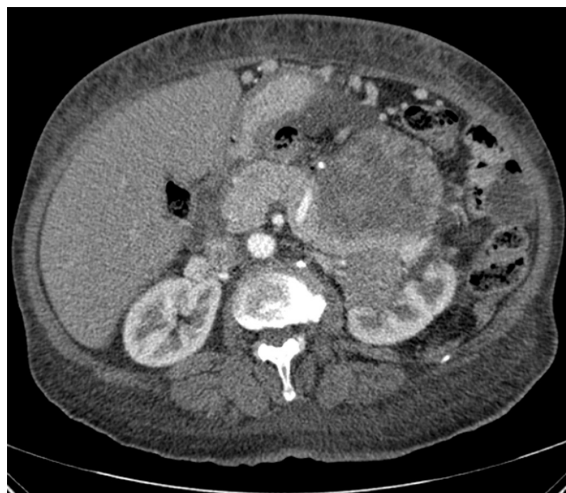

FIGURE 3 - Adrenal mass

As there was no satisfactory response from mitotane, cisplatin and etoposide, her clinical situation worsened and she died 13 months after having had an adrenalectomy. The patient's daughter has agreed in writing to allow the publication of this study.

DISCUSSION

Brazil is the country with the second highest numbers of bariatric surgeries and it has the highest number of bariatric surgeons in the world⁵. Although Cushing syndrome is a rare cause of obesity, it is supposed that some of the patients that have had bariatric surgery have it. There are few studies about it in patients with morbid obesity². Cushing is a disease difficult to diagnose and many times its diagnosis happens too late⁶. When hypercortisolism appears, it can be an ACTH – dependent Cushing's syndrome (70 to 80%) or ACTH – independent caused by adrenocortical tumors or hyperplasia adrenal^{7,8}. It is more prevalent in high risk populations such as obese people with poorly controlled diabetes and its incidence ranges between 3.3 to 5.8% in published studies⁸. Screening for Cushing before bariatric surgery has been suggested in order to avoid a procedure that could be lethal and irreversible as it has already been described^{8,9}. There are reports about it over 9.33% in obese patients¹⁰. Approximately 60% of adrenal carcinomas are functioning and 70% are manifested by Cushing syndrome, associated or not to virilization. Virilization and DHEA-S high levels are more associated to malign tumors¹¹. In those tumors, the symptoms associated to the glucocorticoids excess develop fast (from 3 to 6 months)². Patients with higher recurrence risk present a high rate of malignity in the histology (Ki67 staining of >10% of tumor cells, >20 mitotic figures per 50 high power fields) no matter what the tumor size and the vascular and capsular invasion¹². Ki67 is the most powerful detector of the located or advanced disease and it can guide the treatment¹. Adrenal carcinomas grow very fast and very often they present metastasis in the lungs and liver¹¹. This patient's adrenalectomy did not show evidence of metastasis. However, after seven months she had a recurrence of the disease and there was lung metastasis. This case highlights the fact that patients with morbid obesity should be investigated in regard to other endocrinal diseases. Future studies are needed to evaluate the true Cushing syndrome prevalence in this population¹⁰. It

is believed that this is the first case reported in the literature that refers functioning adrenocortical carcinoma which was diagnosed after bariatric surgery. The authors emphasize the importance of having an endocrinologist in the surgical team, who also diagnoses and treats Cushing syndrome in morbidly obese patients.

REFERENCES

1. Fassnacht M, Kroiss M, Allolio B. Update in adrenocortical carcinoma. *The Journal of clinical endocrinology and metabolism*. 2013;98(12):4551-64.
2. Fassnacht M, Terzolo M, Allolio B, Baudin E, Haak H, Berruti A, et al. Combination chemotherapy in advanced adrenocortical carcinoma. *The New England journal of medicine*. 2012;366(23):2189-97.
3. Ribeiro RC, Michalkiewicz EL, Figueiredo BC, DeLacerda L, Sandrini F, Pianovsky MD, et al. Adrenocortical tumors in children. *Brazilian journal of medical and biological research = Revista brasileira de pesquisas medicas e biologicas / Sociedade Brasileira de Biofisica [et al]*. 2000;33(10):1225-34.
4. Sandrini R, Ribeiro RC, DeLacerda L. Childhood adrenocortical tumors. *The Journal of clinical endocrinology and metabolism*. 1997;82(7):2027-31.
5. Buchwald HO, D.M. *Metabolic/Bariatric Surgery Worldwide 2011*. Obesity surgery. 2013;23:427-36.
6. Aron D. Cushing's Syndrome: why is diagnosis so difficult? *Rev Endocr Metab Disord*. 2010;10:5-16.
7. Stiles LE. Cushing syndrome and bariatric surgery: why, when, and how to evaluate preoperatively. *Surgery for obesity and related diseases : official journal of the American Society for Bariatric Surgery*. 2009;5(1):119-21.
8. Fleseriu M, Ludlam WH, Teh SH, Yedinak CG, Deveney C, Sheppard BC. Cushing's syndrome might be underappreciated in patients seeking bariatric surgery: a plea for screening. *Surgery for obesity and related diseases : official journal of the American Society for Bariatric Surgery*. 2009;5(1):116-9.
9. Savastano S, Pivonello R, Colao A. Bariatric surgery for obesity and hidden Cushing syndrome. *Surgery for obesity and related diseases : official journal of the American Society for Bariatric Surgery*. 2009;5(1):121-2.
10. Tiryakioglu O, Ugurlu S, Yalin S, Yirmibesicik S, Caglar E, Yetkin DO, et al. Screening for Cushing's syndrome in obese patients. *Clinics*. 2010;65(1):9-13.
11. Nag S, McCulloch A. Cushing's syndrome due to an adrenocortical carcinoma. *Postgraduate medical journal*. 2003;79(934):466.
12. Berruti A, Fassnacht M, Haak H, Else T, Baudin E, Sperone P, et al. Prognostic Role of Overt Hypercortisolism in Completely Operated Patients with Adrenocortical Cancer. *European urology*. 2013.