



## Original Article

## *Hyptis pectinata* gel prevents alveolar bone resorption in experimental periodontitis in rats



Mônica S. Paixão<sup>a</sup>, Mônica S. Melo<sup>b</sup>, Nicole P. Damascena<sup>b</sup>, Adriano A.S. Araújo<sup>c</sup>, Andrea F. Soares<sup>d</sup>, Denise V.A. Oliveira<sup>d</sup>, Jeison S. Oliveira<sup>d</sup>, Fabrício T.C. Almeida<sup>d</sup>, Francilene S. Amaral<sup>c</sup>, Brancilene S. Araújo<sup>b</sup>, Charles S. Estevam<sup>b</sup>, Marco A. Botelho<sup>e</sup>, Lucindo J. Quintans-Júnior<sup>b,\*</sup>

<sup>a</sup> Department of Odontology, Federal University of Sergipe, Av. Marechal Rondon s/n, Rosa Elze, 49100-000 São Cristóvão, SE, Brazil

<sup>b</sup> Department of Physiology, Federal University of Sergipe, Av. Marechal Rondon s/n, Rosa Elze, 49100-000 São Cristóvão, SE, Brazil

<sup>c</sup> Department of Pharmacy, Federal University of Sergipe, Av. Marechal Rondon s/n, Rosa Elze, 49100-000 São Cristóvão, SE, Brazil

<sup>d</sup> Department of Morphology, Federal University of Sergipe, Av. Marechal Rondon s/n, Rosa Elze, 49100-000 São Cristóvão, SE, Brazil

<sup>e</sup> The Northeast Biotechnology Network, University of Potiguar, Natal, Rio Grande do Norte, Brazil

## ARTICLE INFO

## Article history:

Received 22 July 2014

Accepted 7 December 2014

Available online 12 February 2015

## Keywords:

*Hyptis pectinata*

Periodontitis

Bone loss

Doxycycline

## ABSTRACT

*Hyptis pectinata* (L.) Poit., Lamiaceae, is an aromatic, abundant and broadly used plant species in Sergipe to treat oral and gastrointestinal pain and inflammation. The aim of the present study was to analyze the relation between periodontitis and changes in the corporal mass and alveolar bone structure after induction of experimental periodontal disease in rat treated or not treated with *H. pectinata* gel at 5% (GS5%) and 10% (GS10%), comparing their effects with doxycycline gel at 10% (D10%, positive control), vehicle gel (negative control) and a group with experimental periodontal disease, but non-treated. The gels were locally applied in the gingival region immediately after the experimental periodontal disease induction by ligature (3×/day, 11 days). Bone destruction was determined through clinical exam, histopathological analysis and cone beam computed tomography of the experimental animals ( $n = 36$ ). After 11 days of periodontitis induction, all groups that received ligature presented a decrease in the corporal mass, except to the naïve group (without experimental periodontal disease) ( $p < 0.05$ ). Computed tomography results have shown healthy bone structure in the group I and bone resorption for the test groups. Histopathological analysis confirmed the healthy bone structure for naïve group animals, while the test groups exhibited bone loss in several degrees. In particular, the non-treated group animals had an intense inflammatory process. When the periodontium of the animals treated with GS10% was histopathologically analyzed, insertion periodontium was preserved. The results for these groups were significantly different of the vehicle group ( $p < 0.05$ ). According to the results, the gel based in the aqueous extract of *H. pectinata* at 10% can prevent bone loss in experimental periodontal disease similarly to doxycycline 10%.

© 2014 Sociedade Brasileira de Farmacognosia. Published by Elsevier Editora Ltda. All rights reserved.

## Introduction

Pathological cases of gingivitis and periodontitis, the oral illnesses more prevalent in Brazil are target of special attention in needy communities, especially in the Brazilian Northeast, where the individuals with these pathologies normally have evolved cases, which are accompanied with the deterioration of the dental unit as well as their bone support (Botelho et al., 2007). They are frequently linked to oral bacteria, which are associated to many systemic diseases such as pneumonia and cardiovascular diseases. Therefore, it

has been emphasized the need to oral care in the systemic control of health (Takarada et al., 2004).

Periodontitis, an important cause of teeth loss in adults, is a chronic inflammatory disease characterized by located bone resorption (Chambrone and Chambrone, 2006; Botelho et al., 2010). Recent researches have indicated the local utilization of doxycycline gels as an isolated treatment, which prevent tooth scaling and root planning and are effective in combating the periodontal disease (Tinoco and Tinoco, 2000). In addition, it has been suggested that the association of natural products with preventive care can reduce the high incidence of diseases that affect the dental element as the periodontal disease (Juiz et al., 2010; Siqueira et al., 2010; Guimarães et al., 2013). Recently, our group has developed study about the pharmacological use of natural products, as

\* Corresponding author.

E-mail: [lucindo@pq.cnpq.br](mailto:lucindo@pq.cnpq.br) (L.J. Quintans-Júnior).

medicinal plants, to treat orofacial disorders (Quintans-Júnior et al., 2010; Bonjardim et al., 2011; Siqueira-Lima et al., 2014; Quintans et al., 2014).

*Hyptis* species are aromatic plants that present pharmacologically active substances with antimicrobial, antifungal, anti-HIV, analgesic and antiinflammatory activities, and cytotoxicity and insecticide properties (Bispo et al., 2001; Santos et al., 2008; Oliveira et al., 2011; Franco et al., 2011; Paixão et al., 2013). *H. pectinata* (L.) Poit., Lamiaceae, an aromatic perennial bush species with low foliar density and erect branches, is widely spread in the states of Sergipe and Alagoas. The plant can be easily found around cities to be used for treating oral, gastric disorders and fever (Martinez, 1989; Paixão et al., 2013). Its aqueous extract has previously shown antinociceptive and antiedematogenic effects by reducing symptoms up to 54% at 400 mg/kg (Bispo et al., 2001). Since the plant leaf crude aqueous extract showed orofacial antinociception (Paixão et al., 2013), it was found necessary to further investigate its action against other orofacial diseases such as periodontitis. Therefore, the aim of the present study was to analyze the relation between periodontitis and changes in the corporal mass and alveolar bone structure after induction of experimental periodontal disease (EPD) in rat treated or not treated with *H. pectinata* gels compared with the standard drug doxycycline.

## Materials and methods

### Plant material

*Hyptis pectinata* (L.) Poit., Lamiaceae, leaves were collected during the florescence period in the metropolitan area of Aracaju, Sergipe, Brazil (255 m, 10°55'56.1" South, 37°06'34.7" West). The plant material was identified and a voucher specimen was deposited in the herbarium of the Department of Biology in the Federal University of Sergipe under the number ASE-19005.

### Aqueous extract preparation

Leaves were dried in an oven at 37 °C with air renewal and circulation for 48 h until complete dehydration. Afterwards, they were triturated to give a fine powder (2 kg), which was extracted with distilled water (3:10, w/v) under constant agitation for 4 h at 35 °C. After filtration, the supernatant was lyophilized to give the dry crude aqueous extract (CAE, 32 g). CAE was distributed in seven pots and kept in a desiccator in the Laboratory of Natural Product Pre-clinical Pharmacology of the Federal University of Sergipe to be used in the subsequent experiments, when they were redissolved in water to give specific concentrations.

### Gel preparation

CAE was maintained under dark to avoid the possible light degradation of some of the compounds present in it. For the gel base production, 0.2% Nipagim® (Batch GBG0020625, Pharma Special), 0.05% EDTA disodium (Batch 090707#2, DEG) and purified water were measured and heated together in a water-bath up to 70 °C. When the temperature was reached, the mixture was removed from the water-bath and slowly added to hydroxyethyl cellulose, which was stirred until complete homogenization and solubilization of the polymer. When this previous mixture reached 40 °C, Germal® previously solubilized in water was added to complete homogenization until the gel formation. Afterwards, triethanolamine was added for pH adjustment to the range 5.0–6.0 at environment temperature. *H. pectinata* extract was mixed with propilenoglicol (Batche 10030930C, Pharma Nostra) and incorporated in the gel at 5% or 10% considering gel mass.

The gels were stored in white polyethylene containers kept hermetically sealed at 8 °C until use. Stability studies to evaluate gel consistency on a 2-month period were performed with the formulations being kept in different conditions (4 °C, 37 °C and environment temperature) and the gel formulation viscosity was measured in regular intervals. The study indicated that gel viscosity, color and consistency did not change significantly during the period analyzed in the specified circumstances.

### Animals

A previous training with the research team on anesthesia procedures, adaptation and handling of the animals and gels, and convenient placement of the bondages was done before the beginning of the experiment. The animals were positioned on the surgery table to allow the rat oral opening maintenance, facilitating the access to the maxilla posterior region of their teeth. Previous to the experiment, 36 male Wistar rats (100–200 g) were housed in temperature controlled rooms and received water and food ad libitum. All experiments were conducted in accordance with local guidelines on the welfare of experimental animals and with the approval of the Committee on Ethics in Animal Research of the Federal University of Sergipe (#47/09).

The experimental groups were divided in naïve (animals non-treated and not subjected to EPD), non-treated group (NT, animals subjected to EPD, but without treatment), vehicle-treated group (V, animals subjected to EPD and treated with vehicle gel), GS5% group (animals subjected to EPD and treated with local *H. pectinata* gel at 5%, w/w), GS10% group (animals subjected to EPD and treated with local *H. pectinata* gel at 10%, w/w) and D10% group (animals subjected to EPD and treated with local doxycycline gel at 10%, w/w). Doxycycline was utilized as a reference drug. The local treatment with the gel was first performed immediately after the surgical procedure and then three times/day until the animal sacrifices on the 11th day.

The animals in the test groups with periodontal diseases ( $n=6$ , each group) received a ligature, while the animals in the control group (naïve,  $n=6$ ) were not induced for periodontitis, although they were submitted to capture, hold, daily weighing and sacrifice similarly to the test groups.

### Induction of experimental periodontal disease (EPD)

The EPD protocol used in present study was performed similarly to Botelho et al. (2007, 2010). A sterilized nylon (3.0) thread ligature was placed around the cervix of the second upper-left molar of rats anesthetized with 10% ketamina (0.08 ml/100 g, *i.p.*) and xilazine chlorhydrate (0.04 ml/100 g). The ligature was knotted on the buccal side of the tooth, resulting in subgingival position palatally and in supragingival position orally. The contralateral right side was used as the unligated control. Animals were weighted daily.

### Histopathological analysis

After sacrifice under anesthesia, animals had their maxillae excised. The specimens were fixed in 10% neutral buffered formalin and demineralized in 7% nitric acid. These specimens were then dehydrated, embedded in paraffin and sectioned along the molars in a mesio-distal plane for hematoxylin and eosin staining. Sections of 6 µm thickness, which included the roots of the first and second molars, were used. The areas between the first and second molars, where the ligature was placed, were analyzed under light microscopy using a 0–3 grade score, considering the inflammatory cell influx, and alveolar bone and cementum integrity, as described previously (Botelho et al., 2007): score 0, absence or only a discrete cellular infiltration (inflammatory cell infiltration is sparse

and restricted to the region of the marginal gingiva) with preserved alveolar process and cementum; score 1, moderate cellular infiltration (inflammatory cellular infiltration present all over the gingival insert) with some minor alveolar resorption process and intact cementum; score 2, accentuated cellular infiltration (inflammatory cellular infiltration present in both gingival and periodontal ligament) with accentuated degradation of the alveolar process and partial destruction of cementum; and score 3, accentuated cellular infiltrate, complete resorption of the alveolar process and severe destruction of cementum.

#### Weight loss analysis

All the animals had their corporal mass measured before the surgery and in the 11 subsequent days, which was the experimental period. Values observed were expressed as the variation of the corporal mass (g) regarding the initial mass.

#### Cone-beam computed tomography

Prior the cone-beam computed tomography (CBCT), animals were sacrificed and their hemiarcs were dissected. These hemiarcs were submitted to CBCT using a tomography scanner model i-Cat (Imaging Sciences International) with an exposition area of 6 cm and exposition time of 40 s with voxel of 0.2 mm (maximum resolution). The digital images were analyzed using their axial, sagittal and coronal cuts in the program i-Cat Cone-Beam 3D Dental Imaging System, version 3.1.62. Results were expressed as scores according to scores used in the Laboratory of Pre-clinical Pharmacology of Natural Products to Federal University of Sergipe: 0, absence or discreet bone reabsorption; 1, bone reabsorption moderated; and 2, severe bone reabsorption.

#### Statistical analysis

The data are presented as the mean  $\pm$  SEM. Differences between groups were evaluated by analysis of variance (ANOVA) followed by Dunnett's or Bonferroni's tests using GraphPad Prisma v5.0 when means were compared. Statistical differences were considered to be significant at  $p < 0.05$ .

## Results

#### Macroscopic analysis

Before the histopathological analysis, gingiva alterations were evaluated with an odontological magnifying glass Bioart 4 $\times$  to note macroscopic texture modifications, absence of interproximal papilla and changes in the position or outline of gingiva in the animals of the groups with induced periodontal disease (NT, V, GS5%, GS10% and D10%), which were not present in the naïve group.

Gingiva of the upper second molar teeth in vestibular, palatine and interproximal regions of the naïve animals had similar clinical aspects. It rounded the cervical portion of the teeth and finished in a pointed form similar a knife edge. Interdental papillas were sharp and finished in triangular form. However, when the animals in the groups with induced periodontal disease (NT, V, GS5%, GS10% and D10%) were evaluated, it was shown that they had flaccid gingiva in the region of the upper first molar with apical migration of gingival margin and absence of interdental papillas, characterizing an inflammatory process in the gingival vestibular and palatine faces.

#### Histopathological analysis

The histopathological analysis of the region between the first and second molars of the normal periodontium shows periodontal

ligament (pl), alveolar bone (ab), dentin (d), cementum and gingiva (Fig. 1A). The histopathology of the periodontium of the animals subjected to periodontitis in the NT and V groups revealed intense inflammatory cell infiltration coupled with cementum destruction and complete alveolar process resorption (Fig. 1B and C), whose median received score 3. GS5% produced no significant change as demonstrated on Fig. 1D. However, a reduction of inflammatory cell infiltration with a partial preservation of the cementum and alveolar process was found in the periodontium of animals in GS10% and D10% (Fig. 1E and F, respectively), whose medians received score 1. These values were statistically significant ( $p < 0.05$ , respectively) when compared to the V and NT group (Fig. 2).

#### Weight loss analysis

As of general, all animals in the experimental groups presented variation in their weight after the analysis period. Animals in the experimental groups treated with *H. pectinata* and doxycycline gels had an increased weight after 11 days ( $p < 0.05$ ), while a decrease in the corporeal body mass was observed for animals in the NT and V groups (Fig. 3). However, animals in the naïve group, which did not have periodontal disease, showed the highest increase in the body weight (Fig. 3).

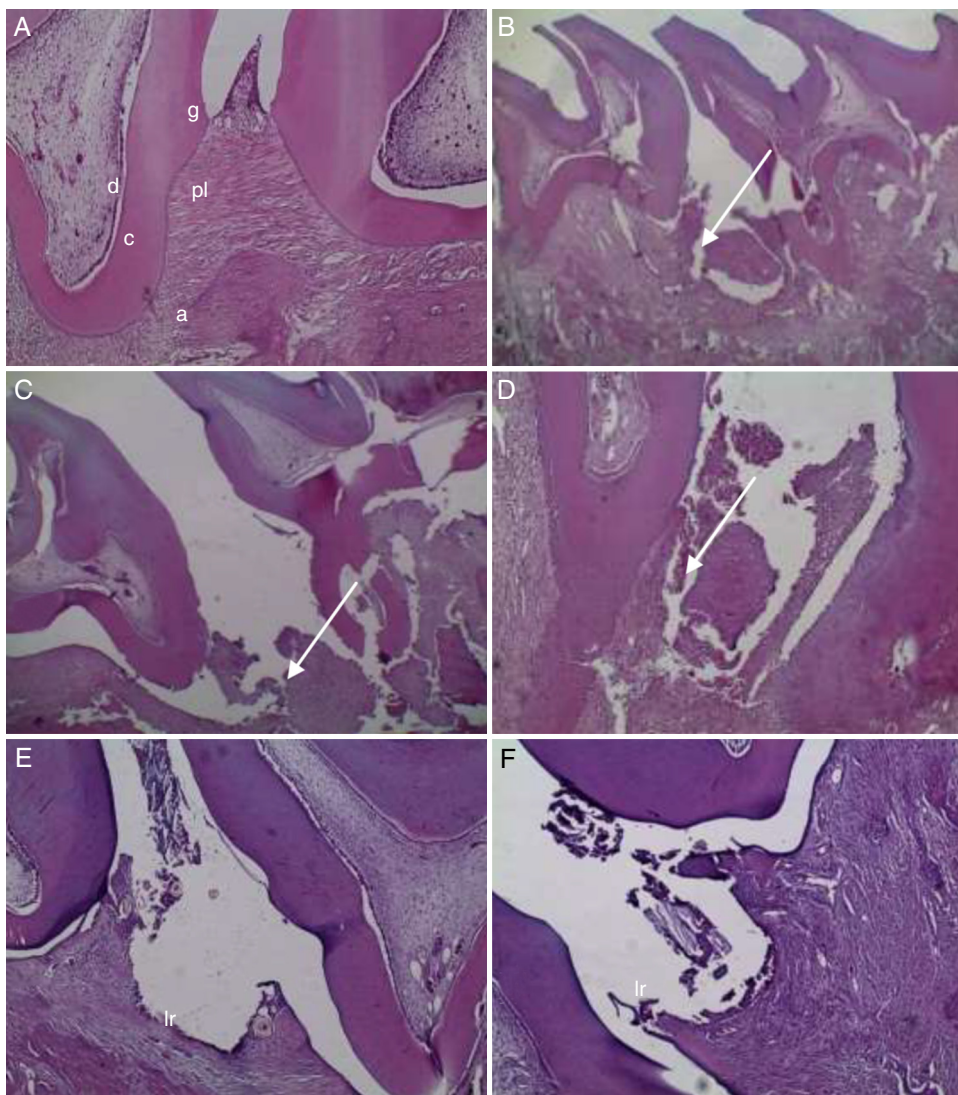
#### CBCT

CBCT images of the animal hemiarcs showed alveolar bone losses in varied degrees (Fig. 4) when compared to the naïve group, after 11 days of experiment. Severe alveolar bone losses were observed in the animal hemiarcs of the NT and V groups. In the other hand, the hemiarcs obtained from the animals treated with *H. pectinata* gels (GS5% and GS10%) had a significantly lower bone loss ( $p < 0.05$ ), which was similar to the one observed for the D10% group (Fig. 5).

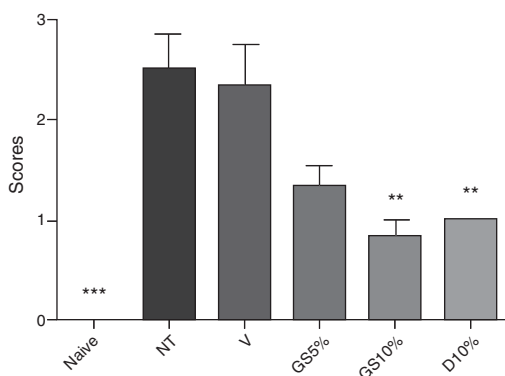
## Discussion

This study demonstrates that the local application of a dental gel based on *H. pectinata* has anti-inflammatory effect and also prevents alveolar bone resorption and weight loss in animals with periodontitis, which is still considered the main oral health problem in most of the developing countries, affecting 60–90% of children in schools as well as adults (Petersen and Yamamoto, 2005). As it is frequently seen in these countries, where natural products are used to treat several illnesses, it has been suggested the use of gels based in natural products in local application as supporting in the periodontal therapy (Pai et al., 2004). In this context, previous studies have shown that some natural products such as propolis (rich in flavonoids) and essential oils have cariostatic activity by inhibiting the enzymes that facilitate microbial aggregation and biofilm production as well as the growth of *Streptococcus mutans*, which will prevent periodontitis (Chung et al., 2006; Duarte et al., 2006).

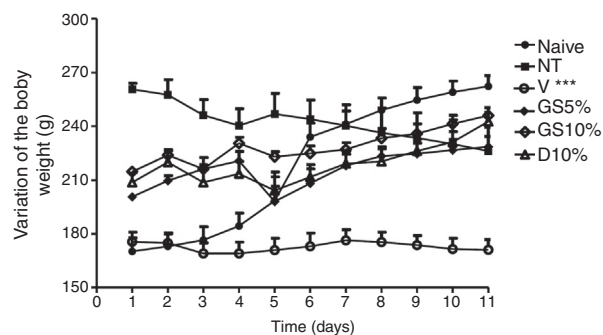
Although the use of systemic drugs against periodontal disease has been demonstrated in several studies (Lima et al., 2000; Bezerra et al., 2000; Menezes et al., 2005), there are few studies involving the use of antimicrobial drugs locally applied as adjunct to the treatment of the experimental periodontitis. Thus, the present study aimed to evaluate the effect of the local application of gels based in *H. pectinata* (5% and 10%) in the gingival region, as well as to elucidate the mechanisms by which these phytochemicals act in an animal model periodontitis, comparing them with a well-known antimicrobial drug, doxycycline (positive control), and a vehicle gel (negative control). For that, the model of induced periodontal disease developed by using the technique of ligature placement around the tooth was used due to its easy setup and high reliability during the development of the periodontal disease (Nassar



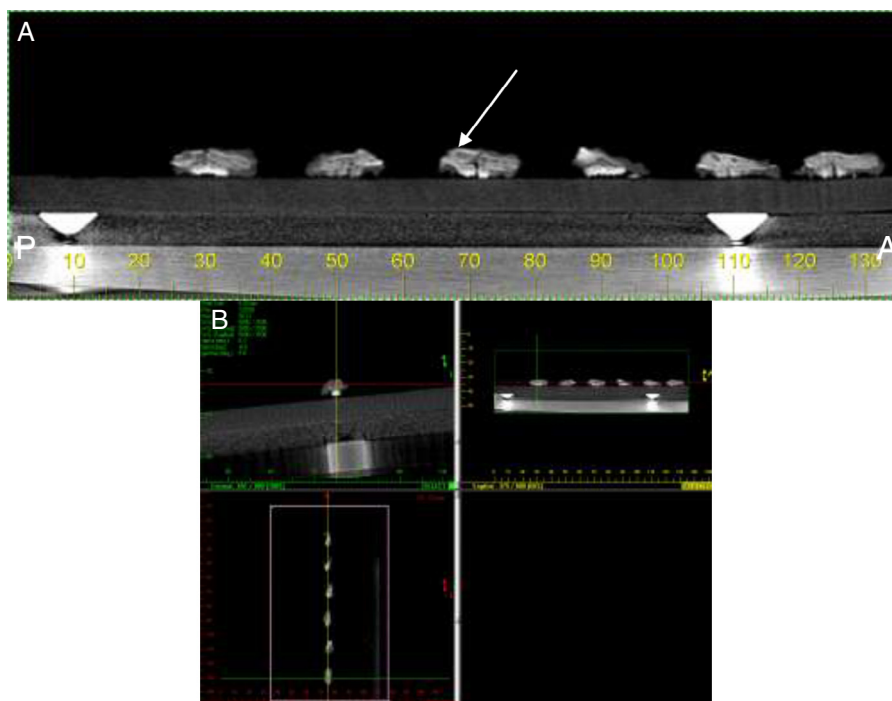
**Fig. 1.** Histopathological images of the naive (A), NT (B), V (C), GS5% (D), GS10% (E) and D10% (F) gel groups. Mesial region of the left second upper molar after 11 days of EPD induction. (A) Interproximal region shows a normal periodontal ligament (pl), alveolar bone (ab), dentin (d), cementum (c) and gingiva (g) with health sulcular and junctional epithelia in normal conformation (HE 100 $\times$ ). (B) and (C) Intense insertion loss and bone resorption (arrow) in the interproximal and furcation regions (HE 40 $\times$ ). (D) Loss of insertion and bone resorption in the interproximal region (Ir) with formation of bone sequestration (arrow) involved with inflammatory infiltrate (HE 40 $\times$ ). (E) and (F) Flat gingival papilla with apical migration of the junctional epithelium and discreet resorption of insertion periodonte to the ligature region (Ir) (HE 100 $\times$ ).



**Fig. 2.** Effect of the treatment with V, GS5%, GS10% and D10% gel on the EPD. Significant differences between means were found in comparison with the V group by ANOVA followed by the Bonferroni's test. \* $p < 0.05$ , \*\* $p < 0.01$  and \*\*\* $p < 0.001$ .



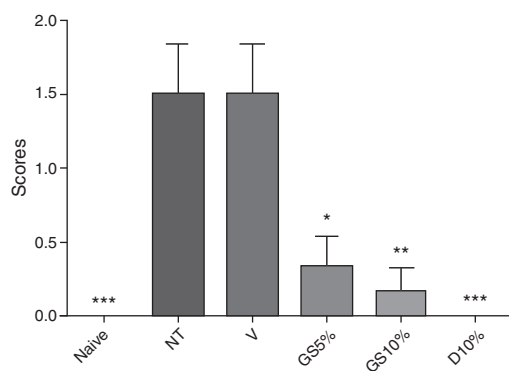
**Fig. 3.** Effect of the V, GS5%, GS10% and D10% in the variation of the body weight of rats submitted to EPD after 11 days of its induction. Data values are expressed as mean  $\pm$  SEM ( $n = 6$ ) and were measured each day before and after the EPD induction during 11 days. Significant differences between means were found in comparison with the naive group by ANOVA followed by the Dunnett's test. \* $p < 0.05$ , \*\* $p < 0.01$  and \*\*\* $p < 0.001$ .



**Fig. 4.** Cone-beam computed tomography images analyzed through three cuts: axial, sagittal and coronal. (A) Sagittal view evidencing the tomography of the six pieces of the NT group. The presence of bone resorption in the ligature region can be seen (arrow). (B) MPR screen of the classical i-Cat scanner (Imaging Sciences International). An exposition area of 6 cm and exposition time of 40 s with voxel of 0.2 mm (maximum resolution) was used. Images for the NT group.

et al., 2003, 2004). This periodontal disease model is characterized by a progressive accumulation of bacterial biofilm in the ligature with consequent increase of the inflammatory infiltrate, which will destroy the periodontal tissue (conjunctive and bone tissue).

The structure and the organization of the periodontal tissue in the molar tooth region in rats, including oral gingival epithelium, oral sulcular epithelium, junctional epithelium, collagen periodontal fibers, cellular and acellular cementum and alveolar bone, are very similar to the human teeth. The biggest difference consists in the fact that the gingival sulcular epithelium of rats is keratinized, but studies have shown that the gingival functional barrier is not different in rats and humans, although the extension of the affected area is larger in the later. Thus, the model used in the present study is able to reproduce the main characteristics found in human periodontitis and as such is appropriated for the study of this disease (Botelho et al., 2007).



**Fig. 5.** Effect of V, GS5%, GS10% and D10% gels in the bone resorption caused by the EPD. Significant differences between means were found in comparison with the V group by ANOVA followed by the Bonferroni's test. \* $p < 0.05$ , \*\* $p < 0.01$  and \*\*\* $p < 0.001$ .

Ligature placement around the first upper molar in the animals of the experimental groups provided an initial gingival lesion characterized by a microvascular dilation of the region with an increase on the hydrostatics pressure and fluid permeability, besides leukocyte displacement to the furrow (Botelho et al., 2010). In this study, the groups that did not receive treatment with *H. pectinata* or doxycycline gels behaved accordingly, as demonstrated by the NT and V groups, which were not statistically different when compared with each other and presented the symptoms of an acute lesion in the periodontal tissues (Holzhausen, 2002). The macroscopic results presented here suggest that the ligature placement around the animal teeth caused significant alterations in the gingival macroscopic characteristics, like redness, bleeding and curved papilla. These findings corroborate with Holzhausen (2002), which affirmed that in the development of the induced inflammatory periodontal disease, biofilm accumulation in the dental surfaces near the gingiva is the direct cause of the inflammation.

One of the possible regulatory pathways for the inflammatory response in periodontal diseases could be cytokine production by the different sub-populations of auxiliary T lymphocytes (T helper, Th), which would attenuate or increase the inflammatory reaction in the periodontal tissues, and determine the activity or latency of the periodontal disease (Gemmel and Seymour, 2006). Cytokines are mediators that act on several cell types to stimulate, inhibit or destroy the periodontal tissues (Lindhe, 1999) as demonstrated by the histopathological analysis of the animals in the groups with EPD (NT, V, GS5%, GS10% and D10%), where alveolar bone losses in varied degrees were present, while the naïve group (without EPD) did not show any sign of bone loss. These results corroborate with Nassar et al. (2003, 2004) and Botelho et al. (2007). It is believed that in normal physiologic situations, bone formation and resorption progression are in an equilibrium that is regulated so that bone resorption by osteoclasts precedes new bone formation by osteoblasts (Cueto-Manzano et al., 1999).

Leaf aqueous extract of the *H. pectinata* (CAE) was used in the present study due to the easy access that the low income

population has to this natural product as well as the easiness by which it can be manipulated for topic administration. Doxycycline was chosen not only due to its antimicrobial action, but also due to its anti-collagenolytic effect. Several authors demonstrated that the use of this drug is efficient as supporting agent in the periodontitis treatment because it acts by inhibiting metalloproteinases, consequently, reducing the destruction of the periodontal tissues. However, it is well-known that very high doses of this drug do little against the alterations in the susceptibility of the periodontal microflora, which in turn reduces the occurrence of bacterial resistance (Bezerra et al., 2000; Caton et al., 2001; Golub et al., 2001). Nonetheless, the topic application of the doxycycline gel was previously performed to treat periodontitis (Tomasi and Wennstrom, 2004; Machion et al., 2006; Botelho et al., 2007). The drug was proved effective by reducing bone resorption, bone turnover and number of microorganisms in the affected sites as well as the osteoclast activity. Thus, doxycycline was used as positive control. Administration of *H. pectinata* at 10% (GS 10%) immediately after the EPD induction significantly prevented the alveolar bone resorption similarly to the doxycycline gel (D10%).

Histopathological analysis and CBCT images evidenced tissue alterations and bone resorption in all groups with periodontal disease, although animals in GS5%, GS10% and D10% groups showed mild alterations when compared to NT and V groups, which presented intense cell inflammatory infiltrate after 11 days of EPD induction with total destruction of the alveolar bone, which was previously found by Bezerra et al. (2000), Lima et al. (2000) and Menezes et al. (2005). In a study evaluating the periodontal destruction due to the ligature placement when used together with antibiotics for the control of the bacterial film, the inhibition of the alveolar bone loss and the infectious feature of the experimental periodontitis were demonstrated (Sallay et al., 1982; Botelho et al., 2010). The findings in the present study suggest that *H. pectinata* gel may be inhibiting bone loss probably by controlling the formation of bacterial film.

Several studies have been done on the use of medicinal plants associated with the conventional periodontal treatment so that the anti-inflammatory effect can be observed as well as the reduction in the counting of the microorganisms responsible for tissue destruction of the dental element (Lee and Chung, 2004; Bakri and Douglas, 2005; Feres et al., 2005). In this context, a previous study involving *H. pectinata* showed the plant aqueous extract has monoterpenes, sesquiterpenes, sesquiterpenic lactones and triterpenes with important pharmacological activities. The hemostatic effect of the plant fresh leaves as well as the antimicrobial activity against *Escherichia coli*, *Staphylococcus aureus*, *Klebsiella pneumoniae*, *Pseudomonas aeruginosa* and *Streptococcus* sp. were demonstrated (Basílio et al., 2006). According to Juiz et al. (2010), plants with activity against periodontopathogens would be more effective if they also inhibited *S. mutans* growth because this organism facilitates the bacterial biofilm installation. Nascimento (2005) evaluated the in vitro antimicrobial potential of *H. pectinata* essential oil and found that its antimicrobial activity against *S. mutans* was equivalent to chlorhexidine. Moreover, the antinociceptive and anti-inflammatory effects of the *H. pectinata* leaf aqueous extract with low extract toxicity was also shown (Bispo et al., 2001; Paixão et al., 2013).

Thus, considering the results of studies on the antimicrobial and anti-inflammatory properties of *H. pectinata*, the findings here presented showed that *H. pectinata* CAE gels developed in the Laboratory of Pharmacotechnology of the Federal University of Sergipe decrease the initial inflammatory response, which reflected in the posterior consequences of the periodontal disease such as the bone resorption. This accentuated reduction of the neutrophil inflammatory infiltrate induced by the treatment with GS5%, GS10% and D10% in topical form could better explain the preservation of the

collagen fibers in the periodontal ligament, as well as the minor resorption of the alveolar bone.

A significant loss of body weight was observed for the animals in the NT and V groups, which was probably caused by the surgery trauma and acute inflammatory process that followed it, complicating animal chewing and feeding. However, treatment with *H. pectinata* and doxycycline reduced or prevented the inflammatory process, which in turn reduced the time its effect lasted in the animals, which were able to chew and eat fairly normally when compared with the NT and V groups. Animals treated with GS5%, GS10% and D10% progressively gained body weight from the 6th day after EPD induction. These findings are in accordance with the study of Lima et al. (2000), where the animal lost around 10% of their weight in the first day after EPD induction, but returned to their initial weight upon treatment. According to Botelho et al. (2007, 2010), the gel topic application have benefits by decreasing both the pain and the bacterial account as well as promoting oral conditions for a better feeding of the rats treated with gels based in natural products.

## Conclusions

This study demonstrates that the local application of a dental gel based on *H. pectinata* at 10% has anti-inflammatory effect and also prevents alveolar bone resorption and weight loss in animals with experimental periodontitis. The study revealed the great potential of the gel to combat periodontal diseases, although further studies are needed to clarify its usefulness in clinical situations.

## Conflict of interest

There is no conflict of interest.

## Authors' contributions

MSP, MSM, NPD, MGBO, AFS, DVAO, JSO, FTCA, FSA and LJQ-J contributed with pharmacological tests. AASA, BSA, CSE, MAB contributed with plant obtention and aqueous extract preparation. AASA, BSA, CSE, MAB and LJQ-J contributed with study design, analysis of results, preparation of the paper.

## References

- Bakri, I.M., Douglas, C.W.I., 2005. Inhibitory effect of garlic extract on oral bacteria. *Arch. Oral Biol.* 50, 645–651.
- Basílio, I.J.L.D., Agra, M.F., Rocha, E.A., Leal, C.K.A., Abrantes, H.F., 2006. Estudo farmacológico comparativo das folhas de *Hyptis pectinata* (L.) Poit. e *Hyptis suaveolens* (L.) Poit. (Lamiaceae). *Acta Farm. Bonaer.* 25, 518–525.
- Bezerra, M.M., De Lima, V., Alencar, V.B., Vieira, I.B., Brito, G.A., Ribeiro, R.A., Rocha, F.A., 2000. Selective cyclooxygenase-2 inhibition prevents alveolar bone loss in experimental periodontitis in rats. *J. Periodontol.* 71, 1009–1014.
- Bispo, M.D., Mourão, R.H., Franzotti, E.M., Bomfim, K.B., Arrigoni-Blank, M.F., Moreno, M.P., Marchioro, M., Antonioli, A.R., 2001. Antinociceptive and anti-inflammatory effects of the aqueous extract of *Hyptis pectinata* leaves in experimental animals. *J. Ethnopharmacol.* 76, 81–86.
- Bonjardim, L.R., Silva, A.M., Oliveira, M.G.B., Guimarães, A.G., Antonioli, A.R., Santana, M.F., Serafini, M.R., Santos, R.C., Araújo, A.A.S., Estevam, C.S., Santos, M.R.V., Lyra, A., Carvalho, R., Quintans-Júnior, L.J., Azevedo, E.G., Botelho, M.A., 2011. *Sida cordifolia* leaf extract reduces the orofacial nociceptive response in mice. *Phytother. Res.* 25, 1236–1241.
- Botelho, M.A., Paixão, M.S., Allegretti, C., Argentino-Júnior, J., Araújo, R., Rodrigues, K., Martins, E., Marinho, G., Queiroz, D., Ruela, R., Correia, J.M., Quintans-Júnior, L.J., 2010. Anti-inflammatory effect of diclofenac diethylammonium gel on acute phase of ligature induced periodontitis in rats. *Lat. Am. J. Pharm.* 29, 1371–1376.
- Botelho, M.A., Rao, V.S., Carvalho, C.B., Bezerra-Filho, J.G., Fonseca, S.G., Vale, M.L., Montenegro, D., Cunha, F., Ribeiro, R.A., Brito, G.A., 2007. *Lippia sidoides* and *Myracrodruon urundeuva* gel prevents alveolar bone resorption in experimental periodontitis in rats. *J. Ethnopharmacol.* 113, 471–478.
- Caton, J.G., Ciancio, S.G., Blieden, T.M., Bradshaw, M., Crout, R.J., Hefti, A.F., Massaro, J.M., Polson, A.M., Thomas, J., Walker, C., 2001. Subantimicrobial dose doxycycline as an adjunct to scaling and root planning: post-treatment effects. *J. Clin. Periodontol.* 28, 782–789.

- Chambrone, L.A., Chambrone, L., 2006. Tooth loss in well-maintained patients with chronic periodontitis during longterm supportive therapy in Brazil. *J. Clin. Periodontol.* 33, 759–764.
- Chung, J.Y., Choo, J.H., Lee, M.H., Hwang, J.K., 2006. Anticariogenic activity of macelignan isolated from *Myristica fragrans* (nutmeg) against *Streptococcus mutans*. *Phytomedicine* 4, 261–266.
- Cueto-Manzano, A.M., Konel, S., Hutchison, A.J., Crowley, V., France, M.W., Freemont, A.J., Adams, J.E., Mawer, B., Gokal, R., 1999. Bone loss in long-term renal transplantation: histopathology and densitometry analysis. *Kidney Int.* 55, 2021–2029.
- Duarte, S., Rosalen, P.L., Hayacibara, M.F., Cury, J.A., Bowen, W.H., Marquis, R.E., Rehder, V.L., Sartoratto, A., Ikegaki, M., Koo, H., 2006. The influence of a novel propolis on mutans streptococci biofilms and caries development in rats. *Arch. Oral Biol.* 51, 15–22.
- Feres, M., Figueiredo, L.C., Barreto, I.M., Coelho, M.H., Araújo, M.W., Cortelli, S.C., 2005. *In vitro* antimicrobial activity of plant extracts and própolis in saliva samples of healthy and periodontally-involved subjects. *J. Int. Acad. Periodontol.* 7, 90–96.
- Franco, C.R., Antonioli, A.R., Guimarães, A.G., Andrade, D.M., Jesus, H.C., Alves, P.B., Bannet, L.E., Patrus, A.H., Azevedo, E.G., Queiroz, D.B., Quintans-Júnior, L.J., Botelho, M.A., 2011. Bioassay-guided evaluation of antinociceptive properties and chemical variability of the essential oil of *Hyptis fruticosa*. *Phytother. Res.* 25, 1693–1699.
- Gemmel, E., Seymour, G.J., 2006. Regulação imune dos perfis de citocinas Th1/Th2 na doença periodontal. In: Gemmel, E., Seymour, G.J. (Eds.), *Periodontologia 2000: Controle imunológico na Doença Periodontal*. Editora Santos, Santos, pp. 21–41.
- Golub, L.M., McNamara, T.F., Ryan, M.E., Kohut, B., Blieden, T., Payonk, G., Sipos, T., Baron, H.J., 2001. Adjunctive treatment with subantimicrobial doses of doxycycline: effects on gingival fluid collagenases activity and attachment loss in adult periodontitis. *J. Clin. Periodontol.* 28, 146–156.
- Holzhausen, M., (Dissertation, M.S. in Periodontology) 2002. Efeito do celecoxib sobre o desenvolvimento de doença periodontal induzida em ratos. Faculty of Odontology, State University of São Paulo, Araraquara, 123 pp.
- Guimarães, A.G., Quintans, J.S., Quintans-Júnior, L.J., 2013. Monoterpenes with analgesic activity – a systematic review. *Phytother. Res.* 27, 1–15.
- Juiz, P.J.L., Alves, R.J.C., Barros, T.F., 2010. Uso de produtos naturais como coadjuvante no tratamento da doença periodontal. *Braz. J. Pharmacogn.* 20, 134–139.
- Lee, J.H., Chung, M.S., 2004. *In vitro* anti-adhesive activity of an acidic polysaccharide from *Panax ginseng* on *Porphyromonas gingivalis* binding to erythrocytes. *Planta Med.* 70, 566–568.
- Lima, V., Bezerra, M.M., Alencar, V.B.M., Vidal, F.D., Rocha, F.A., Brito, G.A.C., Ribeiro, R.A., 2000. Effects of chlorpromazine on alveolar bone loss in experimental periodontal disease in rats. *Eur. J. Oral Sci.* 108, 123–129.
- Lindhe, J., 1999. *Tratado de periodontia clínica e implantologia oral*. Guanabara Koogan, Rio de Janeiro, pp. 720.
- Machion, L., Andia, D.C., Lecio, G., Nociti, F.H., Casati, M.Z., Sallum, A.W., Sallum, E.A., 2006. Locally delivered doxycycline as an adjunctive therapy to scaling and root planing in the treatment of smokers: a 2-year follow-up. *J. Periodontol.* 77, 606–613.
- Martinez, M., 1989. *Las Plantas Medicinales de México*. Editorial Botas, Mexico, pp. 508.
- Menezes, A.M., Rocha, F.A., Chaves, H.V., Carvalho, C.B., Ribeiro, R.A., Brito, G.A., 2005. Effect of sodium alendronate on alveolar bone resorption in experimental periodontitis in rats. *J. Periodontol.* 76, 1901–1909.
- Nascimento, P.F.C., (São Cristóvão. Dissertação de mestrado) 2005. Avaliação *in vitro* do potencial antimicrobiano do óleo essencial de *Hyptis pectinata* (L.) Poit. e de colutórios sobre os *Streptococcus mutans*. Faculdade de Medicina, Universidade Federal de Sergipe.
- Nassar, C.A., Nassar, P.O., Abi Rached, R.S., Holzhausen, M., Marcantonio, E., Spolidorio, L.C., 2004. Effect of cyclosporin A on alveolar bone homeostasis in a rat periodontitis model. *J. Periodontol. Res.* 39, 143–148.
- Nassar, C.A., Nassar, P.O., Spolidorio, D.M.P., Spolidorio, L.C., 2003. Efeito de anti-inflamatório no desenvolvimento da doença periodontal induzida: avaliação radiográfica em ratos. *Rev. Odontol. UNESP* 32, 125–130.
- Oliveira, L.M., Nepomuceno, C.F., Freitas, N.P., Pereira, D.M.S., Silva, G.C., Lucchese, A.M., 2011. Vegetative propagation of *Hyptis leucocephala* Mart. ex Benth and *Hyptis platanifolia* Mart. ex Benth (Lamiaceae). *Rev. Bras. Plantas Med.* 13, 73–78.
- Pai, M.R., Acharya, L.D., Udupa, N., 2004. Evaluation of antiplaque activity of *Azadirachta indica* leaf extract gel-a 6-week clinical study. *J. Ethnopharmacol.* 90, 99–103.
- Paixão, M.S., Melo, M.S., Oliveira, M.G., Santana, M.T., Lima, A.C., Damascena, N.P., Dias, A.S., Araujo, B.S., Estevam, C.S., Botelho, M.A., Quintans-Júnior, L.J., 2013. *Hyptis pectinata*: redox protection and orofacial antinociception. *Phytother. Res.* 27, 1328–1333.
- Petersen, P.E., Yamamoto, T., 2005. Improving the oral health of older people: the approach of the WHO Global Oral Health Programme. *Community Dent. Oral Epidemiol.* 33, 81–92.
- Quintans, J.S.S., Costa, E.V., Tavares, J.F., Souza, T.T., Araújo, S.S., Estevam, C.S., Barison, A., Cabral, A.G.S., Silva, M.S., Serafini, M.R., Quintans-Júnior, L.J., 2014. Phytochemical study and antinociceptive effect of the hexanic extract of leaves from *Combretum duaratanum* and friedelin, a triterpene isolated from the hexanic extract, in orofacial nociceptive protocols. *Rev. Bras. Pharmacogn.* 24, 60–66.
- Quintans-Júnior, L.J., Melo, M.S., De Sousa, D.P., Araujo, A.A.S., Onofre, A.S.C., Gelain, D.P., Gonçalves, J.C.R., Araújo, D.A.M., Almeida, J.R.G.S., Bonjardim, L.R., 2010. Antinociceptive effects of citronellal in formalin-, capsaicin-, and glutamate-induced orofacial nociception in rodents and its action on nerve excitability. *J. Orofac. Pain* 24, 305–312.
- Sallay, K., Sanavi, F., Ring, I., Pham, P., Behling, U.H., Nowotny, A., 1982. Alveolar bone destruction in the immunosuppressed rat. *J. Periodontol. Res.* 17, 263–274.
- Santos, P.O., Costa, M.J.C., Alves, J.A.B., Nascimeto, P.F.C., Melo, D.L.F.M., Barbosa Jr., A.M.B., Trindade, R.C., Blank, A.F., Arrigoni-Blank, M.F., Alves, P.B., Nascimento, M.P.F., 2008. Chemical composition and antimicrobial activity of the essential oil of *Hyptis pectinata* (L.) Poit. *Quim. Nova* 31, 1648–1652.
- Siqueira, R.S.S., Bonjardim, L.R., Araujo, A.A.S., Araújo, B.E.S., Melo, M.G.D., Oliveira, M.G.B., Gelain, D.P., Silva, F.A., de Santana, J.M., Rocha, R.F., Moreira, J.C.F., Antonioli, A.R., Quintans-Júnior, L.J., 2010. Antinociceptive activity of atranorin in mice orofacial nociception tests. *Z. Naturforsch. C* 65, 551–561.
- Siqueira-Lima, P.S., Araújo, A.A.S., Lucchese, A.M., Quintans, J.S.S., Menezes, P.P., Alves, P.B., Lucca Júnior, W., Santos, M.R.V., Bonjardim, L.R., Quintans-Júnior, L.J., 2014. Beta-cyclodextrin complex containing *Lippia grata* leaf essential oil reduces orofacial nociception in mice – evidence of possible involvement of descending inhibitory pain modulation pathway. *Basic Clin. Pharmacol. Toxicol.* 114, 188–196.
- Takarada, K., Kimizuka, R., Takahashi, N., Honma, K., Okuda, K., Kato, T., 2004. A comparison of the antibacterial efficacies of essential oils against oral pathogens. *Oral Microbiol. Immunol.* 19, 61–64.
- Tinoco, E.M.B., Tinoco, N.M.B., 2000. Diagnóstico e Prevenção das Doenças Periodontais. In: Buischi, Y.P. (Ed.), *Promoção de Saúde Bucal na Clínica Odontológica*. Artes Médicas, São Paulo, pp. 99–123.
- Tomasi, C., Wennstrom, J.L., 2004. Locally delivered doxycycline improves the healing following non-surgical periodontal therapy in smokers. *J. Clin. Periodontol.* 31, 589–595.