

Anatomical relationship between the posterior mitral valve annulus and the coronary arteries. Implications to operative treatment

Relação anatômica entre a porção posterior do ânulo mitral e as artérias coronárias: implicações no tratamento cirúrgico

Clodualdo J. N. PESSA, Walter J. GOMES, Roberto CATANI, José Carlos PRATES, Enio BUFFOLO

RBCCV 44205-710

Abstract

Objective: This work aimed at analyzing the anatomical relationship among the mitral annulus, the circumflex artery and the posterior left ventricular artery, correlating the distance among these structures to the pattern of coronary network dominance.

Method: Eighty-five human hearts, previously preserved in 10% formaldehyde solution, were studied. The coronary network dominance pattern was initially evaluated. Next, atriotomy and left ventriculotomy in the posterior wall of the heart were performed, starting from the pulmonary veins toward the heart apex through the mitral annulus. The atrial wall was removed near the annulus, all around the posterior annulus. Five points were demarcated on the annulus: 1: - anterior commissure, 2: - between the anterior commissure and the midpoint of the posterior annulus, 3: - midpoint of the posterior annulus, 4: - between the midpoint of the posterior annulus and the posterior commissure, 5: - posterior

commissure. The distance among the structures was measured through these points with an electronic caliper.

Results: Right dominance was observed in 81.17% of the cases, balanced dominance in 16.47% and left dominance in 2.35%. Right dominant hearts showed that the region of lowest distance between the annulus and the coronary arteries was the anterior commissure, where the circumflex artery was distant to the annulus 3.996 ± 1.865 mm while the region of greatest distance was the posterior commissure, measuring 7.783 ± 2.615 mm.

Conclusion: This study provided better understanding of the anatomical relationship between the mitral valve and the adjacent coronary arteries, thereby helping cardiac surgeons to prevent operative complications.

Descriptors: Mitral valve. Heart surgery procedures. Coronary circulation. Myocardial infarction.

Work performed in the Cardiovascular Surgery Department – Surgery Department and Descriptive and Topographic Anatomy Section – Morphology Department Paulista Medical School–Federal University of São Paulo.

Work presented at the VII Congress of the Cardiovascular Surgery Society of the State of São Paulo, Campos do Jordão, November 2003 and the 31° National Congress of Heart Surgery, Curitiba, April 2004.

This article is part of the master's dissertation of Dr Clodualdo J. N. Pessa (Coordinator: Prof. Dr. Walter J. Gomes).

Correspondence address: Clodualdo J. N. Pessa. Rua Machado Bittencourt, 379 Ap 71 – 04044-001, Vila Clementino – São Paulo SP. Phone: (11) 5084-3220.
E-mail: clodualdopessa@yahoo.com.br

Article received in September, 2004
Article accepted on December, 2004

Resumo

Objetivo: Este trabalho objetivou analisar a relação anatômica entre o ânulo da valva atrioventricular esquerda (mitral), a artéria circunflexa e a artéria posterior do ventrículo esquerdo, relacionando a distância entre as estruturas citadas ao padrão de dominância coronariana.

Método: Foram estudados 85 corações humanos, previamente fixados em solução de formaldeído a 10%. Inicialmente, avaliou-se o padrão de dominância coronariana. A seguir, realizou-se atriotomia e ventriculotomia esquerdas na parede posterior do coração, a partir das veias pulmonares em direção ao ápice cardíaco, seccionando-se o ânulo mitral. Removeu-se a parede atrial ao nível do ânulo, em toda a porção da cúspide posterior. Sobre o ânulo foram demarcados cinco pontos: 1 - comissural anterior, 2 - entre o comissural anterior e o ponto médio posterior do ânulo, 3 - ponto médio posterior do ânulo, 4 - entre o ponto médio posterior do ânulo e o comissural posterior, 5 - comissural posterior. Nestes

pontos foi medida a distância entre as estruturas com um paquímetro eletrônico.

Resultados: Padrão de dominância direita foi observado em 81,17% dos casos, circulação balanceada em 16,47% e dominância esquerda em 2,35%. Nos corações que apresentaram dominância direita observou-se que a região de maior proximidade entre o ânulo e as estruturas vasculares foi a comissural anterior, $3,996 \pm 1,865$ mm, enquanto a região de menor proximidade foi a comissural posterior, medindo $7,78 \pm 2,615$ mm.

Conclusão: Este estudo propiciou melhor compreensão da relação anatômica entre a valva mitral e as artérias coronárias adjacentes, podendo auxiliar o cirurgião na diminuição de complicações cirúrgicas.

Descritores: Valva mitral. Procedimentos cirúrgicos cardíacos. Circulação coronária. Infarto do miocárdio.

INTRODUCTION

Surgical procedures involving the left atrioventricular valve (mitral valve) have always been associated with a potential risk of acute myocardial infarction [1-4], and secondarily with the iatrogenic injury of the circumflex artery and of the posterior artery of the left ventricle. This complication is caused by the variability of the anatomical relationships that exist between the posterior segment of the mitral annulus and the coronary arteries that run through the left portion of the coronary network.

Previous studies have shown there is a relationship between the mean distance of the mitral annulus from the adjacent coronary arteries and the dominance pattern of the coronary network. However, there have been few works that analysed this anatomical relationship, just as the numbers of patients that have been studied is small [1,2,5-17].

The aim of this study is to analyze the anatomical relationship between the mitral valve annulus and the coronary arteries located in the left portion of the coronary network near to the posterior cusp of the mitral valve.

METHOD

Hearts, which had been previously preserved in 10% formaldehyde solution, from 85 adult men and women with ages ranging from 24 to 74 were studied. The hearts came from the Topographic and Descriptive Anatomy Section of the Morphology Department of the Paulista School of Medicine, Federal University of São Paulo.

Left atriotomy and ventriculotomy in the posterior wall of the heart were performed from the pulmonary veins towards the heart apex, sectioning the mitral annulus. By

opening this line, the transition region between the mitral valve system, left atrial wall and the left ventricle was identified.

Posteriorly, the entire portion of the atrial wall near to the mitral annulus corresponding to the posterior cusp was removed. Thus it was possible to see the whole valvar annulus and the coronary arteries that exist in the left portion of the coronary network.

By anatomical dissection, the parts were classified according to the coronary dominance pattern either as: right dominance, left dominance or balanced dominance, according to the description shown in Table 1 [1,6,12,18-22].

Table 1. Pattern of coronary network dominance

Coronary Pattern	Description
Right dominance	The posterior interventricular artery and the posterior artery of the left ventricle originate from the right coronary artery
Left dominance	The posterior interventricular artery and the posterior artery of the left ventricle originate from the left coronary artery
Balanced circulation	The posterior interventricular artery originates from the right coronary artery The posterior wall of the left ventricle is irrigated by the circumflex artery

The posterior portion of the mitral annulus was delineated using five main points, which were numbered from 1 to 5 in an anticlockwise direction [1]: the two

commissures (anterior and posterior), one point in the posterior midpoint of the annulus and the other two, at the midpoint between the commissures and the posterior midpoint of the annulus. The distances were measured, in millimeters, between the mitral annulus through these points to the coronary arteries, as shown in the Figures 1 and 2.

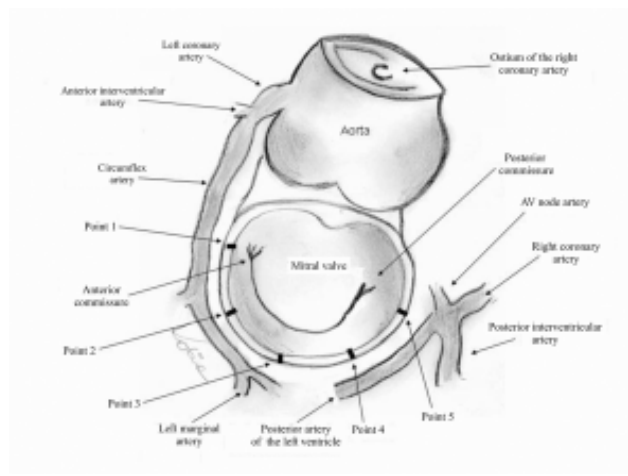


Fig. 1 – Demarcation of the posterior portion of the mitral valve annulus

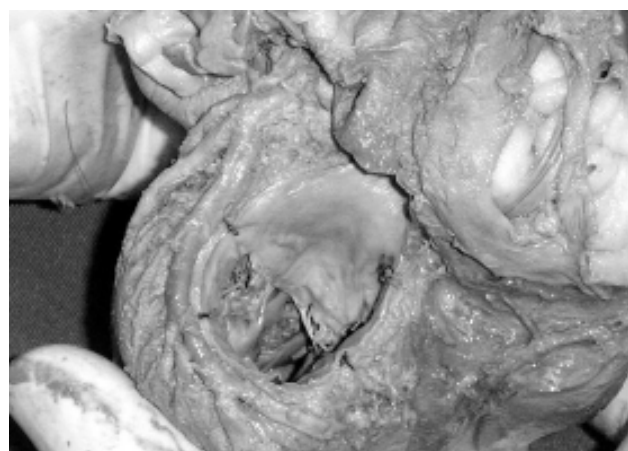

Fig. 2 – Anatomical specimen with balanced circulation. Anatomic relationship between the studied structures

Statistical analysis of the data was achieved using the Student-Newman-Keuls test to compare the mean distances. The data are presented as means and standard-deviations. A p-value < 0.05 was considered significant.

The study was approved by the Ethics Committee on Research of the Federal University of São Paulo.

RESULTS

Pattern of coronary dominance

Sixty-nine patients (81.17%) presented with right coronary dominance, fourteen patients (16.47%) with balanced dominance and two patients (2.35%) with left coronary dominance.

Distance between the mitral annulus and the coronary arteries in hearts with right dominance

The shortest distance between the mitral annulus and the coronary arteries occurred at Point 1 (3.99 ± 1.86 mm), while the longest distance occurred at Point 5 (7.78 ± 2.61 mm), as demonstrated in Figure 3.




Fig. 3 – Mean distance (in mm) between the mitral annulus and the arteries that circulate in hearts with right dominance at the five predetermined points

Statistical analysis revealed that there were statistically significant differences between the mean distances at Point 1 compared to other points ($p < 0.01$). The same occurred when comparing the mean distance at Point 2 and at Points 3, 4 and 5. However significant differences were not observed when comparing the distances at Points 3, 4 and 5 as shown in Table 2.

Distance between the mitral annulus and the coronary arteries in hearts with balanced dominance

In the hearts with balanced dominance, the shortest distance between the structures was also observed at Point 1 (3.56 ± 1.63 mm), whilst the longest distance was found at Point 3 (6.52 ± 2.48 mm), as shown in Table 3.

Distance between the mitral annulus and the coronary arteries in hearts with left dominance

In this study only two hearts were observed with left dominance (incidence of 2.35%). The data which refer to these patients are shown in Table 4.

Table 2. Distance (in mm) between the mitral annulus and the arteries that circulate in hearts with right dominance at the five predetermined points

Data	Point 1	Point 2	Point 3	Point 4	Point 5
N	69	68	40	37	56
Minimum distance	1.01	1.53	2.53	1.92	1.50
Maximum distance	11.80	13.20	15.90	12.70	13.10
Mean	3.99	5.50**	7.20***††	6.75***†	7.78***†††
SD	1.86	2.40	3.77	3.20	2.61
Minimum CI 95%	3.54	4.92	5.99	5.68	7.08
Maximum CI 95%	4.44	6.08	8.41	7.82	8.48

** p<0.01 vs. Point 1 *** p<0.001 vs. Point 1 † p<0.05 vs. Point 2 †† p<0.01 vs. Point 2 ††† p<0.001 vs. Point 2

DP – Standard deviation, IC – Confidence interval

Table 3. Distance (in mm) between the mitral annulus and the arteries that circulate in hearts with balanced circulation at the five predetermined points

Data	Point 1	Point 2	Point 3	Point 4	Point 5
N	14	14	13	9	2
Minimum distance	1.84	2.33	2.62	3.37	1.21
Maximum distance	7.45	8.47	14.6	10.3	4.83
Mean	3.56	4.51	6.41	6.52	
SD	1.63	1.70	3.42	2.48	

SD – Standard deviation

Table 4. Distance (in mm) between the mitral annulus and the arteries that circulate in hearts with left dominance at the five predetermined points

Heart	Point 1	Point 2	Point 3	Point 4	Point 5
Número 35	4.09	5.73	4.61	3.70	4.69
Número 69	3.69	3.84	2.18	4.77	10.8

Passage of the arteries in the left portion of the coronary network in hearts with right dominance

In this study, the circumflex artery was present in the left portion of the coronary network at Points 1 and 2 in 100% of cases. In 55% of the patients, the circumflex artery reached Point 3 and only in 7.24% of cases it was present at Point 4. The circumflex artery was never present at Point 5.

The posterior artery of the left ventricle, a branch of the right coronary artery, was present in the left portion of the coronary network mainly at Points 3, 4 and 5. At Point 5 it

was present in 81% of the cases, at Point 4 in 46% and only in 2.89% it reached Point 3. The posterior artery of the left ventricle was never present at Points 1 and 2.

Passage of the arteries in the left portion of the coronary network in hearts with balanced dominance

In this subgroup, the circumflex artery was present in the left portion of the coronary network at Points 1 and 2 in 100% of the cases. In 92.8% of them, it arrived at Point 3 and in 64.2%, Point 4. However, only in 14.2% of the cases it reached Point 5.

In two cases (14.2%), an arterial branch from the right coronary artery was observed in the coronary network near to the posterior commissural region – Point 5.

COMMENTS

In our sample, the distribution of the hearts according to the pattern of coronary artery dominance gave right dominance supremacy, observed in 81.17% of the cases. In the literature [18,19], we observed a small number of hearts in the subgroup of hearts with left dominance, which in our sample was equivalent to only 2.35%. Thus, our results are similar to previously published studies.

Considering the passage of the arteries in the left portion of the coronary network, we verified that the circumflex artery was more prevalent at Points 1 and 2, while the posterior artery of the left ventricle was mainly observed at Points 4 and 5.

Analyzing the data from the hearts with balanced dominance, we noted that the results were similar to those found the hearts with right dominance. The number

of hearts with left dominance (only two cases) was insufficient to make any statistical analysis realistic.

In respect to the subgroup with right dominance, we observed that the anterior commissural region was on the shortest line between the circumflex artery and the mitral valvar annulus (3.99 ± 1.86 mm); in some cases these structures were separated by only 1.01 mm. The posterior commissural region – Point 5, was at a point of greatest separation of the posterior artery of the left ventricle from

the mitral annulus (7.78 ± 2.61 mm).

Our data were discordant to the results presented by CORNU et al. [1], as, according to these authors, the distance between the structures in the anterior commissural regions, in the case of right dominance, is 8 mm. Using a different methodology, VIRMANI et al. [13] affirmed that, in this subgroup of patients, the distance between the structures in question, in the proximal portion of the circumflex artery, is 8.4 mm.

Before this paper, published results suggested that if an injury of the circumflex artery in patients with right dominance is not observed, it was due to the great distance between these structures. However, our results decisively contradict and discarded this possibility. Thus, we understand that susceptibility to iatrogenic injury of the circumflex artery is not related to the pattern of coronary network dominance.

Iatrogenic injuries of the coronary arteries associated with mitral valve surgery as mentioned in the literature occurred predominantly in the anterior commissural region. Vascular injury appeared in two situations: in the first case the suture that anchors the prosthesis in the annulus of the valve transfixated the artery [5], changing its shape and causing partial or subtotal obstruction. The other possibility was total occlusion of the artery due to its inclusion by the suture [14,16]. The repercussions of the vascular lesion are associated to the type of injury, partial obstruction or occlusion [5,14,16], the location of the injured artery, the preoperative myocardial reserve and the coronary network dominance. Its clinical manifestation is expressed by unexpected cardiogenic shock in the intraoperative or the immediate postoperative periods, followed by an increase in the ST segment, the appearance of refractory ventricular arrhythmias, an increase in the levels of the cardiac enzymes and difficulty to take the patient off the bypass (CPB) [16].

According to the authors, injury of the circumflex artery may be suspected in the intraoperative period due to the absence of blood flow, which can be demonstrated by coronary Doppler ultrasound or by hypokinesia of the lateral-posterior wall of the left ventricle seen using intraoperative echocardiogram [12]. Treatment may involve venous grafting to the infarcted area [6,11,12,16] or reopening of the left atrium and re-suturing the posterior portion of the mitral annulus [14].

We concluded that the present study adds to previously published data and thus improves the understanding of the surgical anatomy of the mitral valve, and may contribute to reducing the incidence of iatrogenic injuries of arteries that circle the posterior portion of the annulus.

BIBLIOGRAPHIC REFERENCES

1. Cornu E, Lacroix PH, Christides C, Laskar M. Coronary artery damage during mitral valve replacement. *J Cardiovasc Surg* 1995;36:261-4.
2. Ellis FH Jr, Callahan JA, McGoan DC, Kirklin JW. Results of open operation for acquired mitral-valve disease. *N Eng J Med* 1965;272:869-74.
3. Khonsari S. Atlas de cirurgia cardíaca. Cuidados em técnica operatória. 1ª ed. Santos:Livraria e Editora Santos;1990. p.63-88.
4. Wells FC, Shapiro LM. Mitral valve disease. 1st ed. Oxford:Butterworth-Heinemann;1996. p.135-47.
5. Danielson GK, Cooper E, Tweedore DN. Circumflex coronary injury during mitral valve replacement. *Ann Thorac Surg* 1967;4:53-9.
6. Morin D, Fischer AP, Sohl BE, Sadeghi H. Iatrogenic myocardial infarction: a possible complication of mitral valve surgery related to anatomical variation of the circumflex coronary artery. *Thorac Cardiovasc Surg* 1982;30:176-9.
7. Mulpur AK, Kotidis KN, Nair UR. Partial circumflex artery injury during mitral valve replacement: late presentation. *J Cardiovasc Surg* 2000;41:333-4.
8. Roberts WC, Morrow AG. Compression of anomalous left circumflex coronary arteries by prosthetic valve fixation rings. *J Thorac Cardiovasc Surg* 1969;57:834-8.
9. Roberts WC. Complications of cardiac valve replacement: characteristic abnormalities of prostheses pertaining to any or specific site. *Am Heart J* 1992;103:113-22.
10. Roberts WC, Morrow AG. Causes of early postoperative death following cardiac valve replacement: clinico-pathologic correlations in 64 patients studied at necropsy. *J Thorac Cardiovasc Surg* 1967;54:422-37.
11. Speziale G, Fattouch K, Ruvolo G, Fiorenza G, Papalia U, Marino B. Myocardial infarction caused by compression of anomalous circumflex coronary artery after mitral valve replacement. *Minerva Cardioangiol* 1998;46:455-6.
12. Tavilla G, Pacini D. Damage to the circumflex coronary artery during mitral valve repair with sliding leaflet technique. *Ann Thorac Surg* 1998;66:2091-3.
13. Toyoda Y, Shida T, Wakita N, Matoba Y, Ozaki N. Mitral valve replacement in a patient with an extensively calcified mitral annulus: report of a case. *Surg Today* 1998;28:427-9.

-
14. Martin Trenor A, Arcas Meca R, Baz Iglesias R, Contreras R. Lesion de la arteria circunfleja izquierda despues de la colocacion de protesis mitrales en presencia de valvulas mitrales calcificadas. *Arch Inst Cardiol Mex* 1973;43:451-6.
 15. Veinot JP, Acharya VC, Bedard P. Compression of anomalous circumflex coronary artery prosthetic valve ring. *Ann Thorac Surg* 1998;66:2093-4.
 16. Virmani R, Chun PK, Parker J, McAllister HA. Suture obliteration of the circumflex coronary artery in three patients undergoing mitral valve operation: role of left dominant or codominant coronary artery. *J Thorac Cardiovasc Surg* 1982;84:773-8.
 17. Hughes RK. Complications of Starr-Edwards mitral valve replacement. *J Thorac Cardiovasc Surg* 1965;49:731-8.
 18. Falci Junior R, Cabral RH, Prates NEVB. Tipos de circulação e predominância das artérias coronárias em corações de brasileiros. *Rev Bras Cir Cardiovasc* 1993;8:152-62.
 19. Stolf NAG, Jatene AD. Tratamento cirúrgico da insuficiência coronariana. 1ª ed. São Paulo:Editora Atheneu;1998. p.17-23.
 20. Gray H, Goss CH. Anatomia. 29ª ed. Rio de Janeiro:Editora Guanabara;1988. p.472-4.
 21. Sobotta J. Atlas de anatomia humana. 19ª ed. Rio de Janeiro:Editora Guanabara Koogan;1990. p.91-117.
 22. James TN. Anatomy of the coronary artery. 1st ed. New York:Harper & Brothers;1961. p.31-75.