

Unusual presentation of idiopathic chronic constrictive pericarditis

Forma inusitada de pericardite crônica constrictiva idiopática

Moacir Fernandes de GODOY¹, Fábio Barros DE FRANCISCHI², Paulo Roberto PAVARINO³, Marcos Aurélio Barboza de OLIVEIRA⁴, Marcelo José Ferreira SOARES⁵, Domingo Marcolino BRAILE⁶

RBCCV 44205-862

Abstract

A 55-year-old male patient presented in our service with progressive dyspnea and ascitis beginning 1 year and 8 months previously. He weighed 160 kg (normal weight 95 kg), with ascitis and orthopnea. On admission he presented normal echocardiograms. An electrocardiogram showed diffuse inverted T waves. An endomyocardial biopsy was not elucidative. A new echocardiogram confirmed a very thick pericardium. Surgical pericardial resection was indicated.

The postoperative period was uneventful with complete remission of symptoms. The anatomopathological analysis was normal. The pericarditis was classified as idiopathic. This case is a warning for the need of much suspicion in patients with apparent causeless voluminous ascitis.

Descriptors: Pericarditis, constrictive. Heart failure, congestive. Cardiomyopathy, restrictive. Echocardiography.

1. Livre-Docente in Cardiology. Adjunct Professor of the Cardiology and Cardiovascular Surgery Department in the Medical School in São José do Rio Preto (FAMERP)

2. Medical Student of the Medical School in São José do Rio Preto.

3. PhD in Health Sciences by FAMERP; Adjunct Professor of the Cardiology and Cardiovascular Surgery Department in the Medical School in São José do Rio Preto (FAMERP)

4. Resident in Cardiovascular Surgery; Assistant Medical Doctor of the Heart Surgery Service of Hospital de Base Regional Medical School Foundation (FUNFARME)

5. Full member of the Brazilian Society of Cardiovascular Surgery (SBCCV); Surgeon Responsible for the Heart Surgery Service of Hospital de Base Regional Medical School Foundation (FUNFARME)

6. Livre Docente in Cardiovascular Surgery (Adjunct Professor of the Cardiology and Cardiovascular Surgery Department of the Medical School in São José do Rio Preto (FAMERP) and Adjunct Director of Postgraduation of FAMERP

Work performed in the Medical School in São José do Rio Preto (FAMERP). Hospital de Base Regional Medical School Foundation (FUNFARME)

Correspondence address: Moacir Fernandes de Godoy. Rua Garabed Karabashian, 570 - Bairro Mansur Daud - São José do Rio Preto - SP - CEP 15070-600.

E-mail: mfgodoy@netsite.com.br

Article received in September 10th, 2006

Article accepted in March 7th, 2007

Resumo

Paciente masculino, 55 anos, com queixa progressiva há 1 ano e 8 meses. Estava com 160kg (habitual 95 kg), extremamente edemaciado, com ortopnéia. Trouxe exames ecocardiográficos normais e eletrocardiograma com inversão de onda T. Biópsia endomiocárdica afastou fibrose endomiocárdica ou cardiomiopatia restritiva, mas as curvas pressóricas eram típicas de processo restritivo. Novo ecocardiograma agora mostrou pericárdio bastante espesso.

Indicada pericardiectomia, recebendo alta com remissão completa dos sintomas. O estudo anatomopatológico foi inespecífico, sendo a pericardite classificada como idiopática. O caso alerta para a necessidade de alto grau de suspeição de pericardite constrictiva em pacientes com ascite volumosa sem causa aparente.

Descritores: Pericardite constrictiva. Insuficiência cardíaca congestiva. Cardiomiopatia restritiva. Ecocardiografia.

INTRODUCTION

The pericardium is an avascular fibrotic bag that envelops the heart. It is composed of two layers: the visceral, attached at the pericardium and the parietal, composed of collagen and elastin. One slides over the other, and, between them, there is a small quantity of serous fluid (25 to 30 mL). As it is inelastic, the pericardium restricts acute cardiac dilatations, however it may adapt over a long period [1].

Chronic Constrictive Pericarditis (CCP) is characterized by the presence of inflamed and fused thick fibrotic pericarditis, which restricts diastolic filling of the heart [1-3]. It is rare in children and the diagnosis is difficult to determine; the etiology in 60% of cases is not elucidated [4]. However, it is frequently confused with other diagnoses, such as chronic liver disease, restrictive cardiomyopathy and idiopathic cardiopathy [5]. The objective of this work is to report on an advanced case of constrictive pericarditis, that evolved with severe decompensation and finally, after diagnosis and surgery, presented excellent recovery with complete improvement of the signs and symptoms.

CASE REPORT

DS, a 55-year-old man looked for medical assistance in November 2005, with a history of swelling of the abdomen and lower limbs over a period of 1 year and 8 months. This was accompanied with weakness and breathlessness at slight to medium effort. Seven months previous to this consultation, the patient initiated treatment in another medical service, with suspicion of liver disease and was medicated with furosemide. However, his condition progressively worsened with extreme swelling of the lower limbs and abdomen, significant limitations on effort, difficulty to walk and to lie down in the supine position. He said he had not suffered fever, hematemesis, melena, urinary alterations, choloria, jaundice, coughing, palpitations, precordialgia, abdominal pain, changes in bowel habits, constipation, diarrhea and vomits. Additionally, he did not

have bronchitis, diabetes, tuberculosis, allergies and asthma. He reported systemic arterial hypertension and took 300mg Irbesartan per day.

He said he was a little anxious, but was not taking medications. He used to travel to the Pantanal marshlands on fishing trips. He was not an alcoholic and had stopped to smoke 6 months previously after smoking one packet of cigarettes per day for 35 years.

At the physical examination, the patient was in a regular general condition, with difficulties to walk, very dyspneic, afebrile, with normal color, anicteric, acyanotic, with strong pulses and normal capillary filling. His weight was 160.0 kg. The cardiovascular examination showed typical double rhythm, with normal sounds without murmurs. The arterial blood pressure was 130/80 mmHg and heart frequency was 78 bpm. An examination of the lung showed bilateral vesicular murmur, less obvious in the lower thirds and without adventitious noises. The abdomen showed voluminous ascites, with an abdominal circumference of 156 cm, which was painless with air-fluid noises but without pain on abrupt decompression. The lower limbs were swollen symmetrically 4+/4+, without signs of inflammation or ischemia. The neurological examination was unaltered.

The patient had images and the results of laboratory examinations: abdominal Doppler ultrasonography (13/6/2005): normal; abdominal computed tomography (9/2005): voluminous ascitis with pleural bilateral discharge, normal liver without any sign of portal hypertension, absence of peritoneal carcinomatosis or neoplasias; high digestive endoscopy (31/5/2005): normal and absence of esophageal varices; echocardiogram (26/1/05): slight concentric hypertrophy of the left ventricle, slight functional mitral valve insufficiency; echocardiogram (18/5/05): slight concentric hypertrophy of the right ventricle, slight functional mitral valve insufficiency, slight increase in the left atrium. The blood tests were negative for hepatitis B, hepatitis C, HIV, HTVL3, syphilis and chagas disease. Laboratory examinations (25/08/2005): Anti-DNA non-reagent; FAN non-reagent; Anti-smooth muscle Antibody

= 1/160 (reference value up to 1/20); Antimitochondrial Antibody non-reagent; TSH and T4, Alpha-1-Antitrypsin, C3 and C4 within normal limits. The exam of urine I showed light proteinuria, protein urea ratio above 0.20. Laboratory examinations (04/10/2005): Hemoglobin = 11.5 g/dL; Hematocrit = 36%; Red blood cells = 4.4 millions; Leukocytes = 6300/mm³; Platelet = 227000/mm³; Glycemia = 99 mg/dL; Urea = 50 mg/dL; Creatinine = 1.1 mg/dL; Sodium = 136 mmol/L; Potassium = 3.5 mmol/L; TGO = 10 U/L; TGP = 18 U/L; Gamma-GT = 125 U/L; Total Protein = 6.7 g/dL; Albumin = 3.9 g/dL; Globulin = 2.8 g/dL; Albumin/Globulin ratio = 1.39; urine I exam normal, without proteinuria or other alterations, urinary sodium normal; fecal culture and feces parasitology negative. Examination of ascitic fluid (05/10/2005): glucose = 81 mg/dL; amylase = 21U/L; albumin = 2.7 g/dL; bacteria were not observed; negative for neoplastic cells; leukocytes = 0; red blood cells = 166; ADA = 21.3 (vn until 40). The patient also had a hepatic biopsy, which was without alterations, but the pathologist considered insufficient material for diagnosis.

In November 2005, the patient was consulted in our service with all the aforementioned examinations and yet without diagnosis. He also had an electrocardiogram that showed sinus rhythm, normal heart frequency, AQRS normal and the presence of negative T waves in the inferior and anterior walls (Figure 1).

Thus a restrictive syndrome was suspected possibly due to a heart disorder. As he was in frank decompensation, he was hospitalized basically on diuretic medication giving a relative improvement of the symptoms. A cardiac catheterism was accomplished that showed equal diastolic ventricular and atrial pressures with “square root” morphology (Figure 2). The coronary arteries did not present obstructions. The systolic left ventricular function was normal. As the echocardiograms brought by the patient were indeterminate and did not show alterations, an endomyocardial biopsy of the right ventricle was made to exclude restrictive cardiomyopathy. A repeat echocardiogram concentrating on the possibility of pericarditis, verified severe pericarditis justifying the clinical conditions and confirming the hypothesis of CCP.

Off-pump pericardiectomy by sternotomy was performed with partial removal of the pericardium, which was very thick (Figure 3), preserving the bilateral phrenic nerves. The patient evolved very well, with great improvement and hospital discharge in 7 days, weighing 120 kg. Within 21 postoperative days the patient had a total weight loss of about 70 kg, with complete remission of the ascitis and edema of the lower limbs, without dyspnea, arrhythmia, pain or any other complaint (Figure 4). He was now in Class I (NYHA). The anatomopathological examination of the pericardium was unspecific; reported as “mild unspecific chronic pericarditis with irregular dense fibrosis and areas of granulated tissue”.

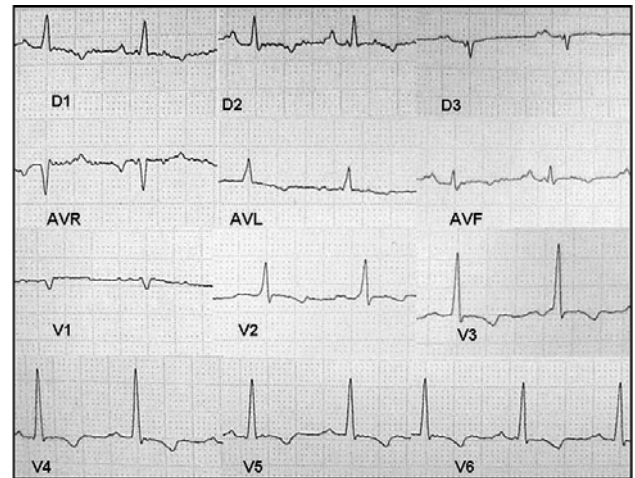


Fig. 1 – Electrocardiograph trace showing diffuse repolarization alterations with T-wave inversion

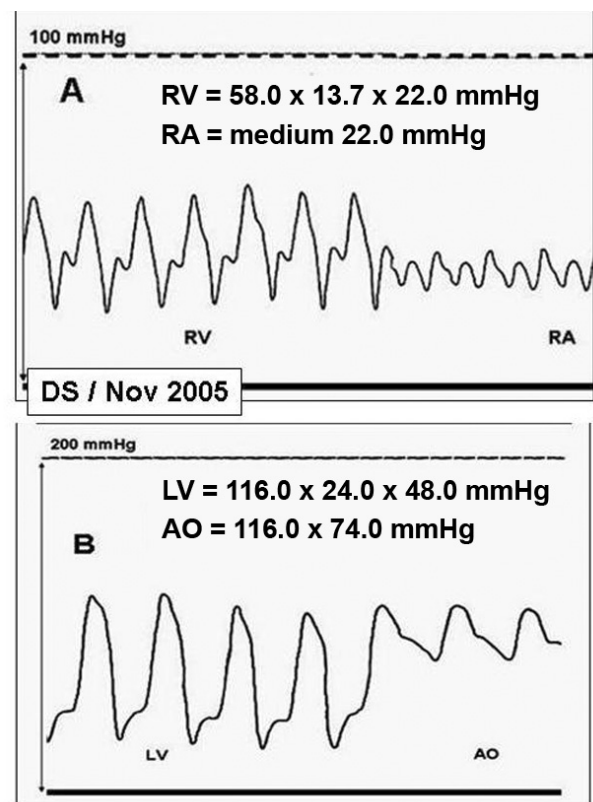


Fig. 2 – Measurement of pressure in the hemodynamics study: Note the typical restrictive curve with diastolic pressure of the right and left ventricles showing “square root” image

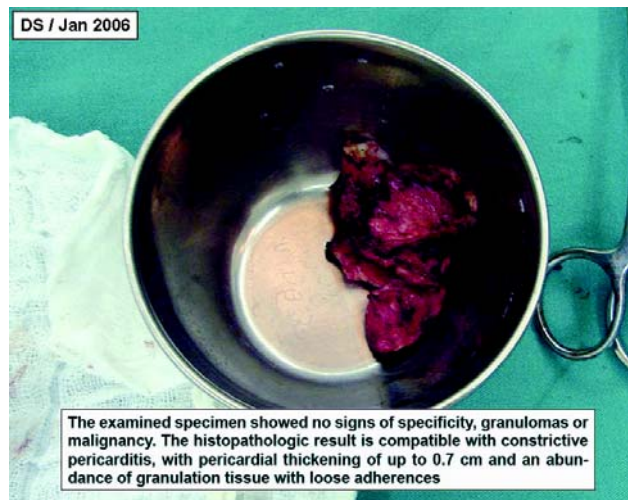


Fig. 3 – Removed pericardial fragments showing great thickening

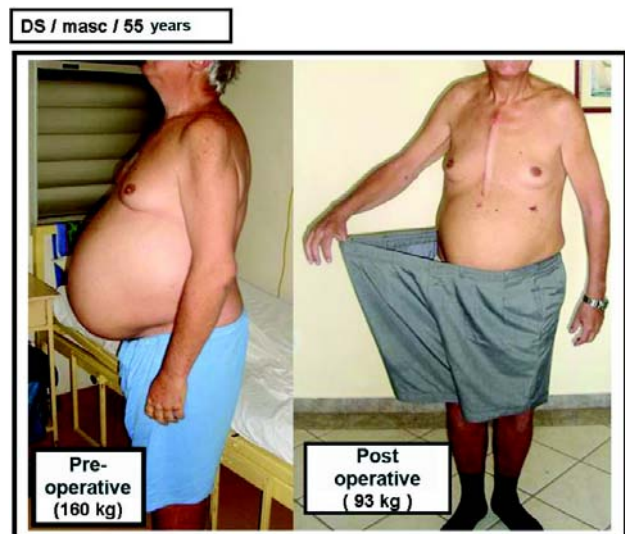


Fig. 4 – Comparative image showing patient before and 21 days after the operation to remove the pericardium: there was a great weight loss (around 70 kg) which was due to water retention

DISCUSSION

Notoriously, the identification of the etymology of CCP is very hard [5]. The causes of CCP include tuberculosis, collagenosis, uremia, rheumatic fever, radiotherapy, neoplasia, previous heart surgery or idiopathic [1-3]. Most CCP given as idiopathic may be diagnosed as resulting from tuberculosis [2,3,5]. Systemic sclerosis can also be

considered a differential diagnosis, due to its cardiac involvement [6].

The exact pathogenesis of CCP remains unknown [5]. It frequently begins with an initial episode of acute pericarditis that gradually develops to a subacute stage, followed by a chronic stage characterized by dense fibrous scarring of the pericardium with obliteration of the pericardial space [5]. In most cases, the visceral and parietal layers become completely merged. CCP is generally a scarring process that causes uniformly restricted filling of all heart chambers [2].

The symmetrical constrictive effect on the pericardium results in an increase and balance of the diastolic pressures in all four heart chambers [1,7]. At the start of diastole, when the intracardiac volume is less than that defined by the swollen pericardium, diastolic filling is not impeded and the initial diastolic filling occurs abnormally rapid because the venous pressure is high. Diastolic filling is rapid and abruptly interrupted when the intracardiac volume reaches the limit set by the noncompliant pericardium [1,7].

The restriction in diastolic filling results in a compensatory retention of sodium and water by the kidney, which contributes to an increase of systemic venous pressure and initially serves to maintain the diastolic filling of ventricles, in spite of the cardiac restriction. The inhibition to release atrial natriuretic factor may contribute to the retention of body fluids [5].

Ascitis, peripheral edema, hepatomegaly and hypoalbuminemia are the most frequent findings [2]. In general, patients with CCP retain more salts and water than patients with other myocardopathy. Ascitis in CCP is disproportional and generally occurs before the appearance of peripheral edema, the opposite to what occurs with congestive heart disease [5]. Vague abdominal symptoms, such as indigestion, dyspepsia, flatulence and anorexia, can also be present. When the filling pressures of the right and left hearts are high, pulmonary venous congestion symptoms, such as dyspnea on effort, coughing and orthopnea are present [1,7]. Pleural effusions and elevation of the diaphragm due to the ascitis may also contribute to the dyspnea. Intense fatigue, weight loss and muscle reduction suggest the presence of fixed or reduced cardiac outflow.

Older patients with long-term CCP can have extensive ascitis with massive edema of the scrotum, thighs and calf muscles. In contrast, the upper part of the chest and of arms can show evidence of muscle loss and severe cachexia.

The heart area can be small, normal or increased. An increase of heart area can be apparent due to coexistent pericardial effusions, contributing to an enormously swollen pericardium or to the prior increase or hypertrophy of the heart chambers. The right superior mediastinum may be prominent, due to ingurgitation of the superior cava vein

and an increase in the left atrium is common. Extensive calcification of the pericardium is present in approximately half of patients and suggests the possibility of a tuberculous etiology. Pleural effusions are seen in 60% of patients [7]. As the left atrial pressure is frequently high, there may be evidence of redistribution of blood flow, while Kerley B lines or infiltrations suggestive of frank pulmonary edema are rare.

At electrocardiography, findings include low voltage QRS, inversion or generalized flattening of the T wave and left atrial abnormalities suggestive of P mitral wave, atrioventricular and intraventricular blocks with widening of the QRS, right ventricular overload, with deviation of axis to the right [7,8]. The echocardiogram is very valuable in the evaluation of pericardial thickening, principally for calcification, however it can also show unspecific alterations [1,4,7]. The most sensitive examination to determine the pericardial thickness is the transesophageal echocardiogram [1]. Computed tomography is a useful instrument in the evaluation of suspicions of CCP. It is particularly useful to identify the pericardial thickness and other findings compatible with CCP. Magnetic resonance can also identify signs suggestive of CCP, including pericardial thickening, dilatation of the vena cavae and hepatic veins and narrowing of the right ventricle.

The chronic increase in the right atrial pressure, causing passive liver, kidney and gastrointestinal tract congestion, can cause other laboratorial alterations. These include a decrease in serum albumin, an elevation in serum globulin, increases in the serum conjugated and unconjugated bilirubin and abnormal liver function tests. Chylous ascitis should occur due to the impedance of the lymphatic drainage during central venous hypertension. The high venous systemic pressure may also produce a variable degree of albuminuria as well as a pronounced loss of proteins, compatible with nephrotic syndrome. Unspecific evidence of the presence of a chronic disease, such as normocytic and normochromic anemia may be found.

It may be extremely difficult to differentiate patients with CCP from patients with restrictive physiology caused by amyloidosis, hemochromatosis and hypereosinophilic syndrome, that can compromise both the pericardium and the myocardium [1,7]. The electrocardiographic findings, both of the CCP and the restrictive cardiomyopathy are similar. When compromise is due to amyloidosis, the echocardiogram reveals an abnormal thickening in the ventricular myocardium or a peculiar "bright" aspect [7].

With findings suggestive of CCP, catheterism of the right and left hearts should be made, to document hemodynamic alterations indicative of restriction and to exclude other causes of right arterial hypertension. Cardiac catheterism and angiography, frequently with endomyocardial biopsy, in general, are useful to discriminate constrictive pericarditis from restrictive cardiomyopathy [1,7].

Cardiac catheterism is useful in the evaluation of patients with suspicion of having CCP: 1. To document the elevations and equilibrium of diastolic filling pressures; 2. To evaluate the effects of CCP on the systolic volume and cardiac outflow; 3. To evaluate the myocardial systolic function; 4. To assist in the difficult differentiation between CCP and restrictive cardiomyopathy; 5. To exclude compression of the coronary arteries or compression of regional out-flow tract by fibrotic pericardium.

Catheterization of the right and left ventricles should be made to permit simultaneous measurement of the right and left heart filling pressures. Typical findings include an increase and balance (within 5 mmHg) of the diastolic pressures of the right atrium, right ventricle, left atrium (mean pulmonary capillary pressure) and diastolic pressure of the left ventricle [4]. Except that the left ventricle pressure, at the end of diastole, exceeds the right ventricle pressure by a few mmHg [1].

In CCP, the diastolic filling is abnormally reflected in a characteristic curve with dips and plateaus of both ventricles [1,3,4]. The rapid elevation of pressure, after the initial diastolic dip, corresponds to a period of quick diastolic filling, while the plateau phase corresponds to the middle and late period of diastole, when there is little ventricle expansion. The right atrial pressure is characterized by a preserved diastolic x descent, an early and prominent diastolic y descent and a and v waves, that are small and equal in height and result in the typical "M" or "W" configurations [4,7].

Coronary angiography can demonstrate that the coronary arteries are apparently within the cardiac area, and not on the heart surface, and occasionally, diastolic or external compression of the coronary arteries can be detected.

CCP is a progressive disease without spontaneous reversal of either pericardial thickening or the abnormal hemodynamic symptoms. Treatment of CCP is pericardiectomy [1,5]. In some patients, the heart function is not restored immediately after pericardiectomy but can take some time for normalization [1]. To avoid damage to the phrenic nerves, the anterior part of the pericardium should be resected [2]. CCP with more than one year of evolution decreases the success of the procedure and increases the mortality rate [2]. An incision by sternotomy allows better exploration of the heart and vessels, minimizing handling of the heart [2]. Postoperative complications include arrhythmia, renal insufficiency as well as cardiac and respiratory insufficiency [2].

A study performed by the Mayo clinic in Singapore, between 1985 and 1995, evaluated 135 cases of constrictive pericarditis. The most common symptom was cardiac insufficiency (67%), followed of chest pain (8%) and abdominal symptoms (6%). Pericardiectomy was

accomplished in 132 patients. Among these, 6% died within 30 postoperative days. Cardiac insufficiency relapsed in 31% of patients attended afterward, with a mean time for the return of symptoms of 7.1 months. From 129 patients that completed the follow-up, 75 (58%) remained alive and asymptomatic [9]. Another study, performed at the same center between 1993 and 1999, compared patients where the thickness of the pericardium measured more than 2 mm (26 patients) and with the thickness of the pericardium = 2 mm (117 patients). The conclusions were that the symptoms were very similar for both groups however, the radiological findings were generally a little clearer in those with thick pericardia. All the patients were submitted to surgery, with significant hemodynamic and symptomatology improvement. The postoperative mortality rate was similar in both groups. The authors highlighted the importance of not excluding the diagnosis of constrictive pericarditis, even with non-significative radiology examinations, stressing the importance of the association of the clinic symptoms, the echocardiogram and catheterism [10].

We believe it is interesting and fitting to present this case due to the severity of decompensation without diagnosis and to warn of the necessity of high degree of suspicion of constrictive pericarditis in patients with substantial ascitis without any apparent cause.

REFERENCES

1. Little WC, Freeman GL. Pericardial disease. *Circulation*. 2006;113(12):1622-32.
2. Yetkin U, Kestelli M, Yilik L, Ergunes K, Kanlioglu N, Emrecan B, et al. Recent surgical experience in chronic constrictive pericarditis. *Tex Heart Inst J*. 2003;30(1):27-30.
3. Hirai S, Hamanaka Y, Mitsui N, Morifugi K, Sutoth M. Surgical treatment of chronic constrictive pericarditis using an ultrasonic scalpel. *Ann Thorac Cardiovasc Surg*. 2005;11(3):204-7.
4. Guitti JCS. Constrictive pericarditis in a 19-month-old child. *Arq Bras Cardiol*. 2000;74(1):51-4.
5. Kothari SS, Roy A, Bahl VK. Chronic constrictive pericarditis: pending issues. *Indian Heart J*. 2003;55(4):305-9.
6. Byers RJ, Marshall DAS, Freemont AJ. Pericardial involvement in systemic sclerosis. *Ann Rheum Dis*. 1997;56(6):393-4.
7. Braunwald E. *Tratado de medicina cardiovascular*. 4ª ed. São Paulo:Roca;1996.
8. Mustafa RM, Braile DM, Greco OT, Santos JL, Ardito RV, Thevenard R. Pericardite constrictiva como diagnóstico diferencial de doença hepática. *Arq Bras Cardiol*. 1991;57(6):473-7.
9. Ling LH, Oh JK, Schaff HV, Danielson GK, Mahoney DW, Seward JB, et al. Constrictive pericarditis in modern era. Evolving clinical spectrum and impact on outcome after pericardiectomy. *Circulation*. 1999;100(13):1380-6.
10. Talreja DR, Edwards WD, Danielson GK, Schaff HV, Tajik AJ, Tazelaar HD, et al. Constrictive pericarditis in 26 patients with histologically normal pericardial thickness. *Circulation*. 2003;108(15):1852-7.