

Case 1/2007

Juxtaposition of atrial appendix at left side on great arteries transposition

Justaposição de apêndices atriais à esquerda na transposição das grandes artérias

Ulisses Alexandre CROTI, Domingo Marcolino BRAILE, Airton Camacho MOSCARDINI, Lilian BEANI

RBCCV 44205-879

CLINICAL DATA

The case of a seven-year-old female Negro child who lived in Alagoas, Brazil is reported. It was known that since birth the infant had suffered from cyanogenic heart disease but the disease was never surgically or pharmacologically treated. She was referred to our service for treatment and presented with significant cyanosis during resting and had difficulty to walk with dyspnea at the slightest effort. She was in a regular general state, the skin color was normal, she was hydrated with regular heart rhythm with two sounds without splitting of the second. She was hyperphonic at the mid left sternal edge with an ejective systolic murmur of +3/6+ at the upper mid left sternal edge. Pulmonary auscultation and abdomen were normal as were the arterial pressures and pulses of all four limbs. Peripheral saturation was 62%.

ELECTROCARDIOGRAM

The electrocardiogram evidenced sinus rhythm and frequency of 110 bpm. The SAP angle was $+60^\circ$ and the $S\hat{A}QRS$ was $+210^\circ$ with a PR interval of 0.12 seconds, the QRS was 0.08 seconds and the QTc was 0.40 seconds. The patient had right atrial overload with a P-wave of 3 mm at DII. Right ventricle overload was also evidenced by QRS complexes presenting Rs at V1 and rS at V6, as well as a QRS axis deviation to the right (Figure 1).

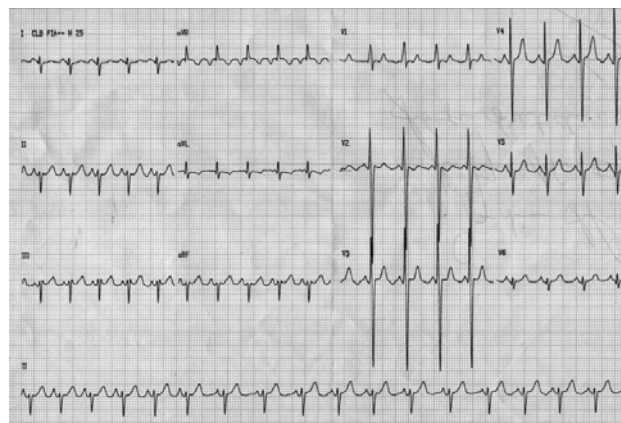


Fig. 1 – Preoperative echocardiogram

RADIOGRAM

The radiogram showed that the cardiac area was within normal limits with a narrow hilum. The pulmonary vascular bed was normal.

ECHOCARDIOGRAM

An echocardiogram demonstrated situs solitus with

Work carried out in the Pediatric Cardiovascular Surgery Service of São José do Rio Preto – Hospital de Base – Medical School in São José do Rio Preto.

Correspondence address: Ulisses Alexandre Croti
Hospital de Base – FAMERP – Avenida Brigadeiro Faria Lima, 5544.
CEP 15090-000 – São José do Rio Preto – São Paulo
Phone (Fax): 17 - 3201 5025 / 3222 6450 / 9772 6560
E-mail: uacroti@uol.com.br

Article received in January 31st, 2007
Article accepted in February 21st, 2007

levocardia. The venoatrial and atrioventricular connections were concordant but the ventriculoarterial connection was not indicating transposition of the great vessels with a wide ostium secundum-type interatrial communication of 22 mm; doubly committed subarterial interventricular communication of 16 mm, the arterial canal was patent and there was significant pulmonary supralvalvar and valvar stenosis with a left ventricle/pulmonary trunk gradient of 72 mmHg as calculated by Doppler.

DIAGNOSIS

The physical examination suggests congenital heart disease with chronic pulmonary hypoflow with the presence of digital clubbing. The echocardiogram satisfactorily diagnosed the disease, however after a meeting between cardiologists and surgeons a cardiac cineangiography was performed to confirm the anatomy and measure the blood pressures which were in agreement to the echocardiographic findings, and confirming the need for total correction of the defect using the Rastelli procedure and closure of the interventricular communication.

SURGERY

A median transsternal thoracotomy was performed and cardiopulmonary bypass was established with hypothermia at 25°C and using antegrade blood cardioplegia at 20-minute intervals. The pulmonary branches had good diameters and were in juxtaposition to the atrial appendices, a condition that was not identified in the pre-operative examinations (Figure 2). The right atrium was opened to empty the left chambers through the interatrial communication. The proximal neck of the pulmonary trunk was sectioned crosswise and sutured with resection of the valve aiming at preventing the formation of thrombi. The distal portion of the pulmonary trunk was drawn to the right of the aorta, after the ligature and sectioning of the arterial canal and dissection of the branches. The tricuspid valve

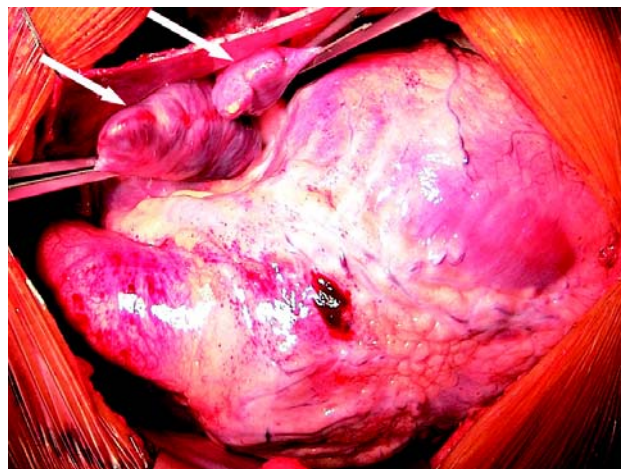


Fig. 2 – Juxtaposition of the atrial appendices to the left (arrows)

was carefully inspected [1] and a decellularized n° 26 homograft was placed between the pulmonary trunk and the right ventricle (Rastelli), with the tube positioned to the right of the aorta. The perfusion duration was 114 minutes and the myocardial ischemia duration was 87 minutes. The patient evolved in the ICU with supraventricular tachycardia and so amiodarone was prescribed. She was released from hospital on the 15th postoperative day after being treated for lobar pneumonia. A control echocardiogram after one month showed that the graft functioned normally and there were no residual defects.

REFERENCE

1. Leu MR, Chiu IS, Hung CR, Wu MH. Surgical implications of juxtaposed atrial appendages and the associated anomalies. *Ann Thorac Surg.* 1992;54(1):134-6.