

Case 2/2007

Left atrial isomerism in the defect of partial atrioventricular septum

Isomerismo atrial esquerdo no defeito do septo atrioventricular parcial

Ulisses Alexandre CROTI, Domingo Marcolino BRAILE, Sírío HASSEM SOBRINHO, Moacir Fernandes de GODOY

RBCCV 44205-880

CLINICAL DATA

The case of a 2-year-old mulatto female infant from Bahia, Brazil is reported. Since birth the child presented with fatigue during breastfeeding which improved with the use of digital and diuretics. The girl was in a regular condition but pallid and with slight dyspnea. Ictus cordis was palpable at the 5th left intercostal space; the heart rhythm was regular with two sounds, systolic murmur +4/6+ at the mid left sternum edge and hyperphonestic of the second sound. Pulmonary auscultation was normal and the liver was 3 cm from the right costal border. Pulses were palpable in all four limbs.

ELECTROCARDIOGRAM

An electrocardiogram showed a low right atrium rhythm with a frequency of 115 bpm. The SÂP was -60° , the SÂQRS was undetermined, the PRs interval was 0.12 seconds, QRS was 0.10 seconds and the QTc was 0.38 seconds. The right ventricle was overloaded as evidenced by the qR complex at V1 and RS complex at V6 (Figure 1).

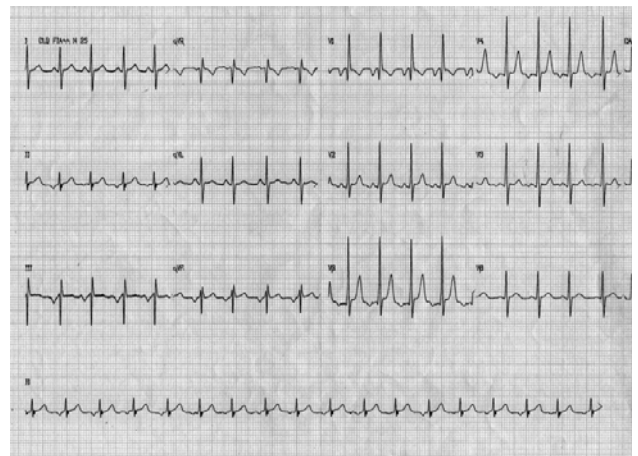


Fig. 1 – preoperative echocardiogram

Work carried out in the Pediatric Cardiovascular Surgery Service of Hospital de Base – Medical School São José do Rio Preto.

Correspondence address: Ulisses Alexandre Croti
Hospital de Base – FAMERP – Avenida Brigadeiro Faria Lima, 5544
CEP 15090-000 – São José do Rio Preto – São Paulo
Phone (Fax): 17 - 3201 5025 / 3222 6450 / 9772 6560
E-mail: uacroti@uol.com.br

Article received in January 31st, 2007
Article accepted in February 21st, 2007

RADIOGRAM

A radiogram demonstrated visceral situs solitus. The cardiac area was elevated with the cardiothoracic index at 0.64. There was a shunt-type prominence of the vascular network with a reduction in volume of the lower left lobe. The diaphragmatic dome was free to the right.

ECHOCARDIOGRAM

An echocardiogram demonstrated situs solitus with levocardia. The venoatrial atrioventricular and ventriculoarterial connections were concordant. There was a partial defect of the atrioventricular septum, left atrial isomerism and atrioventricular valve insufficiency with the insufficiency on the left being significant and on the right mild. The left pulmonary artery had a caliber of 10 mm and the right pulmonary artery had a caliber of 6.5 mm at the root and 10 mm distally presenting with a pressure gradient of 58 mmHg calculated using Doppler. The Qp/Qs ratio was estimated at 4.

DIAGNOSIS

The clinical history of congestive heart failure with hyperphonesis of the second sound identified congenital heart disease with pulmonary hyperflow and pulmonary hypertension. The echocardiogram precisely determined the anatomic characteristics and, faced with the finding of left atrial isomerism, correction of the position of the papillary muscles was attempted as the valvar insufficiency was significant [1]. Additionally, an abdominal ultrasound was performed with the aim of eliminating the possibility of polysplenia.

SURGERY

A median transsternal thoracotomy was performed and cardiopulmonary bypass was established with hypothermia at 28°C using antegrade blood cardioplegia at 20-minute intervals. The atrium was opened morphologically from left to right (Figure 2) as was the pulmonary trunk. Anatomic stenosis was not identified at the root of the right pulmonary artery however a decision to enlarge the initial third using an autologous pericardial patch was taken due to the possibility of functional stenosis as previously demonstrated by echocardiogram. The fissure of the left

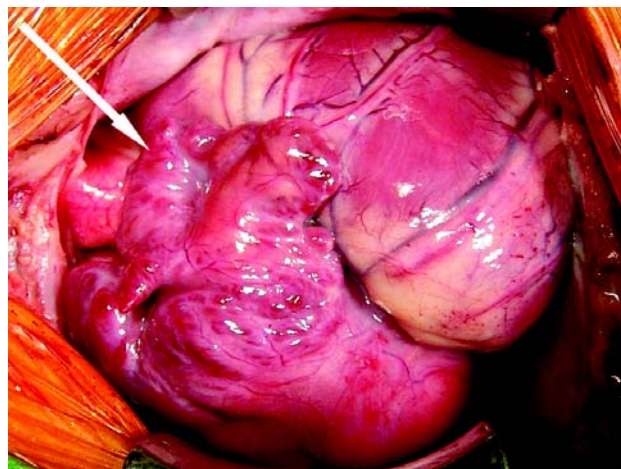


Fig. 2 – left atrial isomerism (arrow)

atrioventricular valve was closed with single sutures using 6-0 polypropylene thread. The *ostium primum*-type interatrial communication was closed using a bovine pericardium patch with running sutures also of 6-0 polypropylene thread, leaving the coronary sinus to the right. The perfusion time was 61 minutes and the myocardial ischemia time was 48 minutes. There was no difficulty in treating the left atrioventricular valve and on testing using saline solution it presented competent. On the 4th postoperative day in the ward, the patient presented with cardiorespiratory arrest due to aspiration of milk. After this event, she evolved satisfactorily from the cardiovascular point of view with a control echocardiogram demonstrating correction of the defect with insignificant regurgitation through the left atrioventricular valve and significant improvement in the size of the cardiac area however she was released from hospital with a severe neurological sequel.

REFERENCE

1. Uemura H, Anderson RH, Ho SY, Devine WA, Neches WH, Smith A, et al. Left ventricular structures in atrioventricular septal defect associated with isomerism of atrial appendages compared with similar features with usual atrial arrangement. J Thorac Cardiovasc Surg. 1995;110(2):436-44.