

Histomorphometric differences between the left and right internal thoracic arteries in humans

Diferenças histomorfométricas entre as artérias torácicas internas esquerda e direita em humanos

Maria Flavia L. RIBEIRO¹, Maximiliano C. KNEUBIL², Marcelo S. AQUINO³, Guiomar N. GOMES⁴, Paulo MAZZILLI⁵, Enio BUFFOLO⁶, Camille D. BENATTI⁷, Walter J. GOMES⁸

RBCCV 44205-942

Abstract

Objective: The use of the left internal thoracic artery in coronary artery bypass surgery is currently recognized as the best option, providing lesser incidence of cardiovascular events and superior long-term survival. As a result, great expansion of bilateral internal thoracic artery (ITAs) grafts has been observed, with additional demonstration of improved long-term survival. Therefore the aim of this study was to examine and compare the histomorphometric structure among different segments of the left and right ITA.

Method: Specimens of ITAs harvested from 18 cadavers were divided in nine proportional segments. Cuts of each

segment had been stained with hematoxylin-eosin and Verhoeff-Van Gieson technique. The following parameters had been analyzed: perimeter of the arterial lumen, thickness of the intima, thickness of the media layer and amount of elastic fiber in the media layer.

Results: The perimeter of both ATIs decreases downstream its course, the proximal segments of the right ITA exhibit perimeter significantly greater than left ITA. The analysis of the intima thickness revealed no significant difference between left and right ITA, except in the segment 9. The thickness of media layer showed no statistical difference between them, except in the segment 1. The number of elastic layers in the distal left ITA segments is significantly higher than right ITA.

1. Graduate student of Medicine. Escola Paulista de Medicina - Federal University of São Paulo.
2. Residency at Escola Paulista de Medicina - Federal University São Paulo.
3. Residency at Escola Paulista de Medicina - Federal University of São Paulo.
4. Auxiliar Professor. Discipline of Renal Physiology and Termometabology. Escola Paulista de Medicina - Federal University of São Paulo.
5. Residency at Escola Paulista de Medicina - Federal University São Paulo.
6. Full Professor of Cardiovascular Surgery. Escola Paulista de Medicina - Federal University of São Paulo.
7. Graduate student of Medicine. Escola Paulista de Medicina - Federal University of São Paulo.
8. Full Associate Professor of Cardiovascular. Surgery Escola Paulista de Medicina - Federal University of São Paulo.

This study was carried out in the Cardiovascular Surgery Discipline. School of Medicine of São Paulo. Federal University of São Paulo. This study was funding by the Programa Institucional de Bolsas de Iniciação Científica - PIBIC/CNPq-UNIFESP/EPM. Student: Maria Flavia L. Ribeiro. Professor: Walter J. Gomes.

Correspondence address

Walter J. Gomes. Disciplina de Cirurgia Cardiovascular. Escola Paulista de Medicina - Universidade Federal de São Paulo - Rua Botucatu, 740 - São Paulo - SP - Brasil - CEP 04023-900.
Phone: (11) 5571-2719.
E-mail: wjgomes.dcir@epm.br

Article received on February 14th, 2008
Article accepted on March 4th, 2008

Conclusion: Data analyses from this study suggest structural differences between the left and right internal thoracic arteries.

Descriptors: Mammary arteries. Myocardial revascularization. Histology, comparative. Humans. Cadaver.

Resumo

Objetivo: O uso do enxerto de artéria torácica interna esquerda (ATIE) é atualmente reconhecido como a melhor opção na cirurgia de revascularização miocárdica, proporcionando menor incidência tardia de eventos cardiovasculares e maior sobrevida. Conseqüentemente, houve grande incremento nas últimas décadas do uso bilateral das artérias torácicas internas (ATIs), com demonstração de melhora adicional de sobrevida em longo-termo. O objetivo desse trabalho foi estudar a estrutura histológica das ATIs esquerda e direita (ATID), com a análise histomorfométrica seqüencial e comparativa entre os segmentos das duas artérias.

Métodos: Foram estudados espécimes de ATIs retirados

de 18 cadáveres, divididos em nove segmentos proporcionais. Cortes de cada segmento foram corados com técnica de hematoxilina-eosina e Verhoeff-Van Gieson. Foram analisados os seguintes parâmetros: perímetro da luz arterial, espessura da íntima, espessura da camada média e quantidade de fibras elásticas da camada média.

Resultados: O perímetro interno de ambas as ATIs diminuiu ao longo do percurso, dos segmentos mais proximais para os mais distais. Os segmentos proximais da ATID apresentaram perímetro significativamente maiores do que os da ATIE. A análise da espessura da íntima revelou não existir diferença significativa entre ATIE e ATID, exceto no segmento 1. A espessura da camada média diminuiu ao longo da extensão das ATIs, não havendo diferença estatística entre elas, exceto no segmento 9. O número de lâminas elásticas nos segmentos distais da ATIE foi estatisticamente superior ao da ATID.

Conclusão: Portanto, os dados do presente estudo sugerem haver diferenças estruturais entre as ATIs direita e esquerda.

Descritores: Artéria torácica interna. Revascularização miocárdica. Histologia comparada. Humanos. Cadáver.

INTRODUCTION

The use of a left internal thoracic artery (LITA) graft in order to revascularize the anterior descending coronary artery has become the gold standard in myocardial revascularization surgery providing better patency, lower incidence of new cardiac events, and increased survival indexes when in comparison to the patients receiving venous grafts [1,2]. Consequently, in the last decades there has been a great increment of bilateral use of internal thoracic arteries (ITAs), which explains the additional improvement of long term survival when in comparison to the use of LITA alone [3-5]. Evidences showed that when ITAs are used to revascularize the left coronary system, both ITAs present similar long term permeability rates [6].

The excellent outcomes achieved with ITA grafts are due to a great extent to the framework of its walls. Contributing to this superiority is the ITA relative immunity to atherosclerosis [7], such as specific wall factors, as the histological [8-10], ultrastructural [8], and histochemical composition [11]. However, previous studies have demonstrated slight differences in anatomical details when comparing LITA and RITA [12-14]. Although the LITA's histological structure has been adequately studied and reported in the literature, RITA has been poorly studied and

its sequential structure of information is lacking.

Therefore, the aim of this study was to study both left and right ITAs' histological structure using comparative and sequential histomorphometric analysis among different segments of both arteries.

METHODS

Samples of left and right ITAs harvested from 18 fresh cadavers from the São Paulo County Coroner (Serviço de Verificação de Óbitos da Cidade de São Paulo) were studied. The dissections consisted in carefully harvesting of ITAs, from its origin in the subclavian artery to its bifurcation, giving rise to the superior epigastric and musculophrenic arteries. In each sample, the total length of ITAs from their origin to the bifurcation was divided into nine proportional segments (Figure 1). The segments, numbered 1 to 9, were fixed using 10% buffered formalin. Afterwards, the segments were dehydrated, diaphanized, and included in paraffin. 5- μ m transversely-oriented histological sections were made from the mid portion of each segment. Two techniques (hematoxylin and eosin stain, and Verhoeff-Van Gieson stain) were used to stain the segments, which were prepared for both light microscopy and histomorphometry (Figure 2).

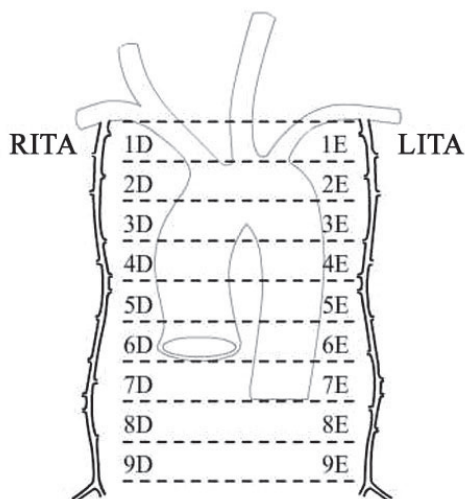


Fig. 1 - The total length of the left and right internal thoracic arteries (Left and Right ITAs) from its origin to its bifurcation was divided into nine proportional segments.

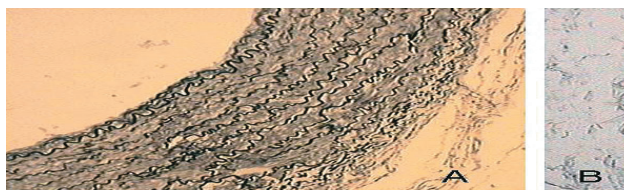

Fig. 2 - Photomicrography of the right internal thoracic artery (A) and left internal thoracic artery segment 6 stained by the Verhoeff-Van Gieson technique (magnification 200x)

The images were captured by a Zeiss light microscope coupled to a computer with a high-resolution monitor where the images were processed and digitalized. The histomorphometric analysis was performed using the software Image-Pro Plus 4 (Media Cybernetics, Inc., Silver Spring, USA).

Analyzed parameters

The following parameters were analyzed: arterial lumen perimeter, thickness of tunicae media and intima, and the amount of elastic fibers of tunica media. These parameters were compared among the segments of each ITA (intragroup) and after between both ITAs (intergroup).

The arterial lumen perimeter direct analysis was carried out using x50 magnification, whereas the thickness of tunica intima, tunica media, and the number of elastic fibers in tunica media was amplified x200. For greater study accuracy, four different regions of the same diametrically opposed section were analyzed.

Morphometrical data are presented as mean \pm standard deviation. Analysis of variance (ANOVA) was performed to compare the means among the segments of each ITA, followed by the Bonferroni correction for multiple comparisons. Comparisons between the values of LITA and RITA were done with a paired student's *t*-test or Wilcoxon matched pairs signed rank sum test, depending on the distribution. We considered $p < .05$ as significant. Statistical analysis was performed using the software GraphPad Prism Software (GraphPad Software, Inc, San Diego, CA).

RESULTS

The findings of the present study showed that the proximal segments of RITA (R1, R2, R4) presented significantly large perimeter values when compared to the segments of LITA (L1, L2, L4) ($p < 0.01$). In the intragroup analysis, the internal perimeter of both ITAs decreased downstream its course, from the more proximal segments to the more distal ones. There was no statistically significant difference in LITA when the segments were compared among themselves. In RITA, the segment 1 was significantly larger than segments 7, 8, and 9; segment 1 >5 ($p < 0.05$) and segment 2 >9 ($p < 0.05$). Part of the LITA data outcome have already been described in a previous study [10] (Figure 3).

Regarding the thickness of tunica media, there was no statistically significant difference between the arteries studied, except in segment 9, in which the LITA values were lower than those of RITA ($p < 0.001$). The thickness of tunica media decreased through the proximal to distal length in both LITA and RITA (Figure 4).

In LITA, the segments 3 and 5 were significantly

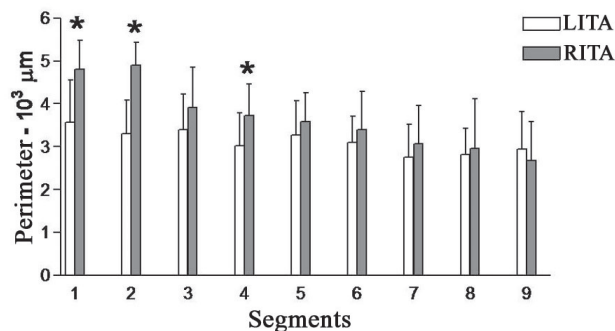


Fig. 3 - Comparison between the internal perimeter of both left internal thoracic artery (LITA) and right internal thoracic artery (RITA). The internal perimeter of both ITAs decreases along its route. The RITA proximal segments show significantly larger perimeter values than those of LITA (* significant difference between LITA and RITA, $p < 0.01$).

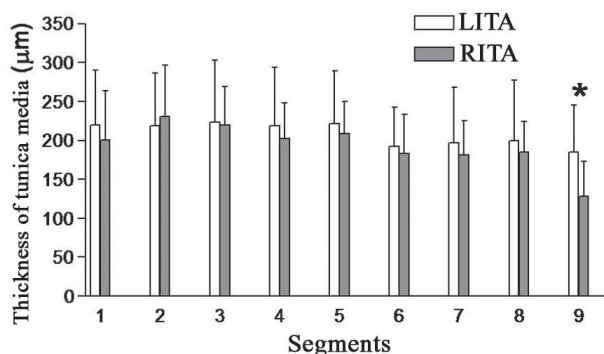


Fig. 4 - There was no statistically significant difference when comparing left and right internal thoracic arteries (LITA and RITA, respectively) thickness of tunica media, except in segment 9, in which RITA values were lower than those of LITA (* significant difference between LITA and RITA, $p < 0.001$). The thickness of tunica media decreases along the proximal to distal length in both LITA and RITA.

larger when compared to segment 9 ($p < 0.05$). In RITA, the segment 1 was significantly larger when compared to segment 9 ($p < 0.001$), segment 2 was larger than segments 6, 7, 8, and 9 ($p < 0.001$) and segments 3, 4, 6, 7, and 8 were larger than segment 9 ($p < 0.001$).

The analysis of the thickness of tunica intima did not present significant difference between LITA and RITA, with exception of segment 1 with a segment value of RITA lower than that of LITA ($p < 0.02$) (Figure 5). The thickness of tunica intima was increased in LITA proximal segments; the segment 1 was significantly larger when compared to segments 2, 5, 6, 7, 8, and 9 ($p < 0.01$) and when compared to segment 3 ($p < 0.05$). In RITA, the segment 2 was significantly larger when compared to segment 7 ($p < 0.05$).

Regarding the amount of elastic layers, there was a

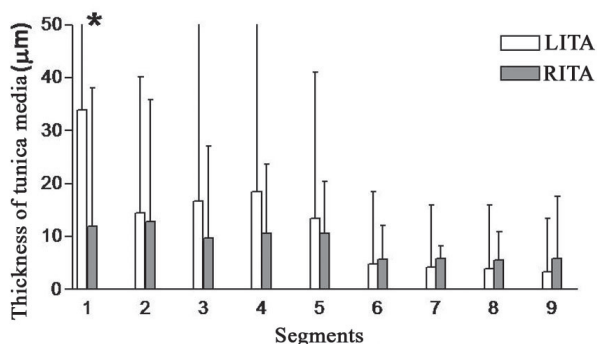


Fig. 5 - There was no statistically significant difference when comparing left and right internal thoracic arteries (LITA and RITA, respectively) thickness of tunica intima, except in segment 1, with RITA value segment being lower than that of LITA (* significant difference between both LITA and RITA, $p < 0.02$).

statistically significant difference among both ITAs segments. A larger amount of elastic fibers was found from segment 4 to 8 in LITA than in RITA (L4xR4 $p < 0.003$; L5xR5, L6xR6, L7xR7, L8xR8 $p < 0,0001$). In LITA, the amount of elastic layers was concentrated in the intermediate segments and it was found to be reduced in the proximal and distal segments. In RITA, it was observed a relative uniformity in the distribution of the amount of elastic layers among its segments. There was no statistical difference among segments 1 through 8. Segment 9 presented significantly less elastic layers than the other segments ($p < 0.01$) (Figure 6).

DISCUSSION

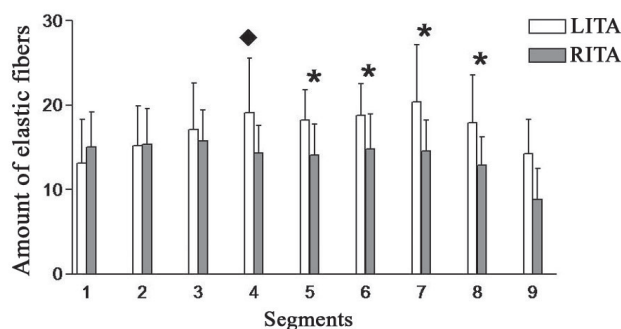


Fig. 6 - There was a significant statistically difference in the amount of elastic layers between ITAs segments. From the segment 4 to 8 it has been found greater amount of elastic fibers in left ITA than in right ITA (♦ significant difference between LITA and RITA, $p < 0.003$; * significant difference between LITA and RITA, $p < 0.0001$).

The present study showed subtle differences, but significant ones, in the histological comparison of the sequential histological structure between both ITAs. The RITA perimeter in the proximal segments is larger than those in LITA becoming increasingly similar as the arteries descend through the thorax wall. These data positively correlate and reinforce the findings of the previous anatomical study [12,13]. Most importantly, the amount of elastic layers present in the LITA distal segments was found to be superior to that of RITA. It was also observed an uneven distribution of elastic layers between both arteries.

In part, the explanation could be attributed to the embryological origin. The left subclavian artery arises from the left 7th intersegmental artery, while the right subclavian artery arises from multiple embryological origin: from proximal to distal arises from the 4th aorta arch, right dorsal aorta (between the 4th and the 7th intersegmental arteries), and from the right 7th intersegmental artery [15].

Anatomical differences between both ITAs have already

been demonstrated elsewhere, with the diameter of RITA being larger than that of LITA [12,13,16], the length of LITA being superior to that of RITA, and the distance difference from both arteries to the sternum border [13]. However, another study comparing the ITAs' morphology did not revealed differences in length, diameter, thickness and wall structure, thus concluding that the morphology of both arteries are similar [17].

Recent studies have revealed that the RITA used to revascularize the coronary arteries of the posterolateral heart wall through the transverse sinus has similar long term patency to the LITA anastomosed to the anterior descending artery [18,19]. It has been demonstrated that this effect expresses itself as a mean survival increase of 15% at 20 postoperative years [3-5].

Undoubtedly, the excellent results with the use of the LITA in CABG are due to, to a great extent, its histological structure. Clinical and experimental evidence show that the ITA graft is not only a simple conduit for the transportation of blood to the myocardium. It possesses several biological characteristics such as its relative immunity to atherosclerosis, active vasodilation with remodeling of the arterial wall, its great capacity of nitric oxide secretion, and other endothelial factors, regulating the vasomotor tonus and the auto-repair mechanism [10].

Previous studies that have examined LITA histological structure have shown contradictory outcomes. Van Son et al. [20] studied the comparative histology of various arterial conduits used in myocardial revascularization surgery, but they considered LITA as presenting a regular structure throughout its route. In a further study repairing the inaccuracy of the preceding study, Van Son et al. [9] showed the variability of ITA histological composition in its different segments. This study, as well as the findings of the present study, has strengthened the higher predominance of elastic fibers in LITA mid segment than in proximal and distal segments. On the other hand, LITA is pharmacologically reactive [21,22]. He [22] reported that different LITA segments showed fluctuations in contractility responses when tested with distinctive vasoactive agents and He concluded that the mid segment is a "passive conduit", but the distal segment (3 to 4 cm proximal to the bifurcation) is pharmacologically reactive. Even though LITA has been adequately studied, RITA histological structure has remained relatively overlooked with scarce information regarding its sequential structure. The use of the distal third of ITA for coronary grafting was controverted due to the possibility of a major spasm [22]. However, our data showed that RITA apparently has a more regularly distributed wall histological structure throughout its length with a relatively steady amount of elastic layers.

Nakayama et al. [23] studying late angiographically outcomes of different LITA segments anastomosed to the

anterior descending (AD) coronary artery showed that all LITA segments were capable of proportionally increasing both diameter and flow adjusting to the demand of the revascularized coronary artery.

Marx et al. [24], studying the structure of ITA distal segment in 100 patients, have found a great variation in the composition of tunica media. The media could be classified into three different types: muscular, hybrid and elastic type. In 52% the elastic type dominated in the distal part. Hybrid and muscular patterns were found in 22 and 26%, respectively. Therefore, even among specimens of distal segments of ITA there is a great histological variability, making previous extrapolations susceptible of questionings.

Additionally, studies have demonstrated that the diameter and the location of ITAs segments used in the coronary grafting did not constitute increasing factors of graft occlusion rate [25]. The structure and caliber of ITAs are well adapted to that of the graft recipient coronary artery, creating less flow turbulence and great release of endothelial mediators, thus assuring long durability.

CONCLUSION

The data of the present study suggest that there are structural differences between both right and left ITAs. Further studies aiming at comparatively analyzing the endothelial function and vasoreactivity should provide additional information. The potential implications of these findings in the patency of grafts and in the long-term clinical outcomes remain to be elucidated.

ACKNOWLEDGEMENTS

The authors wish to thank Prof. Dr. Oswaldo Giannotti-Filho (in memoriam) for his valuable help in setting up and analyzing of the slides. Also, thanks to Drs Gaia and Rafael Loduca, for their help in collecting the samples and in the preparation of the slides.

REFERENCES

1. Loop FD, Lytle BW, Cosgrove DM, Stewart RW, Goormastic M, Williams GW, et al. Influence of the internal-mammary-artery graft on 10-year survival and other cardiac events. *N Engl J Med.* 1986;314(1):1-6.

2. Cameron A, Davis KB, Green G, Schaff HV. Coronary bypass surgery with internal-thoracic-artery grafts: effects on survival over a 15-year period. *N Engl J Med.* 1996;334(4):216-9.
3. Lytle BW, Blackstone EH, Sabik JF, Houghtaling P, Loop FD, Cosgrove DM. The effect of bilateral internal thoracic artery grafting on survival during 20 postoperative years. *Ann Thorac Surg.* 2004;78(6):2005-14.
4. Taggart DP, D'Amico R, Altman DG. Effect of arterial revascularisation on survival: a systematic review of studies comparing bilateral and single internal mammary arteries. *Lancet.* 2001;358 (9285):870-5.
5. Berreklouw E, Rademakers PP, Koster JM, van Leur L, van der Wielen BJ, Westers P. Better ischemic event-free survival after two internal thoracic artery grafts: 13 years of follow-up. *Ann Thorac Surg.* 2001;72(5):1535-41.
6. Shah PJ, Durairaj M, Gordon I, Fuller J, Rosalion A, Seevanayagam S, et al. Factors affecting patency of internal thoracic artery graft: clinical and angiographic study in 1434 symptomatic patients operated between 1982 and 2002. *Eur J Cardiothorac Surg.* 2004;26(1):118-24.
7. Kay HR, Korn ME, Flemma RJ, Tector AJ, Lepley D Jr. Atherosclerosis of the internal mammary artery. *Ann Thorac Surg.* 1976;21(6):504-7.
8. Sims FH. The internal elastic lamina in normal and abnormal human arteries. A barrier to the diffusion of macromolecules from the lumen. *Artery.* 1989;16(3):159-73.
9. van Son JA, Smedts F, de Wilde PC, Pijls NH, Wong-Alcala L, Kubat K, et al. Histological study of the internal mammary artery with emphasis on its suitability as a coronary artery bypass graft. *Ann Thorac Surg.* 1993;55(1):106-13.
10. Kneubil MC, Gomes WJ, Aquino MS, Mazzilli P, Gomes GN, Ribeiro MFL, et al. Estudo histomorfométrico seqüencial da artéria torácica interna esquerda. *Rev Bras Cir Cardiovasc.* 2006;21(4):371-6.
11. Chaikhouni A, Crawford FA, Kochel PJ, Olanoff LS, Halushka PV. Human internal mammary artery produces more prostacyclin than saphenous vein. *J Thorac Cardiovasc Surg.* 1986;92(1):88-91.
12. Henriquez-Pino JA, Gomes WJ, Prates JC, Buffolo E. Surgical anatomy of the internal thoracic artery. *Ann Thorac Surg.* 1997;64(4):1041-5.
13. Henriquez-Pino JA, Gomes WJ, Prates JC, Buffolo E. Estudo anatômico da artéria torácica interna aplicado à cirurgia cardiovascular. *Rev Bras Cir Cardiovasc.* 1997;12(1):83-8.
14. Gupta M, Sodhi L, Sahni D. Variations in collateral contributions to the blood supply to the sternum. *Surg Radiol Anat.* 2002;24(5):265-70.
15. Moore KL, Persaud TVN. *Embriologia básica.* 4ª ed. Rio de Janeiro:Guanabara Koogan;1995.
16. Lachman N, Satyapal KS. Morphometry of the internal thoracic arteries. *Surg Radiol Anat.* 1998;20(4):243-7.
17. Märkl B, Raab S, Arnholdt H, Vicol C. Morphological and histopathological comparison of left and right internal thoracic artery with implications on their use for coronary surgery. *Interact Cardiovasc Thorac Surg.* 2003;2(1):73-6.
18. Ascione R, Underwood MJ, Lloyd CT, Jeremy JY, Bryan AJ, Angelini GD. Clinical and angiographic outcome of different surgical strategies of bilateral internal mammary artery grafting. *Ann Thorac Surg.* 2001;72(3):959-65.
19. Buxton B, Tatoulis J, Fuller J. Arterial conduits update. *Heart Lung Circ.* 2005;14(Suppl 2):S14-7.
20. Van Son JA, Smedts F, Vincent JG, van Lier HJ, Kubat K. Comparative anatomic studies of various arterial conduits for myocardial revascularization. *J Thorac Cardiovasc Surg.* 1990;99(4):703-7.
21. Evora PR, Pearson PJ, Discigil B, Oeltjen MR, Schaff HV. Pharmacological studies on internal mammary artery bypass grafts. Action of endogenous and exogenous vasodilators and vasoconstrictors. *J Cardiovasc Surg.* 2002;43(6):761-71.
22. He GW. Contractility of the human internal mammary artery at the distal section increases toward the end. Emphasis on not using the end of the internal mammary artery for grafting. *J Thorac Cardiovasc Surg.* 1993;106(3):406-11.
23. Nakayama Y, Sakata R, Ura M. Growth potential of left internal thoracic artery grafts: analysis of angiographic findings. *Ann Thorac Surg.* 2001;71(1):142-7.
24. Marx R, Clahsen H, Schneider R, Sons H, Klein RM, Gulker H. Histomorphological studies of the distal internal thoracic artery which support its use for coronary artery bypass grafting. *Atherosclerosis.* 2001;159(1):43-8.
25. Sabik JF 3rd, Lytle BW, Blackstone EH, Khan M, Houghtaling PL, Cosgrove DM. Does competitive flow reduce internal thoracic artery graft patency? *Ann Thorac Surg.* 2003;76(5):1490-7.