

The use and midium-term evaluation of decellularized allograft cusp in the surgical treatment of the Tetralogy of Fallot

Emprego e avaliação em médio prazo da cúspide de homoenxerto decelularizado na correção da tetralogia de Fallot

Leonardo Andrade MULINARI¹, Fábio Binhara NAVARRO², Gustavo Klug PIMENTEL², Silvia Midori MIYAZAKI³, Cristiane Nogueira BINOTTO⁴, Eliana Costa PELISSARI³, Nelson Itiro MIYAGUE⁵, Francisco Diniz Affonso DA COSTA⁶

RBCCV 44205-974

Abstract

Objective: To describe the technique of implantation and to show the echocardiographic follow-up of the cusped patch of decellularized homograft used to augment the right ventricle outflow tract in patients with tetralogy of Fallot.

Methods: Fifteen patients were submitted this implant from March 2005 to August 2007.

Results: The mean follow-up was 12.7 months (1-25 months). The echocardiography results showed: pulmonary insufficiency was mild in nine (60%) moderate in three (20%) and severe in three (20%); the systolic right ventricle function was normal in 13 (86.7%) and mild dysfunction in two (13.3%); 11 (73.4%) did not had any gradient though the valve and four (26.6%) had mild stenosis; the mobility and thickness of the valves were normal in all cases; there were no calcification; one patient had dilated pulmonary annulus with a Z score of + 2.5.

Conclusion: In midterm follow-up the decellularized homograft patch seams to be a good option to treat the right ventricle obstruction in patients with tetralogy of Fallot.

Descriptors: Tetralogy of Fallot. Heart defects, congenital. Treatment outcome. Child. Follow-up studies. Transplantation, homologous.

Resumo

Objetivo: Descrever a técnica de preparo e a evolução ecocardiográfica das cúspides de homoenxerto decelularizado utilizadas em pacientes com tetralogia de Fallot.

Métodos: No período de março de 2005 a agosto de 2007, 15 pacientes foram submetidos ao implante deste tipo de enxerto e foram acompanhados clinicamente e com ecocardiograma para avaliar o resultado morfofuncional dos enxertos.

1. Adjunct Professor of the Surgery Department of the Federal University of Paraná (Cardiovascular surgeon of Pequeno Príncipe Hospital).
2. Cardiovascular surgeon of Pequeno Príncipe Hospital
3. Specialist in Pediatric Cardiology; Pediatric Cardiologist of Pequeno Príncipe Hospital
4. PhD in Pediatric Cardiology; Pediatric cardiologist of Pequeno Príncipe Hospital.
5. Titular Professor of the Pontifical Catholic University of Paraná (PUCPR); Pediatric cardiologist of Pequeno Príncipe Hospital.
6. Titular Professor of the Pontifical Catholic University of Paraná; Cardiovascular surgeon of Pequeno Príncipe Hospital

This study was carried out at the Pequeno Príncipe Hospital; Dr. Raul Carneiro Hospital Association of Child Protection; Cardiovascular Surgery Service.
Curitiba - PR - Brasil

Correspondence address:

Prof. Dr. Leonardo Andrade Mulinari - Av. Marechal Floriano Peixoto 306, sala 141 Curitiba, PR – CEP 80010-130 Tel/Fax: (41) 3018-9911.
E-mail: dr.mulinari@terra.com.br

Article received on November 5nd, 2007

Article accepted on May 22th, 2008

Resultados: O acompanhamento médio foi de 12,7 meses (1-25 meses). A análise ecocardiográfica em médio prazo revelou: insuficiência pulmonar leve em nove (60%) pacientes, moderada em três (20%) e importante em três (20%); a função sistólica do ventrículo direito esteve preservada em 13 (86,7%) pacientes e com disfunção leve em dois (13,3%); 11 (73,4%) pacientes não apresentaram gradientes na via de saída do ventrículo direito (VD), e em quatro (26,6%) pacientes evidenciou-se a presença de estenose leve; a mobilidade da cúspide foi normal em todos os pacientes; não houve espessamento maior de 1,5mm nas cúspides analisadas; não se detectou nenhuma calcificação

nas cúspides. Catorze (93,3%) pacientes apresentaram Z score entre -1 e 0,7 e um (6,7%) paciente apresentou anel pulmonar com Z score de + 2,5.

Conclusão: O retalho de homoenxerto decelularizado parece ser uma boa opção para a ampliação da via de saída do VD nos pacientes submetidos à correção total da tetralogia de Fallot em médio prazo.

Descritores: Tetralogia de Fallot/cirurgia. Cardiopatias congênitas. Resultado de tratamento. Criança. Seguimentos. Transplante homólogo.

INTRODUCTION

The tetralogy of Fallot (TF) represents approximately 10% of congenital heart diseases, and the cyanotic congenital heart disease is the most common among them [1]. Although the patients receive surgical treatment at an older age, the best age for treatment is within the first six months of life, and is preferably a surgery for total correction [2-4].

The principles of intracardiac surgical correction have changed little since their first report by Lilehai in 1954 [5]. The approach of right ventricle outflow tract (RVOT) stenosis can be performed in several ways, depending on the morphology of the infundibulum and the pulmonary valve. The relief is best obtained with the resection of the infundibulum muscles of the right ventricle and, when necessary, with pulmonary commissurotomy, atriopulmonary correction [6]. In order to achieve this, the minimum acceptable values of two standard deviations below normal of the pulmonary ring (Z score = -2) and the right-to-left ventricular maximum pressure ratio (RV/LV 0,75) [7] must be met.

However, for the relief of RVOT stenosis in approximately 50% of corrections, enlargement with some kind of synthetic or biological material is necessary, whether with a valve or without. This kind of material is known as a "transannular patch."

Several kinds of transannular patches are used in the surgical treatment of TF. Among them, we would like to highlight the bovine pericardium patches with or without monocuspid, the synthetic tissue patches with monocuspid of expanded polytetrafluoroethylene (PTFE), and the cryopreserved homograft patches [8]. All of these patches have obvious limitations in the search for the best transannular patch, such as: an inability to grow, calcification and degeneration, all of which compromise the patch's durability [9].

The clinical outcomes obtained with the use of decelularized homograft in the RVOT as a valved tube in the Ross operation were excellent [10]. Based on this experience with the use of decellularized homografts - which presented advantages over cryopreserved homografts because they do not degenerated so quickly and still remain with their long-term functionality - we began to use this tissue when enlargement of the RVOT was needed in patients with TF.

The aim of this study is to describe the technique for preparing the transannular patch with cuspid of decellularized homograft, as well as to show the echocardiographic evolution of these grafts during the enlargement of the RVOT in the TF.

METHODS

Between March 2005 and August 2007, 51 patients with TF were operated. In five patients, the performed surgery was palliative, with a systemic pulmonary shunt. From the 46 remaining children, 18 were operated by only atriopulmonary access; in 10 patients, the transannular patch consisted of a bovine pericardium monocuspid; in 2, the cryopreserved homograft monocuspid; in one patient, a L-hydro heterograft was used, and in 15, the enlargement was performed using a valved patch made from decellularized homograft. This kind of graft was made available for us from March 2005.

The aim of this study was to perform follow-ups of the 15 patients with TF who needed enlargement of the RVOT, and for this procedure, a decellularized homograft was used as tissue.

This study was carried out at Pequeno Príncipe Hospital in Curitiba, Paraná in Brazil, and was approved by the ethics committee of this Institution (CEPSH - HPP 24/2007).

The process used in this study for the preservation and

decellularization of the graft was the “PUC,” because it was developed at the Human Heart Valve Bank of Santa Casa de Misericórdia in Curitiba, an institution linked to the Pontifical Catholic University of Paraná (PUCPR).

The homografts are harvested from cadavers that meet the criteria of organ donors. The hearts are transported to the Engineering and Cell Transplantation Laboratory – PUCPR – where the cardiac valves are dissected in laminar flow and the diameters in this step are measured with Hegar’s dilator. Next, the valves are immersed for 24 hours in a nutrient medium (Roswell Park Memorial Institute (RPMI) containing the antibiotics cefoxitin 240µg/ml, lincomycin 120µg/ml, B polymyxin 100µg/ml and vancomycin 50µg/ml, according to current protocol at the Human Heart Valve Bank of Santa Casa de Misericórdia in Curitiba. After this step, the valves are decellularized with sodium dodecyl sulfate (SDS) (a process which lasts 10 days), and kept in the nutrient medium (RPMI) with antibiotics at 4°C until the implant. At the end of the procedure, a control histological analysis is performed to confirm complete decellularization [11].

Out of these 15 patients, two have already been operated for total correction of TF and were re-operated to correct restenosis in RVOT.

The age of this group of patients ranged from 2 months to 11 years. The mean age for patients who underwent the first surgery was 15.2 months, and was 8 years for patients who underwent reoperations.

After installation of cardiopulmonary bypass with moderate hypothermia (32°C) and myocardial protection with multidose blood cardioplegia (4:1) at 4°C (Braile Biomédica®), the right atrium is opened, and the exploration of the right ventricular cavity is performed through the tricuspid valve. The surgeons must then decide whether the procedure will be performed through only atriopulmonary access - that is, without ventriculotomy. Otherwise, the pulmonary ring will be enlarged the minimum amount needed to relieve the RVOT. This ring is measured with graduated measuring instruments and compared to the pulmonary ring size table that determines a ring size based on surface area of the body.

Because the size of aortic or pulmonary cuspid in adults can vary by only a few millimeters and because only one cuspid will be used, we were able to choose any graft between 17mm and 23mm in diameter. As opposed to the cryopreserved grafts (which require about 30 minutes of preparation), the decellularized grafts come packaged and ready to use. The packaging is opened, the graft is inspected, and one of the larger cuspid is selected. The graft is cut to fit a segment of the aortic or pulmonary wall that is distal to this cuspid. This procedure is done in such way that the cuspid edge can be at the same level of the edges of the pulmonary valves after the implant (Figures 1 to 3).

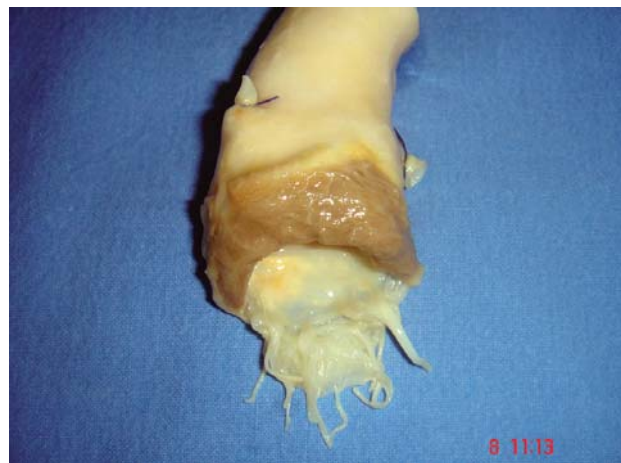

Fig. 1 – Decellularized aortic homograft

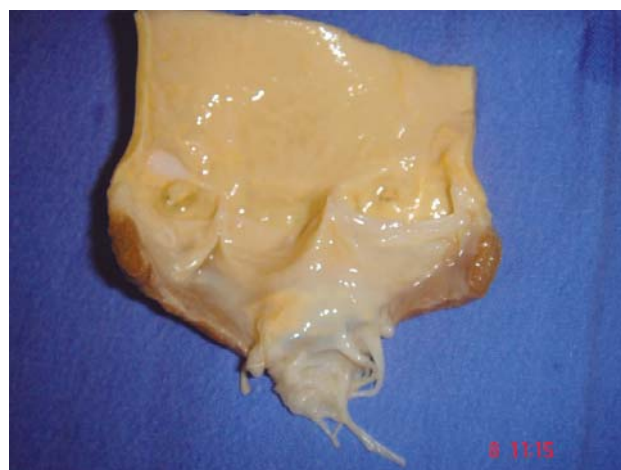

Fig. 2 – Sectioned homograft in its longitudinal axis. In detail, the preservation of the anterior leaflet of the mitral valve

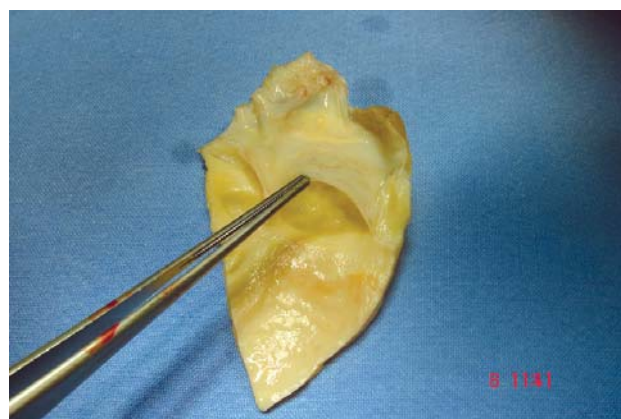


Fig. 3 – Aortic monocuspid homograft with the anterior leaflet of the mitral valve

The preference is given to pulmonary homografts if the ventriculotomy can be minimal (Figure 4). Aortic homografts are preferred in cases of hypoplastic infundibula because the aortic-mitral valve contiguity allows for the anterior leaflet of the homograft mitral valve to be used as complement during the ventriculotomy closure “below” the monocuspid (Figure 5). In cases in which the pulmonary homograft was used and the graft extension proved to be necessary for the ventriculotomy closure, a segment of bovine pericardium was used (Figure 6).

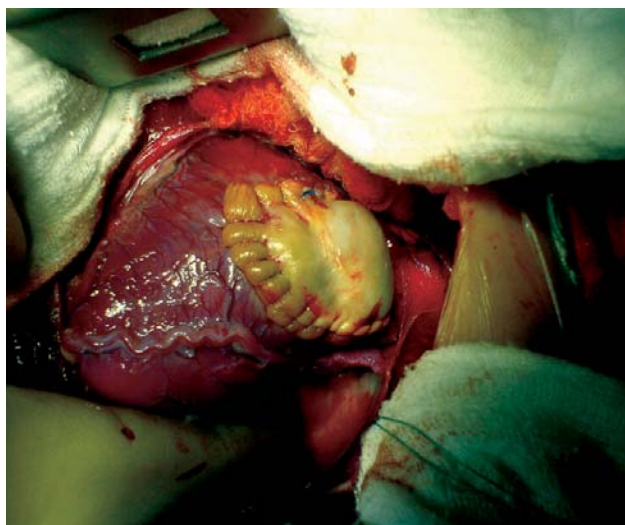


Fig. 4 – Pulmonary monocuspid homograft implantation

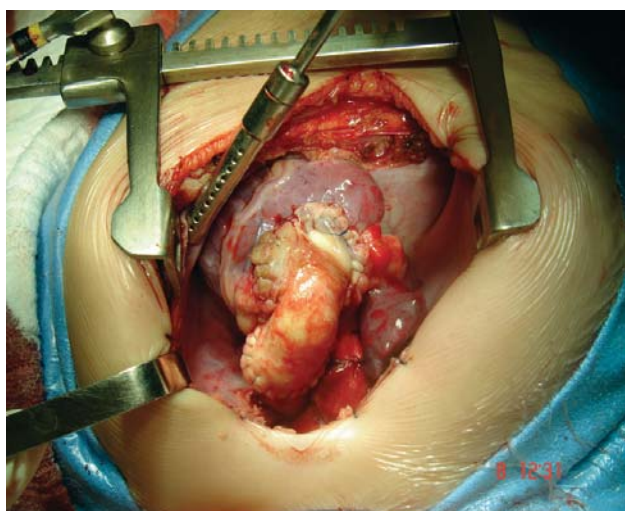


Fig. 5 – Aortic monocuspid homograft implantation with extension of the anterior leaflet of the mitral valve

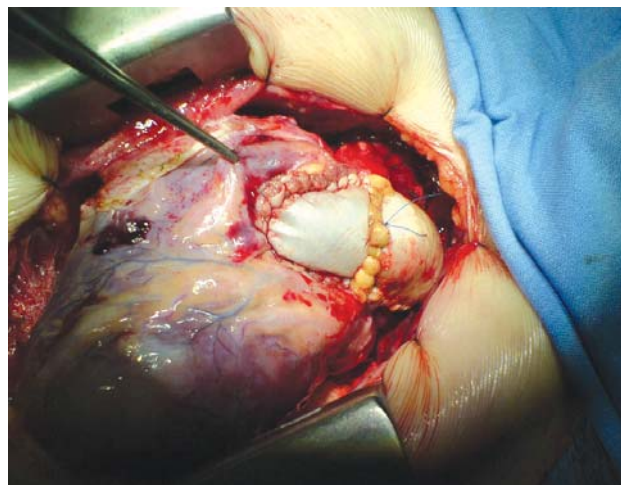


Fig. 6 – Pulmonary monocuspid homograft implantation with bovine pericardium extension

The closure of interventricular communication is performed using the tricuspid valve with bovine pericardium or a PTFE patch. Next, the transannular patch of decellularized homograft is carefully implanted to put the edge of the cuspid on the same level of the patient’s cuspid. A bicuspid graft was used in one patient and a monocuspid in the others. At the end of the procedure, the RV/LV pressure ratio was taken for all patients.

To evaluate these grafts, the patients received follow-up exams during the immediate postoperative period and after being discharged. The patients received both clinical and echocardiographic evaluations. Doctors compared the echocardiogram scores from the exam performed before discharge to the scores from the exam that was performed during the outpatient appointments. This comparison is made in an attempt to evaluate:

a) Pulmonary insufficiency: the pulmonary insufficiency was evaluated by color Doppler in parasternal short axis position with visualization of the largest possible area of the right ventricle and pulmonary valve. Pulmonary insufficiency – when the reflux occurred in the juxta-valvar right ventricle outflow tract – was slight. When the reflux area took up 20% to 40% of the right ventricle, the pulmonary insufficiency was moderate; and when the reflux area was greater than or equal to 40% of the total area of the right ventricle (and also if there was a holodiastolic increase in the pulmonary branches), the pulmonary insufficiency was considered severe;

b) RV function: RV function was evaluated by the ejection fraction using the Simpson method, and was considered normal if it was above 48%;

c) RVOT gradient: Expressed as peak gradient. Slight stenosis was defined as peak gradient between 0 and

20mmHg; moderate stenosis was defined as peak gradient greater than 20 and 40mmHg, and stenosis was considered severe when the gradient was greater than 40mmHg;

d) Homograft cuspid mobility: classified as normal or reduced;

e) Leaflet thickness: leaflet was considered absent if it had a thickness of less than 1.5mm; moderate if it had a thickness between 1.5 and 3mm, and severe if it had a thickness greater than 3mm;

f) Presence of calcification: classified as present or absent;

g) Pulmonary "ring" size (Z score): we define pulmonary ring as the region just below the coaptation of the patient's cuspid with the homograft. For calculation of the Z score, we used the information from the nomograms table relative to the body surface.

In this study, the results are limited to analysis of the last echocardiogram performed in the patients.

RESULTS

The 15 patients survived and received follow-up outpatient care, where they were evaluated using clinical examinations and echocardiography. The mean evolution was 12.7 months, ranging from 1 to 25 months.

The patients are clinically well, in New York Heart Association functional class I or II.

The echocardiographic analysis of the last return revealed the following:

a) Pulmonary insufficiency: nine (60%) patients presented mild pulmonary insufficiency, three patients (20%) were moderate, and three (20%) were severe;

b) RV funtion: 13 patients (86.7%) presented preserved RV systolic function and two patients (13.3%) presented slight systolic dysfunction (EF by Simpson of 31 and 39%);

c) RVOT gradient: 11 patients (73.4%) did not present RVOT gradients, and in four patients (26.6%), there was slight pulmonary stenosis;

d) Homograft cuspid mobility: normal in all patients;

e) Leaflet mobility: there was no thickening greater than 1.5mm in the analyzed leaflets;

f) Calcification: there was not calcification in decellularized cuspid;

g) Pulmonary "ring" size (Z score): 14 patients (93.3%) presented Z score between -1 and 0.7 and only one patient (6.7%) presented pulmonary ring with a score of Z +2.5.

DISCUSSION

Our purpose for patients with good TF anatomy is always total primary correction, at any age and in both elective and emergency surgeries.

Currently, in terms of surgical of correction of TF, the

main question is about how to enlarge the RVOT. Because there are several aspects regarding the enlargement, we must decide how much the pulmonary ring should be enlarged. We must consider which tissue should be used in this enlargement and how to provide competency to the pulmonary valve in short- and long-term.

This study aims to show an alternative to the RVOT enlargement using a homologous and decellularized tissue (with cuspid). In this way, we put forward a theoretical attempt at a graft with greater durability potential than those currently available.

Two main aspects must be emphasized when the enlargement is necessary: first, the late functional evolution of the patients operated on for TF will be better if the presence of pulmonary insufficiency was minor; secondly, the absence of arrhythmias seems to be an important factor for long-term survival [12-14]. Thus, when the RVOT is needed, it should aim for a minimum ventriculotomy, because less healing in ventricular tissue seems to be related to a lower incidence of arrhythmia, as well as the use of some kind of valve mechanism to minimize the occurrence of pulmonary insufficiency [15-17].

The minimum ventriculotomy is an easy step during a surgical procedure; however, pulmonary valve competency remains a challenge for cardiovascular surgeons. Thus, because the patients are still operated in the first year of life, the use of a valve mechanism needs to solve the problems of durability (which are growth and the absence of degeneration) [18-19].

Recently, a new kind of biological tissue processing has been arousing great interest. This process is called decellularization, and consists of several chemical treatments that allow for the decellularization of the valve cuspid and the tube arterial walls. For decellularization, others have proposed the use of trypsin, sodium dodecyl sulphate, octyl phenoxyethanol, deoxicolic acid, hypo- and hypertonic solutions, enzymes such as RNase and DNase, ethanol, and glycerol. Apart from the current methodology, the aim is to obtain an acellular tissue without damaging the components of the extracellular matrix, such as collagen and elastic fibers, as well as to keep macromolecules proportions intact. Thus, the purpose is to obtain an immunologically inert matrix with preserved biomechanical properties that is non-cytotoxic and totally biocompatible [20-21].

Decellularized homografts are already in clinical use, especially for replacement of RVOT as a conduit for the Ross surgery, and with a fair functional outcome. These studies have shown that decellularized grafts may be related to a lower immune response when compared with cryopreserved grafts [22-25].

Although there are many available processes of

decellularization, all grafts in this study were decellularized with the technique described as "PUC," which was completely arranged by the Human Heart Valve Bank of Santa Casa de Misericórdia in Curitiba.

We understand that decellularization as a technology for tissue preparation may bring benefits to patients with TF. We emphasize that the availability of these grafts is limited because they depend on organ donations.

The analysis of any valve substitute should be done the in short-, mid- and long-term. In this study of patients with TF, the immediate analysis is impaired in terms of insufficiency because, since the right ventricle is very hypertrophic and not very complacent, it is not possible to perform an accurate evaluation of pulmonary insufficiency. The echocardiogram uses the same evaluation methods for aortic insufficiency to evaluate pulmonary insufficiency; however, all of these methods present limitations for pulmonary valve evaluation [26]. Another aspect to note is that, when comparing patients with the same degree of pulmonary insufficiency, those who have an intact infundibulum present a better long-term evolution [27].

As the aim of this study is to improve the mid- and long-term evolution of the patients who underwent surgical correction, we simply analyzed the patients' last echocardiograms.

The immediate evolution of the patients operated on for TF is currently very good; however, we should be concerned with the long-term evolution. In this study, we used the echocardiographic follow-up results to show that the RVOT enlargement in patients who received the decellularized homograft was fair immediately after surgery and during the midterm evaluation.

The absence of any calcification and the presence of normal mobility and thickness of the cusps are the main factors that encourage us to prefer these substitutes to other substitutes, such as the bovine pericardium grafts, which are known to present rapid calcificam after implantation [28].

This kind of transannular patch was effective, both to prevent restenosis and for pulmonary valve efficiency. However, this kind of graft is limited by its availability. Finally, it is worth noting that, for an evaluation of restenosis or late pulmonary insufficiency, we need a more long-term follow-up of these patients.

CONCLUSION

The decellularized homograft patch with cuspid seems to be a good option for right ventricle outflow tract enlargement in patients who underwent total correction of TF in an mean period of 12.7 months and at a maximum of 25 months.

REFERENCES

1. Hoffman JI. Incidence of congenital heart disease: I. Postnatal incidence. *Pediatr Cardiol*. 1995;16(3):103-13.
2. Zannini L, Borini I. State of the art of cardiac surgery in patients with congenital heart disease. *J Cardiovasc Med (Hagerstown)*. 2007;8(1):3-6.
3. Moraes Neto F, Gomes CA, Lapa C, Hazin S, Tenório E, Mattos S, et al. Tratamento cirúrgico da tetralogia de Fallot no primeiro ano de vida. *Rev Bras Cir Cardiovasc*. 2000;15(2):143-53.
4. Sadiq A, Shyamkrishnan KG, Theodore S, Gopalakrishnan S, Tharakan JM, Karunakaran J. Long-term functional assessment after correction of tetralogy of Fallot in adulthood. *Ann Thorac Surg*. 2007;83(5):1790-5.
5. Lillehei CW, Cohen M, Warden HE, Varco RL. The direct-vision intracardiac correction of congenital anomalies by controlled cross circulation; results in thirty-two patients with ventricular septal defects, tetralogy of Fallot, and atrioventricularis communis defects. *Surgery*. 1955;38(1):11-29.
6. Pacifico AD, Kirklin JK, Colvin EV, McConnell ME, Kirklin JW. Transatrial-transpulmonary repair of tetralogy of Fallot. *Semin Thorac Cardiovasc Surg*. 1990;2(1):76-82.
7. Kirklin JK, Kirklin JW, Pacifico AD. Transannular outflow tract patching for tetralogy: indications and results. *Semin Thorac Cardiovasc Surg*. 1990;2(1):61-9.
8. Brown JW, Ruzmetov M, Vijay P, Rodefeld MD, Turrentine MW. Right ventricular outflow tract reconstruction with a polytetrafluoroethylene monocusp valve: a twelve-year experience. *J Thorac Cardiovasc Surg*. 2007;133(5):1336-43.
9. Bechtel JF, Gellissen J, Erasmi AW, Petersen M, Hiob A, Stierle U, et al. Mid-term findings on echocardiography and computed tomography after RVOT-reconstruction: comparison of decellularized (SynerGraft) and conventional allografts. *Eur J Cardiothorac Surg*. 2005;27(3):410-5.
10. Costa FD, Pereira EW, Barboza LE, Haggi Filho H, Collatusso C, Gomes CH, et al. Ten-year experience with the Ross operation. *Arq Bras Cardiol*. 2006;87(5):583-91.
11. Homoexertos Valvares Decelularizados. Ensaio Experimentais e Clínicos. Banco de Valvas Cardíacas Humanas da Santa Casa de Misericórdia de Curitiba. Curitiba: Pontifícia Universidade Católica do Paraná; 2007.
12. Kalil RAK, Prates PR, Sant' Anna JRM, Prates PRL, Vedolin L, Teixeira Filho GF, et al. Ausência de ventriculotomia previne arritmias ventriculares pós correção da tetralogia de Fallot? *Rev Bras Cir Cardiovasc*. 1997;12(1):30-3.

13. Folino AF, Daliento L. Arrhythmias after tetralogy of Fallot repair. *Indian Pacing Electrophysiol J.* 2005;5(4):312-24.
14. Uebing A, Fischer G, Bethge M, Scheewe J, Schmiel F, Stieh J, et al. Influence of the pulmonary annulus diameter on pulmonary regurgitation and right ventricular pressure load after repair of tetralogy of Fallot. *Heart.* 2002;88(5):510-4.
15. He GW. A new technique of transannular monocusp patch-repair of the right ventricular outflow tract in repair of tetralogy of Fallot. *Heart Lung Circ.* 2007;16(2):107-12.
16. Kirklin JW, Blackstone EH, Jonas RA, Shimazaki Y, Kirklin JK, Mayer JE Jr, et al. Morphologic and surgical determinants of outcome events after repair of tetralogy of Fallot and pulmonary stenosis. A two-institution study. *J Thorac Cardiovasc Surg.* 1992;103(4):706-23.
17. Kadner A, Tulevski II, Bauersfeld U, Prêtre R, Valsangiacomo-Buechel ER, Dodge-Khatami A. Chronic pulmonary valve insufficiency after repaired tetralogy of Fallot: diagnostics, reoperations and reconstruction possibilities. *Expert Rev Cardiovasc Ther.* 2007;5(2):221-30.
18. Boethig D, Goerler H, Westhoff-Bleck M, Ono M, Daiber A, Haverich A, et al. Evaluation of 188 consecutive homografts implanted in pulmonary position after 20 years. *Eur J Cardiothorac Surg.* 2007;32(1):133-42.
19. Sayk F, Bos I, Schubert U, Wedel T, Sievers HH. Histopathologic findings in a novel decellularized pulmonary homograft: an autopsy study. *Ann Thorac Surg.* 2005;79(5):1755-8.
20. Cebotari S, Lichtenberg A, Tudorache I, Hilfiker A, Mertsching H, Leyh R, et al. Clinical application of tissue engineered human heart valves using autologous progenitor cells. *Circulation.* 2006;114(1 Suppl):I132-7.
21. Zehr KJ, Yagubyan M, Connolly HM, Nelson SM, Schaff HV. Aortic root replacement with a novel decellularized cryopreserved aortic homograft: postoperative immunoreactivity and early results. *J Thorac Cardiovasc Surg.* 2005;130(4):1010-5.
22. Bechtel JF, Müller-Steinhardt M, Schmidtke C, Brunswik A, Stierle U, Sievers HH. Evaluation of the decellularized pulmonary valve homograft (SynerGraft). *J Heart Valve Dis.* 2003;12(6):734-9.
23. Hawkins JA, Hillman ND, Lambert LM, Jones J, Di Russo GB, Profaizer T, et al. Immunogenicity of decellularized cryopreserved allografts in pediatric cardiac surgery: comparison with standard cryopreserved allografts. *J Thorac Cardiovasc Surg.* 2003;126(1):247-52.
24. da Costa FD, Dohmen PM, Duarte D, von Glenn C, Lopes SV, Haggi Filho H, et al. Immunological and echocardiographic evaluation of decellularized versus cryopreserved allografts during the Ross operation. *Eur J Cardiothorac Surg.* 2005;27(4):572-8.
25. Costa F, Fornazari DF, Matsuda CN, Torres RA, Sardetto E, Ferreira ADA, et al. Dez anos de experiência com a substituição da valva aórtica com homoenxertos valvares aórticos implantados pela técnica da substituição total da raiz *Rev Bras Cir Cardiovasc.* 2006;21(2):155-64.
26. Snider AR, Serwer GA, Ritter SB. *Echocardiography in pediatric heart disease.* 2nd ed. St. Louis: Mosby; 1997. p.189.
27. d'Udekem d'Acoz Y, Pasquet A, Lebreux L, Ovaert C, Mascart F, Robert A, et al. Does right ventricular outflow tract damage play a role in the genesis of late right ventricular dilatation after tetralogy of Fallot repair? *Ann Thorac Surg.* 2003;76(2):555-61.
28. Anijar AM, Maluf MA, Buffolo E. Reconstrução da continuidade ventrículo-pulmonar (conexão VD-TP): técnicas e táticas cirúrgicas. *Rev Bras Cir Cardiovasc.* 1998;13(1):33-41.