

# Double skeletonized internal thoracic artery vs. double conventional internal thoracic artery in diabetic patients submitted to OPCAB

*Dupla artéria torácica esqueletizada versus convencional na revascularização do miocárdio sem CEC em diabéticos*

Rodrigo MILANI<sup>1</sup>, Paulo Roberto BROFMAN<sup>2</sup>, Maximiliano GUIMARÃES<sup>3</sup>, Laura BARBOZA<sup>3</sup>, Rodrigo Mezzalira TCHAICK<sup>4</sup>, Hugo MEISTER FILHO<sup>4</sup>, Thales BAGGIO<sup>4</sup>, Francisco MAIA<sup>5</sup>

RBCCV 44205-999

## Abstract

**Objective:** To evaluate the influence of the technique used in the dissection of thoracic arteries in the evolution of diabetic patients submitted to OPCAB.

**Methods:** Seventy diabetic patients submitted to OPCAB using bilateral thoracic arteries were evaluated. In Group A, thoracic arteries were dissected as a pedicle, while in Group B they were skeletonized.

**Results:** The mean age of patients in Group A was  $52.14 \pm 7.35$  years old versus  $55.71 \pm 8.1$  years for Group B ( $p=0.057$ ). In Group A, six patients (17.1%) were insulin dependent against nine (25.7%) in Group B ( $p = 0.561$ ). The EUROSCORE was  $3.97 \pm 2.49$  for Group A opposed to  $4.14 \pm 3.06$  for Group B ( $p = 0.879$ ). The number of distal anastomoses in Group A was  $3 \pm 0.77$  versus  $3.03 \pm 0.89$  in Group B ( $p = 0.981$ ). Three patients (8.57%) from Group A presented with mediastinitis. Insulin dependence was the only significant risk factor ( $p=0.008$ ) for mediastinitis. In this group the use of skeletonized ITAs significantly decreased the incidence of mediastinitis ( $p = 0.044$ ).

**Conclusion:** The incidence of mediastinitis was lower in the group for which thoracic arteries were dissected using

skeletonization. Among insulin-dependent diabetics, 50% of the patients from the group in which the pedicled internal thoracic artery was utilized presented with mediastinitis; the utilization of skeletonized ITAs significantly decreases the incidence of mediastinitis.

**Descriptors:** Myocardial revascularization. Thoracic arteries. Diabetes mellitus.

## Resumo

**Objetivo:** Avaliar a influência da técnica utilizada na dissecação das artérias torácicas na evolução de pacientes diabéticos submetidos a revascularização sem CEC.

**Métodos:** Setenta pacientes diabéticos submetidos a revascularização sem CEC com duas artérias torácicas foram avaliados. No grupo A, as artérias torácicas foram dissecadas de modo convencional, enquanto no grupo B foram esqueletizadas.

**Resultados:** A idade média do grupo A foi de  $52,14 \pm 7,35$  anos contra  $55,71 \pm 8,1$  anos no grupo B ( $p=0,057$ ). No grupo A, seis (17,1%) pacientes eram diabéticos insulino-dependentes contra nove (25,7%) no grupo B ( $p=0,561$ ). O

1. Master in Surgical Practice; PhD in Surgical Practice; Adjunct professor of PUC/PR; Cardiovascular Surgeon
2. Master in Surgical Practice; PhD in Surgical Practice; Titled professor of PUC/PR; Cardiovascular Surgeon
3. Specialist; Cardiovascular Surgeon
4. Resident in Cardiovascular Surgery
5. Master; Cardiologist.

Correspondence address:

Prof. Dr. Rodrigo Milani

Rua Cezar Correia de Souza, 54 - Sta Felicidade - Curitiba - PR - Brasil. CEP: 82015-220. Tel.: (41) 3323-4926 Fax: (41) 3232-8982

E-mail: rodrigo.milani@sbccv.org.br

Work carried out in Santa Casa de Misericórdia PUC/PR, Curitiba, PR, Brazil

Article received on January 14<sup>th</sup>, 2008

Article accepted on July 7<sup>th</sup>, 2008

EUROSCORE foi de  $3,97 \pm 2,49$  para o grupo A contra  $4,14 \pm 3,06$  no grupo B ( $p=0,879$ ). O número médio de anastomoses distais no grupo A foi de  $3 \pm 0,77$  contra  $3,03 \pm 0,89$  para o grupo B ( $p=0,981$ ). Três (8,57%) dos pacientes do grupo A apresentaram mediastinite contra nenhum do grupo B ( $p=0,239$ ). A diabetes insulino-dependente foi o único fator estatisticamente significativo ( $p=0,008$ ) para mediastinite. Neste grupo, a utilização de artéria torácica interna esqueletizada diminuiu significativamente a incidência de mediastinite ( $p=0,044$ ).

**Conclusão:** A incidência de mediastinite foi menor no

grupo onde ambas as artérias torácicas foram dissecadas de forma esqueletizada, apesar de, devido ao baixo número de casos, não apresentar diferença estatística. Nos portadores de diabetes insulino-dependente, 50% dos pacientes do grupo em que a artéria torácica foi obtida de forma convencional apresentaram mediastinite, sendo que a utilização de artéria torácica esqueletizada diminuiu significativamente a incidência de mediastinite.

**Descritores:** Revascularização miocárdica. Artéria Torácica Interna. Diabetes mellitus.

## INTRODUCTION

The routine use of the left internal thoracic artery (LITA) for coronary artery bypass grafting (CABG) has been reported since the start of the 1980s [1]. The results of its utilization after 10 years show a greater superiority in respect to the saphenous vein when atherosclerotic disease-free evolution is considered over the same period [2]. For the patient, this represents a longer survival free of angina and without the necessity of reoperations [3].

The use of both internal thoracic arteries (ITAs) for CABG has been much debated by cardiovascular surgeons [4], and their utilization represents a modification in previously employed operative routines. Several studies have been published showing greater benefits when both ITAs are used for CABG [5-8].

In diabetic patients, especially those with type I diabetes, the use of both ITAs is an issue for great concern due to possible complications related to the sternum with the reduction in vascularization [9].

Some recent studies have demonstrated that the removal of skeletonized ITAs preserves the blood flow to the sternum and, consequently, diminishes the incidence of sternal complications [10].

In this study, we retrospectively evaluated two groups of diabetic patients; one group used skeletonization of both ITAs and the other used conventionally harvested thoracic arteries. The main aim of the study was to assess the incidence of complications related to the sternum.

## METHODS

Seventy diabetic patients, submitted to off-pump CABG utilizing both ITAs were retrospectively evaluated. The seventy patients were divided into two groups: in Group A, both ITAs were obtained in the conventional manner, while in Group B the ITAs were obtained using skeletonization.

The anesthetic technique and initial preparation have previously been described [11]. After opening the sternum and performing hemostasis (bone wax was not utilized) the left pleura was opened in both groups. After harvesting the left internal thoracic artery (LITA), the same procedure was performed on the right. In Group A, the arteries were conventionally harvested using clip 200 (Horizon) for hemostasis of the larger branches and cauterization (Valleylab force 2) with a power of 30W for coagulation of the smaller branches. Both anterior intercostal veins were removed together with the ITAs.

In Group B, both ITAs were harvested using skeletonization (Figure 1). The clip employed was smaller, clip 100 (Horizon) and the power of cauterization (Valleylab – force 2) was half that used for Group A. All the branches of the ITA in Group B were ligated and both anterior intercostal veins were preserved. Simultaneously, when necessary, the great saphenous vein was dissected in both groups.

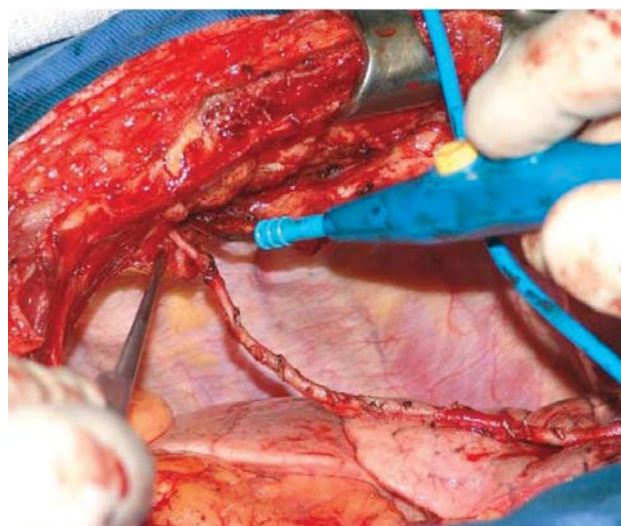


Fig. 1 - Skeletonized Internal Thoracic Artery

After harvesting both ITAs, 2.0 mg/kg of heparin was administered to all patients. After opening the pericardium, a stitch of 2-0 ethibond fixed to a strip of cotton measuring 3.5 x 70 cm was applied to the pericardial deflection between the inferior vena cava and the left inferior pulmonary vein [12].

The distal anastomoses were performed first. When venous grafts were necessary, the order started with the right coronary artery and its branches, then the circumflex artery and its branches, finishing with the anterior wall, anterior interventricular artery and its branches.

The LITA was preferentially utilized for the anterior interventricular artery, but, in some patients it was used for the marginal branches of the circumflex artery. The right internal thoracic artery (RITA) was normally utilized for the marginal branches of the circumflex artery and, in some patients, for the anterior interventricular artery and the right coronary artery (Figure 2).

When performing the anastomoses, the approached coronary artery was temporarily occluded by means of a proximal ligature using 4-0 prolene thread supported on silicone. To perform the distal anastomoses, apart from the Lima stitch [12], a suction stabilizer (ESTECH) was utilized – Figure 3.

In patients who received venous grafts, at the end of the distal anastomoses the aorta was partially clamped and the proximal anastomoses were carried out.

The initial dose of heparin was reverted at 75%. Patients were prescribed nitroglycerin for a period of 24 hours from the end of the operation. All the patients remained in the intensive care unit for at least one night.

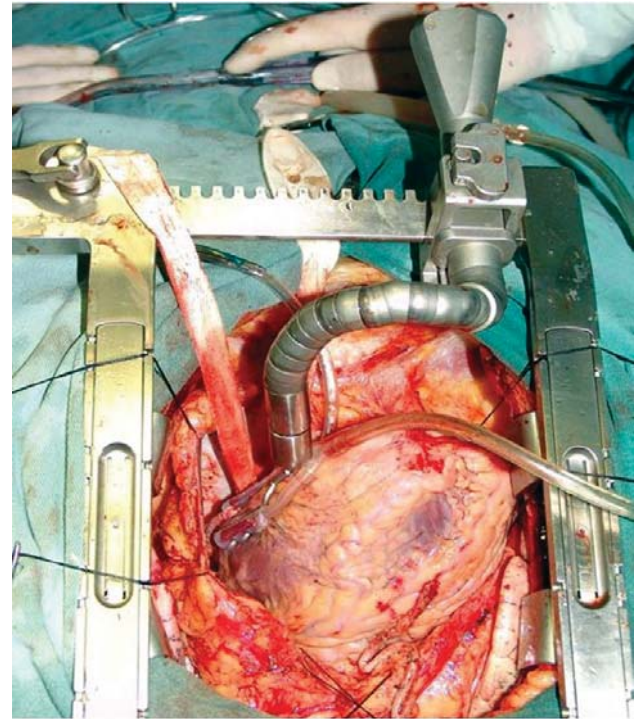


Fig. 3 - Suction stabilizer (Estech)

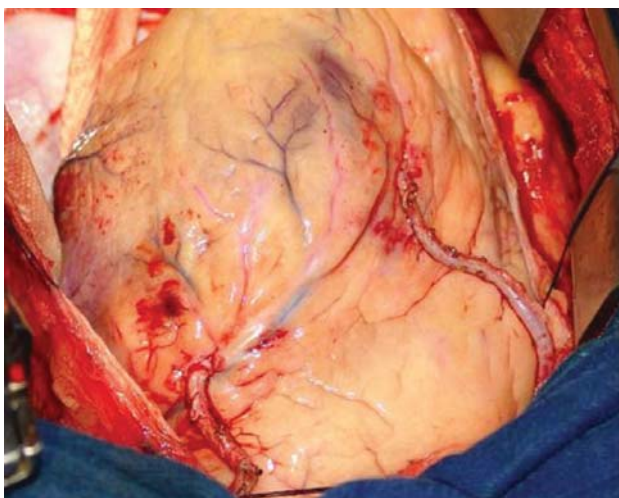


Fig. 2 - Double skeletonized Internal Thoracic Artery

## RESULTS

Seventy diabetic patients submitted to off-pump CABG were evaluated. The patients were divided into two groups. In Group A, with 35 patients, both ITAs were harvested in the conventional manner, while the 35 patients of Group B received both ITAs harvested using skeletonization.

In Group A, the mean age was  $52.14 \pm 7.35$  years, ranging from 38 to 68 years old, while in Group B the mean age was  $55.71 \pm 8.1$  years ( $p$ -value = 0.57) varying between 39 and 75 years old. In Group A, 24 patients (68.5%) were men versus 25 (71.4%) in Group B ( $p$ -value = 1).

In respect to the risk factors for coronary artery disease, among the patients of Group A, 31 (88.5%) were hypertensive versus 34 (97.1%) in Group B ( $p$ -value = 0.356) and 17 patients (48.5%) of Group A had high levels of cholesterol opposed to 14 (40%) of Group B ( $p$ -value = 0.631). In Group A, 17 patients (48.5%) were smokers versus 11 (31.4%) in Group B ( $p$ -value = 0.222).



All the 70 patients were diabetics and among those of Group A, 6 (17.1%) were insulin dependent against 9 (25.7%) of Group B (p-value = 0.561). One patient (2.8%) of Group A suffered from chronic renal failure while 4 patients (11.4%) in Group B suffered from this disease (p-value = 0.356).

In relation to the functional class in the preoperative period, 20 patients (57.1%) of Group A were in functional class III/IV against 18 (51.4%) of Group B (p-value = 0.811). The left ventricle ejection fraction was normal in 10 patients (28.57) of both groups, it was moderately affected (35% to 55%) in 11 patients (31.34%) of Group A against 14 (40%) of Group B (p-value = 0.303), and was significantly affected, with an ejection fraction of less than 35% in 14 patients (40%) of Group A and 11 patients (31.43%) of Group B (p-value = 0.303).

The EUROSCORE for preoperative mortality risk was  $3.97 \pm 2.49$  with a variation between 0 and 10 points for Group A and  $4.14 \pm 3.06$  (p-value = 0.879) ranging from 0 to 11 points for Group B. The mean number of coronary arteries revascularized was  $3 \pm 0.77$  (range: 2 to 5) in Group A and  $3.03 \pm 0.89$  (range: 2 to 5) in Group B (p-value = 0.981).

In Group A the LITA was utilized for the anterior interventricular branch in 16 patients (45.7%), for the marginal branches of the circumflex artery in 13 patients (37.1%) and for the diagonal and diagonalis arteries in 6 (17.1%). The RITA was used for the anterior interventricular branch in 18 patients (51.4%), for the marginal branches of the circumflex artery in eight (22.8%), for the diagonalis artery in one (2.8%) and for the right coronary artery in eight (22.8%). In Group B, the LITA was utilized for the anterior interventricular branch in 25 patients (71.4%), for the marginal branches of the circumflex artery in nine patients (25.7%) and for the diagonal artery in one (2.8%). The RITA was used for the anterior interventricular branch in nine patients (25.7%), for the marginal branches of the circumflex artery in 13 (37.1%), for the diagonal artery in one (2.8%) and for the right coronary artery in 12 (34.2%).

Seventeen patients (48.5%) of Group A and 14 patients (40%) of Group B remained for one night in the intensive care unit (p-value = 0.631). Only six patients (17.1%) of Group A and nine (25.7%) of Group B remained more than two nights in the intensive care unit (p-value = 0.561). When the complications of the patients were evaluated, six patients (17.1%) of Group A presented with acute atrial fibrillation against four (11.4%) of Group B (p-value = 0.734), and four patients (11.4%) of Group A and three (8.57%) of Group B suffered from bronchopneumonia. Three patients (8.57%) of Group A presented with mediastinitis versus no patients of Group B (p-value = 0.239). Insulin-dependent

diabetes was the only statistically significant factor for mediastinitis (p-value = 0.008). In this subgroup of insulin-dependent diabetic patients, the use of skeletonized ITAs significantly reduced the incidence of mediastinitis (p-value = 0.044).

## DISCUSSION

The superiority of the LITA compared to the great saphenous vein in revascularization of the anterior interventricular artery considering the survival rate and patency is well known [13-15]. The utilization of a second arterial graft in CABG, in particular the right ITA, has been shown in a series of works [5-8] as a predictive factor of better patency and long-term survival. The RITA has characteristics similar to the LITA however there is some resistance to its use due to the possible increase in the incidence of sternal complications, especially in diabetic patients and its short length, which limits its utilization as an in situ graft, and the increase in operative time for its harvesting.

Recently the use of bilateral skeletonized ITAs in diabetic patients has resulted in a sternal complication rate similar to non-diabetic patients, as well as, an apparently longer segment of graft with a better flow. And so it is possible to utilize both ITAs in practically the entire heart [16].

Harvesting of the ITA using skeletonization is defined as removal of the arterial conduit maintaining its satellite veins as well as the tissue around the artery. As the ITA is more exposed using this technique, direct electrocauterization should be avoided, thereby minimizing the occurrence of spasms and lesions. All the branches should be directly ligated, with small metal clips being the most practical manner to achieve this.

Menezes et al. [17] described the removal of the LITA using skeletonization employing an ultrasonic scalpel and without the use of metal clips. The results of 188 patients enrolled in this study were reported; there was no necessity to use maneuvers to increase the blood flow in the graft and there was no infection of the sternum. The time required to harvest the skeletonized ITA was 33 minutes. The authors concluded that this technique reduces the time ITA harvesting, does not cause spasms, does not require metal clips and is an easily reproduced procedure recommended for skeletonization. In our series, although this was not an objective of the study, it was clear that the bilateral removal of skeletonized ITAs requires a longer operative time than harvesting using the conventional method. This additional time, however, is partially recovered at the end of the operation during the review of hemostasis, as both reviewing the

thoracic wall and the ITAs are quicker when skeletonization is used.

De Paulis et al. [18], in their work, demonstrated the role of the harvesting technique of both ITAs in superficial and deep infections of the sternum. The authors compared a group of 300 patients, in which both arteries were obtained using the conventional method, with a group of 150 patients in which bilateral skeletonization was used. The use of skeletonized ITAs was one of the factors that determined the lower incidence of superficial and deep sternal infections. The authors concluded that the use of both ITAs gave rise to a high risk of sternal infections when compared to the use of just one and that the use of bilateral skeletonized ITAs significantly diminished this risk and could be used in patients with high risk of sternal complications.

Peterson et al. [19] analysed the results of two groups of diabetic patients submitted to CABG using both ITAs. In Group A, with 70 patients, the ITAs were dissected using the skeletonization technique and in Group B, with 36 patients, the ITAs were removed using the conventional method. For the patients of Group A, there was a significantly lower rate of sternal complications. The authors concluded that with the use of skeletonized ITAs, diabetic patients are no longer contraindicated for this strategy of surgical procedure.

A review article, in which 214 diabetic patients submitted to off-pump CABG using both ITAs were analyzed, Hirose et al. [20] demonstrated the effectiveness of skeletonization in the prevention of sternal infections, whether superficial or deep. In their comments, the authors referred to the necessity of using ultrasonic cauterization to improve the harvesting of skeletonized thoracic arteries, as the use of conventional electrocauterization may cause heat lesions due to the absence of adjacent tissues. The authors commented that, before skeletonization, approximately 34% of diabetic patients received two thoracic arteries, with this number increasing to 61% of diabetic patients with the use of skeletonization. In this series, the incidence of sternal complications was less in the skeletonized group. The incidence of mediastinitis was 0.9% in patients who used the skeletonized ITAs versus 3% in the pedicled group, and, the incidence of superficial infection of the sternum was 3.5% in the skeletonized group compared to 12.1% in the conventional group.

The authors concluded that the bilateral use of skeletonized thoracic arteries in diabetic patients is safe and may reduce the incidence of sternal complications.

Miana et al. [21] presented a study utilizing the RITA (20 patients) or the radial artery (38 patients) as the second arterial graft. The authors did not observe statistical differences in the immediate evolution of the patients when

death, reoperation for bleeding and mediastinitis were assessed. However, they stressed that for the group of patients who received RITA grafts, the time of operation was greater.

In a recent article, Martins et al. [22] presented their results of a group of patients submitted to CABG utilizing both ITAs. Of a total of 700 patients enrolled, 552 were non-diabetic and 148 were diabetic. The groups were statistically similar in respect to age, gender, risk factors, previous infarction, functional class and number of distal anastomoses per patient. An analysis of the results showed no significant differences when death, bleeding and sternal dehiscence were evaluated. The authors concluded that critical selection of patients and a refined operative technique may benefit diabetic patients with the bilateral use of the ITAs.

In our series, we evaluated two groups of diabetic patients in whom both ITAs were employed in CABG, with, for one group the arteries being removed using the pedicled technique and for the other, both arteries were dissected using the skeletonization method. The incidence of insulin-dependent diabetics was similar in both groups, as was the incidence of other risk factors. The mean number of revascularized coronary arteries was also similar for the two groups. In the group that received two pedicled ITAs, three patients evolved with mediastinitis, while in the skeletonized artery group, none of the patients had this complication. In the statistical analysis, insulin-dependent diabetes mellitus was the only statistically significant risk factor for the development of mediastinitis. The bilateral utilization of skeletonized ITAs significantly reduced the incidence of this complication.

Even after the initial period, required to completely dominate the ITA skeletonization technique, the time spent to obtain both grafts is longer than that spent using the pedicled method. Perhaps, with the use of ultrasonic cauterization, this time can be greatly reduced. With the utilization of conventional cauterization, much care is necessary not to excessively expose the thoracic artery to the heat irradiated by this device, which may cause hematomas, spasms and irreversible lesions. During the reviewing of the thoracic wall, electrocauterization should also be utilized with much care, as there is a risk of injuring the satellite veins and all the effort to preserve part of the vascularization of the thoracic wall will be lost.

## CONCLUSION

In conclusion, the data attained in our study suggest that the bilateral use of skeletonized ITAs offers a certain degree of protection against mediastinitis in diabetic

patients, especially those who are insulin dependent. The time spent for dissection of both arteries is greater when the skeletonization technique is used however this is compensated by less time spent on reviewing the hemostasis of the thoracic wall. After starting to use the skeletonized LITA, we became much more liberal in the utilization of both ITAs in diabetic patients.

#### REFERENCES

1. Gall S Jr, Lowe JE, Wolfe WG, Oldham HN Jr, Van Trigt P 3rd, Glower DD. Efficacy of the internal mammary artery in combined aortic valve replacement-coronary artery bypass grafting. *Ann Thorac Surg.* 2000;69(2):524-30.
2. Henessy TG, Codd MB, Donnelly S, Hartigan C, McCann HA, McCarthy C, et al. Long-term clinical outcome following coronary artery bypass grafting for isolated stenosis of the left anterior descending coronary artery. *Eur Heart J.* 1998;19(3):447-57.
3. Wang AY, Bobryshev YV, Cherian SM, Liang H, Inder SJ, Lord RS, et al. Structural features of cell death in atherosclerotic lesions affecting long-term aortocoronary saphenous vein bypass grafts. *J Submicrosc Cytol Pathol.* 1999;31(3):423-32.
4. Lytle BW, Loop FD. Superiority of bilateral internal thoracic artery grafting: it's been a long time comin'. *Circulation.* 2001;104(18):2152-4.
5. Rizzoli G, Schiavon L, Bellini P. Does the use of bilateral internal mammary artery (IMA) grafts provide incremental benefit relative to the use of a single IMA graft? A meta-analysis approach. *Eur J Cardiothorac Surg.* 2002;22(5):781-6.
6. Cosgrove DM, Lytle BW, Loop FD, Taylor PC, Stewart RW, Gill CC, et al. Does bilateral internal mammary artery grafting increase surgical risk? *J Thorac Cardiovasc Surg.* 1988;95(5):850-6.
7. Kouchoukos NT, Wareing TH, Murphy SF, Pelate C, Marshall WG Jr. Risks of bilateral internal mammary artery bypass grafting. *Ann Thorac Surg.* 1980;49(2):210-7.
8. Taggart DP, D'Amico R, Altman DG. Effect of arterial revascularisation on survival: a systematic review of studies comparing bilateral and single internal mammary arteries. *Lancet.* 2001;358(9285):870-5.
9. Galbut DL, Traad EA, Dorman MJ, DeWitt PL, Larsen PB, Kurlansky PA, et al. Seventeen-year experience with bilateral internal mammary artery grafts. *Ann Thorac Surg.* 1990;49(2):195-201.
10. Higami T, Kozawa S, Asada T, Shida T, Ogawa K. Skeletonization and harvest of the internal thoracic artery with an ultrasonic scalpel. *Ann Thorac Surg.* 2000;70(1):307-8.
11. Milani RM. Análise dos resultados imediatos para operação de revascularização do miocárdio sem pinçamento total da aorta [Tese de Mestrado] Curitiba:Universidade Federal do Paraná;2000.
12. Lima RC. Padronização técnica de revascularização miocárdica da artéria circunflexa e seus ramos sem circulação extracorpórea [Tese de Doutorado]. São Paulo:Universidade Federal de São Paulo, Escola Paulista de Medicina;1999.
13. Loop FD, Lytle BW, Cosgrove DM, Stewart RW, Goormastic M, Williams GW, et al. Influence of the internal-mammary-artery graft on 10-year survival and other cardiac events. *N Engl J Med.* 1986;314(1):1-6.
14. Cameron A, Davis KB, Green G, Schaff HV. Coronary bypass surgery with internal-thoracic-artery grafts--effects on survival over a 15-year period. *N Engl J Med.* 1996;334(4):216-9.
15. Lytle BW, Loop FD, Cosgrove DM, Ratliff NB, Easley K, Taylor PC. Long-term (5 to 12 years) serial studies of internal mammary artery and saphenous vein coronary bypass grafts. *J Thorac Cardiovasc Surg.* 1985;89(2):248-58.
16. Calafiori AM, Vitolla G, Iaco AL, Fino C, Di Giammarco G, Marchesani F, et al. Bilateral internal mammary artery grafting: midterm results of pedicled versus skeletonized conduits. *Ann Thorac Surg.* 1999;67(6):1637-42.
17. Menezes AM, Vasconcelos FP, Lima RC, Costa MG, Escobar MAS. Aspectos técnicos na esqueletização da artéria torácica interna com bisturi ultra-sônico. *Rev Bras Cir Cardiovasc.* 2007;22(2):206-11.
18. De Paulis R, Notaris S, Scaffa R, Nardella S, Zeitani J, Del

- Giudice C, et al. The effect of bilateral internal thoracic artery harvesting on superficial and deep sternal infection: The role of skeletonization. *J Thorac Cardiovasc Surg.* 2005;129(3):536-43.
19. Peterson MD, Borger MA, Rao V, Peniston CM, Feindel C. Skeletonization of bilateral internal thoracic artery grafts lowers the risk of sternal infection in patients with diabetes. *J Thorac Cardiovasc Surg.* 2003;126(5):1314-9.
20. Hirose H, Amano A, Takanashi S, Takahashi A. Skeletonized bilateral internal mammary artery grafting for patients with diabetes. *Interact Cardiovasc Thorac Surg.* 2003;2(3):287-92.
21. Miana LA, Lima DS, Whitaker JF, Passos PHC, Loures PL, Miana AA. Resultados imediatos da artéria torácica interna direita e artéria radial como segundo enxerto arterial na revascularização do miocárdio. *Rev Bras Cir Cardiovasc.* 2007;22(1):60-7.
22. Martins SK, Santos MA, Tirado FHP, Martins Jr FCE, Malat HF, Jatene AD, et al. Revascularização do miocárdio com emprego de ambas as artérias mamárias internas em pacientes diabéticos. *Rev Bras Cir Cardiovasc.* 2007;22(3):291-6.