

# New technology: valve repair using biodegradable rings

*Nova tecnologia: valvuloplastias com anéis biodegradáveis*

Rodolfo NEIROTTI<sup>1</sup>, Mustafa CIKIRIKCIOGLU<sup>2</sup>, Alberto DELLA MARTINA<sup>3</sup>, Philippe LE GOFF<sup>4</sup>, Afksendiyos KALANGOS<sup>5</sup>

RBCCV 44205-1032

## Abstract

**Objective:** To introduce a new concept in the annuloplasty technology. Although rigid and flexible rings meet the basic needs of adults, they do not preserve the changes in shape and size occurring during the cardiac cycle. If implanted in children, such materials do not allow growth of the native annulus.

**Methods:** From March 2003 to March 2007, 207 patients underwent mitral and/or tricuspid valve repair implanting polidioxanone biodegradable rings - Bioring®. Patients were divided into two groups: Group 1, Adults: n=121. Mean age: 48 years (+- 19.2). Oldest 85 years. Group 2, Pediatric: n=86. Mean age: 9.6 years (+- 4.4). Youngest 0.5 years.

**Results:** Group 1, Hospital mortality: 3.3%. Mean follow-up: 26.4 months ± 15.4. Four patients underwent mitral valve replacement 1, 2, 2 and 4 months post repair. Group 2, Hospital mortality: 1.2%. Mean follow-up: 26.7 months ± 13.4. Seven mitral reoperations within 1 to 24 months, 2 for valve re-repair, 5 for valve replacement.

**Conclusions:** Biodegradable rings remodel the shape, reinforce the repair, restore the function of the atrioventricular valves and maintain the three dimensional dynamic motion and geometry of the mitral and tricuspid valves annulus. Growth potential is preserved in children. Although the biodegradable annuloplasty ring was first designed and developed for a pediatric population, it is currently applied to adult cases. Children with single ventricle and AV valve incompetence are an additional indication. The mid-term results showed that degradation of the device occurred without negative observable

consequences. Long-term results should confirm these findings.

**Descriptors:** Heart valves. Absorbable implants. Heart valve prosthesis Mitral valve/surgery. Tricuspid valve/surgery.

## Resumo

**Objetivo:** Introduzir um novo conceito na tecnologia de anuloplastia. Embora anéis rígidos e flexíveis cumpram com as necessidades básicas em adultos, não preservam mudanças na forma e no tamanho ocorridos durante o ciclo cardíaco. Se implantado em crianças, eles não permitem o crescimento do anel nativo.

**Métodos:** De março de 2003 a março de 2007, 207 pacientes submeteram-se ao reparo da valva mitral e/ou tricúspide implantando anéis biodegradáveis de polidioxanona Bioring®. Pacientes foram separados em dois grupos: Grupo 1, Adultos n=121. Idade média: 48 anos (± 19,2). Mais velho 85 anos. Grupo 2, Pediátrico: n=86. Idade média: 9,6 anos (± 4,4). Mais novo 0,5 anos.

**Resultados:** Grupo 1 - mortalidade hospitalar: 3,3%; seguimento médio: 26,4 meses ± 15,4. Quatro pacientes submetidos à substituição da valva mitral 1,2,2 e 4 meses pós-reparo. Grupo 2 - mortalidade hospitalar: 1,2%; seguimento médio: 26,7 meses, ± 13,4. Sete reoperações mitrales entre 1 a 24 meses, duas para novo reparo da válvula, cinco para substituição valvar.

**Conclusões:** Anéis biodegradáveis remodelam a forma, reforçam o reparo, devolvem a função das valvas

1. MD, PhD, Clinical Professor of Surgery and Pediatric. Michigan State University. Master in Public Administration, Harvard University. Honorary member Brazilian Society of Cardiovascular surgery; Consultant Cardiovascular Surgeon, University Hospital of Geneva, Switzerland. Scientific Consultant, Bioring SA, Lonay, Switzerland.
2. MD, PhD; Cardiac Surgeon, University Hospital of Geneva, Switzerland.
3. PhD; R & D Scientist, Bioring SA, Lonay, Switzerland.
4. PhD; Chief Technology Officer, Bioring SA, Lonay, Switzerland.
5. Professor MD, PhD, Chief of the Department of Cardiovascular Surgery, University Hospital of Geneva, Switzerland.

This study was carried out at the Department of Cardiovascular Surgery. University Hospital of Geneva, 24, rue Micheli du Crest 1211. Genebra, Suíça.

Correspondence address:

Rodolfo Neirotti MD. Residence de la Cote 60. Morges CH 1110. Switzerland.

E-mail: RA\_Neirotti@ksg06.harvard.edu

Article received on July 4<sup>th</sup>, 2008  
Article accepted on October 21<sup>st</sup>, 2008

atrioventriculares, mantendo a dinâmica tridimensional e geometria dos anéis valvares mitrais e tricuspídeos. Além disso, estes anéis preservam o crescimento potencial em crianças. Embora o anel de anuloplastia biodegradável tenha sido inicialmente desenvolvido para população pediátrica, é atualmente aplicado em adultos. Crianças com ventrículo-único e incompetências valvares A-V são indicações adicionais.

Resultados a médio prazo mostraram que a degradação do produto ocorreu sem consequências negativas observáveis. Resultados a longo termo deverão comprovar estes achados.

**Descritores:** Valvas cardíacas. Implantes absorvíveis. Próteses valvulares cardíacas. Valva mitral/cirurgia. Valva tricúspide/cirurgia.

INTRODUCTION

Biotechnology has made significant contributions to medicine and surgery in general and to cardiac surgery in particular. To develop the biodegradable rings, it was necessary to adjust the degradation time by hydrolysis of polydioxanone, a biocompatible polymer. Polydioxanone, like many biodegradable polymers, is a polyester. Ester is a bond with polar nature-less stable-hence more reactive that can be broken down by hydrolysis. Hydrolysis of the ester bond results in formation of an alcohol and an acid, (2-Hydroxyethoxy) acetic acid [1]. The latter, triggers an inflammation inducing the formation of fibrous tissue [2,3].

The use of biodegradable rings is a new concept in the evolving annuloplasty technology- from the rigid ring to the biodegradable one. While rigid and flexible rings meet the needs of adults, they do not allow growth of the native annulus in children. Biodegradable rings induce fibrous tissue with structural function which preserves the growth potential of the annulus in the pediatric population maintaining the three- dimensional dynamic geometry of the mitral and tricuspid valves. The mitral orifice undergoes striking changes in its size and shape during different parts of the cardiac cycle [4]. The annulus changes its shape both in the horizontal plane and in the vertical plane, where it changes from a saddle shape to a more flat structure [5]. Preserving them can improve the result and durability of the repair [4].

Although the biodegradable annuloplasty ring was first designed and developed for a pediatric population, it is currently applied to adult cases as well.

METHODS

From March 2003 to March 2007, 207 patients underwent mitral and/or tricuspid valve repair implanting 222 biodegradable rings (Kalangos' ring, Bioring®, Lonay, Switzerland). Patients were divided in two groups: Group 1, (Adults, n=121). Mean age: 48 years ( $\pm$  19.2). Oldest 85 years. Group 2, (Pediatric,  $\leq$  16, n=86). Mean age: 9.6 years ( $\pm$  4.4). Youngest 0.5 years (Table 1). The preoperative functional status for the adult and pediatric population is

Table 1. Distribution of the atrioventricular valves requiring repair

Group	Patients n=207	Mean age	Mitral	Tricuspid	Both
I Adults	121	48 years ( $\pm$ 19.2) Oldest: 85 years	91	19	11
II Pediatric	86	9.6 years ( $\pm$ 4.4) Youngest: 5 months	57	23	6

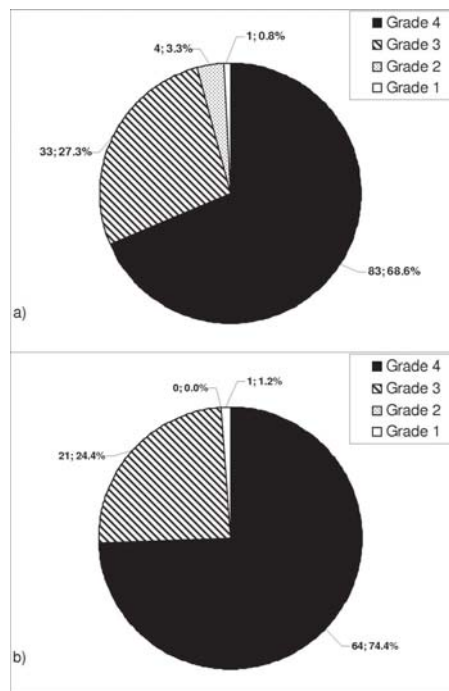
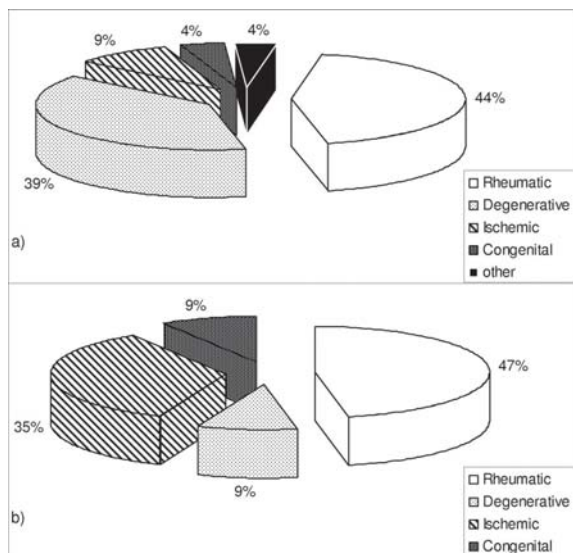


Fig. 1 - A) Chart showing the preoperative the New York Heart Association functional class (NYHA) of the Adult population. B) Table showing the preoperative New York Heart Association functional class (NYHA) of the pediatric population

disclosed in Figures 1A and 1B, respectively. The etiology of the mitral valve pathology in the adult and the pediatric population is shown on Figures 2A and 2B.



**Fig. 2 - A)** Chart disclosing the mitral valve pathologies in the adult population. **B)** Table showing the mitral valve pathologies in the pediatric population

In both groups, the repair was evaluated in surgery by trans-esophageal echocardiography and after discharge by trans-thoracic echocardiography.

The mitral and tricuspid models include a re-absorbable polymeric 'C' curved segment of a poly-1,4-dioxanone polymer, prolonged by a 2/0 monofilament polyvinylidene fluoride (PVDF) suture-in continuity over the entire biodegradable ring-with a swaged stainless steel needle in each end. The specific molecular weight of the ring provides a structural memory that protects it from subsequent deformity.

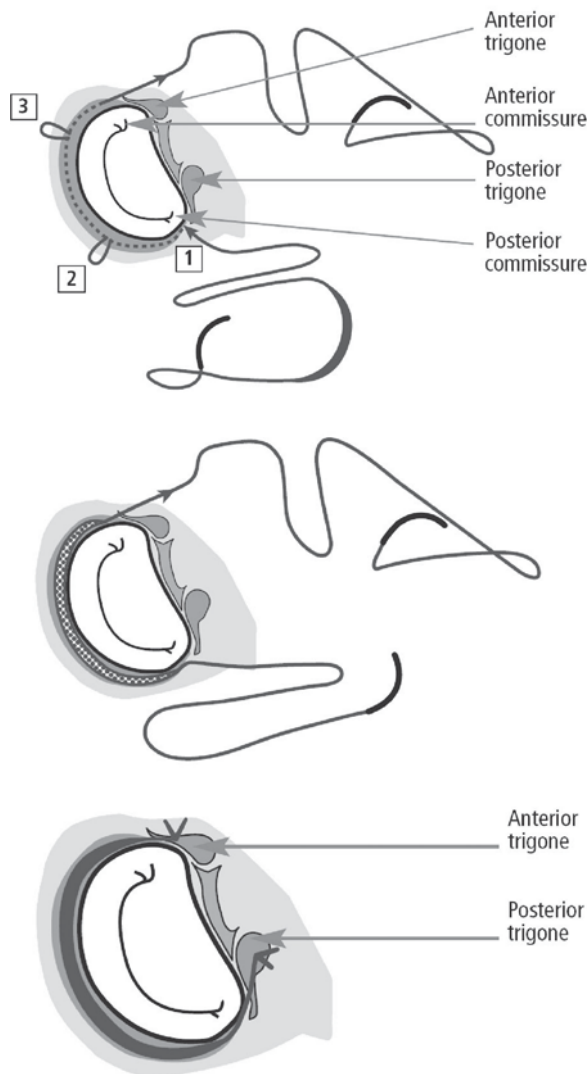
**Operative technique for the mitral implantation** (Figure 3)

The anterior leaflet of the mitral valve was unfurled and the ring was chosen according to the sizer that matched the leaflet's surface area.

The sub-endocardial insertion started at the level of the posterior commissure, 2 mm away from the hinge point and 3 mm in depth, *taking always the same exit point* to move forward around the posterior annulus.

The implantation was completed by fixation of the extremities to the anterior and posterior trigones, respectively. Altogether, the time of implantation and ischemia was significantly shorter than with the traditional rings. This was particularly important in complex valve repairs or in concomitant procedures.

Alternative technique: the suture extensions were tied in the middle of the anterior annulus when this segment is dilated in: Ischemic mitral insufficiency; Barlow disease (5%); Idiopathic cardiomyopathy.



**Fig. 3 -** Showing of technique for mitral annuloplasty with subendocardial insertion of a mitral biodegradable ring

**Operative Technique for the Tricuspid Implantation** (Figure 4)

- The anterior leaflet of the tricuspid valve was sized to select the appropriate ring;
- With the heart beating, the sub-endocardial insertion started at the level of the postero-septal commissure, with the shortest end of the ring, 2 mm away from the hinge point and 3 mm in depth, *taking always the same exit point* to move forward around the anterior annulus;
- The implantation was completed by fixation of the anterior and the posterior extremities, respectively;
- Careful attention was paid to rhythm changes due to the vicinity of the sinus node to the posterior fixation point.

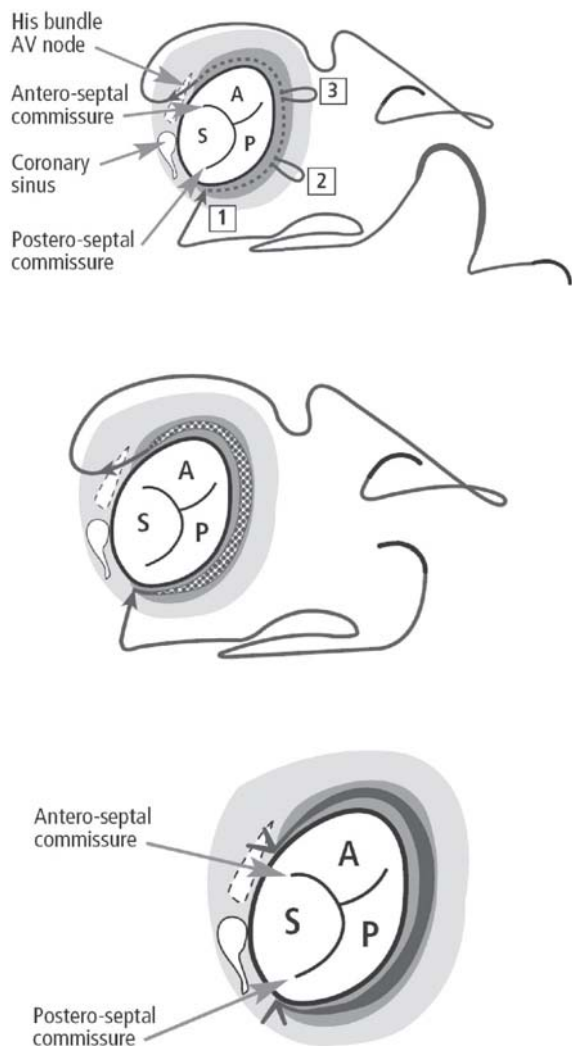


Fig. 4 - Surgical technique for tricuspid annuloplasty with subendocardial insertion of a tricuspid biodegradable ring

RESULTS

Group 1 (Adults n= 121)

Hospital mortality (four patients) was 3.3%. Mean follow-up was 26.4 months ± 15.4. The surgical techniques for both valves were: annuloplasty + repair in 113; ring alone in 18. Concomitant procedures: five patients had an aortic valve replacement and 17 a Maze operation. Intra-operative trans-esophageal echocardiography showed no regurgitation in 71 patients, trivial incompetence in 37 and mild regurgitation in 13. The mean mitral gradient was 2.9 ± 3.1 mmHg. Re-operations: four patients underwent mitral valve replacement 1, 2, 2 and 4 months post repair. There

was one late death, 2 months after operation, due to gastrointestinal bleeding (Figure 5A).

Group 2 (Pediatric n= 86)

Hospital mortality (one patient) was 1.2%. Mean follow-up was 26.7 months ± 13.4. The surgical techniques for both valves were: Annuloplasty + repair 77 cases; ring alone in nine patients. Concomitant procedures: aortic valve repair (n=5); repair of congenital cardiac anomalies (n=15). Intra-operative trans-esophageal echocardiography showed no regurgitation in 47 cases; there was trivial incompetence in 24 patients and mild reflux in 15. The mean mitral gradient was 2.7 ± 2.7 mmHg. Seven patients required re-operation within 1 to 24 months, two for mitral valve re-repair and five for mitral valve replacement (Figure 5B).

In both groups, the incidence of rheumatic valve disease was higher than expected due to the inclusion of patients referred from developing countries.

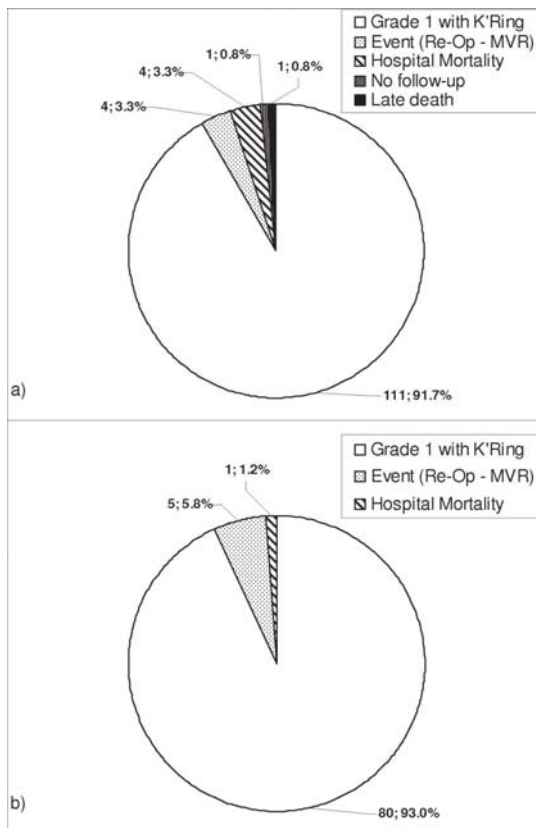


Fig 5 - A) Showing of postoperative outcomes in the adult group. K'Ring : Kalangos' ring; Re-op: reoperations; MVR: mitral valve replacement. There was one late death, 2 months after surgery, due to gastrointestinal bleeding. B) Showing of the postoperative outcomes in the pediatric population. K'Ring: Kalangos' ring. Re-op: reoperations; MVR: mitral valve replacement. Among the 7 patients that required reoperations, 2 continue with a ring. MVR: mitral valve replacement

## DISCUSSION

The good functioning of the native or repaired heart valve depends on the coaptation capacity of its leaflets. Annuloplasty rings are artificial prosthesis sutured to the native mitral or tricuspid valve annulus that have been used since 1968, to remodel the shape, correct the dilatation and consolidate the repair of the valve and improve coaptation of the valves leaflets during systole [6]. In systole, in the normal mitral valve, the transverse diameter is longer than the anteroposterior diameter. When the annulus is dilated, the transverse diameter is shorter than the anteroposterior diameter. The dilatation affects mainly both commissures and the posterior segment. The use of incomplete 'C'-curved rings to remodel the dilated segment is based on this concept.

A better understanding of the three-dimensional geometry and the dynamic of the native valve annulus during the normal cardiac cycle lead to the evolution of the rings from the first rigid planar stainless steel-based Carpentier's ring to the flexible Duran ring and to the more recent Cosgrove-Edwards bands. While these conventional devices respond to the needs of the adult population, they do not allow for the further growth of the native annulus-an important issue for the long term results if implanted in children. Indeed, their implantation in growing hearts could result in a stenotic effect which could worsen with time.

These considerations were the driving force for the development of a new concept in annuloplasty valve repair-a device that allows for growth of the native annulus. Encouraging results were reported in annuloplasties, performed mainly in the pediatric population, using different techniques and different biodegradable materials [7-10]. However, even though those trials were based on a good rational approach and gave promising results, techniques required some degree of craftsmanship and therefore were less predictable. For this reason, it was decided to develop a biodegradable ring that was not only applicable to the pediatric population but also easier to implant than the available devices.

The following characteristics of biodegradable implants were considered:

- Promote/accelerate body self-repair;
- Provide a gradual transition to regain a normal organ function;
- Do not interfere with organ growth in children;
- No need for operations to remove them;
- Low risk of infection.

The biodegradable ring is also a partial ring with a 'C' curved shape that allows a homogeneous remodeling of the dilated annular segments using different pre-designed sizes.

An experimental animal trial was conducted to assess the histo-biocompatibility of the biodegradable ring and

orifice area growth in a porcine model. The smallest (size 16) biodegradable ring was implanted into the tricuspid annulus of 16 juvenile pigs (30 kg - 43 kg). Transthoracic echocardiography controls performed at monthly intervals showed no signs of tricuspid valve dysfunction, a preserved ventricular contractility, and physiological growth of the tricuspid valve orifice without significant transvalvular gradients. This was confirmed by macroscopic measurements of the valve orifices on the sacrificed pigs which had increased their body weights from 30-43 to 190-200 Kg (average of more than 500%) over a year. Histological sections in all dissected hearts, at different time points after surgery, showed that a fibrous autologous tissue was developed in replacement of the implanted polydioxanone device, reabsorbed by hydrolysis, six months or more following implantation. Moreover, it was found that the fibrous tissue continues to growing for a few months after complete re-absorption of the device [11].

In addition, in a series of 20 patients operated on between 1994 and 2003-mean follow-up of 62 + months- who had mitral valve repair implanting biodegradable rings that were smaller than the commercially available ring sizes (<26), there were no evidence of mitral stenosis [12]. The newly grown fibrous tissue remodels the annulus, prevents further stretching preserving its physiological dynamical motion without interfering with growth [13].

Biodegradable rings are new solutions and undoubtedly contribute to today's emerging advances in annuloplasty technology [11].

A recent retrospective echo-cardiographic study performed in our institution in 213 patients-Carpentier's rings (n=173); biodegradable rings (n=40)-showed that when compared with rigid rings, biodegradable rings have:

1. less gradient, measured at 3 months, 6 months and 1 year. While the rigid showed a steady increase the biodegradable increase was significantly lower;
2. better posterior leaflet mobility: it was significantly decreased in the rigids and only mildly reduced in the biodegradable;
3. faster recovery of the shortening fraction after surgery. It was initially reduced in both but the recovery to preoperative values was 3 months for the rigids and 3 weeks for the biodegradable;

Altogether, when compared with rigid rings, biodegradable rings have less gradient, better posterior leaflet mobility and faster recovery of the shortening fraction after surgery-important features for the short, medium and long term results of valve repairs [14].

Persistence and progression of tricuspid valve incompetence after the repair of functional mitral regurgitation and the significant risk associated with re-operation has triggered the interest on a more aggressive policy of performing a tricuspid annuloplasty at the time of

the initial mitral valve surgery [15]. Because considerable tricuspid dilatation can be present even in the absence of substantial tricuspid regurgitation, surgical repair of the tricuspid valve based on tricuspid dilatation rather than regurgitation-if the tricuspid annular diameter is greater than twice the normal size-can lead to potential benefits [16]. The short time of implantation and ischemia required for the biodegradable rings, make them attractive in cases needing repair of both valves and/or concomitant procedures.

There is an increasing trend to recommends early surgery for patients with mitral valve regurgitation. This approach is justified only in patients undergoing repair by surgeons who routinely perform mitral valves repair, no replacement. Because the number of patients currently undergoing valve repair is not sufficient, there is a need to train more surgeons capable to repair valves [17].

Atrioventricular valve repair with this new technology is feasible with good early and mid term results. Its intra-annular implantation prevents the device from coming into contact with blood, thus avoiding thromboembolic complications and systemic anticoagulation therapy unlike the traditional rings-sutured on the native annulus-until they are covered with tissue. It also diminishes the risk of infection if used in the presence of infective endocarditis [18].

Altogether, biodegradable rings enhance the well known benefits of valve repair and improve the access to these procedures because of its use in the pediatric population.

#### REFERENCES

1. Sabino MA, González S, Márquez L, Feijoo JL. Study of the hydrolytic degradation of polydioxanone PPDx. *Polymer Degradation and Stability*. 2000;69(2):209-16.
2. Lickorish D, Chan J, Song J, Davies JE. An in-vivo model to interrogate the transition from acute to chronic inflammation. *Eur Cell Mater*. 2004;8:12-20.
3. Agrawal CM, Athanasiou KA. Technique to control pH in vicinity of biodegrading PLA-PGA implants. *J Biomed Mater Res*. 1997;38(2):105-14.
4. Salgo IS, Gorman JH 3rd, Gorman RC, Jackson BM, Bowen FW, Plappert T, et al. Effect of annular shape and leaflet curvature in reducing leaflet stress. *Circulation*. 2002;106(6):711-7.
5. Yacoub MH, Cohn LH. Novel approaches to cardiac valve repair: from structure to function: Part I. *Circulation*. 2004;109(8):942-50.
6. Carpentier A. Cardiac valve surgery: the "French Correction" *J Thorac Cardiovasc Surg*. 1983;86(3):323-37.
7. Durán CM, Revuelta JM, Val Bernal F. A new absorbable annuloplasty ring in the tricuspid position: an experimental study. *Thorac Cardiovasc Surg*. 1986;34(6):377-9.
8. Chachques JC, Acar C, Latremouille C, Fontaliran F, Mihaileanu S, Chauvaud S, et al. Absorbable rings for pediatric valvuloplasty: preliminary study. *Circulation*. 1990;82(5 Suppl):IV82-8.
9. Duran CM, Balasundaram SG, Bianchi S, Herdson P. The vanishing tricuspid valvuloplasty: a new concept. *J Thorac Cardiovasc Surg*. 1992;104(3):796-801.
10. Miyamura H, Eguchi S, Watanabe H, Kanazawa H, Sugawara M, Tatebe S, et al. Total circular annuloplasty with absorbable suture for the repair of the atrioventricular valve regurgitation in atrioventricular septal defect. *J Thorac Cardiovasc Surg*. 1994;107(6):1428-31.
11. Kalangos A, Sierra J, Vala D, Cikirikcioglu M, Walpoth B, Orrit X, et al. Annuloplasty for valve repair with a new biodegradable ring: an experimental study. *J Heart Valve Dis*. 2006;15(6):783-90.
12. Kalangos A, Beghetti M, Sierra J, Christenson JT. Repair of congenital mitral insufficiency in infant and children mid to long term results. In: *EACTS/ESTS Joint Meeting*;2003;Vienna,Austria.
13. Salleh A, Wong, Dimon Z, Joshi P. Dynamic changes of mitral annulus post-implantation of Kalangos' biodegradable annuloplasty rings. In: *9th Annual Meeting, Malaysian Association for Thoracic and Cardiovascular Surgery*. Langkawi;2006;Malaysia.
14. Kalangos A, Christenson JT, Beghetti M, Cikirikcioglu M, Kamentsidis D, Aggoun Y. Mitral valve repair for rheumatic valve disease in children: midterm results and impact of the use of a biodegradable mitral ring. *Ann Thorac Surg*. 2008;86(1):161-9.
15. Antunes M. Late occurring tricuspid regurgitation. The forgotten valve-tricuspid valve disease. Postgraduate course. *Adult Cardiac Surgery*. In: *21st Annual Meeting of the European Association Cardiothoracic Surgery*;2007;Geneva, Switzerland.
16. Dreyfus GD, Corbi PJ, Chan KM, Bahrami T. Secondary tricuspid regurgitation or dilatation: which should be the criteria for surgical repair? *Ann Thorac Surg*. 2005;79(1):127-32.
17. Sarano M. When to treat asymptomatic mitral regurgitation. Session: Mitral valve surgery. Techno College. In: *21st European Association for CardioThoracic Surgery*;2007;Geneva, Switzerland.
18. Kazaz H, Celkan MA, Ustunsoy H, Baspinar O. Mitral annuloplasty with biodegradable ring for infective endocarditis: a new tool for the surgeon for valve repair in childhood. *Interact Cardiovasc Thorac Surg*. 2005;4(4):378-80.