

Tratamento cirúrgico de rabdomiosarcoma primário do coração

Surgical treatment of primary cardiac rhabdomyosarcoma

Ricardo de Carvalho LIMA¹, Adriano MENDES², Elson BEZERRA³, Wilson OLIVEIRA⁴

RBCCV 44205-1083

Resumo

Os autores reportam caso de jovem de 16 anos, o qual apresentou dispnéia progressiva. No momento do atendimento foi feito diagnóstico de febre reumática com comprometimento da valva mitral. Ecocardiograma bidimensional demonstrou a presença de massa móvel dentro do átrio esquerdo. O tumor apresentava lobos, se projetando para o interior do ventrículo esquerdo durante a diástole, provocando turbulência. O paciente foi submetido a ressecção cirúrgica, complicada com reoperação e troca valvar mitral. A histopatologia demonstrou tratar-se de rabdomiosarcoma primário e o diagnóstico clínico diferencial com febre reumática e doença valvar mitral foi muito difícil desde o seu início.

Descritores: Neoplasias. Valvas cardíacas. Valva mitral.

Abstract

The authors report a case of a 16-year-old man who presented progressive dyspnea. At that time the diagnosis of rheumatic fever with mitral valve involvement was performed. The bidimensional echocardiogram showed presence of mobile mass inside the left atrium. The tumor presented lobules, projecting into the left ventricle during the diastole and provoking turbulence. The patient underwent surgical resection with postoperative course needing re-operation for mitral valve replacement. Histopathology has proven that such tumor was a primary cardiac rhabdomyosarcoma and the early clinical diagnosis of rheumatic mitral valve disease was very difficult.

Descriptors: Neoplasms. Heart valves. Mitral valve.

INTRODUCTION

The incidence of primary tumors of the heart in autopsy series ranges from 0.0017 to 0.28 per cent and about one-fourth of all cardiac tumors exhibit typically malignant histological characteristics and invasive behavior [1]. Malign tumors in cardiac valves are rare and have been reported in the literature as representing only 10% of primary tumors [2]. Usually the diagnosis is atrial myxoma

because the methods of diagnosis do not identify the histological aspect [3,4]. Rhabdomyosarcoma is a malignant tumor of mesenchymal origin which often diffusely infiltrates the myocardium but which may also, on occasion, form a polypoid extension into the cardiac chambers and therefore have been clinically mistaken for myxoma. Left atrium tumors generally present signs and symptoms suggestive of mitral stenosis, but congestive heart failure with a poor prognosis may be present [5-7].

1. Professor Titular da UPE. Chefe da Divisão Cirúrgica do PROCAPE.
2. Mestre em Cardiologia pela Faculdade de Ciências Médicas – UPE. Cardiologista do PROCAPE.
3. Especialista em Cardiologista. Cardiologista do PROCAPE.
4. Mestre em Doenças Tropicais. Professor de Cardiologia da Faculdade de Ciências Médicas – UPE.

Endereço para correspondência:
Ricardo C. Lima
Rua Arnóbio Marques, 310 - Santo Amaro – Recife, PE, Brasil - CEP 50100-130.
E-mail: rclima@elogica.com.br

Trabalho realizado na Faculdade de Ciências Médicas, Hospital Universitário Oswaldo Cruz, Universidade de Pernambuco, Recife, PE, Brasil.

Artigo recebido em 18 de junho de 2008
Artigo aprovado em 23 de janeiro de 2009

Here we report a young man who presented with increasing dyspnea, palpitation, and edema of the lower limbs, who was found to have a rhabdomyosarcoma in the mitral valve.

CASE REPORT

A 16-year-old male, previously otherwise healthy, was admitted with a history of palpitation, progressive dyspnea on minimal effort, edema of lower limbs, fever and anemia. At physical examination the patient was not short of breath, had no cyanosis or high jugular venous pulse. Arterial pressure was 90 x 70 mmHg, gallop cardiac rhythm and heart rate of 140 beats per minute. Cardiac auscultation showed diastolic and systolic murmurs in the mitral area, systolic murmurs in the aortic focus and hyperphonic P2. On the frontal view of the radiograph a cardiac enlargement could be seen with a double contour on the right-hand side. At that moment a rheumatic mitral regurgitation was detected and a diagnosis of stenosis made.

The two-dimensional echocardiography test showed left atrium enlargement and a normal left ventricle, a normal aorta and an ejection fraction of 67%. There was a huge mobile lobulated mass in the left atrium adhering to the anterior wall of the atrial septum measuring 3 cm x 4 cm, projecting to the left ventricle during diastole, provoking a turbulent flow and a gradient of 14 mmHg. The right atrium was enlarged with a normal right ventricle and pulmonary pressure of 65 mmHg. The diagnosis was made suggesting left atrium myxoma (Figure 1).

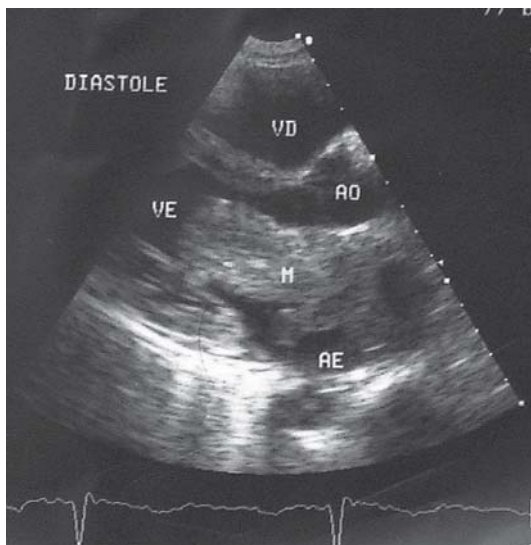


Fig. 1 - Two dimensional echocardiogram test during diastole showing the tumor projecting into the left ventricle. Ao = aorta; VD = right ventricle; VE = left ventricle; M = tumor mass; AE = left atrium

At the operation, a tumor was found in the left atrium with extensive infiltration into the atrial septum and adhesion of the anterior leaflet of mitral valve, which was slightly thickened. The tumor was resected together with part of the atrial septum and the anterior mitral leaflet was preserved (Figure 2). The atrial septum was reconstructed with bovine pericardium and the mitral valve repaired.

In the immediate postoperative period, the patient presented severe mitral regurgitation with arterial hypotension, renal insufficiency and a sudden cardiac arrest. He was submitted a new operation and the mitral valve was replaced using a porcine valve. After the second operation the patient presented brain damage and died after three months of follow-up.

The histological examination and immunohistochemistry showed a diagnosis of rhabdomyosarcoma.

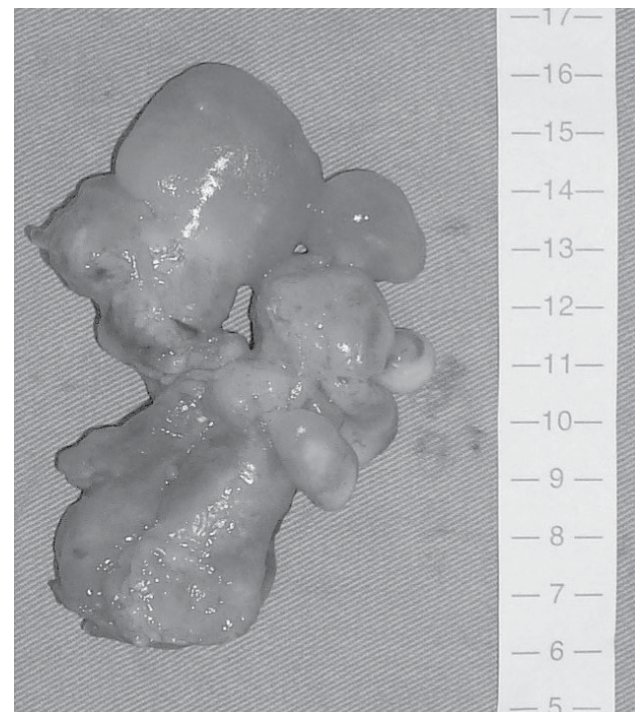


Fig. 2 - The gelatinous surgical aspect of the tumor excised was very similar to the atrial myxoma

DISCUSSION

The majority of cardiac tumors are primary and benign. Myxomas of the left atrium are the ones most frequently encountered and the treatment usually presents good results. On the other hand, primary malignant tumors do not present good results after surgical treatment and are very rarely recognized preoperatively [5]. Sarcomas are more frequently located on the right-hand side of the heart and

their incidence ranges from 2% to 5% of all malignant tumors [8]. The symptoms depend on the degree of cardiac obstruction, such as valvar obstruction, arrhythmias, pericardium effusion with cardiac tamponing, systemic embolization and systemic symptoms. In the present case the tumor was located in the septal atrium and involved the mitral valve and the patient presented embolization to the brain.

About 75% of all patients with cardiac sarcomas have pathological evidence of distant metastases at the time of death. The most frequent sites of metastases are the lungs, brain, thoracic lymph nodes, mediastinum and, less often, the liver, kidneys, adrenals, pancreas, bone, spleen and bowel. During the operation a coronary fistula to the pericardium and also to the peritoneum was observed, resulting in death. No metastases or fistulas were observed in the patient [8].

The diagnosis is usually easily made by means of a transthoracic and transesophageal echocardiogram [5]. Magnetic nuclear resonance (MNR) is useful to determine the localization of the tumor and the extent of metastases to the thorax and abdomen. In the present case MNR was not performed owing to the seriousness of the patient's condition during hospitalization. The immunohistochemistry test was necessary to make the differential diagnosis with pseudoinflammatory tumors or sarcoma. These are tumors of striated muscle which most often diffusely infiltrate into the myocardium, but which may also, on occasion, form a polypoid extension into the cardiac chamber and have therefore been clinically mistaken for myxoma. The polypoid appearance during the operation in this case initially suggested a myxoma tumor. The resection should be performed, due to the infiltrative nature of the tumor; this approach, however, does not change the unfavorable prognosis. The prognosis is poor and mean survival is five months after the resection as a result of local recidivation or metastases [8]. Radiotherapy and

chemotherapy adjuvants or a heart transplant do not improve survival.

The differential diagnosis is still difficult in a country where rheumatic fever is present because patients with this cardiac tumor can be mistaken for ones with a rheumatic mitral valve. The result observed in this case was comparable with other cases described in the literature.

REFERENCES

1. Pezzella AT. Primary cardiac tumors. *Ann Thorac Surg.* 1996;61(3):1041-2.
2. Edwards FH, Hale D, Cohen A, Thompson L, Pezzella AT, Virmani R. Primary cardiac valve tumors. *Ann Thorac Surg.* 1991;52(5):1127-31.
3. Kuroda H, Nitta K, Ashida Y, Hara Y, Ishiguro S, Mori T. Right atrial myxoma originating from the tricuspid valve. *J Thorac Cardiovasc Surg.* 1995;109(6):1249-50.
4. Lima RC, Moraes CR, Arruda MB, Lagreca JR, Escobar M, Raposo L, et al. Mixoma do átrio direito. *Rev Bras Cir.* 1977;67(5/6):161-4.
5. Huang Z, Sun L, Du M, Ruan Y, Wang H. Primary cardiac valve tumors: early and late results of surgical treatment in 10 patients. *Ann Thorac Surg.* 2003;76(5):1609-13.
6. Dralle JG, Jain D, Sundram P, Replogle RL. Cardiac valvular chondroma. *Ann Thorac Surg.* 1994;58(5):1540-2.
7. Shahian DM, Labib SB, Chang G. Cardiac papillary fibroelastoma. *Ann Thorac Surg.* 1995;59(2):538-41.
8. Hauser C, Guelpa G, Lopez JL, Janzer RC, Chaubert P, Baumann RP. Cardiac fibrosarcoma discovered by cerebral metastases. *Rev Med Suisse Romande.* 1999;119(10):833-7.