

Right coronary bypass grafting with coronary-coronary venous bypass graft

Revascularização da artéria coronária direita com enxerto venoso coronária-coronária

Andrea Cristina Oliveira FREITAS¹, Wladimir Faustino SAPORITO², Luis Antonio DONELLI¹, João Roberto BREDA³, Leandro Neves MACHADO⁴, Louise HORIUTI⁴, Adilson Casemiro PIRES⁵

RBCCV 44205-1107

Abstract

Objective: The following report describes the experience of the Cardiovascular Surgery Team of the ABC Medical School with coronary-coronary bypass grafting.

Methods: Four patients undergone off-pump coronary artery bypass grafting, with coronary-coronary bypass of the right coronary artery, by using great saphenous vein graft.

Results: The follow-up period was 3 to 5 years without any intra- or postoperative recurrence. One patient presented anginal symptoms four years after the surgery and underwent cinecoronariography that revealed patent anastomosis.

Conclusion: The coronary-coronary bypass is a good option for patients undergone coronary artery bypass grafting.

Descriptors: Myocardial revascularization/methods. Saphenous vein/transplantation. Aortic diseases/surgery. Coronary disease/surgery.

Resumo

Objetivo: Descrever a experiência do Serviço de Cirurgia Cardiovascular da Faculdade de Medicina da Fundação do ABC com a revascularização do miocárdio com ponte coronária-coronária.

Métodos: Foram analisados quatro pacientes submetidos a operação com ponte coronária-coronária, todos sem circulação extracorpórea. Em todos os casos, foi realizada ponte coronária-coronária na artéria coronária direita exclusivamente, utilizando segmento da veia safena magna.

Resultados: Não houve nenhuma intercorrência intra ou pós-operatória. O tempo de seguimento variou de 3 a 5 anos. Apenas um dos pacientes apresentou angina após quatro anos da operação, sendo submetido a cinecoronariografia, que demonstrou ponte coronária-coronária livre de lesões.

Conclusão: A ponte coronária-coronária constitui opção viável e satisfatória para pacientes submetidos à revascularização do miocárdio.

Descritores: Revascularização miocárdica/métodos. Veia safena/transplante. Aortopatias/cirurgia. Doença das coronárias/cirurgia.

1. Specialist; Cardiovascular Surgeon.
2. Surgeon; Teaching Auxiliary Professor of FMABC.
3. PhD; Teaching Auxiliary Professor of FMABC.
4. Cardiovascular Surgery Resident;
5. PhD; Titular Professor of Thoracic Surgery of FMABC.

Correspondence address:
Andrea Cristina Oliveira Freitas - Hospital de Ensino da Faculdade de Medicina da Fundação do ABC
Rua Silva Jardim, 470, São Bernardo do Campo, SP, Brazil - ZIP Code: 09715-090.
E-mail: acofreitas@uol.com.br

This study was carried out at the Teaching Hospital of the ABC Medical School - São Bernardo do Campo, SP, Brazil.

Article received on January 18th, 2009
Article accepted on July 29th 2009

INTRODUCTION

The severe atherosclerosis of the ascending aorta is a risk factor for increased perioperative morbidity and mortality in coronary artery bypass grafting, because of the possibility of systemic embolism and, especially, the central one. It is estimated that this problem is present in up to 13% of patients undergoing this procedure, especially during the aortic cannulation near the innominate artery for using in cardiopulmonary bypass. In these cases, manipulation of the aorta should be avoided [1].

One alternative to reduce the incidence of atheroembolism is to perform the operation without cardiopulmonary bypass. Not manipulating the aorta can be achieved through techniques that exclude the aorta as a site of graft proximal anastomosis, as the use of both internal thoracic arteries and sequential grafts. Moreover, the coronary-coronary bypass graft, due to the simplicity and satisfactory patency in the long-term should also be considered by the surgeon [1-3].

The aim of this study is to report the experience of the Cardiovascular Surgery Service of the ABC Foundation Medical School in performing coronary artery bypass grafting with coronary-coronary bypass grafting.

METHODS

In the period of 2003 to 2005, 287 CABG surgeries were performed by the Cardiovascular Surgery Service of the ABC Foundation Medical School. Of these, four (1.39%) patients underwent operation with coronary-coronary bypass, whereas three presented porcelain aorta and one by shortage of graft.

The four patients were male, aged 73, 79, 74 and 63 years. All procedures were performed without cardiopulmonary bypass, with the aid of coronary stabilizer. The only patient who presented severe atherosclerotic aorta did not have at his disposal sufficient grafts, since it was reoperation. There was consent from patients to participate in the study.

Coronary-coronary bypass grafting was performed in the right coronary artery only, using segment of the great saphenous vein with a continuous 7-0 polypropylene suture, proximal and distal one. The time of follow-up ranged from 3 to 5 years up to now. The monitoring was performed by electrocardiogram, *echodopplercardiogram* and myocardial perfusion scintigraphy annually. We did not consider necessary to perform cinecoronariography in the absence of symptoms or changes suggestive of ischemia in supplementary exams.

RESULTS

There were no intra- or postoperative complications. Also, there was no death. Only one patient presented signs

of ischemia four years after surgery, manifested by unstable angina. This patient underwent cinecoronariography that showed coronary-coronary bypass free of lesions (Figure 1) and obstruction in 70% of the marginal branch - not involved before the surgery. The other patients remained asymptomatic, without signs of electrocardiography or recent image of ischemia.

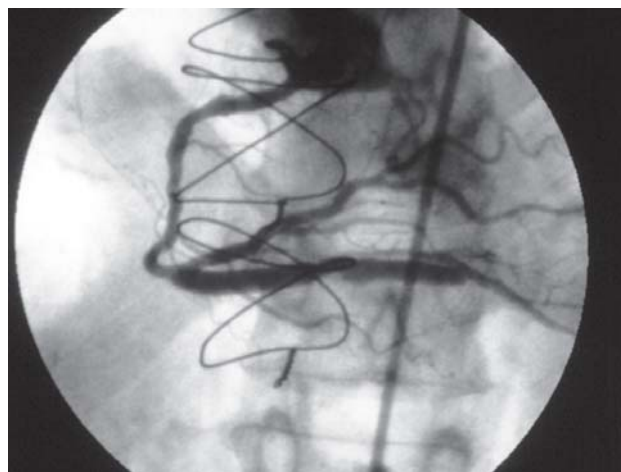


Fig. 1 – Patent coronary-coronary graft after four years of postoperative

DISCUSSION

The stroke is presented as an important cause of morbidity in the postoperative period of heart surgery, especially in patients with severe atherosclerosis of the aorta [1,4]. This condition is found most frequently in elderly patients. According to estimates by the American Society of Thoracic Surgery, about one third of patients undergoing CABG are older than 70 years [5].

There are several ways to avoid manipulation of the ascending aorta in the case of porcelain aorta. Cannulation of the axillary or femoral artery associated to induction of ventricular fibrillation, avoiding aortic clamping; the use of other sites for proximal anastomosis, such as a coronary artery or other graft; the surgery without use of cardiopulmonary bypass and the combination of these techniques are the main strategies available [1-3,5].

The coronary-coronary bypass was first described by Rowland and Grooters [6] in 1987, in two cases, one with porcelain aorta and the other for shortage of grafts. In the two patients the greater saphenous vein was used as graft. It can also be used in the cases of porcelain aorta, and also

when there is stenosis or occlusion of the subclavian artery or shortage of grafts. Korkmaz et al. [7] suggest as other indications for the coronary-coronary bypass the inappropriate flow or inadvertent lesion of pedicled internal thoracic artery, in addition to situations on which the use of internal thoracic artery represents a significant increase in morbidity. This, when used in insulin-dependent diabetic patients, elderly, patients with chronic obstructive pulmonary disease or obese, may be a predisposing factor to infections or respiratory disorders.

Most of the reports shows the diversity of possible coronary-coronary bypass. All arteries can be used in this type of bypass grafting, although the right coronary artery has particular importance due to its superficial location, easy access and frequent absence of atherosclerosis in its segment near the ostium. In this situation, venous grafts could have patency comparable to the use of arterial grafts [7-9]. In this study, the low follow-up time still does not allow such a comparison.

Korkmaz et al. [7] recommend the use of internal thoracic artery, whereas it was the graft used in all patients in their sample, including those with single lesion in the right coronary artery. They highlight the technical facility and recognized long-term patency. Moreover, it would be less subjected to spasm than other arterial grafts such as gastroepiploic or radial artery. In this study, the authors chose to use the greater saphenous vein in all cases and the initial results are similar to those in the literature.

The coronary-coronary bypass grafting can be performed either in two segments of the same artery as in different arteries. The long-term patency, although there are few reports about it, seems to be excellent. Mariscalco et al. [8] reported a case in which a greater saphenous vein graft, performed between two segments of right coronary artery was patent after 19 years postoperatively. Biglioli et al. [9] emphasized that the flow through the coronary-coronary bypass would be more physiological, once it occurs during diastole. This situation leads to lower pressure inside the graft compared to that pressure in the aorta and could explain the favorable hemodynamic conditions to its prolonged patency.

CONCLUSION

From the data collected by the authors and the reports from the literature, we concluded that the coronary-coronary bypass grafting has encouraging results and it is a

satisfactory and viable option for patients undergoing coronary artery bypass grafting, particularly those with porcelain aorta, stenosis or obstruction of the subclavian artery, and in reoperation with a shortage of grafts.

REFERENCES

1. Erdil N, Ates S, Demirkilic U, Tatar H, Sag C. Coronary-coronary bypass using vein graft on a beating heart in a patient with porcelain aorta. *Tex Heart Inst J.* 2002;29(1):54-5.
2. Silva AMRP, Campagnucci VP, Pereira WL, Rosa RF, Franken RA, Gandra SMA, et al. Revascularização do miocárdio sem circulação extracorpórea em idosos: análise da morbidade e mortalidade. *Rev Bras Cir Cardiovasc.* 2008;23(1):40-5.
3. Lima R, Diniz R, Césio A, Vasconcelos F, Gesteira M, Menezes A, et al. Revascularização miocárdica em pacientes octogenários: estudo retrospectivo e comparativo entre pacientes operados com e sem circulação extracorpórea. *Rev Bras Cir Cardiovasc.* 2005;20(1):8-13.
4. Uva MS, Pedro A, Caria R, Mesquita A, Bau J, Pinho J, et al. Coronary surgery in patients with porcelain aorta. *Rev Port Cardiol.* 2002;21(6):769-80.
5. Ricci M, Karamanoukian HL, D'Ancona G, Bergsland J, Salerno TA. Coronary artery bypass grafting in the presence of atheromatous or calcified aorta: on-pump or off-pump? *Heart Surg Forum.* 2000;3(1):12-4.
6. Rowland PE, Grooters RK. Coronary-coronary artery bypass: an alternative. *Ann Thorac Surg.* 1987;43(3):326-8.
7. Korkmaz AA, Onan B, Tamtekin B, Oral K, Aytekin V, Bakay C. Right coronary revascularization by coronary-coronary bypass with a segment of internal thoracic artery. *Tex Heart Inst J.* 2007;34(2):170-4.
8. Mariscalco G, Blanzola C, Leva C, Bruno VD, Luvini M, Sala A. 19-year patency of a coronary-coronary venous bypass graft. *Tex Heart Inst J.* 2005;32(4):583-5.
9. Biglioli P, Alamanni F, Antona C, Sala A, Susini G. Coronary-coronary bypass: theoretical basis and techniques. *J Cardiovasc Surg (Torino).* 1987;28(3):333-5.