

# Giant coronary artery dilatation in an asymptomatic patient

## *Dilatações gigantes das artérias coronárias em paciente assintomático*

Enisa de Miranda de Freitas CARVALHO<sup>1</sup>, Tomas A. SALERNO<sup>2</sup>, Kevin COY<sup>3</sup>

RBCCV 44205-1110

### **Abstract**

A case of giant dilatation of coronary arteries is presented, with review of the literature on the subject, and discussions about management of the patients with such disease.

**Descriptors:** Aneurysm. Coronary aneurysm. Coronary disease. Vasodilation.

### **Resumo**

Um caso de dilatação gigante de artérias coronárias é apresentado, com revisão da literatura sobre o assunto, e discussão sobre como abordar esses pacientes.

**Descritores:** Aneurisma. Aneurisma coronário. Doença das coronárias. Vasodilatação.

## INTRODUCTION

Dilatation of four giant coronary arteries is a rare angiographic finding. The pathogenesis of this condition is not very well understood. Therapeutic strategies, including the need for any surgical intervention and timing for surgery, are not very clear, especially in asymptomatic patients. The aim of this report is to describe the case of a patient with dilatation of four coronary arteries. To our knowledge, there are no previous report in the literature on such case like this presented herein.

## CASE REPORT

41-year-old male patient, african-american with a history of chronic renal failure stage 5, secondary to hypertension. The patient underwent a kidney transplant in 1996, which failed in 2003 and is undergoing dialysis since then. The

patient denied any personal or family history of cardiovascular disease, smoking, diabetes mellitus, dyslipidemia or myocardial infarction. The patient also denied chest pain, dyspnea, orthopnea, paroxysmal nocturnal dyspnea, palpitations or fatigue. The clinical history and laboratory tests did not suggest arteritis as an underlying disease related to presentation of dilation of coronary arteries. In 2007, the patient was referred for cardiac evaluation of surgical risk before undergoing a second kidney transplant.

He presented the following exams, performed in August 2006: resting electrocardiogram that showed regular sinus rhythm, absence of progression of R-wave, and left ventricular hypertrophy with strain pattern; cardiac stress test and echocardiogram showed no evidence of exercise-induced ischemia, but the latter revealed dilated cardiomyopathy with a left ventricle ejection fraction between 35% and 40%. The stress echocardiogram

1. Master's Degree. Post Doctoral Research Support Coordinator of the Department of Anesthesia - University of Miami.
2. PhD. Head of the Cardiothoracic Surgery Division at Jackson Memorial Hospital - University of Miami.
3. PHD; Cardiologist at Jackson Memorial Hospital - University of Miami.

This study was carried out at the Division of Cardiology and Cardiothoracic Surgery, University of Miami Miller School of Medicine and Jackson Memorial Hospital, Miami, Florida.

Correspondence address:  
Tomas A. Salerno, M.D. Cardiothoracic Surgery 1611 NW 12<sup>th</sup> Avenue  
Miami, Florida, USA - 33136.  
E-mail: tsalerno@med.miami.edu

Article received on December 22<sup>nd</sup>, 2008  
Article accepted on August 14<sup>th</sup>, 2009

performed in November 2007 reached 78% of maximum heart rate with no chest pain, absence of ischemic changes and no changes in mobility of the cardiac walls, increased ejection fraction of 15% above normal values (suggesting the absence of exercise-induced ischemia), no arrhythmia, and normal functional capacity. As the stress echocardiography was not conclusive, the patient was then referred for coronary angiography.

Coronary angiography performed in December 2007 showed severe calcification of the coronary arteries. The right coronary artery was the dominant vessel with considerable dilatation (7.39 mm) without significant stenosis (Figure 1). The left coronary artery presented large caliber (6.45 mm). The anterior descending coronary artery had a segment with intense dilation (11.46 mm) with two to three inches long, with calcification in the mean portion and severe narrowing in the distal portion of the dilated segment when compared to the normal caliber of the artery. The circumflex coronary artery presented similarly large dilation (7.16 mm), without significant stenosis. The total ejection fraction was 40%. There was no significant mitral regurgitation.

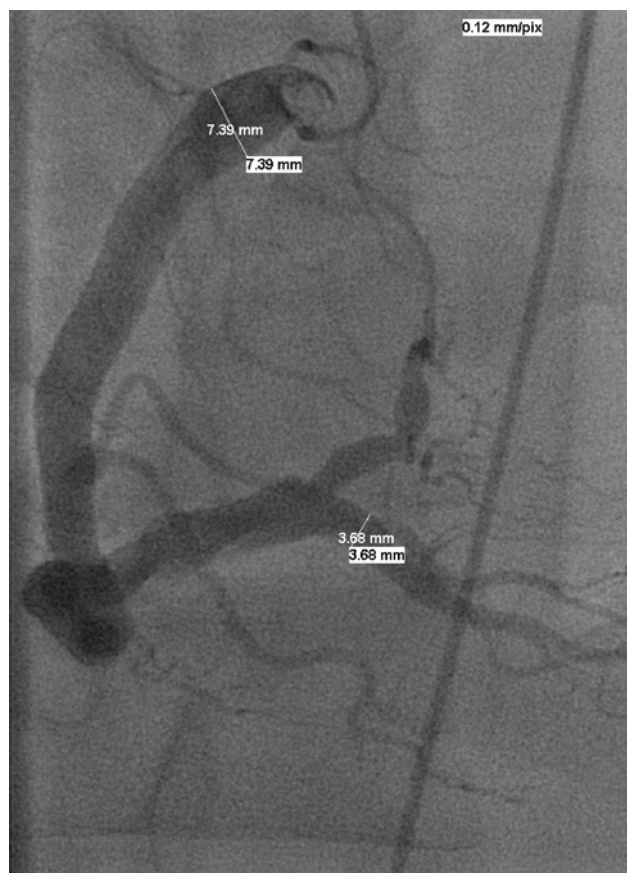


Fig. 1 – Coronary angiography showing the right coronary artery with large dilation

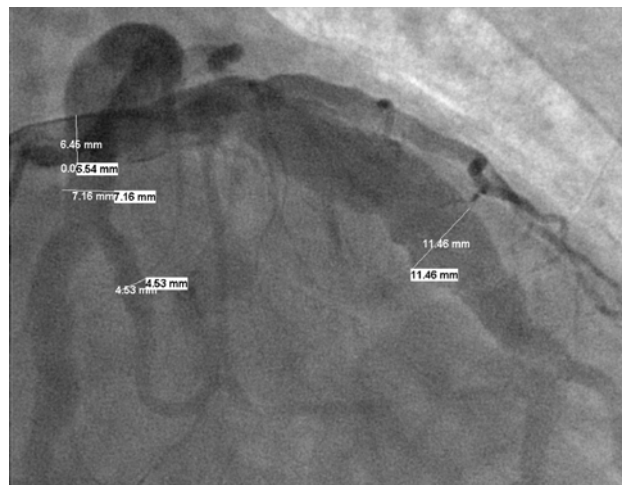

Fig. 2 – Coronary angiography showing the left, anterior descending and circumflex coronary arteries with considerable dilations

The hemodynamic evaluation showed left ventricular end-diastolic pressure remarkably high. As it was diagnosed dilated coronary artery and CABG would not lead to a resolution of the presentation, the patient received authorization from the cardiology team and underwent kidney transplantation, and was guided to make strict follow-up with cardiologist thereafter. As the patient presented coronary calcification, atherosclerosis seemed to us the most probable cause.

## DISCUSSION

The advent of cardiac catheterization allowed the *in vivo* diagnosis of dilatation of the coronary arteries. There is a difference between coronary artery ectasia and aneurysm of coronary arteries, although such diseases may be manifestation of the same pathological process [1]. The coronary aneurysms have multiple definitions, but the most accepted is the focal increase of the diameter that exceeds 1.5-2 times [2] the “normal” adjacent segment. Aneurysms can be saccular or fusiform. Saccular aneurysm is defined as the aneurysm with a transverse dimension greater than the longitudinal dimension of the segment, while fusiform aneurysm is an aneurysm with longitudinal dimension of at least 200% of its transverse dimension [3].

This patient can not be classified as bearer of coronary aneurysms, since he does not have a focal dilatation, instead, he presents diffuse dilatation of the coronary arteries. One study assessed a large group of 20,087 patients with aneurysms of the coronary arteries [4] and no patient presented more than three vessels with aneurysms. Coronary arteries ectasia (CAE) is defined as a local or diffuse dilatation in coronary arteries. Ectasia is considered

diffuse when it affects more than one segment in the same or different artery and local when an only arterial segment is involved [4]. CAE is diagnosed when a segment of the artery is greater than 1.5 times the diameter of the segment of the normal adjacent artery [5].

We classify this case based on the classification proposed by Markis et al. [6], modified by Nyamu et al. [7] on coronary artery ectasia (Type I: isolated diffuse ectasia, Type II: diffuse local ectasia in combination, Type III: local isolated ectasia; Type IV: involvement of the left coronary artery trunk; whereas IVb concomitant involvement of other vessels) and the patient was classified as type IV. Using the classification proposed by Markis et al. [6], modified by Harikrishnan et al. [1] (Type I: diffuse ectasia of two or three vessels, and Ia diffuse three-vessel disease; Type II: diffuse ectasia in one vessel and local in the other; Type III: diffuse ectasia in one vessel; Type IV: local ectasia in one, two or three vessels) and the patient was classified as type Ia.

However, as the patient presented diffuse dilatation of four vessels (left main coronary artery, anterior descending, circumflex and right coronary artery), we emphasize that typically the assessment of left coronary trunk is performed separately and thus the case reported presents four coronary arteries dilated, which is a rare event. The prevalence found in studies on ectasia of the coronary arteries of patients with IVb classification (Markis et al. [6], modified by Nyamu et al. [7]) is of 3.73% and of patients with I classification (a+b) (Markis et al. [6], modified by Harikrishnan et al. [1]) is of 5.8% [8]. The small number of such cases found in the studies and literature makes it difficult to determine the best treatment for the reported case. However, studies [1,3,6] on coronary artery ectasia recommend that the current treatment for dilation of coronary arteries should include a method of therapy for each aforementioned potential complications. The appropriate regime includes: (1) anticoagulation to minimize the risk of thrombus formation, (2) antiplatelet therapy, (3) blocker therapy with calcium channel blockers to prevent spasm of the coronary arteries (the use of beta blockers should be avoided, which can lead to spasm of the coronary

arteries due to an overlap of the alpha receptor). Nitrates can also be used. Since this case is about diffuse dilatation of all coronary arteries, we have the choice of prophylaxis as a recommended treatment for coronary artery ectasia. The rarity of four coronary arteries with ectasia difficults to establish a guideline on conservative treatment versus surgical approach.

#### REFERENCES

1. Harikrishnan S, Krishnakumar N, Jaganmohan T. Coronary artery ectasia: is it time for a reappraisal? *Clin Cardiol.* 2007;30(10):536.
2. Robinson FC. Aneurysms of the coronary arteries. *Am Heart J.* 1985;109(1):129-35.
3. Harikrishnan S, Sunder KR, Tharakan J, Titus T, Bhat A, Sivasankaran S, et al. Coronary artery ectasia: angiographic, clinical profile and follow-up. *Indian Heart J.* 2000;52(5):547-53.
4. Swaye PS, Fisher LD, Litwin P, Vignola PA, Judkins MP, Kemp HG, et al. Aneurysmal coronary artery disease. *Circulation.* 1983;67(1):134-8.
5. Hartnell GG, Parnell BM, Pridie RB. Coronary artery ectasia. Its prevalence and clinical significance in 4993 patients. *Br Heart J.* 1985;54(4):392-5.
6. Markis JE, Joffe CD, Cohn PF, Feen DJ, Herman MV, Gorlin R. Clinical significance of coronary arterial ectasia. *Am J Cardiol.* 1976;37(2):217-22.
7. Nyamu P, Ajit MS, Joseph PK, Venkitachalam L, Sugirtham NA. The prevalence and clinical profile of angiographic coronary ectasia. *Asian Cardiovasc Thorac Ann.* 2003;11(2):122-6.
8. Yilmaz H, Sayar N, Yilmaz M, Tangurek B, Çakmak N, Gurkan U, et al. Coronary artery ectasia: clinical and angiographical evaluation. *Turk Kardiyol Dern Ars.* 2008;36(8):530-5.