

# Video-assisted minimally invasive mitral valve repair: periareolar approach

*Plastia valvar mitral minimamente invasiva videoassistida: abordagem periareolar*

Robinson POFFO<sup>1</sup>, Renato Bastos POPE<sup>2</sup>, Alisson Parrilha TOSCHI<sup>2</sup>, Cláudio Alexandre MOKROSS<sup>3</sup>

RBCCV 44205-1114

## CHARACTERIZATION OF THE PATIENT

53-year-old female patient, Caucasian and weighing 42 kg with history of tiredness, dry cough and recent dyspnea on moderate effort evolving in a week to minimum effort. She denied any associated pathology or medication use. Physical examination showed malnutrition, with paleness of the skin and mucosae and mild dyspnea. Pulmonary auscultation revealed rales at the bases and cardiac auscultation revealed a sinus rhythm, with holosystolic murmur in the mitral focus with first hypophonesis sound.

Radiography showed normal heart size, with bibasal pulmonary congestion. The echocardiogram showed left atrial dimension (LA) slightly increased (4.1 cm) and left ventricle (LV) with cavity diameter at the upper limit of normal (LV Systolic Diameter: 3.0 cm – LV Diastolic Diameter: 5.0 cm) and normal myocardial thickness. Other cavities were normal. The mitral valve was thickened and redundant, with myxomatous appearance, showing anterior leaflet of flail appearance surpassing the point of coaptation with partial rupture of the chordae of the anterior leaflet. Doppler showed mild holosystolic flow. The ejection fraction was estimated at 76%. The tricuspid valve presented functional reflux and the pulmonary arterial pressure was estimated between 35 and 45 mmHg.

As preoperative preparation it was requested cardiac catheterization, by taking care to avoid puncture of the femoral vessels, since there were possibility of assisted

minimally invasive mitral valve surgery. There was no evidence of coronary disease and the pressures were normal in the aorta and left ventricle with increase of pulmonary capillary (16 mmHg). Ventriculography revealed a severe mitral insufficiency.

After discussing the clinical case, mitral valvuloplasty was indicated. In conversation with the patient, after explanation of the types of possible techniques to approach the mitral valve disease, she decided by video-assisted minimally invasive approach.

Surgical correction consisted of mitral valve repair, using neochordae of PTFE (Gore-Tex) [1] (Figure 1) for anterior leaflet and annuloplasty with semi-rigid ring Carpentier-Edwards Physio Ring® (Edwards Lifesciences). The video-assisted minimally invasive periareolar approach [2] was chosen. The cardiopulmonary bypass (CPB) time was 98 minutes (min) and aortic clamping was 73 min.



Fig. 1- Confection of the PTFE loops

**THE VIDEO PERTINENT TO THE TEXT IS AVAILABLE AT THE BJCVS WEBSITE: [www.rbccv.org.br/video/v24n3/](http://www.rbccv.org.br/video/v24n3/)**

This study was carried out at the Hospital Israelita Albert Einstein – São Paulo – SP and Hans Dieter Schmidt Hospital – Joinville – SC

1. Coordinator of the Minimally Invasive Cardiac Surgery Program of the Hospital Israelita Albert Einstein – São Paulo – SP. Coordinator of the Cardiac Surgery Service of the Hans Dieter Schmidt Hospital – Joinville – SC. Master's Degree in Surgical Clinics at Federal University of Paraná.
2. Cardiovascular Surgeon of the Hans Dieter Schmidt Hospital – Joinville – SC.

3. Plastic Surgeon of the Hans Dieter Schmidt Hospital – Joinville – SC.

Correspondence address:

Robinson Poffo

Av. Albert Einstein, 672/701 – CEP 05652-901 – São Paulo – SP

E-mail: [drpoffo@einstein.br](mailto:drpoffo@einstein.br)

**CONFLICT OF INTEREST STATEMENT:**

The author declares that there is no conflict of interests.

Article received on August 5th, 2009  
Article accepted on September 8th 2009

The patient had an uneventful postoperative course. At the echocardiogram of the day of discharge, the valve presented with normal functioning without evidence of mitral insufficiency. The period of mechanical ventilation was 4.2 hours, the postoperative bleeding of 235 ml, length of ICU stay of 20 hours and she was discharged from hospital on the 3<sup>rd</sup> postoperative day.

#### DESCRIPTION OF SURGICAL TECHNIQUE

The patient was intubated using Carlens orotracheal tube for selective lung ventilation and positioned with the right side of the chest elevated at 20°, with the arm positioned along the body. Disposable pads for external cardiac defibrillation were placed in the region of the right scapula and the anterior-lateral left hemithorax. It was performed the passage of nasopharyngeal thermometer and transesophageal transducer. Initially, marks for surgical access (Figure 2) were performed using a surgical pen. Then, sterile plastic field with iodophor (Ioban2®) was applied across the exposed area following the routine of our service.

The right angle surgical skin incision was performed using scalpel blade No. 15, following the previous marking of the half of the inferior circumscription of the transition of the nipple-areolar complex with the right breast skin, from 4 to 10 hours. After the section of the dermis, when the loose connective tissue is reached, which makes the transition between the dermis and glandular tissue, changing the angle of inclination of the scalpel for 45° positioned at the eccentric angle of the nipple-areolar complex, moving just less of a half centimeter in this plan [3]. Mammary glandular tissue was then sectioned with scissors, using the entire length of the incision until reaching the major pectoralis. Retractor of mammary tissue was introduced and subglandular dissection was performed by reaching the intercostal space of interest (4th right intercostal space - RICS). Layer hemostasis was performed accurately.

The chest was approached through the 4th RICS [4], between the anterior axillary line (AAL) and right hemiclavicular (RHL). To enlarge the work space, we used soft tissue retractor Alexis® (Applied Medical). The right lung was selectivated. In the same intercostal space, anterior to the axillary middle line, an optical trocar of 5 mm and 30°

was introduced and in the 7° RICS in the AAL, a 7 mm trocar was introduced for insufflation of CO<sub>2</sub> and introduction of the soft atrium/left ventricle aspirator (DLP®, Medtronic, inc.). The surgical instrument used was specific for this type of procedure, consisting of transthoracic aortic clamp, pliers, tweezers and long scissors, with approximately 35 cm for videothoracoscopy. Under optical vision, the pericardium was opened two centimeters anterior to the phrenic nerve. This incision extended from the inferior vena cava to superior one. The pericardium was pulled by four points, which were exteriorized through the chest wall using a retractor/hook.

After systemic heparinization, cardiopulmonary bypass (CPB) was established by decannulation of the femoral vessels, whereas the skin was incised in the right inguinal groove and the femoral vessels were cannulated using the Seldinger technique under direct vision. For arterial cannulation Bio-Medicus® cannula No. 17 French (Fr) (Medtronic, inc.) was used and for venous line, femoral cannula Eopa No. 21 Fr (Medtronic, Inc.). The venous drainage was assisted by vacuum. The patient was maintained at 28° Celsius (°C). For perfect positioning of the cannulas the transesophageal echocardiography was used.

Through the 2nd RICS in AAL, transthoracic aortic clamp (Chitwood clamp - Fehling, inc.) was introduced. Using videothoracoscopy, the ascending aorta was clamped and punctured with a metal needle of 30 cm (Geister, Inc.) for administration of cold antegrade cardioplegia (6°C) with HTK solution (Custodiol®). In the puncture site a purse suturing was performed using Teflon 2-0 braided polyester suture passed through a tourniquet for subsequent removal of air from the ascending aorta. The opening of the left atrium was anterior to the right pulmonary veins and the atrial withdrawal was performed by using a specific transthoracic retractor (Estech, inc.) passed through 4th RICS, lateral to the region of the left internal mammary artery.

With the introduction of optics in the left atrium, the mitral valve was inspected on which a partial rupture of the chordae to the anterior leaflet was revealed. Three points of 2.0 braided polyester were passed, the first in the posterolateral fibrous trigone, the second in the anterolateral fibrous trigone and the third in the posterior region of the mitral annulus and exteriorized through the minithoracotomy with the aim of rectifying the valve. We opted for the preservation of this valve using the technique of implantation of neochordae of PTFE, with pre-measured loops of Gore-tex® wire - CV5 [1]. Using a specific meter (Geister, inc), the distance between the right plan of valve closure was measured in areas adjacent to non-

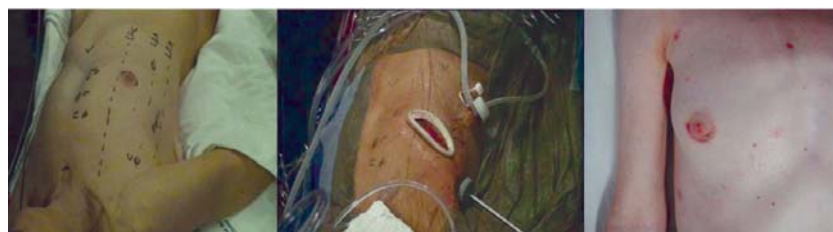

Fig. 2 – Preoperative marks, transoperative aspect and evolution of the periareolar wound in 30 days

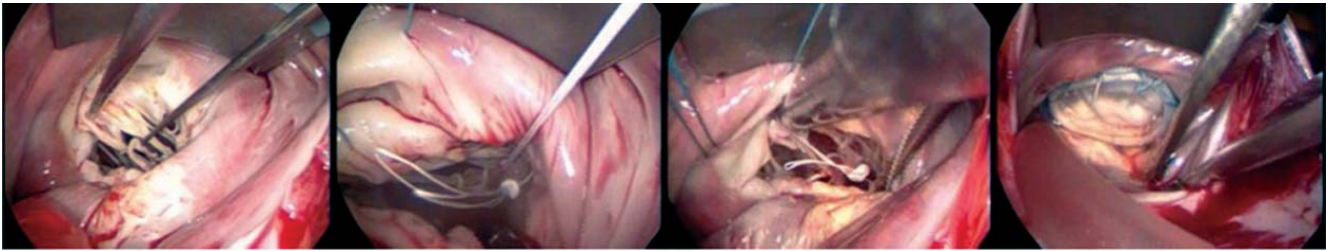


Fig. 3 – Identification of the chordae rupture to the mitral valve anterior leaflet, implant of Gore-Tex® loops with its settlement on the papillary muscle and anterior leaflet, and final appearance of the valve repair

prolapsed ones and the respective papillary muscle. A point with two loops was performed, which was settled on the head of the papillary muscle from which the ruptured chordae originated. This point was supported in Teflon. Then, it was sutured to the edge of the anterior mitral valve leaflet, where there was a rupture of the chordae tendinae through simple points of Gore-tex® CV5 wire (Figure 3).

To finish the valvuloplasty, points of 2.0 braided polyester were passed around the ring for implantation of semi-rigid ring No. 32 Carpentier-Edwards Physio Ring® (Edwards Lifesciences). At test with saline solution the valve presented competent. Since the opening of the left atrium the CO<sub>2</sub> injection was maintained at a flow rate of 3 liters per minute, with the aim of reducing the possibility of air embolism. The left atrium was sutured using 3-0 polypropylene yarn, through which a ventricular suction catheter was left passed through the valve to remove residual air.

Maneuvers for deaeration of the left chambers were performed by mobilizing the operating table in a Trendelenburg and anti-Trendelenburg position and alternating lateral left-right position. Aspiration was performed by the left ventricle and the tourniquet from the point of puncture for cardioplegia was left open so that the residual air of the ascending aorta could be evacuated. Inspection of the left cavities through transesophageal echocardiography was performed, as there was no residual air, the aorta was clamped and the patient rewarmed.

After disconnection of CPB, the femoral vessels were decannulated and heparin was reversed. After hemostasis review, the pericardium was closed by interrupted sutures of 2-0 braided polyester. The chest drain was exteriorized through the hole of the optical trocar and directed into the pericardial sac. Such device was kept in negative aspiration of 20 mmH<sub>2</sub>O.

Periareolar access was closed in layers, initially the muscle and then the pre-aponeurotic mammary tissue thickening with polyglecaprone 25 (Caprofil®) 3-0. A new grip of the edges of the surgical incision was performed

using Allis forceps with surgical correction of the plans and approximation of the mammary tissue in two or three sutures using the same suture yarn. Suture of the subdermal plane was performed with Polyglycolic Acid (PGA) yarn (Monocryl®) 4-0 colorless with blade needle. The central portions of the edges of the nipple-areolar complex and skin were used as an initial reference point and, from this, the plan subdermal suture was performed with points distributed equidistantly. When achieving a good coaptation of the wound edges, the synthesis of the skin was performed using a mononylon 5-0, vertical-U sutures Perseus type, with the knot directed inside the nipple-areolar complex and reaching only the subdermal plane of the skin, following the same sequence of subdermal points previously performed. The other orifices were closed using simple nylon 5-0 points. The dressing wound was performed with thin and local layer of healing ointment on the edge of the surgical wound and occlusion with gauze and micropore®.

#### REFERENCES

1. Von Opper UO, Mohr FW. Chordal replacement for both minimally invasive and conventional mitral valve surgery using premeasured Gore-Tex loops. *Ann Thorac Surg.* 2000;70(6):2166-8.
2. Poffo R, Selbach RA, Mokross CA, Fukuti F, Pilatti M, Cidral I. Correção cirúrgica da comunicação inter-atrial: uma nova abordagem. In: 10º Congresso da SICVESP; 2007; Águas de São Pedro; SP. Anais: Rev Bras Cir Cardiovasc. 2007; 22(4):530.
3. Jenny H. The areolar approach to augmentation mammoplasty. *Int J Aesthetic Plast Surg.* 1972-F. Heyer-Schulte Corporation product brochure (1972).
4. Poffo R, Bonin M, Selbach RA, Pilatti M. Troca valvar mitral minimamente invasiva videoassistida. *Rev Bras Cir Cardiovasc.* 2007; 22(4)491-4.