

Surgical treatment of chronic type A aortic dissection in patients undergoing coronary artery bypass grafting

O tratamento operatório da dissecação aórtica crônica tipo A em pacientes submetidos à revascularização cirúrgica do miocárdio

João Carlos LEAL¹, Victor Rodrigues Ribeiro FERREIRA², Luis Ernesto AVANCI³, Domingo Marcolino BRAILE⁴

RBCCV 44205-1204

Abstract

Surgical treatment of aortic dissection is a challenge for the cardiac surgeon, especially in patients undergoing cardiac operations. Our objective in this case report is to demonstrate how we treat the chronic type A aortic dissection in revascularized patients using percutaneous arterial and venous cannulae.

Descriptors: Extracorporeal circulation. Myocardial revascularization. Systemic inflammatory response syndrome. Aortic aneurysm/surgery.

Resumo

O tratamento operatório da dissecação aórtica é um desafio para o cirurgião cardíaco, sobretudo nos pacientes submetidos a operação cardíaca prévia. Nosso objetivo neste relato de caso é demonstrar como tratamos a dissecação aórtica crônica tipo A em paciente revascularizado utilizando cânulas arterial e venosa percutâneas.

Descritores: Circulação extracorpórea. Revascularização miocárdica. Síndrome de resposta inflamatória sistêmica. Aneurisma aórtico/cirurgia.

INTRODUCTION

The acute type A aortic dissection, according to the Stanford classification is a challenging disease for the cardiac surgeon. The incidence of the disease has increased significantly due to the easier diagnosis. The causes are many, among them the late postoperative period of patients

undergoing coronary artery bypass grafting (CABG). The high mortality rate within 48 hours reflects the severity of the disease, even though it is called chronic after the fourteenth day. The purpose of this case report is to demonstrate how we treat the chronic type A aortic dissection in patients revascularized using percutaneous arterial and venous cannulae.

1. Masters and Ph.D. in Cardiovascular Surgery at the University of Campinas (UNICAMP), Adjunct Professor at FAMERP.
2. Clinical Cardiologist, Intensivist Cardiologist of cardiovascular surgery.
3. Associate member of SBCCV; Cardiovascular surgeon responsible for intensive care.
4. Lecturer- Professor of FAMERP and the University of Campinas (UNICAMP), editor in chief of the Brazilian Journal of Cardiovascular Surgery.

Work performed at Hospital Beneficência Portuguesa, São José do Rio do Rio Preto-SP/Instituto Domingo Braile, São José do Rio Preto, SP, Brazil.

Correspondence address: João Carlos Ferreira Leal
Rua Luiz Vaz de Camões, 3111 - Bairro Redentora - São José do Rio Preto, SP, Brasil - CEP 15015-750.
E-mail: joaocarlos@braile.com.br

Article received on February 22nd, 2010
Article accepted on June 25th, 2010

CASEREPORT

Male patient, 53 years, 85 kg, 1.75 m (BMI = 27.75 kg/m²), hypertensive (HBP) and dyslipidemic underwent coronary artery bypass grafting in 2006 with anastomoses from the left to the anterior interventricular coronary artery and saphenous vein graft to the marginal branch, right coronary artery, first and second diagonal branches, with support of cardiopulmonary bypass (CPB). The patient remained asymptomatic until August 2009 when he presented an episode of chest pain radiating to the dorsal region, having undergone a series of cardiovascular tests. Coronary angiography showed significant obstructive lesion of 85% loss of area in the right aorto-coronary graft, mild inferior hypokinesia, aortic dissection type A and moderate aortic valve insufficiency. The Doppler echocardiogram showed: ascending aortic diameter of 79 mm, left atrial diameter of 26 mm, LVDD (left ventricular diastolic diameter) of 57 mm, septum of 11 mm and ejection fraction = 0.75; ascending aortic dissection and significant aortic valve insufficiency. The 64-channel CT angiography of thoracic aorta confirmed the dissection that started at the aortic root at the valve plane and extended to the distal ascending portion before the brachiocephalic trunk and had 100 mm in diameter leading to the report of aortic dissection type A (Figure 1).

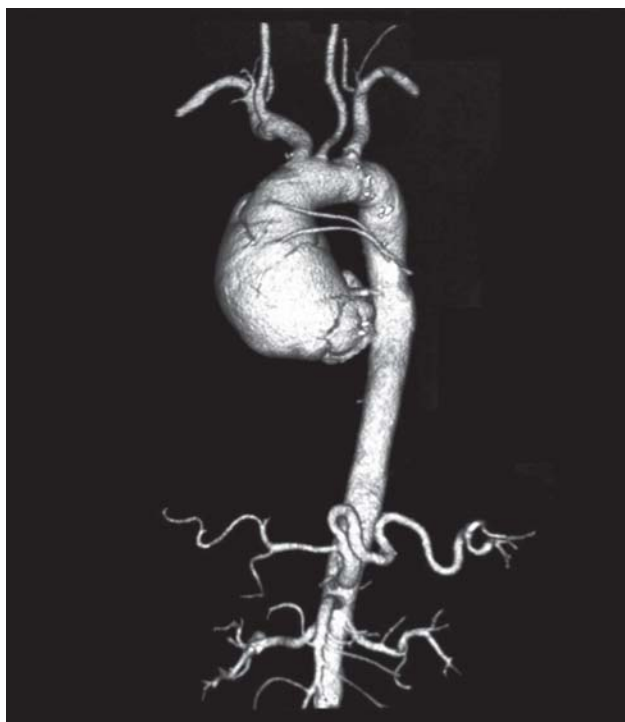


Fig.1 - Chronic dissection type A in revascularized patient

The treatment of aortic dissection type A is operative, aggressive and of high risk. CPB was initiated before the opening of the chest to prevent injury to the aorta, which presented a diameter of 100 mm. We used percutaneous arterial and venous cannulation, via femoral artery after systemic heparinization. The 24 French venous cannula reached the superior vena cava aided by guiding wire and transesophageal Doppler echocardiogram (TEE) and the 14-French arterial cannula was installed without the aid of TEE. The left magna saphenous vein was removed in order to make a right aorto-coronary anastomosis graft.

The patient underwent moderate hypothermia of 25° C without total circulatory arrest, the heart protection used was blood, antegrade and retrograde, isothermal and of low volume. After opening the ascending aorta, the dissection was confirmed, the proximal anastomoses of vein grafts were in the true lumen and the sinuses of Valsalva were intact. Thus, the ascending aorta and the aortic valve leaflets were removed; the proximal anastomoses of vein grafts were isolated en bloc. A metallic aortic prosthesis

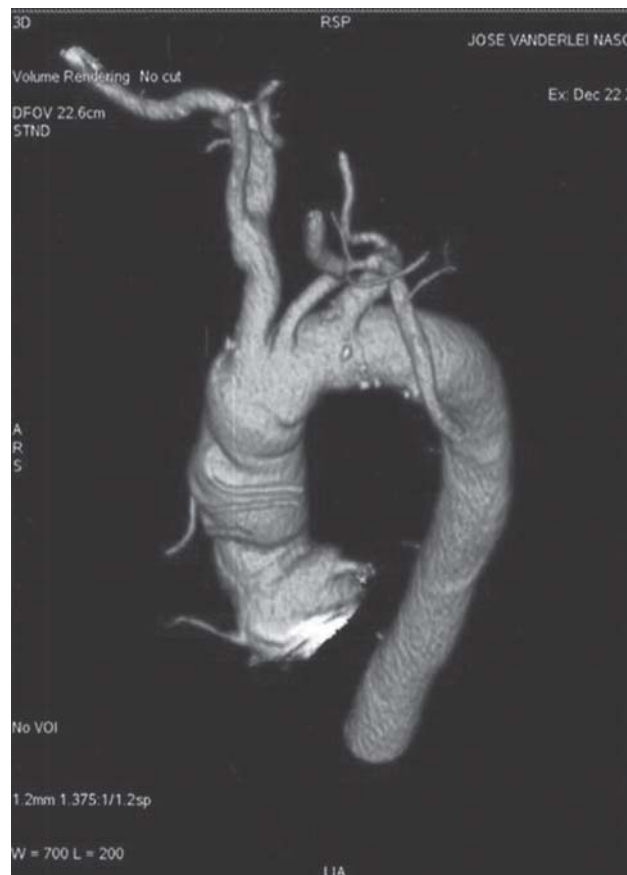

Fig. 2 - Correction of chronic dissection type A in revascularized patient with smooth bovine pericardial tube and implant of a metallic prosthesis in aortic position

No. 27 was implanted and it was performed the reconstruction of the ascending aorta with a smooth tube of bovine pericardium (BP) No. 33, with construction of anastomoses en bloc of the venous grafts in the tube of BP were and the new right aorta-coronary venous graft. The patient was heated up to 37°C, the heartbeat restarted with bradycardiac sinus rhythm and left the CPB with hemodynamic stability. The intraoperative TEE demonstrated the smooth tube of BP with great performance, well-functioning metallic prosthesis and myocardial function preserved.

The immediate postoperative period was satisfactory, with overall hospital stay of up to nine days. The medication used was beta-blockers, diuretics, statins and oral anticoagulants. The CTA of 64 control channels in the late postoperative period showed good permeability of the aorta, which had maximum transverse diameters of 36, 29 and 27 mm, respectively, in their ascending, transverse and descending portions, with a normal metallic prosthetic aortic valve (Figure 2). The patient has periodic clinical follow-up, with good clinical outcome, and currently is asymptomatic.

DISCUSSION

The causes of aortic dissection are several. During and after cardiac surgery is a rare but fatal phenomenon, with a prevalence of 0.16% observed in a review of 14,877 patients and above 0.6% in patients undergoing aortic valve operation. The mortality of the dissection during cardiac surgery is high, ranging between 20% and 50%, requiring immediate treatment [1,2]. Over 10 years, we recorded only one (0.05%) case of aortic chronic dissection type A in 2160 coronary artery bypass grafting surgeries performed in our department.

The natural history of aortic dissection after cardiac surgery is not clear. However, there are some studies that demonstrated the occurrence of aortic dissection in the late postoperative period of patients undergoing CABG. In the aortas were observed atheroma plaques, wall dilatation, cystic necrosis and collagen disease [3,4]. The patient in this case report is dyslipidemic, which possibly led to the presence of the atheroma plaque in the ascending aorta and caused the aortic dissection. There are also major implications for the occurrence of aortic dissection that involve the surgical technique, such as the manipulation of the aorta. Authors demonstrated that patients with myocardial revascularization developed aortic dissections according to the intimal lesion at the site of the aortic clamping and the time interval between the procedure and the dissection was up to 53 months [5]. Our patient had a

follow-up period of 38 months. Coronary angiography, despite being of high risk for these patients it is an important test to assess graft patency and to check if the proximal anastomoses of vein grafts are in the true lumen of the aorta, allowing the bulk handling of anastomoses.

There are several surgical tactics and techniques for the treatment of aortic dissection type A, especially in patients with previous cardiac surgery. The use of percutaneous arterial and venous cannulae can be a good alternative, especially in patients with dilated aorta, as in this case. The idea is to start the CPB before the median sternotomy approach to facilitate the mediastinum, and manipulation of the aorta. TEE is essential in the percutaneous venous cannulation, as it allows visualization of cannulation to the superior vena cava and to evaluate the preserved left ventricular function. In this case it also allowed evaluating the metallic valve prosthesis.

Although it is only one case report, it is important to consider the use of percutaneous arterial and venous cannulation via femoral artery in the treatment of aortic dissection type A with increased aortic diameter, as in this case. This surgical tactic allows opening the chest without lesion to the aortic wall and facilitates handling the reconstruction of the ascending aorta by not showing cannulae in the operative field.

REFERENCES

1. Still RJ, Hilgenberg AD, Akins CW, Daggett WM, Buckley MJ. Intraoperative aortic dissection. *Ann Thorac Surg.* 1992;53(3):374-9.
2. Chavanon O, Carrier M, Cartier R, Hébert Y, Pellerin M, Pagé P, et al. Increased incidence of acute ascending aortic dissection with off-pump aortocoronary bypass surgery? *Ann Thorac Surg.* 2001;71(1):117-21.
3. Bopp P, Perrenoud JJ, Périat M. Dissection of ascending aorta. Rare complication of aortocoronary venous bypass surgery. *Br Heart J.* 1981;46(5):571-3.
4. Nicholson WJ, Crawley IS, Logue RB, Dorney ER, Cobbs BW, Hatcher CR Jr. Aortic root dissection complicating coronary bypass surgery. *Am J Cardiol.* 1978;41(1):103-7.
5. Hagl C, Ergin MA, Galla JD, Spielvogel D, Lansman S, Squitieri RP, et al. Delayed chronic type A dissection following CABG: implications for evolving techniques of revascularization. *J Card Surg.* 2000;15(5):362-7.