

Long-term evolution of mitral commissurotomy in rheumatic patients with low echocardiographic score

Evolução tardia da comissurotomia mitral em pacientes reumáticos com baixo escore ecocardiográfico

Luciano Rapold Souza¹, Carlos Manuel de Almeida Brandão², Pablo Maria Alberto Pomerantzeff³, Osanam Amorim Leite Filho⁴, Luiz Francisco Cardoso⁵, Noedir Antonio Groppo Stolf⁶

DOI: 10.5935/1678-9741.20110012

RBCCV 44205-1293

Abstract

Introduction: The good results of open mitral commissurotomy are well known and there is a hypothesis that it could provide better results in patients selected by echocardiographic score.

Objective: The purpose of this study is to analyze the late results with open mitral commissurotomy in patients selected by score and to identify variables influencing these results.

Methods: From January 1990 to August 1994, 50 patients were submitted to open mitral commissurotomy due to rheumatic mitral stenosis in Heart Institute of University of Sao Paulo Medical School. Patients with age < 60 years, in functional class II, III or IV (New York Heart Association) and echocardiographic score ≤ 9 were included. The mean age was 32.7 ± 8.3 years and 41 patients (82%) were female. The functional class was II in three patients (6%), III in 46

(92%) and IV in one (2%). Forty six patients (92%) were in sinus rhythm and four (8%) were in atrial fibrillation. The mean mitral valve area was 0.9 ± 0.2 cm².

Results: There was no hospital mortality. There were two late deaths, one related to valve disease. Actuarial survival was 95.5 ± 3.1 %, freedom from reoperation was 62.3 ± 11.8 % and freedom from thromboembolism was 88.2 ± 5.0 % in 18 years. There was no endocarditis. The grade of the echocardiographic score had no significant influence on the reoperations in late evolution.

Conclusion: Open mitral commissurotomy presented excellent long term results in rheumatic patients with low echocardiographic score.

Descriptors: Rheumatic Heart Disease. Mitral Valve Stenosis. Cardiovascular Surgical Procedures.

1. Doctor of Science from the School of Medicine, University of São Paulo (USP), Head of Cardiovascular Surgery of the Hospital Portugues de Salvador, Salvador, Bahia, Brazil.
2. Doctor of Medicine, FMUSP, Medical Assistant of the Surgical Unit of Valve Disease, Heart Institute, Hospital das Clínicas, FMUSP (InCor - HC-FMUSP, São Paulo, Brazil).
3. Associate Professor in the Department of Cardiovascular Surgery at FMUSP, Director of Valve Disease Surgical Unit of InCor - HC-FMUSP) São Paulo, Brazil.
4. Graduated in Medicine from the Federal University of Piauí, Graduate Student in the Department of Cardiovascular Surgery at FMUSP, São Paulo, Brazil.
5. Associate Professor, FMUSP, Assistant of the Valve Disease Clinic of InCor - HC-FMUSP, São Paulo, Brazil.

6. Professor of Cardiovascular Surgery at FMUSP, Director of Surgery Division of InCor - HC-FMUSP, São Paulo, Brazil.

Work performed at the Heart Institute, Hospital das Clínicas, School of Medicine, University of São Paulo, São Paulo, Brazil.

Correspondence address:

Luciano Rapold Souza. Alameda das Samambaias, 375, casa 4 – Piatã – Salvador, BA, Brazil – Zip Code: 41650-230.

Article received on March 25th, 2011

Article accepted on July 19th, 2011

Resumo

Introdução: Os bons resultados da comissurotomia mitral a céu aberto são bem conhecidos e existe a hipótese de que se poderiam obter melhores resultados em pacientes selecionados pelo escore ecocardiográfico.

Objetivo: Analisar os resultados tardios da comissurotomia mitral em pacientes selecionados pelo escore ecocardiográfico e identificar variáveis com influência nesses resultados.

Métodos: De janeiro de 1990 a agosto de 1994, 50 pacientes com estenose mitral reumática foram submetidos à comissurotomia mitral a céu aberto no Instituto do Coração do Hospital das Clínicas da Faculdade de Medicina da Universidade de São Paulo. Foram incluídos pacientes com idade < 60 anos, classe funcional II, III ou IV (*New York Heart Association*) e escore ecocardiográfico ≤ 9 . A idade média foi de $32,68 \pm 8,29$ anos, sendo 41 (82%) pacientes do sexo feminino. Três (6%)

pacientes estavam em classe funcional II, 46 (92%) em III e um (2%) em IV. Quarenta e seis (92%) pacientes apresentavam ritmo sinusal e quatro (8%), fibrilação atrial. A área valvar mitral média foi de $0,9 \pm 0,2$ cm².

Resultados: Não houve mortalidade hospitalar. Ocorreram dois óbitos tardios, um relacionado à valvopatia. A sobrevida actuarial foi de $95,5 \pm 3,1\%$, sobrevida livre de reoperação, $62,3 \pm 11,8\%$, e sobrevida livre de tromboembolismo, $88,2 \pm 5,0\%$ em 18 anos. Não houve endocardite. O escore ecocardiográfico não teve influência significativa em reoperações na evolução tardia.

Conclusão: A comissurotomia mitral a céu aberto obteve resultados tardios excelentes nos pacientes com baixo escore ecocardiográfico.

Descritores: Cardiopatia Reumática. Estenose da Valva Mitral. Procedimentos Cirúrgicos Cardiovasculares.

INTRODUCTION

In 1984, Inoue et al. [1] introduced the valvuloplasty by mitral balloon catheter. The morphological evaluation of the mitral valve by Doppler echocardiography was standardized by the score established by Wilkins et al. [2] and Block et al. [3], who found an inverse correlation between the degree of success of valvuloplasty and value of the echocardiographic score. Valvuloplasty by balloon then began to be indicated in patients with echocardiographic score <8. Mitral commissurotomy was placed in the background in literature, as studies for the balloon valvuloplasty showed, in patients with scores <8, results similar to those of surgical series [4,5].

In 1994, Antunes et al. [6] presented a series with 100 selected patients with mitral stenosis selected by echocardiographic score undergoing open commissurotomy, with immediate results superior to balloon valvuloplasty. In our midst, Cardoso et al. [7] presented a study comparing open commissurotomy with balloon valvuloplasty, with advantage over the increase in valve area for the group submitted to commissurotomy.

There are several publications in the literature showing the long-term results of open mitral commissurotomy [8-11], but most of these works make no reference to the echocardiographic score.

The aim of this study was to analyze the late evolution of patients with rheumatic mitral stenosis with low echocardiographic score who underwent open mitral

commissurotomy and to identify variables that influence this development.

METHODS

Between January 1990 and August 1994, 50 patients with rheumatic mitral stenosis, symptomatic consecutively underwent open mitral commissurotomy in the Heart Institute, Hospital das Clínicas, School of Medicine, University of São Paulo (InCor-HC FMUSP). The protocol was approved by the Scientific Committee of the Heart Institute and the Research Ethics Committee of Hospital das Clínicas, FMUSP. All patients agreed to participate and signed the consent form.

Patients aged <60 years, functional class (FC) between II and IV and echocardiographic score <9. Patients with other surgical indication for heart disease, history of embolic event, an image suggestive of intracavitary thrombus or mitral regurgitation greater than mild at the transthoracic Doppler echocardiography were excluded.

The age ranged between 20 and 54 years, averaging 32.68 ± 8.29 years, 41 (82%) patients were female and nine (18%) were male. As for FC, three (6%) patients were in FC II, 46 (92%) in FC III and one (2%) in class IV. The electrocardiogram, six (92%) patients had sinus rhythm and four (8%), atrial fibrillation.

Doppler echocardiographic assessment in the mitral valve area ranged between 0.5 and 1.4 cm², with an average of 0.9 ± 0.2 cm². The mitral valve gradient ranged between

3.0 and 28.0 mmHg with a mean of 12.3 ± 5.6 mmHg. The fraction of left ventricular ejection fraction ranged between 0.57 and 0.86, averaging 0.72 ± 0.05 . In 42 (84%) patients, there was no mitral regurgitation, and eight (16%), mild mitral insufficiency. As for the echo score and the value was "4" in three (6%) patients, "5" in one (2%), "6" in 10 (20%), "7" in 12 (24%), "8" in 18 (36%) and "9" in six (12%).

The postoperative follow-up was conducted by hospital visits, telephone interviews or mailed questionnaires.

Data will be presented in accordance with the revised guidelines for presenting data and nomenclature [12]. The estimated probability of survival was calculated by the Kaplan-Meier. We also calculated the linearized rates of events.

The following Doppler echocardiographic variables were correlated with reintervention (reoperation or catheter-balloon valvuloplasty) of the mitral valve: the value of the score, the subvalvular component score, valve area before surgery and valve area in the immediate postoperative period. Univariate analysis for the determination of risk factors for reintervention on the mitral valve was performed using Fisher's exact test for qualitative factors. We adopted a significance level of 5%.

RESULTS

There was no hospital mortality.

In the immediate postoperative period, Doppler echocardiographic evaluation, the mitral valve area ranged between 1.7 and 3.6 cm², with an average of 2.5 ± 0.4 cm². The increase was statistically significant compared to preoperative values ($P < 0.0001$). The mitral valve gradient ranged between 2.0 and 15.0 mmHg with a mean of 5.8 ± 2.6 mmHg ($P < 0.0001$). In 32 (64%) patients, there was no mitral regurgitation in 16 (32%), mild regurgitation, and in two (4%), moderate impairment.

There were two late deaths. One patient died at 30 months of follow-up of respiratory complications of scleroderma, and one had sudden death at 94 months follow up. Patients were followed for 70-72 months/patients. The actuarial survival was $95.5 \pm 3.1\%$ at 216 months (Figure 1).

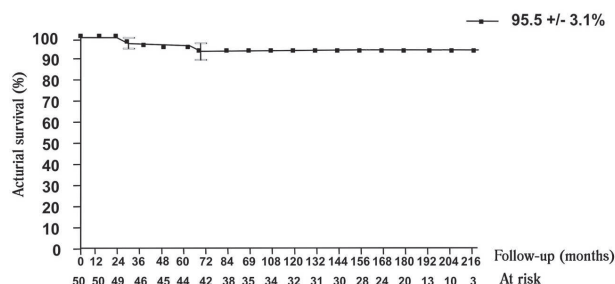


Fig 1 - Actuarial survival

In late clinical evaluation, 22 (50%) patients were in FC I, 14 (31.8%) in FC II and eight (18.2%) in FC III. There were nine reoperations in the long term. Five patients underwent mitral valve replacement by bioprosthesis, with an average of 101 months. Four patients underwent mitral recommissurotomy, with an average of 171 months. The linearized rate of reoperation was 1.5% /patient-year survival and freedom from reoperation was $62.3 \pm 11.8\%$ in 216 months (Figure 2).

There were two catheter balloon valvuloplasty in the late evolution at 62 and 95 months of follow-up.

There were no cases of endocarditis in this series.

There were three episodes of thromboembolism in the late follow-up. One patient, patient with chronic atrial fibrillation, ischemic stroke presented to two months postoperatively, another patient at 72 months and had a transient ischemic attack at 84 months. These events were associated with episodes of paroxysmal atrial fibrillation. The linearized rate of thromboembolism was 0.4% /patient-year and thromboembolism-free survival, $88.2 \pm 5.0\%$ in 216 months (Figure 3).

No variable echocardiographic study was associated with statistically significant reintervention on the mitral valve (Table 1).

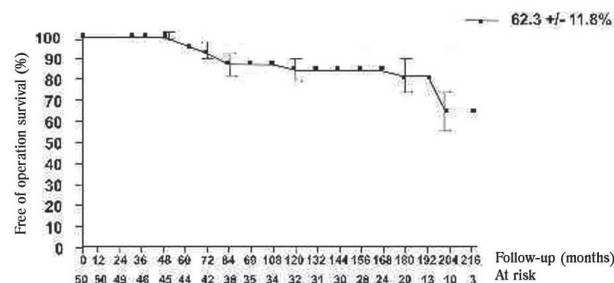


Fig 2 - Actuarial survival free from reoperation

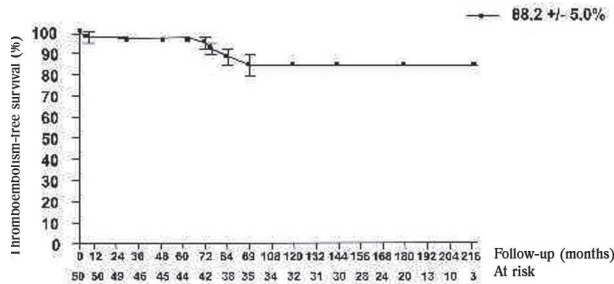


Fig 3 - Actuarial survival free from thromboembolism

Table 1. Univariate analysis for reintervention on the mitral valve.

Reintervention (n)	Yes	No	P
Echocardiographic score			
“4, 5 or 6” (14)	3	11	0.1821
“7, 8 or 9” (36)	8	28	
“Subvalvar” component of the score			
“1 or 2” (38)	9	29	0.2247
“3 or 4” (12)	2	10	
Mitral valve area before surgery			
< 1 (29)	8	21	0.3440
≥ 1 (21)	3	18	
Mitral valve area in the IPO			
< 2.42 (25)	4	21	0.5000
≥ 2.42 (25)	7	18	

IPO = Immediate post-operative

DISCUSSION

The introduction of balloon valvuloplasty has brought new knowledge and, with them, new stimulus to the discussion on the treatment of mitral stenosis. The interest generated by the less invasive procedure with a line of intense scientific research. However, this information deserves a more careful analysis, since in these studies about open mitral commissurotomy; patients are not selected by echocardiographic score.

Antunes et al. [6,13] used the echocardiographic score as selection criteria for mitral commissurotomy, obtaining satisfactory results. In 100 patients with scores <10, the average pre-operative mitral valve area of $1.04 \text{ cm}^2 \pm 0.23$ increased to $2.88 \pm 0.49 \text{ cm}^2$ in the immediate postoperative period. There was no hospital mortality. The same group was reassessed in late follow-up, with actuarial survival of 96% in 9 years, freedom from reoperation of 98% and free of valve-related events by 92%. These publications demonstrate the potential benefit of mitral commissurotomy indicated based on echocardiographic score.

Our study was conducted in this research line, in order to assess the results of this approach in our midst. The actuarial survival was similar in our study, 95.5%. The clinical evaluation, the authors reported that 93% of patients were in functional class I or II in the late postoperative period. In our series, 82% of the patients were in the same condition in the last assessment, but with a follow up longer. Herrera et al. [10] in a study with 18 years of follow-up like ours, showed 75.2% of actuarial survival, which demonstrates that in patients with low echocardiographic score, survival is greater.

The reoperation-free survival, our results were worse, with the caveat that our follow-up time was greater.

Discordant results may be observed in the literature. An example is the wide variation of linear rates of reoperation after surgery described by different authors. In a study of 100 patients, Housman et al. [14] described a linear rate of reoperation of 4.2% / patient-year. Vega et al. [15] in a similar study, reported rate of 0.4% / patient-year. These results suggest that, regardless of other variables, the authors whose best results have been more rigorous in the selection of intra-operative cases. In our series, the reoperation rate was 1.5% / patient-year, supported by selected patients with lower echocardiographic score.

Randomized studies comparing valvuloplasty and mitral commissurotomy in selected patients by means of echocardiographic scores are still scarce in the literature. Ben Farhat et al. [16] conducted a prospective, randomized study, comparing the evolution of 90 patients with rheumatic mitral stenosis with a score <8. Thirty patients underwent balloon valvuloplasty (group 1), 30, the open mitral commissurotomy (group 2), and 30, closed commissurotomy (group 3). In the immediate results, the mitral valve area increased from $0.9 \pm 0.2 \text{ cm}^2$ to $2.1 \pm 0.5 \text{ cm}^2$ in group 1, $0.9 \pm 0.2 \text{ cm}^2$ to $2.2 \pm 0.4 \text{ cm}^2$ group 2 and $0.9 \pm 0.2 \text{ cm}^2$ to $1.6 \pm 0.3 \text{ cm}^2$ in group 3. The actuarial survival free from reintervention on the mitral valve was 90% in group 1, 93% in group 2 and 50% in group 3, in seven years. Observed in this study a slight advantage over the commissurotomy valvuloplasty in all aspects.

In our country, Cardoso et al. [7] in a prospective, randomized study compared the results of open mitral commissurotomy with the balloon valvuloplasty in 88 patients with rheumatic mitral stenosis, with scores <9. The group submitted to balloon valvuloplasty had an increase in the average mitral valve area of $1.05 \pm 0.25 \text{ cm}^2$ to $2.18 \pm 0.40 \text{ cm}^2$, while the commissurotomy group had an increase of $0.98 \pm 0.21 \pm 0.46 \text{ cm}^2$ to 2.52 cm^2 . With a follow-up of 12 months, the difference in valve area between the groups was attenuated, and the mean mitral valve area after 12 months was $2.02 \pm 0.42 \text{ cm}^2$ for the valvuloplasty group and $2.13 \pm 0.32 \text{ cm}^2$ for the commissurotomy group. The occurrence of mitral valvuloplasty was higher in the group. After 5 years of follow up [17], these authors observed a reduction of mitral valve area in two groups, the greater the commissurotomy group ($P = 0.005$), with slight increase in mitral valve gradient in the two groups ($P = \text{NS}$).

Some other studies have linked components of the score the worst results with balloon valvuloplasty. The component of the subvalvular echo score was analyzed separately because the most important involvement of the subvalvular apparatus in some studies was associated with worse outcomes, both in closed and in the commissurotomies balloon valvuloplasty [18-20]. Arnoni et al. [11] refer to the importance of the treatment of subvalvular to obtain better results in the long term. In our

series, however, there is no long-term difference in the incidence of reoperation or reintervention in patients with higher scores and greater involvement of the subvalvular apparatus.

Choudhary et al. [21] used as a criterion for indication of open mitral commissurotomy, severity of disease in the subvalvular plane, presence of calcification, atrial thrombus, mild regurgitation, valve disease associated with another, and treatment failure or restenosis after closed commissurotomy or balloon valvuloplasty. These findings seem relevant, since these two methods are not acting in subvalvular level and there is potential benefit in proceeding to papillectomy important in cases with involvement of the subvalvular apparatus.

We believe that the open mitral commissurotomy has advantages over the valvuloplasty balloon catheter [22,23], with lower incidence of postoperative complications and clinical outcomes consistent long-term, and the adoption of minimally invasive techniques [24,25], we can further improve these results and provide a treatment of the mitral valve with quality and aesthetic benefits.

CONCLUSIONS

Patients with mitral stenosis with low echocardiographic score underwent open mitral commissurotomy showed clinical late.

REFERENCES

1. Inoue K, Owaki T, Nakamura T, Kitamura F, Miyamoto N. Clinical application of transvenous mitral commissurotomy by a new balloon catheter. *J Thorac Cardiovasc Surg.* 1984;87(3):394-402.
2. Wilkins GT, Weyman AE, Abascal VM, Block PC, Palacios IF. Percutaneous balloon dilatation of the mitral valve: an analysis of echocardiographic variables related to outcome and the mechanism of dilatation. *Br Heart J.* 1988;60(4):299-308.
3. Block PC, Tuzcu EM, Palacios IF. Percutaneous mitral balloon valvotomy. *Cardiol Clin.* 1991;9(2):271-87.
4. Palacios IF. Percutaneous mitral balloon valvotomy for patients with mitral stenosis. *Curr Opin Cardiol.* 1994;9(2):164-75.
5. Cohen DJ, Kuntz RE, Gordon SP, Piana RN, Safian RD, McKay RG, et al. Predictors of long-term outcome after percutaneous balloon mitral valvuloplasty. *N Engl J Med.* 1992;327(19):1329-35.
6. Antunes MJ, Nascimento J, Andrade CM, Fernandes LE. Open mitral commissurotomy: a better procedure? *J Heart Valve Dis.* 1994;3(1):88-92.
7. Cardoso LF, Rati MAN, Pomerantzeff PMA, Medeiros CCJ, Tarasoutchi F, Rossi EG, et al. Avaliação comparativa entre valvoplastia percutânea e comissurotomia a céu aberto na estenose mitral. *Arq Bras Cardiol.* 1998;70(6):415-21.
8. Smith WM, Neutze JM, Barrat-Boyes BG, Lowe JB. Open mitral valvotomy. Effect of preoperative factors on result. *J Thorac Cardiovasc Surg.* 1981;82(5):738-51.
9. Cohn LH, Allred EN, Cohn LA, Disesa VJ, Shemin RJ, Collins JJ Jr. Long-term results of open mitral valve reconstruction for mitral stenosis. *Am J Cardiol.* 1985;55(6):731-4.
10. Herrera JM, Veja JL, Bernal JM, Rabasa JM, Revuelta JM. Open mitral commissurotomy: fourteen- to eighteen-year follow-up clinical study. *Ann Thorac Surg.* 1993;55(3):641-5.
11. Arnoni AS, Couto WJ, Dinkhuysen JJ, Chaccor P, Meneghelo ZM, Souza LCB, et al. Comissurotomia mitral: como evoluem os pacientes a longo prazo? *Rev Bras Cir Cardiovasc.* 1990;5(2):106-12.
12. Edmunds LH Jr, Clark RE, Cohn LH, Grunkemeier GL, Miller DC, Weisel RD. Guidelines for reporting morbidity and mortality after cardiac valvular operations. Ad Hoc Liaison Committee for Standardizing Definitions of Prosthetic Heart Valve Morbidity of the American Association for Thoracic Surgery and The Society of Thoracic Surgeons. *J Thorac Cardiovasc Surg.* 1996;112(3):708-11.
13. Antunes MJ, Vieira H, Ferrão de Oliveira J. Open mitral commissurotomy: the 'golden standard'. *J Heart Valve Dis.* 2000;9(4):472-7.
14. Housman LB, Bonchek L, Lambert L, Grunkemeier G, Starr A. Prognosis of patients after open mitral commissurotomy. Actuarial analysis of late results in 100 patients. *J Thorac Cardiovasc Surg.* 1977;73(5):742-5.
15. Vega JL, Fleitas M, Martinez R, Gallo JI, Gutierrez JA, Colman T, et al. Open mitral commissurotomy. *Ann Thorac Surg.* 1981;31(3):266-70.
16. Been Farhat M, Ayari M, Maatouk F, Betbout F, Gamra H, Jarra M, et al. Percutaneous balloon versus surgical closed and open mitral commissurotomy: seven-year follow-up results of a randomized trial. *Circulation.* 1998;97(3):245-50.

17. Cardoso LF, Grinberg M, Pomerantzeff PM, Rati MA, Medeiros CC, Vieira ML, et al. Comparison of open commissurotomy and balloon valvuloplasty in mitral stenosis. A five-year follow-up. *Arq Bras Cardiol.* 2004;83(3):248-52.
18. Medeiros CCJ, Moraes AV, Cardoso LF, Rati MAN, Abenmsur H, Azevedo JG, et al. São os componentes do aparelho valvar mitral de mesmo valor preditivo na valvoplastia mitral por cateter balão? Estudo ecodopplercardiográfico. *Arq Bras Cardiol.* 1991;57(1):17-20.
19. Kirklin JW. Percutaneous balloon versus surgical closed commissurotomy for mitral stenosis. *Circulation.* 1991;83(4):1450-1.
20. Borges IP, Peixoto EC, Peixoto RT, Oliveira PS, Salles Netto M, Labrunie M, et al. Comparação da evolução a longo prazo da valvoplastia mitral percutânea por balão com a técnica de Inoue versus a do balão único. Análise dos fatores de risco para óbito e eventos maiores. *Arq Bras Cardiol.* 2007;89(1):52-9.
21. Choudhary SK, Dhareshwar J, Govil A, Airan B, Kumar AS. Open mitral commissurotomy in current era: indications, technique, and results. *Ann Thorac Surg.* 2003;75(1):41-6.
22. Pomerantzeff PMA, Brandão CMA, Faber CM, Grinberg M, Cardoso LF, Tarasoutchi F, et al. Plástica da valva mitral em portadores de febre reumática. *Rev Bras Cir Cardiovasc.* 1998;13(3):211-5.
23. Pomerantzeff PMA, Brandão CMA, Faber CN, Fonseca MH, Puig LB, Grinberg M, et al. Plástica da valva mitral: resultados aos 17 anos de experiência. *Rev Bras Cir Cardiovasc.* 1999;14(3):185-90.
24. Cohn LH, Soltesz EG. The evolution of mitral valve surgery: 1902-2002. *Am Heart Hosp J.* 2003;1(1):40-6.
25. Poffo R, Bonin M, Selbach RA, Pilatti M. Troca valvar mitral minimamente invasiva videoassistida. *Rev Bras Cir Cardiovasc.* 2007;22(4):491-4.