

# Endovascular repair of ascending aorta and coronary stent implantation

## *Correção endovascular da aorta ascendente associada a implante de stents coronários*

Eduardo Keller Saadi<sup>1</sup>, Leandro de Moura<sup>2</sup>, Alexandre Zago<sup>3</sup>, Alcides Zago<sup>4</sup>

DOI: 10.5935/1678-9741.20110025

RBCCV 44205-1306

**Endovascular treatment of ascending aorta pseudoaneurysms with coronary stents implantation at the same procedure was feasible, although longer followup is necessary.**

**Descriptors: Aorta. Endovascular procedures. Coronary artery bypass. Stents.**

### INTRODUCTION

Endovascular treatment of thoracic aortic diseases has progressed rapidly and led to a reduction in morbidity and mortality when compared to conventional surgery. The procedure is well established to treat descending thoracic and abdominal aorta pathologies [1-5]. However, only a few studies have reported on the treatment of lesions in the ascending aorta (AA) [6,7]. We describe the lifesaving implantation of stent grafts together with percutaneous coronary interventions (PCI) in two patients with AA pseudoaneurysm and coronary artery disease who had previously undergone coronary artery bypass grafting (CABG) and had mediastinitis.

### CASEREPORTS

Patient 1 was a 56-year-old woman who had undergone CABG in another center 6 months earlier. She had a left internal mammary artery (LIMA) inserted into the left

**Tratamento endovascular de pseudoaneurismas da aorta ascendente com o implante de stents coronários no mesmo procedimento foi factível, embora seja necessário um maior seguimento.**

**Descritores: Aorta. Procedimentos endovasculares. Ponte de artéria coronária. Stents.**

anterior descending (LAD) artery and two vein grafts, one to the right coronary artery (RCA) and the other to the circumflex artery. During hospitalization she developed mediastinitis and was treated with antibiotics and debridement that was repeated seven times. Five months after the operation, the sternal wound bled, but bleeding stopped after manual compression. A month later she had again severe bleeding through the sternum and shock, and was transferred to our hospital under manual compression of the wound. A computed tomography (CT) scan obtained 2 days before admission showed a small pseudoaneurysm in the mid part of the AA (Figure 1A). The LIMA was patent, but the vein grafts were occluded.

We decided to proceed with urgent endovascular repair. The AA diameter was 29 mm and the distance between the coronary ostia and the brachiocephalic trunk was 8.5 cm. We used two Gore-Tex™ (W. L. Gore and Associates, Flagstaff, AZ) abdominal aortic cuff extensions (31.5 mm in diameter and 4.5 cm long) and 3 stents in the RCA (Figures 1B-C). PCI was performed via the right femoral artery, and

Work performed at Hospital de Clínicas de Porto Alegre (HCPA), Universidade Federal do Rio Grande do Sul (UFRGS), Porto Alegre, RS, Brazil.

#### Correspondence

Eduardo Keller Saadi. Rua Ramiro Barcelos, 2350 – Porto Alegre, RS, Brazil – CEP 90035-903

E-mail: esaadi@terra.com.br

1. PhD; Professor of Faculdade de Medicina-Cirurgia Cardiovascular/ Universidade Federal do Rio Grande do Sul (UFRGS), Porto Alegre, RS, Brazil.
2. Graduating in Medicine; Physician of Hospital de Clínicas de Porto Alegre, Porto Alegre, RS, Brazil.
3. PhD; Professor of the post-graduation in Cardiology of Universidade Federal do Rio Grande do Sul (UFRGS), Porto Alegre, RS, Brazil.
4. PhD; Full Professor of Faculdade de Medicina da Universidade Federal do Rio Grande do Sul (UFRGS), Porto Alegre, RS, Brazil.

Article received on May 6<sup>th</sup>, 2011  
Article accepted on June 20<sup>th</sup>, 2011

the endografts were inserted via the right axillary artery. The patient was administered intravenous antibiotics and antiplatelet drugs for 4 weeks. Bleeding stopped, and a postoperative CT scan showed that the result was good with no endoleaks (Figure 1D).

Patient 2, a 74-year-old man who had undergone CABG (LIMA to the LAD), a vein graft to an occluded right coronary, and a vein graft to the circumflex artery) 6 years earlier, developed severe chest pain. During investigation, a pseudoaneurysm contiguous to the vein graft to the RAC was detected. All the grafts were patent; the patient had a tight left main coronary artery stenosis and a lesion in the circumflex artery. The AA diameter was 38 mm, and the distance between the coronary ostia and the

brachiocephalic trunk was 10.5 cm. This patient underwent PCI (two drug eluting stents in the left main artery and one in the circumflex artery), and a Gore-Tex™ TAG endoprosthesis (40 x 100) was implanted through the left femoral artery (Figures 2A-D). We left a “safety net” stiff guide wire from the right carotid artery to the descending aorta in case the endograft obstructed the brachiocephalic trunk origin.

A type 1a endoleak is currently under evaluation using CT scans. The prosthesis was not properly accommodated in the proximal segment of the AA, mainly in the portion close to the left coronary ostia (Figures 2A-D). The patient received antibiotics, aspirin and clopidogrel and was discharged 4 days after the procedure.

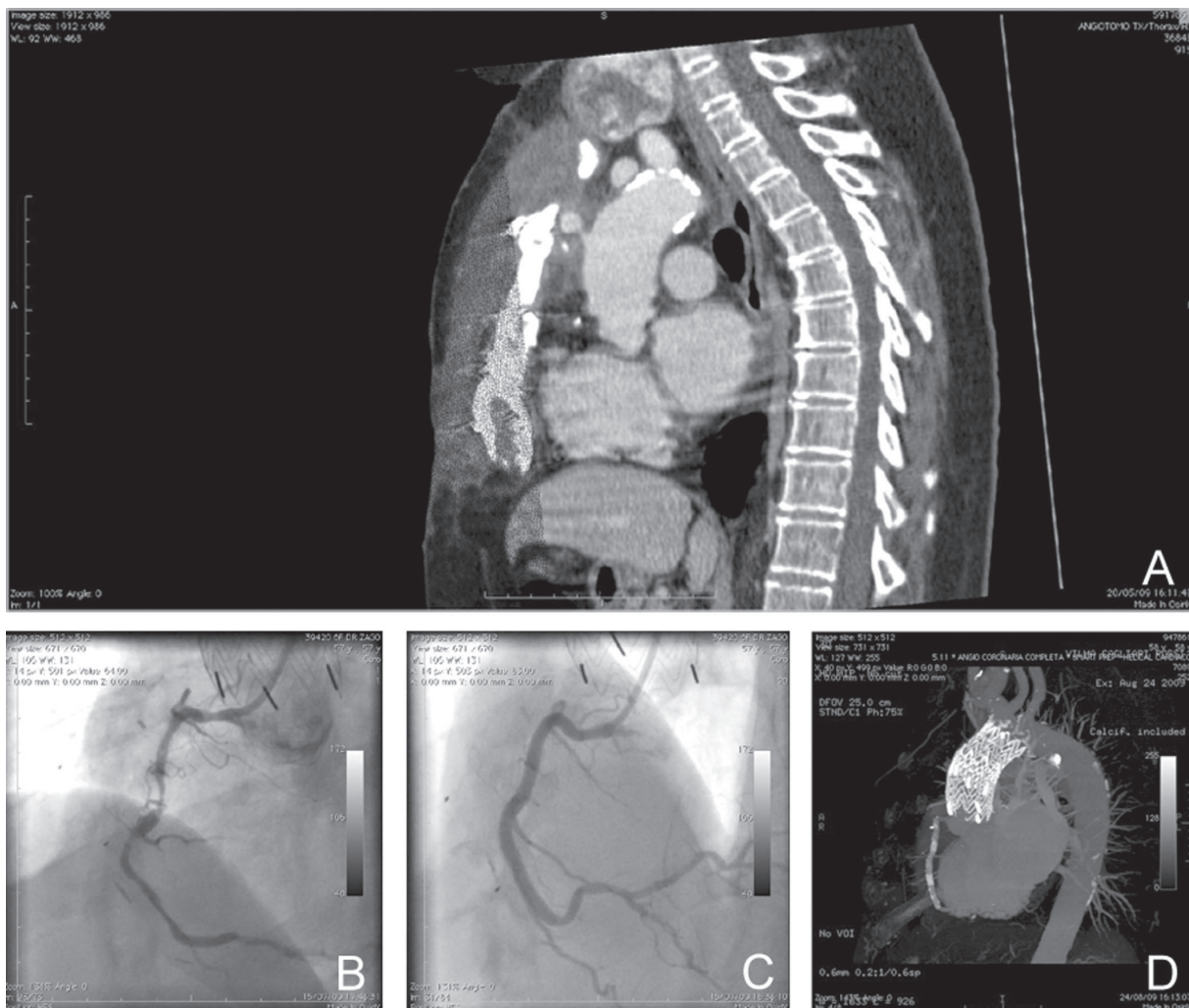
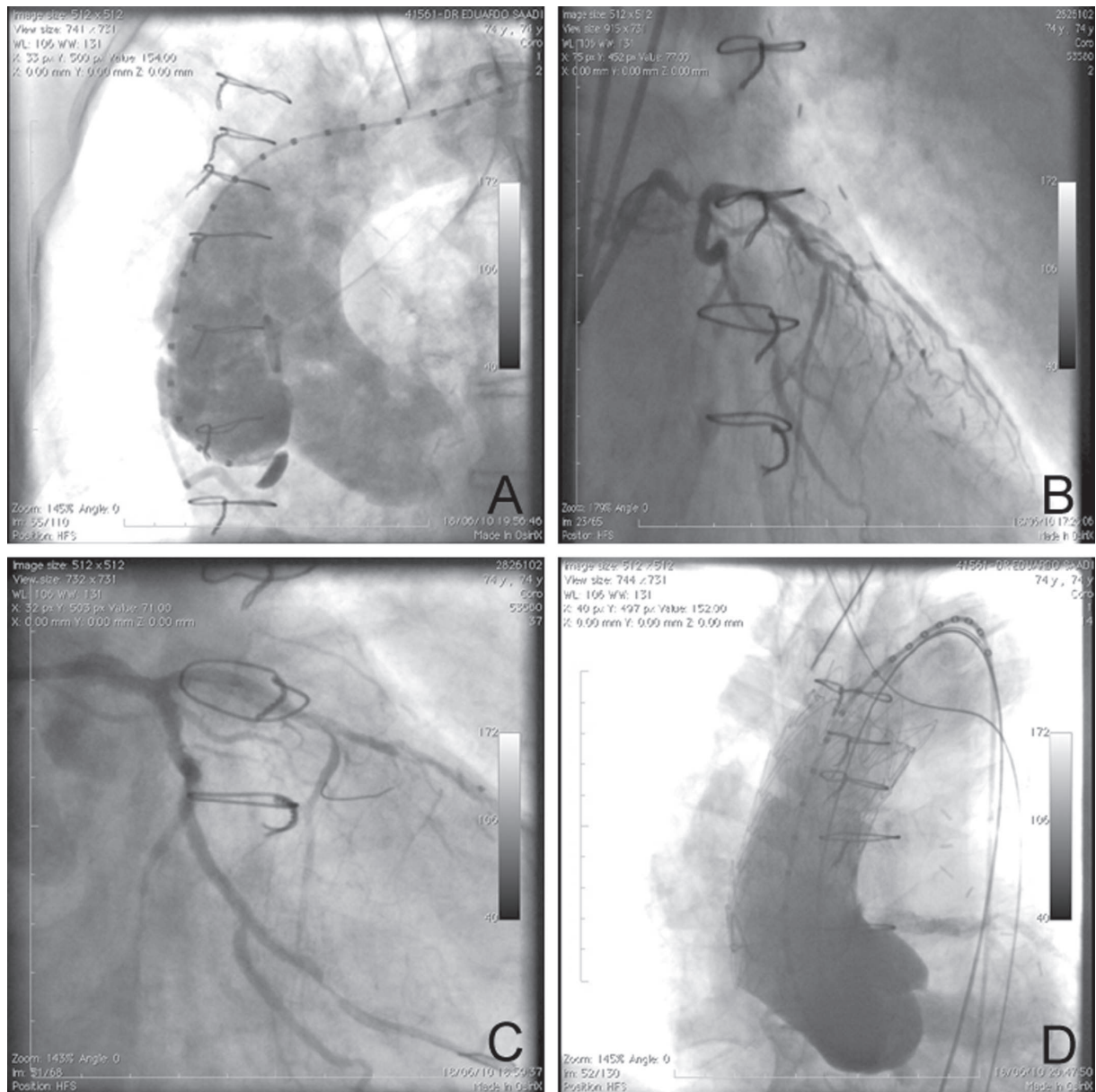


Fig. 1 – A: Pseudoaneurysm of ascending aorta. B: RCA lesions. C: Three stents implanted in RCA. D: Postoperative CT shows that three stents and two extension cuffs are well positioned. CT: computed tomography, RCA: right coronary artery



*Fig. 2 – A: Aortography shows ascending aorta pseudoaneurysm. B: Severe stenosis of left main artery and lesion in circumflex artery. C: Two drug eluting stents implanted in left main artery and one in circumflex artery. D: Final aortogram shows Gore - Tex™ (W. L. Gore and Associates, Flagstaff, AZ)TAG endoprosthesis after deployment*

## DISCUSSION

Mediastinitis with pseudoaneurysm formation is a dreadful complication of myocardial revascularization. Bleeding usually leads to death unless there is prompt intervention. Conventional surgery, the criterion standard for treatment in these situations, consists of replacement of the AA with a Dacron graft or homograft with

extracorporeal circulation. The LIMA and other vein grafts are usually patent, and the pseudoaneurysm may be adherent to the sternum. The procedure is, therefore, associated with high mortality and morbidity rates.

Currently available aortic endografts have limitations to be used in the AA and aortic arch. Devices developed for the descending thoracic aorta are too long to be deployed between the coronary arteries and the brachiocephalic trunk [8-10].

In patient 2 the distance between the left coronary artery and the brachiocephalic trunk was 10.5 cm, the aortic diameter, 38 mm, and the distance between left common femoral artery and the aortic valve, 90 cm. In this particular case, a normal thoracic endograft (40 mm X 100 mm; Gore-Tex™ - TAG) was inserted via the left femoral artery using the conventional 100-cm delivery system. The patient had three patent grafts: the LIMA inserted into the anterior interventricular (LAD) artery, a vein graft to the right artery, and a vein graft to the circumflex artery. As we would have to cover both vein grafts with the stent graft in the AA, a PCI was performed in the left main artery (two drug eluting stents) and in the circumflex artery. The vein graft to the RCA was simply closed with the endoprosthesis. All the procedures were carried out in one step.

Abdominal aortic delivery systems are too short to reach the AA from the femoral artery, and the diameters are too narrow to cope with a larger AA. In patient 1, the aortic diameter was 28 mm and the distance between the coronary ostia and the brachiocephalic trunk, 80 mm; therefore, we decided to insert two abdominal aorta extension cuffs (Gore-Tex™; 31.5 mm in diameter and 4.5 cm long each) via the right axillary artery, a technique that has been previously described [11]. In this patient, only the LIMA was patent to the LAD artery; the vein graft to the RCA was occluded, and the RCA had three points of critical stenosis. Therefore, three stents were implanted in this vessel.

Endovascular treatment of ascending aorta pseudoaneurysms with coronary stents implantation at the same procedure was feasible, although longer followup is necessary.

To our knowledge these are the first two cases in which the AA has been treated using endovascular surgery together with coronary stent implantation.

## CONCLUSION

Endovascular treatment of AA pseudoaneurysms following CABG is feasible. Concomitant PCI was safe and effective. Further studies should be conducted to evaluate this novel technique.

## REFERENCES

1. Saadi EK. É possível formar um cirurgião endovascular? Rev Bras Cir Cardiovasc. 2007;22(1):III-IV.
2. Dias RR, Judas G, Oliveira MAP, Malbouisson LMS, Fiorelli AI, Stolf NAG. Há espaço para o tratamento endovascular nas dissecções crônicas da aorta descendente? Rev Bras Cir Cardiovasc. 2007;22(4):441-7.
3. Fioranelli A, Razuk Filho A, Castelli Júnior V, Karakhanian W, Godoy JMP, Caffaro RA. Mortalidade no tratamento endovascular nas dissecções aórticas tipo B. Rev Bras Cir Cardiovasc. 2011;26(2):250-7.
4. Koning GG, Vallabhaneni S, Marrewijk CJV, Leurs LJ, Laheij RJ, Buth J. Mortalidade relacionada ao tratamento endovascular do aneurisma da aorta abdominal com o uso dos modelos revisados. Rev Bras Cir Cardiovasc. 2007;22(1):7-14.
5. Saadi EK. Tratamento endovascular dos aneurismas da aorta torácica: passo a passo. Rev Bras Cir Cardiovasc. 2009;24(2):45-8.
6. Wang ZG, Massimo CG, Li M, Pan SL, Zhang HK, Jing W, et al. Deployment of endograft in the ascending aorta to reverse type A aortic dissection. Asian J Surg. 2003;26(2):117-9.
7. Uchida K, Imoto K, Yanagi H, Machida D, Okiyama M, Yasuda S, et al. Endovascular repair of ascending aortic rupture: effectiveness of a fenestrated stent-graft. J Endovasc Ther. 2010;17(3):395-8.
8. Chuter TA. Endovascular repair in the ascending aorta: stretching the limits of current technology. J Endovasc Ther. 2007;14(6):799-800.
9. Moon MC, Morales JP, Greenberg RK. The aortic arch and ascending aorta: are they within the endovascular realm? Semin Vasc Surg. 2007;20(2):97-107.
10. Almeida RM, Leal JC, Saadi EK, Braille DM, Rocha AS, Volpiani G, et al. Thoracic endovascular aortic repair - a Brazilian experience in 255 patients over a period of 112 months. Interact Cardiovasc Thorac Surg. 2009;8(5):524-8.
11. Saadi EK, Dussin LH, Moura L, Machado AS. The axillary artery: a new approach for endovascular treatment of thoracic aortic diseases. Interact Cardiovasc Thorac Surg. 2010;11(5):617-9.