

Terminal ischemic cardiomyopathy associated with complication of stenting in the treatment of acute myocardial infarction

Cardiomiopatia isquêmica terminal associada à complicação do uso de stent no tratamento de infarto agudo do miocárdio

Renato Braulio¹, Cláudio Léo Gelape², Geraldo Brasileiro Filho³, Maria da Consolação Vieira Moreira⁴

DOI: 10.5935/1678-9741.20110026

RBCCV 44205-1307

A serious complication such as dissection of the left main coronary artery, with significant reduction in coronary blood flow by the true lumen, requires quick action. Therefore, the immediate choice of stent with appropriate length and size to treat the complication is necessary.

Descriptors: Stents. Heart Transplantation. Myocardial Ischemia.

Uma complicação grave, como a dissecação do tronco de coronária esquerda, com redução relevante do fluxo sanguíneo coronário pela luz verdadeira, requer ação rápida. Diante disso, a escolha imediata do stent no comprimento e calibre adequados para tratar a complicação se faz necessária.

Descritores: Stents. Transplante de Coração. Isquemia Miocárdica.

CASE STUDY

EDFS Patient, female, 60 years, original from Pernambuco. In January 2009, when she was home, she had an episode of severe chest pain accompanied by sweating and general malaise. She sought the local emergency care unit, where she was diagnosed with acute myocardial infarction (AMI) with supra-ST segment elevation. Also during the first visit the patient had an episode of cardiac arrest, being promptly revived, evolving without neurological deficit.

Transferred to a hospital of high complexity, after 12 hours of the onset of AMI, she underwent angioplasty of the LAD artery. During the procedure it was performed dissection of the left coronary artery trunk, thus, opting for stenting in the trunk.

The patient developed severe ischemic cardiomyopathy and heart failure class IV (NYHA), refractory to optimal medical treatment and without possibility of revascularization or geometric reconstruction of the left ventricle. She moved to Belo Horizonte-MG, she sought for

1. Master, Chief Resident in Cardiovascular Surgery, Hospital das Clínicas.
2. Ph.D., Professor, Department of Surgery, School of Medicine, UFMG. Coordinator of the Department of Cardiology and Cardiovascular Surgery, Hospital das Clínicas.
3. PhD, Professor, Department of Pathology, School of Medicine, UFMG).
4. PhD, Associate Professor, Department of Clinical Medicine, School of Medicine, UFMG, Coordinator of the Heart Transplant Team, Hospital das Clínicas.

Study conducted at Hospital das Clínicas, UFMG, Belo Horizonte, MG, Brazil.

Correspondence address:

Renato Braulio. Avenida Professor Alfredo Balena, 110, 5º andar - Cardiologia. Zip Code: 30130-100 - Belo Horizonte - MG - Brazil. E-mail: renatobraulio1@ig.com.br

Abbreviations and acronyms: AMI, acute myocardial infarction, NYHA: New York Heart Association, AMI: acute myocardial infarction, LMCA: left main coronary artery

Article received on April 18th, 2011
Article accepted on September 4th, 2011

the ambulatory of cardiac insufficiency of the UFMG, where she was then slated for heart transplantation at the HC-UFMG in August 2009. In April 2010, she underwent successful heart transplantation, progressing uneventfully and was discharged after 14 days of operation.

PRE-TRANSPLANTION ELECTROCARDIOGRAM

Sinus rhythm, HR: 72 bpm, anteroseptal inactivity.

PRE-TRANSPLANTION RADIOGRAPHY

Increased heart size and mild pulmonary congestion

PRE-TRANSPLANTATION CORONARY ANGIOGRAPHY AND LEFT VENTRICULOGRAPHY (CATE)

Ostial occlusion of the circumflex artery and proximal subocclusion of left anterior descending artery, with extensive antero-apical akinesia to ventriculography.

PRE-TRANSPLANTION

ECODOPPLERCARDIOGRAM

Severe left ventricular dysfunction with apical aneurysm, anterior akinesia, apical, septal and severe mitral regurgitation, left ventricular ejection fraction: 19%, left ventricle during systole: 55 mm, left ventricle during diastole, 70 mm, left atrium 45 mm, pulmonary artery systolic pressure: 48 mmHg.

MYOCARDIAL SCINTILOGRAPHY WITH THALLIUM

Absence of myocardial viability in the anteroseptal and lateral regions.

OPERATION

Removal of the donor heart

Donor 35 years, male, 70 kg, the victim of traumatic brain injury after three days of internment without signs of

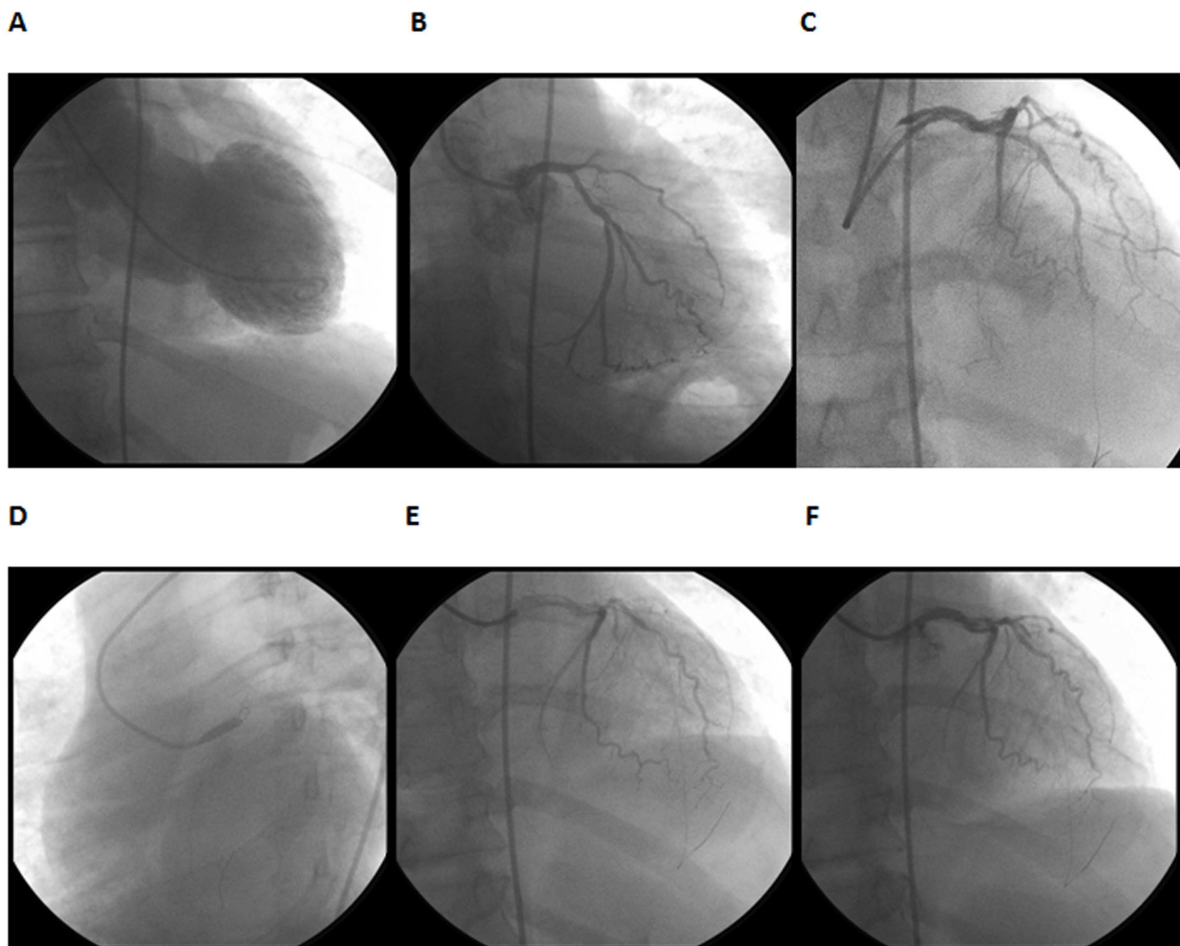


Fig. 1 - A sequence of photos of the CATE shows: A – a left ventricle widely dilated and extensively akinetic in anteroseptal apical wall; B-coronary angiography before the intervention, with occlusion of the LAD at the origin, C-the time of dissection of the left coronary artery trunk, D- the time of inflation of the balloon dilator, E- shows the stent-trunk coming to the circumflex artery, F- final coronary angiography

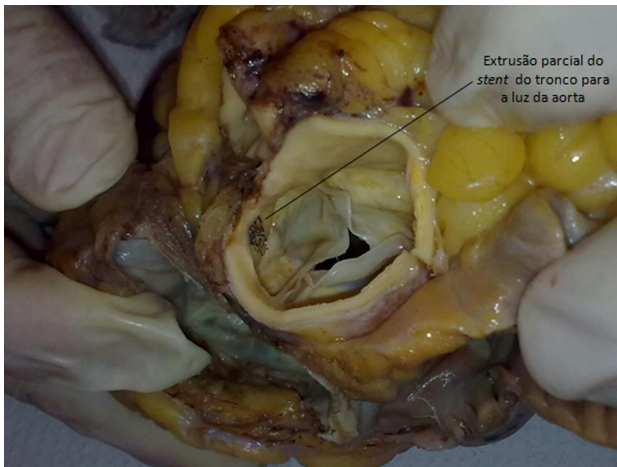


Fig. 2 - partial extrusion of the stent implanted in the left coronary artery trunk into the aortic lumen, evident during pathological examination

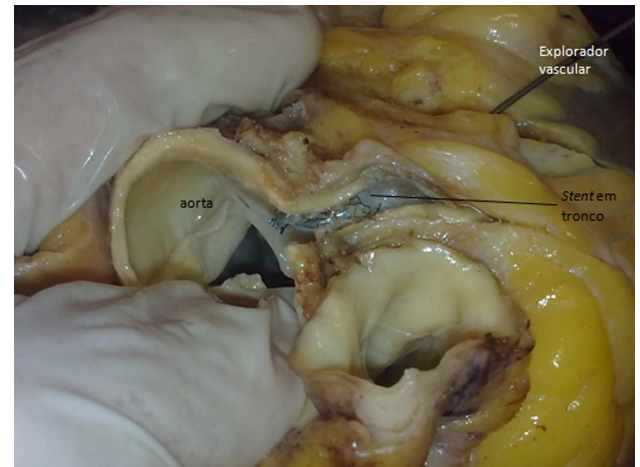


Fig. 3 - During necropsy the circumflex artery was sectioned at the proximal third, where it was introduced a vascular explorer toward the left coronary artery trunk. The explorer proceeds freely toward the epithelialized stent mesh, which occludes the ostium of the circumflex artery

infection, FiO₂ 40%, and using noradrenalin to 0.03 mcg / kg/min.

Median sternotomy, release and cava cerclage, systemic heparinization (4 mg / kg), drainage of the left atrium, aortic clamping, cardioplegia with Celsior® ice solution at 4°C, topical cardioplegia with cold saline solution, cardiectomy with preservation for transportation at 4°C.

Implantation of the donor heart at the receiver

Median sternotomy and release of cava cerclage, systemic heparinization (4 mg/kg), entered into cardiopulmonary bypass (CPB) with cooling at 32°C, aortic clamping, cardiectomy.

Implantation of the donor heart by the bicaval technique [3], maintaining cardioplegia with Celsior® ice solution every 20 minutes, following left atrial anastomosis, inferior vena cava, pulmonary artery, aorta, aortic declamping and anastomosis in the superior vena cava. Removal of CPB in the use of dobutamine and sodium nitroprusside uneventfully. Organ ischemia time of 98 minutes, CPB time and aortic clamping 90 and 73 minutes respectively.

The patient was extubated at the sixth hour after surgery, being discharged from the ICU after 03 days and discharged from hospital on the 14th day postoperatively, after the second endomyocardial biopsy. After 30 days of transplantation the patient was in functional class I during follow-up in the Transplant Clinic. She had complications as traumatic fracture of the calcaneus and was operated successfully.

Anatomic Pathologic Diagnosis

Macroscopic examination of the explanted heart showed that the stent implanted in the left coronary artery trunk

(LCA) suffered partial extrusion into the lumen of the aorta and blocked the left circumflex artery (CX) (Figs. 1-3). The heart had a bulged edge and formed by the left ventricle. On sectioning, there was moderate dilatation of the left ventricular cavity, especially at the tip and the anteroseptal region. On the anterior wall of the left ventricle and the anterior interventricular septum it was found extensive old transmural healed myocardial infarction. In the trunk of the left coronary artery and in the anterior descending and circumflex arteries, atheromatous plaques of varied volume were seen, blocking up to about 80% of the vascular lumen, in the right coronary artery the atherosclerotic obstruction reached up to 20% of the vessel lumen.

DISCUSSION

The severe acute coronary dissection is the most common cause of acute occlusion after coronary angioplasty, occurring in 20 to 40% of cases [1,4]. The primary coronary angioplasty procedure is itself a rescue, always done on an emergency basis, where not always an optimal therapy is possible. A serious complication such as dissection of the left main coronary artery, with significant reduction in coronary blood flow by the true lumen, requires quick action by the intervention. Therefore, the immediate choice of stent length and size appropriate to treat the complication is necessary.

In our case, we observe a mismatch of the length of the stent in relation to the treated coronary trunk. The distal end of the stent was implanted after the ostium of the left anterior descending artery and the proximal end about 5 mm extrusa of the trunk into the aortic lumen. However, the

mesh of the stent covered the ostium of the circumflex artery. Nevertheless, it is likely that initially a flow had occurred to the circumflex through the mesh of the stent. However, later it occurred the epithelialization of the mesh of the stent, leading to complete occlusion of the circumflex artery, as it can be seen in pathological examination of the explanted heart (Fig. 3). Therefore, one can expect that the opening of the circumflex artery by the technique of “kissing balloon”, with the passage of a second guide through the mesh of the stent to access the circumflex, promoting the dilation balloon with two simultaneous trunk/DA and circumflex or even coronary artery bypass surgery could have alleviated the complication here.

Despite the scant literature on complications after stent implantation in cases of iatrogenic dissection of left coronary artery trunk, we believe that ischemic cardiomyopathy refractory may enter the list of complications of such treatment and should be considered and prevented during the procedures.

REFERENCES

1. Breda JR, Breda AS, Pires AC. Operative treatment after iatrogenic left main dissection. *Rev Bras Cir Cardiovasc*. 2008;23(2):268-71.
2. McArdle H, Bhandari M, Kovac J. Emergency coronary stenting of unprotected critical left main coronary artery stenosis in acute myocardial infarction and cardiogenic shock. *Heart*. 2003;89(9):e24.
3. Chacur P, Dinkhuysen JJ, Nina VJS, Abdulmassih NC, Arnoni AS, Souza LCB, et al. Transplante cardíaco ortotópico pela técnica bicaval. *Rev Bras Cir Cardiovasc*. 1997;12(2):145-52.
4. Salgueiro S, Silva AD, Tofano RJ, Costa VC, Pizarro K, Salman AA, et al. Percutaneous stent implantation for treating multivessel coronary disease in patients with and without involvement of the proximal segment of the anterior descending coronary artery. *Arq Bras Cardiol*. 2002;79(1):25-34.