

# Conservative surgical management of mitral insufficiency: an alternative approach

*Tratamento cirúrgico conservador da insuficiência mitral: uma abordagem alternativa*

Francisco Gregori Junior<sup>1</sup>

DOI: 10.5935/1678-9741.20120049

RBCCV 44205-1386

## Abstract

Mitral valve insufficiency is frequently the result of elongated or ruptured chordae tendineae. Several techniques have been described for its correction. However, when there is a severe elongation or rupture of the chordae, the most widely accepted treatment option has been valve replacement. The best long-term outcomes observed in conservative surgeries led us to choose this procedure rather than the correction of mitral valve insufficiency. We described three techniques for correction of mitral prolapse due to elongated and/or ruptured chordae tendineae. In addition, we developed mold pre built bovine pericardial chords (Braile-Gregori prosthesis) for chordae replacement. Finally, since 1987, the rigid prosthetic semicircular ring (Gregori-Braile ring) has been consistently used in our centre for correction of the posterior dilation of mitral annulus preferably in its portion close to the posteromedial commissure.

**Descriptors:** Mitral valve/surgery. Mitral valve insufficiency.

## Resumo

A insuficiência mitral é frequentemente resultado do alongamento ou ruptura das cordas tendíneas. Várias técnicas foram descritas para sua correção. Entretanto, quando o comprometimento das cordas é mais intenso, a substituição valvar tem sido mais usualmente empregada. Os bons resultados a longo prazo observados na cirurgia conservadora têm nos levado a eleger esse procedimento como prioridade. Três técnicas foram por nós desenvolvidas para correção de alongamento e/ou ruptura de cordas tendíneas. Além disso, desenvolvemos uma prótese de pericárdio bovino para a substituição de cordas (prótese Braile-Gregori). Finalmente, desde 1987 empregamos o anel rígido semicircular (anel Gregori-Braile) para a correção do alongamento posterior do anel mitral, com ênfase na sua porção junto à comissura pósteromedial.

**Descritores:** Valva mitral/cirurgia. Insuficiência da valva mitral.

## INTRODUCTION

Conservative management of mitral insufficiency is an alternative technique with attractive features [1-5]. Among the many advocates of valve repair, Alain Carpentier is the best-known [6]. His techniques include a combination of ring annuloplasty, resection of segments of valve leaflets, and shortening, transposition and sectioning of chordae. However, despite this repertoire of repair maneuvers,

replacement of the mitral valve is the most common method used for patients with mitral insufficiency.

Mitral insufficiency, defined as blood regurgitation from the left ventricle to the left atrium through the valve, is a situation predisposing to left ventricular dysfunction, increase of the left atrium, and atrial arrhythmias, regardless of the etiology. Mitral insufficiency is a common feature in rheumatic disease and fibroelastic degeneration. Mitral valve prolapse identified by redundancy of the anterior

1. Head Professor. Cardiac Surgery Division, University of Londrina - Paraná School of Medicine, Londrina, SP, Brazil.

This study was carried out at the Cardiac Surgery Division, University of Londrina - Paraná School of Medicine, Londrina, SP, Brazil.

Correspondence address:  
Francisco Gregori Junior  
Rua Paes Leme, 1264 – Sala 701  
Londrina, PR, Brazil – CEP 86010-520  
E-mail: circardiaca@sercomtel.com.br

Article received on April 12<sup>th</sup>, 2012

Article accepted on June 6<sup>th</sup>, 2012

and/or posterior leaflet, papillary muscle dysfunction, and chordae tendineae elongation or rupture may evolve to mitral insufficiency. Mitral valvuloplasty is an elective procedure for repair of mitral insufficiency, with better results than mitral valve replacement [7].

We have employed mitral reconstructive surgery in our Service since 1979, according to Carpentier techniques. We introduced new alternative techniques that have been used in parallel to those traditional procedures.

#### REPAIR OF ELONGATED CHORDAE TENDINEAE

In 1989, we introduced a new technique for shortening of elongated chordae tendineae [8]. It is particularly suitable for shortening the chordae tendineae in patients in whom the papillary muscles are either thin or deeper than usual. The shortening performed above the anterior leaflet of the mitral valve is quite feasible because of the accessible surgical site and easy quantification of the elongation of the chordae tendineae to be corrected.

Once the elongated chordae is identified, the anterior leaflet is exposed and an orifice about two to three millimeters wide is made at the insertion of the elongated chordae (Figure 1). After that procedure, the elongated chordae is pulled through the orifice with a nerve tractor or even a thick cotton thread, so that the anterior leaflet is towered to an appropriate level, resulting in a satisfactory coaptation of the leaflets. The orifice is sutured with interrupted 5-0 polypropylene sutures. The sutures also fasten the chordae to the atrial surface of the anterior leaflet of the mitral valve.

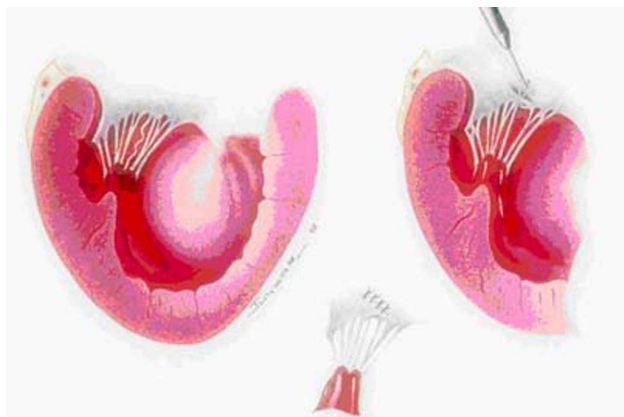


Fig. 1 – Left: schematic illustration shows the elongated chordae. Right: note that the orifice (2 to 3 millimeters wide) is near the edge of the leaflet, at a site corresponding to the insertion site of the elongated chordae. Traction of an elongated chordae through the orifice in the anterior leaflet is observed. The orifice in the anterior leaflet is sutured with interrupted 5-0 polypropylene sutures. Lower: the chordae tendineae are fastened to the atrial surface of the mitral valve

#### REPAIR OF RUPTURED CHORDAE TENDINEAE

##### 1. Neo chordae construction [9]

The mitral valve is carefully evaluated and the ruptured or “missing” chordae of the anterior leaflet are located precisely and marked with a suture. Two parallel incisions are made about five to 12 millimeters apart. The incisions begin at or near the annulus and carried toward the reference suture up to a point five millimeters from the free border of the leaflet. This strip of tissue thus created is detached. The detachment begins near the annulus and is tucked through the slit under the free border, whichever is easier, and brought toward the ventricular cavity. Then, the anterior leaflet is repaired with interrupted 5-0 polypropylene sutures. Next, the strip is sutured to the anterior papillary muscle with 5-0 polypropylene mattress sutures. (Figure 2).

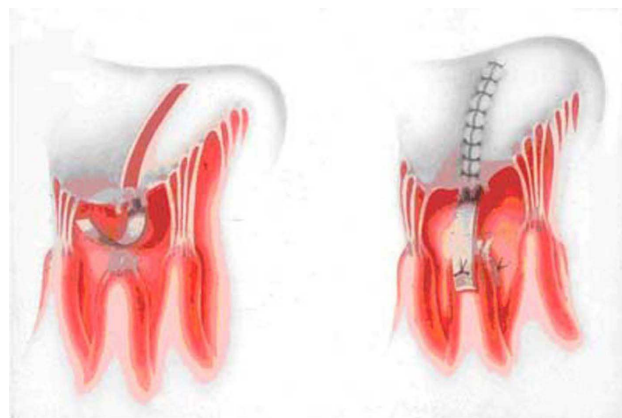


Fig 2 – Left: the strip of tissue is tucked through the slit under the edge of the leaflet. Right: the opening in the prior leaflet is repaired with interrupted 5-0 polypropylene suture, and the neo chorda is sutured to the anterior papillary muscle with 5-0 mattress sutures

##### 2. Partial tricuspid valve transfer [10]

Supply of chordae for the anterior leaflet of the mitral valve proceeds according to two techniques. The first and more frequent technique consists of removing the entire posterior leaflet of the tricuspid valve (with all its elements), I.E., chordae and papillary muscle (Figure 3). The specimen is transferred to the mitral valve by suturing the papillary muscle to that of the mitral valve, corresponding to the ruptured chordae, using one stitch in U anchored on small Dacron pledgets. After attaching the papillary muscle, the donor leaflet is sutured to the anterior leaflet of the mitral valve avoiding extensive chordae that would cause leaflet to prolapse and consequent mitral insufficiency. The same care must be taken regarding the opposite, I.E., chordae retraction with unwanted coaptation of the anterior leaflet

causing mitral insufficiency (Figure 4). The grafted leaflet may be sectioned in the middle. Two heads must remain linked to the papillary muscle by a good number of chordae. One of these heads is sutured to the anterior leaflet and the other to the posterior on (Figure 5). The tricuspid annulus is plicated with 4-0 polypropylene sutures. It is anchored on Dacron pledgets at the posterior portion leaving the bicuspid valve, furthermore, correcting any eventual functional tricuspid insufficiency.

The second technique (Figure 6), a variant of the first one, is applied when the posterior leaflet of the tricuspid valve or even the corresponding papillary muscle is not anatomically adequate. In these cases, the anterior valve is always more developed to compensate for the small posterior leaflet. Thus, a triangular patch is removed from the anterior leaflet with a satisfactory number and texture of chordae and a wedge of the corresponding papillary muscle, which is transferred to the mitral valve and sutured

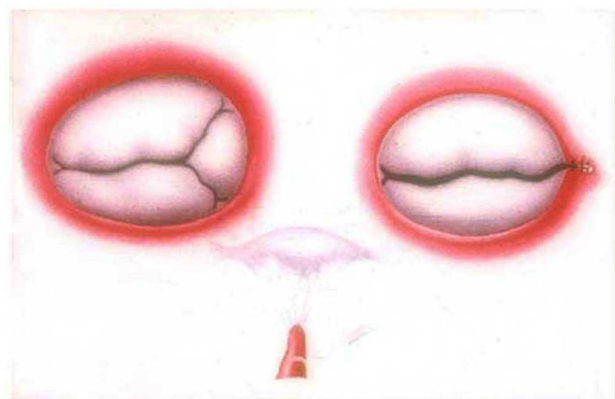


Fig. 3 – Removal of the posterior leaflet of the tricuspid valve, rendering it bicuspid. The specimen (lower) containing the leaflet, chordae tendineae, and the papillary muscle will be transferred to the mitral valve

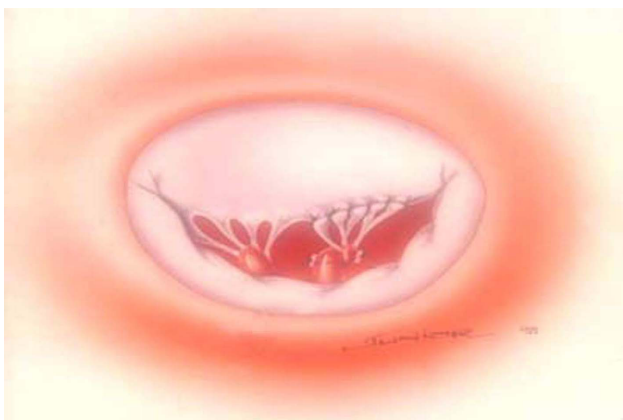

Fig. 4 – Intraoperative aspect after suture of the graft on the papillary muscle and the anterior leaflet of the mitral valve

afterwards, in the same way to the abovementioned technique. The tricuspid valve in these cases remains with its three leaflets. The sectioned edges of the anterior leaflet are joined with separated 5-0 polypropylene stitches.

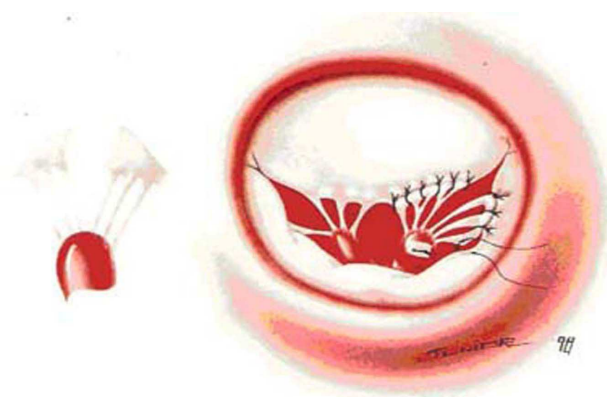


Fig. 5 – The graft sectioned in the middle remaining with two heads linked to the papillary muscle by a good number of chordae. One head is sutured to the anterior leaflet and the other head to the posterior on

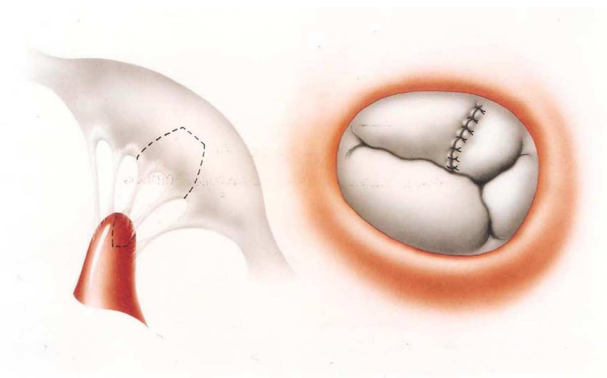


Fig. 6 – Left: a triangular patch is removed from the anterior leaflet of the tricuspid valve, with a satisfactory number and texture of chordae and a wedge of the papillary muscle which is transferred to the mitral valve. Right: sectioned edges of the anterior leaflet is joined with separated 5-0 polypropylene stitches

### 3. Repair of ruptured chordae or thin elongated chordae by premolded bovine pericardium chords [11]

#### The Braille-Gregori Prosthesis

The Braille-Gregori Prosthesis [11] created for repair of ruptured chordae is fashioned as a monobloc (Braille Biomédica Industria, Comércio e Representações S/A® – São Paulo – Brazil) joined at their extremities by two polyester-reinforced strips. The standardized bovine pericardium chordae were two millimeters wide and three



millimeters distant from each other (Figures 7A and B) Standardization of the chordae is confirmed by using measuring instruments ranging in length from 20 to 35 millimeters (Figure 8). The bovine pericardium is treated with 0.5% glutaraldehyde and then submitted to anticalcification treatment with glutamic acid. Next, it is preserved in 4% formaldehyde solution. Rupture levels of nearly 15 kg/cm<sup>3</sup> were found during resistance and durability tests [13]. The chordae length is determined based on the distance from the top of the papillary muscle to the edge of the leaflet in its original non-prolapsed position.



Fig. 7 – A and B: standardized bovine pericardium chordae

### Prosthesis Implant

The implant procedure began by anchoring the prosthesis on the top end of the papillary muscle associated with the ruptured chordae using one or two 5-0 polypropylene threads anchored in a Dacron pad. Subsequently, the other end is attached using individual 5-

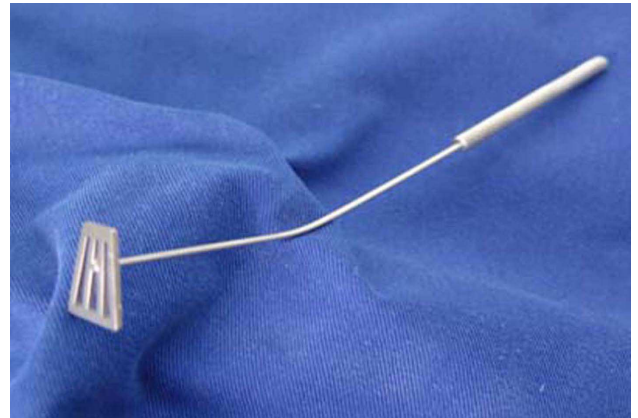


Fig. 8 – Measuring instruments ranging in length from 20 to 35 mm are used to confirm standardization of the chordae

0 polypropylene sutures to the free edge of the affected leaflet (Figure 9). The prosthesis with five standardized chordae may be reduced to as few as two chordae, as required.

### III – MITRAL ANNULOPLASTY (GREGORI-BRAILE RING) [12]

Since the introduction of open valve surgery, annular dilation found in all cases of mitral insufficiency has been treated conservatively. Almost simultaneously, many centers started correcting mitral insufficiency using plication mitral annuloplasty. This surgical procedure is a daily basis practice. After having observed anatomic alterations in patients with mitral insufficiency, Carpentier et al. [6] described several techniques for the correction of mitral insufficiency including annuloplasty with a prosthetic ring. Since then, several centres worldwide have adopted

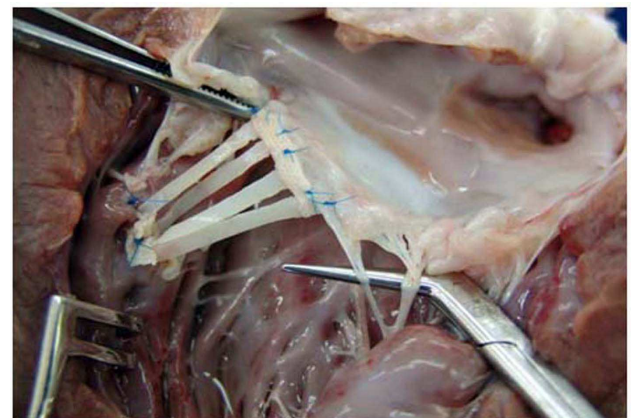


Fig. 9 – Anatomical aspect of the implantation of the prosthesis in an open bovine left ventricle

his techniques with excellent results. From 1979 to 1986, we operated on more than 100 patients using Carpentier ring annuloplasty. One-third of the patients were under the age of 16. Dilation of the anterior side of the mitral annulus between the two fibrous trigonae was demonstrated by Hueb et al. [14]. However, it was frequently found posteriorly and to a greater extent posteriorly and next to the posteromedial commissure (Figure 10). Based on these findings, we developed a rigid prosthetic semicircular ring (stainless steel wrapped in a thin layer of silicon rubber and covered with Dacron velvet) (Figures 11 and 12). By making fine adjustment on its right side, we could correct the dilation of the posterior side of the mitral ring next to the posteromedial commissure. The prosthesis corrects the annular dilation (Figure 13) and avoids the late manifestation of mitral stenosis in children and young patients, which is secondary to restraining the normal growth of the mitral ring. It is observed when closed prosthetic rings are used.

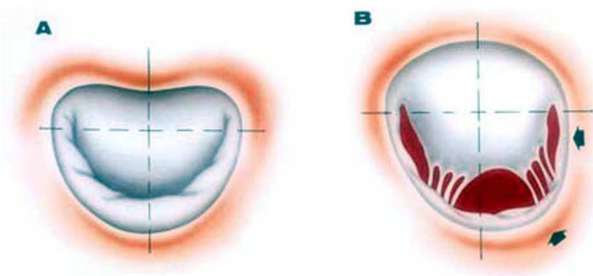


Fig. 10 – A: normal mitral valve annulus. B: posterior dilation of the annulus and to a greater extent next to the posteromedial commissure (arrows)

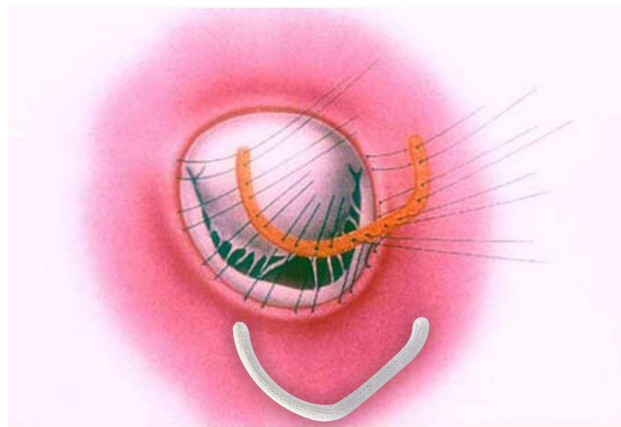


Fig. 12 – Schematic drawing showing the implantation of the Gregori-Braile ring prosthesis. Below the Gregori-Braile ring prosthesis

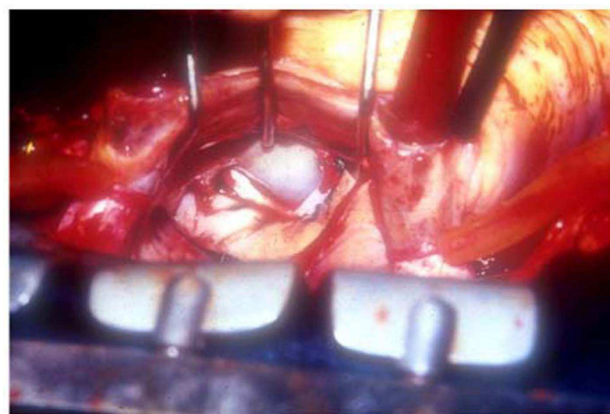


Fig. 13 – Intraoperative surgical aspect of a mitral annuloplasty by the Gregori-Braile ring prosthesis

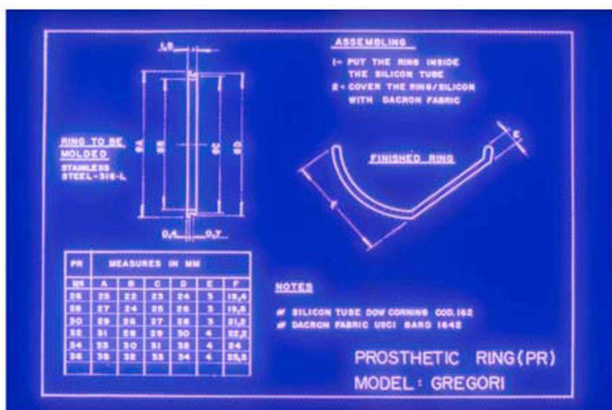


Fig. 11 – Technical drawing. The assembly of the prosthetic semicircular ring. Left: measurements of the largest diameter (in millimeters) in A. Right: attention to the rectification on the right that will correct the posterior dilation of the mitral annulus which is greater next to the posteromedial commissure

## DISCUSSION

The prosthetic ring presented here was first used in our centre in October, in 1987 [12]. Since then, this prosthesis has been employed in more than 40 centres in Brazil and other countries. It was developed to correct the dilation of the posterior mitral annulus, which resulted in a semi-circular shape. In our opinion, the anterior part of the closed-ring prosthesis is not only dispensable but also inconvenient in some situations. The posterior ring annuloplasty concept has been adopted by many surgeons as described by Hendren et al. [15], Salvador et al. [16] and Salati et al. [17] who used bovine pericardium strips fixed by glutaraldehyde. Braile et al. [13] who used berets – also made of a bovine pericardium. The mitral valvular system, including the mitral ring grows and develops in children. Implant of an open prosthesis in children with mitral insufficiency allows for normal growth of the anterior leaflet,



which corresponds to the distance between the fibrous trigonae. Any millimeter growth in this area may avoid the late manifestation of mitral stenosis, which happens when closed rings are used in small children. Our own comparative studies in adults have demonstrated the presence of a mitral transvalvar pressure gradient of smaller magnitude in patients with this prosthesis when compared to patients who had the closed ring implanted. The adjustment on the right side of the prosthetic ring was introduced for the correction of small leakage. It is frequently found next to the posteromedial commissure since this is the portion of the mitral ring with greater dilation. If required, once the Gregori-Braile ring is implanted, the intervention into the subvalvar system is made easily, which includes the shortening of elongated chordae tendineae and sectioning of retractable chordae.

The results have been consistent both in adults and children. Machado & Gregori [18] showed the late evaluation of rheumatic children under the age of 12 undergoing reconstructive mitral valve surgery with implant of the Gregori-Braile ring. After 188 months, the survival rate was 82% and the annual mortality rate 0.38%. Thirty-one (72.6%) patients did not require reoperation and the annual rate of patients who required further surgery was 0.51%.

#### REFERENCES

1. Souza LR, Brandão CMA, Pomerantzeff PMA, Leite Filho OA, Cardoso LF, Stolf NAG. Evolução tardia da comissurotomia mitral em pacientes reumáticos com baixo escore ecocardiográfico. *Rev Bras Cir Cardiovasc.* 2011;26(3):380-5.
2. Tenório EM, Moraes Neto F, Chauvaud S, Moraes CRR. Experiência com a técnica de ampliação do folheto posterior para correção da insuficiência mitral reumática na infância. *Rev Bras Cir Cardiovasc.* 2009;24(4):567-9.
3. Severino ESBO, Petrucci O, Vilarinho KAS, Lavagnoli CFR, Silveira Filho LM, Oliveira PPM, et al. Resultados tardios da plastia mitral em pacientes reumáticos. *Rev Bras Cir Cardiovasc.* 2011;26(4):559-64.
4. Guedes MAV, Pomerantzeff PMA, Brandão CMA, Vieira MLC, Leite Filho OA, Silva MF, et al. Plastia valvar mitral pela técnica do duplo teflon: análise do remodelamento cardíaco pela ecocardiografia tridimensional. *Rev Bras Cir Cardiovasc.* 2010;25(4):534-42.
5. Pomerantzeff PMA, Brandão CMA, Leite Filho OA, Guedes MAV, Silva MF, Grinberg M, et al. Plástica da valva mitral em pacientes com insuficiência mitral reumática: técnicas e resultados de 20 anos. *Rev Bras Cir Cardiovasc.* 2009;24(4):485-9.
6. Carpentier A, Relland J, Deloche A, Fabiani JN, D'Allaines C, Blondeau P, et al. Conservative management of the prolapsed mitral valve. *Ann Thorac Surg.* 1978;26(4):294-302.
7. Akins CW, Hilgenberg AD, Buckley MJ, Vlahakes GJ, Torchiana DF, Daggett WM, et al. Mitral valve reconstruction versus replacement for degenerative or ischemic mitral regurgitation. *Ann Thorac Surg.* 1994;58(3):668-75.
8. Gregori Júnior F, Silva S, Façanha L, Cordeiro C, Aquino W, Moure O. Preliminary results with a new technique for repairing elongated chordae tendineae of the anterior mitral valve leaflet. *J Thorac Cardiovasc Surg.* 1994;107(1):321-3.
9. Gregori F Jr, Takeda R, Silva S, Façanha L, Meier MA. A new technique for repair of mitral insufficiency caused by ruptured chordae of the anterior leaflet. *J Thorac Cardiovasc Surg.* 1988;96(5):765-8.
10. Gregori F Jr, Cordeiro CO, Croti UA, Hayashi SS, Silva SS, Gregori TE. Partial tricuspid valve transfer for repair of mitral insufficiency due to ruptured chordae tendineae. *Ann Thorac Surg.* 1999;68(5):1686-91.
11. Gregori F Jr, Leal JC, Braile DM. Premolded bovine pericardial chords for replacement of ruptured or elongated chordae tendineae. *Heart Surg Forum.* 2010;13(1):E17-20.
12. Gregori F, Silva SS, Hayashi SS, Aquino W, Cordeiro C, Silva LR. Mitral valvuloplasty with a new prosthetic ring. Analysis of the first 105 cases. *Eur J Cardiothorac Surg.* 1994;8(4):168-72.
13. Braile DM, Ardito RV, Pinto GH, Santos JLV, Zaiantchick M, Souza DRS, et al. Plastia mitral. *Rev Bras Cir Cardiovasc.* 1990;5(2):86-98.
14. Hueb AC, Jatene FB, Moreira LF, Pomerantzeff PM, Kallás E, Oliveira SA. Ventricular remodeling and mitral valve modifications in dilated cardiomyopathy: new insights from anatomic study. *J Thorac Cardiovasc Surg.* 2002;124(6):1216-24.
15. Hendren WG, Nemeč JJ, Lytle BW, Loop FD, Taylor PC, Stewart RW, et al. Mitral valve repair for ischemic mitral insufficiency. *Ann Thorac Surg.* 1991;52(6):1246-51.
16. Salvador L, Rocco F, Ius P, Tamari W, Masat M, Paccagnella A. The pericardium reinforced suture annuloplasty: another tool available for mitral annulus repair? *J Card Surg.* 1993;8(1):79-84.
17. Salati M, Scrofani R, Santoli C. Posterior pericardial annuloplasty: a physiological correction? *Eur J Cardiothorac Surg.* 1991;5(5):226-9.
18. Machado VH, Gregori Júnior F. Late heart evaluation of children with rheumatic mitral regurgitation submitted to reconstructive surgery with implantation of Gregori's ring. *Arq Bras Cardiol.* 2005;85(6):403-11.