

Endovascular correction of abdominal aortic aneurysm as a late complication of type A aortic dissection

Correção endovascular de aneurisma de aorta abdominal em complicação tardia de dissecação de aorta tipo A

José Carlos Dorsa Vieira Pontes¹, João Jackson Duarte², Augusto Daige da Silva³, Amaury Mont'Serrat Ávila Souza Dias⁴

DOI: 10.5935/1678-9741.20120108

RBCCV 44205-1433

Abstract

Aortic dissection type A has a great mortality in its acute phase with low annual survival without surgical treatment. Although the chronic cases are exceptions the late complications exist and should be treated.

Descriptors: Aortic aneurysm. Aneurysm, dissecting. Aortic diseases. Endovascular procedures.

Resumo

A dissecação de aorta tipo A apresenta grande mortalidade em sua fase aguda, com baixa sobrevida anual sem tratamento cirúrgico. Embora os casos crônicos sejam exceções, as complicações tardias existem e devem ser tratadas.

Descritores: Aneurisma aórtico. Aneurisma dissecante. Doenças da aorta. Procedimentos endovasculares.

INTRODUCTION

Type A aortic dissection is a cardiovascular event with the highest acute mortality rate when not treated in time [1]. In natural evolution in its acute phase, patients progress to sudden death in 3% of cases and in the absence of immediate appropriate care, the mortality rate can increase by 1% per hour for the first 24 hours, and 80% die within the first two weeks and 95% in one year [2].

CASE REPORT

Chronic hypertensive patients, 74 years old in irregular treatment for hypertension, with several passages in units of emergencies due to hypertensive crisis. The patient

looked for elective care due to pain in the lumbar region. It was also reported that about three years ago, the patient sought immediate medical treatment due to chest pain during an important hypertensive crisis. The individual was hospitalized for blood pressure control, obtaining remission of pain after blood pressure control.

A physical examination was carried out; the patient had a large pulsatile abdominal mass, approximately 7 cm. Chest and abdominal computed tomography revealed a large abdominal aortic aneurysm, 65 mm (Figure 1) and a thrombosed false lumen in ascending and descending aorta (Figure 2).

The patient underwent endovascular repair of the abdominal aortic aneurysm with Braile Biomédica bifurcated prosthesis, obtaining successful aneurysm

1. PhD, Director of the Center of the University Hospital at the Federal University of Mato Grosso do Sul (HU - UFMS), Campo Grande, Mato Grosso do Sul, Brazil.

2. Master, Cardiovascular Surgeon at HU - UFMS, Campo Grande, Mato Grosso do Sul, Brazil.

3. Interventional Cardiologist at HU - UFMS, Campo Grande, Mato Grosso do Sul, Brazil.

4. Cardiovascular Surgeon at HU - UFMS, Campo Grande, Mato Grosso do Sul, Brazil.

Work performed at the University Hospital at the Federal University of Mato Grosso do Sul, Campo Grande, Mato Grosso do Sul, Brazil.

Correspondence Address: José Carlos Dorsa Vieira Pontes
Rua Filinto Muller, 355t, Campo Grande, MS, Brazil – Zipcode: 79080-190
E-mail: carlosdorsa@uol.com.br

Article received on June 5th, 2012
Article accepted on August 8th, 2012

Abbreviations, acronyms and symbols

IRAD International Registry of Acute Aortic Dissections

exclusion with total thrombosis of the aneurysm sac, observed in control tomography 30 days after the procedure (Figure 1).

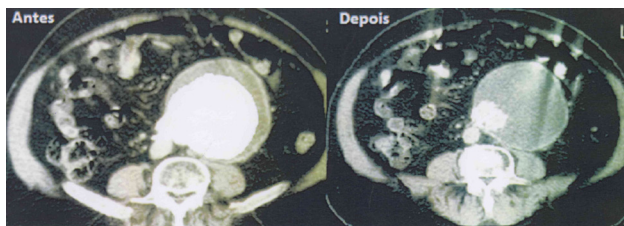


Fig. 1 - Infra renal abdominal aortic aneurysm before and after endovascular correction. Antes - Before, Depois - After

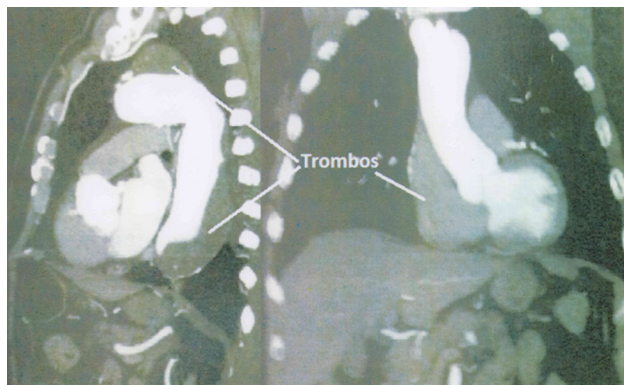

Fig. 2 - Thrombosed false lumen of the ascending aortic arch and descending aorta: type A aortic dissection with spontaneous resolution. Trombos - Thrombi

DISCUSSION

The diagnosis of acute aortic dissection in approximately 38% of cases is not achieved at the first evaluation, and in 28% of cases the diagnosis is made during necropsy [3].

According to the International Registry of Acute Aortic Dissection (IRAD) [4], patients with type A aortic dissection who underwent medical treatment have a mortality rate of 58%, twice as those treated surgically, which was 26%. Also according to the IRAD, mortality was higher in the first seven days, and the most common cause of death was aortic rupture and cardiac tamponade (41.6%). Despite the high hospital mortality of medical

treatment in acute aortic dissection, a third of patients who can be discharged are alive after a 3-day follow-up period [5]. Late complications in aortic dissection refer to distal branches obstruction, aneurysms formation and pseudoaneurysms. The abdominal aortic aneurysms are responsible for approximately 12,000 to 15,000 deaths per year in the United States and are a major cause of death in men over 65 years [6].

The DREAM [7], a Dutch multicenter study, showed lower surgical mortality (30 days) with the endovascular procedure, when compared to open surgery; however this lower surgical mortality is lost over the years. The segments 2 and 4 years show that late mortality is similar in both groups, and the most of the deaths in the medium term are not related to aneurysm rupture but the degenerative diseases correlated with atherosclerosis, such as myocardial infarction and cerebrovascular accident, besides cancer.

According to current indications for surgical treatment of aortic diseases, the indication of surgery for abdominal aortic aneurysm is done for symptomatic cases and for those asymptomatic low-risk surgery cases, with a diameter greater than 5.5 cm or greater than 6.0 cm for high-risk patients [8]. Since they have favorable anatomy, endovascular treatment has recommendation grade "A" in these cases. In our environment, Saadi et al. [9] reported a series of 25 patients undergoing endovascular repair of abdominal aortic aneurysm with 96% of patients alive and free of further intervention, up to a 27-month follow-up period.

This case demonstrates a rare event, which is the spontaneous resolution of a type A aortic dissection with progression throughout the descending and abdominal aorta, and also shows the importance of monitoring the anatomic aortic changes with imaging tests, since this disease the distal vessel involvement is very common and often requires additional invasive procedure that can save a patient's life.

REFERENCES

1. Leal JC, Ferreira VRR, Avanci LE, Braile DM. O tratamento operatório da dissecação aórtica crônica tipo A em pacientes submetidos à revascularização cirúrgica do miocárdio. Rev Bras Cir Cardiovasc. 2010;25(3):403-5.
2. Anagnostopoulos CE, Prabhakar MJ, Kittle CF. Aortic dissections and dissecting aneurysms. Am J Cardiol. 1972;30(3):263-73.

-
3. Spittell PC, Spittell JA Jr, Joyce JW, Tajik AJ, Edwards WD, Schaff HV, et al. Clinical features and differential diagnosis of aortic dissection: experience with 236 cases (1980 through 1990). *Mayo Clin Proc.* 1993;68(7):642-51.
 4. Hagan PG, Nienaber CA, Isselbacher EM, Bruckman D, Karavite DJ, Russman PL, et al. The International Registry of Acute Aortic Dissection (IRAD): new insights into an old disease. *JAMA.* 2000;283(7):897-903.
 5. Tsai TT, Evangelista A, Nienaber CA, Trimarchi S, Sechtem U, Fattori R; International Registry of Acute Aortic Dissection (IRAD), et al. Long-term survival in patients presenting with type A acute aortic dissection: insights from the International Registry of Acute Aortic Dissection (IRAD). *Circulation.* 2006;114(1 Suppl):I350-6.
 6. Svensson LG, Kouchoukos NT, Miller DC, Bavaria JE, Coselli JS, Curi MA; Society of Thoracic Surgeons Endovascular Surgery Task Force, et al. Expert consensus document on the treatment of descending thoracic aortic disease using endovascular stent-grafts. *Ann Thorac Surg.* 2008;85(1 Suppl):S1-41.
 7. Blankensteijn JD, de Jong SE, Prinssen M, van der Ham AC, Buth J, van Sterkenburg SM, et al; Dutch Randomized Endovascular Aneurysm Management (DREAM) Trial Group. Two-year outcomes after conventional or endovascular repair of abdominal aortic aneurysms. *N Engl J Med.* 2005;352(23):2398-405.
 8. Albuquerque LC, Braile DM, Palma JH, Saadi EK, Gomes WJ, Buffolo E. Diretrizes para o tratamento cirúrgico das doenças da aorta da Sociedade Brasileira de Cirurgia Cardiovascular. *Rev Bras Cir Cardiovasc.* 2007;22(2):137-59.
 9. Saadi EK, Gastaldo F, Dussin LH, Zago AJ, Barbosa GV, Moura L. Tratamento endovascular dos aneurismas de aorta abdominal: experiência inicial e resultados a curto e médio prazo. *Rev Bras Cir Cardiovasc.* 2006;21(2):211-6.