



Mammary artery harvesting using the Da Vinci Si robotic system

Dissecção da artéria mamária com uso de sistema robótico Da Vinci Si

Leonardo Secchin Canale¹, MD; Johannes Bonatti², MD

DOI: 10.5935/1678-9741.20140019

RBCCV 44205-1529

Abstract

Internal mammary artery harvesting is an essential part of any coronary artery bypass operation. Totally endoscopic coronary artery bypass graft surgery has become reality in many centers as a safe and effective alternative to conventional surgery in selected patients. Internal mammary artery harvesting is the initial part of the procedure and should be performed equally safely if one wants to achieve excellence in patency rates for the bypass. We here describe the technique for mammary harvesting with the Da Vinci Si robotic system.

Descriptors: Surgical procedures, minimally invasive. Mammary arteries. Thoracoscopy. Robotics.

The internal mammary artery (IMA) has consolidated itself as the preferable graft for coronary artery bypass surgery (CABG). Classically harvested through a sternotomy it is one of the initial but essential steps in CABG surgery. Pediculated and skeletonized techniques were developed, the last one providing longer graft length and preserved blood supply for the sternum.

The use of robotic assistance to perform totally endoscopic CABG has become an accepted option for surgical coronary artery revascularization. Again, the first step in this

Resumo

Dissecção da artéria mamária interna é parte essencial de qualquer operação de revascularização do miocárdio. Cirurgia de revascularização do miocárdio totalmente endoscópica se tornou realidade em muitos centros como uma alternativa segura e efetiva, comparável à cirurgia convencional, em pacientes selecionados. Dissecção da artéria mamária interna é a parte inicial do procedimento e deve ser realizada com igual segurança se quisermos atingir excelentes taxas de patência para a ponte. Descreveremos aqui a técnica de dissecção de artéria mamária interna com o sistema robótico Da Vinci.

Descritores: Procedimentos cirúrgicos minimamente invasivos. Artéria torácica interna. Toracoscopia. Robótica.

surgery is the process of IMA take down, which we will describe here.

Anesthesia uses a double lumen endotracheal tube and places R2 defibrillator patches in the right infraclavicular region and the dorsal part of the left lower chest. The patient is placed in supine position with the left chest slightly elevated. Both arms are tucked to the chest and flank. During prepping and draping care has to be taken that the drapes do not reach beyond the posterior axillary line so as to have enough space for port placement or placement of a minithoracotomy.



Veja o vídeo acessando o link abaixo:

http://rbccv.org.br/video/2226/Disseccao_da_arteria_mamaria_com_uso_de_sistema_robotico_Da_Vinci_Si

1. Cleveland Clinic Foundation, Cleveland, Ohio, USA.
2. Cleveland Clinic Abu Dhabi, Abu Dhabi, United Arab Emirates.

Correspondence address:
Leonardo Secchin Canale
Cleveland Clinic Foundation
9500 Euclid Avenue, J-4-133 – Cleveland, Ohio, USA – Zip code: 44195
E-mail: leonardo.canale@gmail.com

This study was carried out at Cleveland Clinic Foundation, Cleveland, Ohio, USA.

No financial support.

Article received on November 17th, 2013
Article accepted on January 6th, 2014

Abbreviations, acronyms & symbols

| | |
|------|--------------------------------|
| CABG | Coronary artery bypass surgery |
| IMA | Internal mammary artery |
| LIMA | Left internal mammary artery |
| RIMA | Right internal mammary artery |

The Da Vinci SI robotic patient cart (Intuitive Surgical, Inc.) which carries three or four robotic arms approaches the patient perpendicular from the right side. With the left lung deflated (using a dual tube endotracheal tube), a 12 mm camera port is initially inserted in the 5th intercostals space on the anterior axillary line. Carbon dioxide is insufflated to the chest (6-10 mmHg). The camera port hole can be predilated with an 8 mm instrument port. Port insertion has to be performed very gently and awareness of the presence of adhesions and the fact that the heart may be close to the chest wall is very important so as to avoid injury of intrathoracic structures. During this phase, the arterial blood pressure needs to be observed as insufflation may lead to hemodynamic compromise. In this case the insufflation pressure is lowered to a minimum.

The robotic camera is used to inspect the thoracic cavity for adhesions and orient the insertion of the other 2 ports. The right arm port (8 mm) is inserted in the 3rd intercostal space 3 cm anterior to the camera port, so avoid conflict between the robotic arm and the patients left shoulder. The left arm port (8 mm) is inserted in the 7th intercostal space 3 cm anterior to the level of the camera port. By doing so, we position the three arms in a flat triangle, which is a principle for any video assisted port procedure. For a rough orientation the surgeon can place the tip of his/her right third finger on the patient's jugulum and the tip of his/her left third finger on the xiphoid angle. Where the tips of the stretched out thumbs meet is the camera port insertion site. The instrument ports are placed four finger breaths apart from the camera port.

The robotic surgeon then performs an inspection of the left pleural space. For anatomic orientation he visualizes the left subclavian artery and the distal aortic arch. The pericardium and its covering fat pad first come into view. The left internal mammary artery (LIMA) can then be visualized beneath the endothoracic fascia. Harvesting starts where the surgeon sees the artery pulsating which is usually in its cranial part. A 30 degree camera is used "facing up". For most of the procedure the left robotic arm is equipped with EndoWrist fine tissue forceps (Intuitive Surgical, Inc.) and the right robotic arm with a EndoWrist spatula cautery (Intuitive Surgical, Inc.), connected to low power monopolar energy (15W). The parietal pleura, fascia and muscles are then opened all along the lateral aspect of the artery (close to the camera). The LIMA is then carefully detached from the chest wall from distal to proximal end in a skeletonized fashion (Figure 1). Dissection is performed using sweeping movements alongside the artery, part of the time without uti-

lizing energy. The camera provides a 10 times magnification which lead to great visualization of the procedure, but also tends to overestimate the size of branches and the amount of bleeding. We tend to cauterize the small branches (far from the mammary and close to the chest wall) and clip the large ones (Figures 2 and 3). Although there is some bleeding from the transverse thoracic muscle and very small branches with this approach, these are always self limiting. When all the extension of the artery is free from the chest wall the patient is heparinized, and 2 clips are applied to the distal end. One clip is placed slightly proximal to the distal end and the vessel is divided using robotic Pott's scissors.

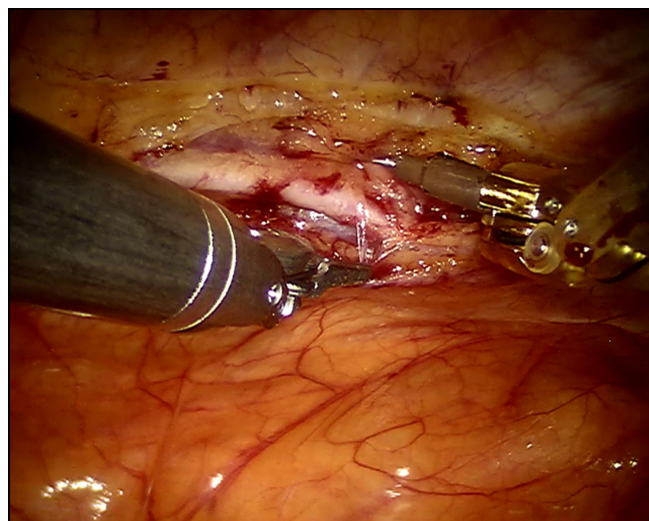


Fig. 1 – Harvesting of the left internal thoracic artery with fine forceps and spatula

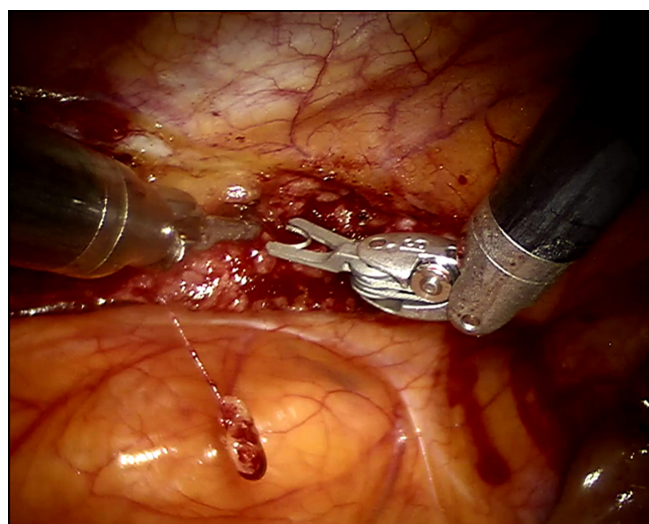


Fig. 2 – Use of endoscopic clip to ligate branch of the mammary artery

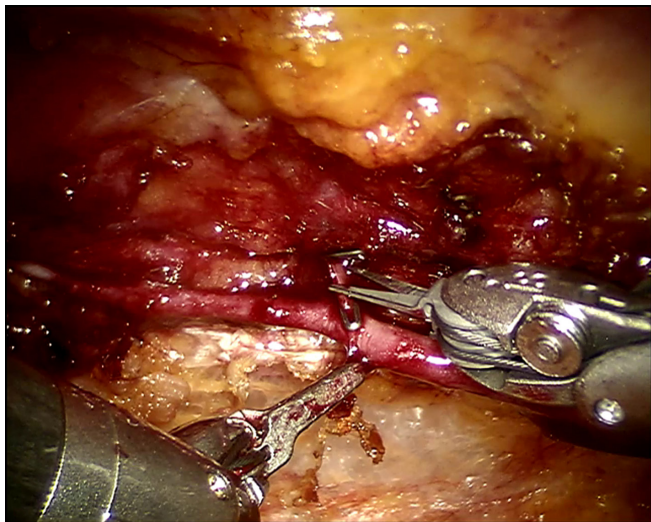


Fig. 3 – Use of endoscopic Potts scissors to cut branch

If bilateral IMAs are being planned, the right internal mammary artery (RIMA) should be dissected first. This is to avoid damage to an already harvested LIMA once the instruments go forward to the right side of the chest. To reach the RIMA, a dissection of the substernal plane is carried out all the way to the right pleura. The pericardium should not be opened at this time. The technique for RIMA takedown is overall similar to the LIMA. Harvesting of the very proximal part can at times be difficult. If the surgeon during harvesting feels difficulties reaching structures on the distal part of the IMA, ports should be checked for exact position from inside the chest. Ports can be pushed in for better reach and the right instrument port can be lifted into sternal direction. A full description of the rest of a totally endoscopic CABG can be found elsewhere [1].

Regarding time to perform this procedure, an important learning curve has been observed. Oehlinger et al. [2] assessed the first 100 LIMAs harvested by the senior surgeon and noticed a decline in total time. The mean time for all cases was 48 minutes. While the first 10 cases required a mean of 140 minutes each, the last 10 cases required only 34 minutes. More recently Yang et al. [3] reported on their first 200 harvested IMAs. Mean time for IMA harvesting was 35 minutes and a significant learning curve was observed: from 41 minutes in the first 30 cases to 29 minutes in the last 30 cases. In both studies the IMA was skeletonized.

A somewhat similar technique for mammary harvesting is described by Ishikawa et al termed “slide fascia technique” [4]. Instead of using a spatula for fascia opening the authors use a forceps connected to the monopolar energy.

Despite these excellent experiences with IMA harvesting, some investigators are trying to push the technique even more forward. Ishikawa et al. [5] developed a tridimensional triangular hook to facilitate handling and traction of the

mammary artery. This small instrument can be introduced in the chest through one of the 8 mm ports and goes around the IMA, held by regular robotic forceps. Experiments in dogs showed a decrease in total time of harvesting. Watanabe et al. [6] developed an electrical chest wall retractor to allow robotic mammary without the use of CO₂ insufflations. It is recognized that CO₂ pressures above 10 mmHg can lead to hemodynamic instability. Also some patients have a very small chest cavity space to allow for easy harvesting (obese patients, cardiomegaly). The authors present a device capable of raising the sternum up to 5-10 cm which avoids completely the use of CO₂.

In summary, robotic totally endoscopic IMA harvesting is feasible and safe. This article also presents a video and pictures of our preferred technique. A learning curve phenomenon is clearly present. More than one technique is available. Further fine adjustments might improve time and ease of operation even further.

Authors' roles & responsibilities

| | |
|-----|--|
| LSC | Manuscript writing, video images editing |
| JB | Manuscript writing, video images editing |

REFERENCES

- Canale LS, Mick S, Mihaljevic T, Nair R, Bonatti J. Robotically assisted totally endoscopic coronary artery bypass surgery. *J Thorac Dis.* 2013;5(Suppl 6):S641-9.
- Oehlinger A, Bonaros N, Schachner T, Ruetzler E, Friedrich G, Laufer G, et al. Robotic endoscopic left internal mammary artery harvesting: what have we learned after 100 cases? *Ann Thorac Surg.* 2007;83(3):1030-4.
- Yang M, Gao CQ, Wu Y, Liu S. Robotic internal thoracic artery harvesting: the learning curve and graft patency. *Chin Med J (Engl).* 2013;126(10):1982-3.
- Ishikawa N, Watanabe G, Tomita S, Ushijima T, Yamaguchi S, Nishida S, et al. Robotic skeletonized internal thoracic artery harvesting: the sliding fascia technique. *Artif Organs.* 2010;34(6):516-8.
- Ishikawa N, Sun YS, Nifong LW, Watanabe G, Chitwood WR Jr. New instrument for robotic-enhanced skeletonized internal thoracic artery harvesting: triangular hook. *Innovations.* 2007;2(2):73-5.
- Watanabe G, Matsumoto I, Kiuchi R. Novel sternum lifting technique for robotic internal thoracic artery graft harvesting. *Innovations.* 2013;8(1):76-9.