

Graft versus host disease in a rat small bowel transplant model after T-cell depleted donor specific bone marrow infusion¹

Alexandre Bakonyi Neto²
 Evangelos P. Misiakos²
 Andreas G. Tzakis²
 Mariana Behro³
 Phillip Ruiz³
 Joshua Miller⁴
 Camilo Ricordi⁵
 Bonifacio K. Takegawa⁶

Bakonyi Neto A, Misiakos EP, Tzakis AG, Behro M, Ruiz P, Miller J, Ricordi C, Takegawa BK. Graft versus host disease in a rat small bowel transplant model after T-cell depleted donor specific bone marrow infusion. *Acta Cir Bras* [serial online] 2003 Mar-Apr;18(2). Available from URL: <http://www.scielo.br/acb>.

ABSTRACT - Low cytoreductive regimen of irradiation associated to unmodified bone marrow infusion (UBM) does not prevent the occurrence of graft versus host disease (GVHD) after transplant.

Purpose: In this study we evaluated the potential advantages of a long-term immunosuppression and T-cell depleted bone marrow infusion (TCDBMI) in preventing the occurrence of GVHD after small bowel transplantation (SBTx). **Methods:** Heterotopic SBTX was performed with Lewis rats as recipients and DA as donors and distributed into 5 groups according to the irradiation, duration of immunosuppression and the use of UBM or TCDBMI: G1 (n=6), without irradiation and G2 (n=9), G3 (n=4), G4 (n=5) and G5 (n=6) was given 250 rd of irradiation. Groups 1,2,4 and G3 and 5 were infused with 100×10^6 UBM and TCDBMI respectively. Animals in G1, 2, 3 were immunosuppressed with 1mg/ FK506/Kg/IM for 5 days and G4 and G5 for 15 days. Anti CD3 monoclonal antibodies and immunomagnetic beads were used for T-cell depletion. Animals were examined for rejection, GVHD, chimerism characterization and ileal and skin biopsies. **Results:** Minimal to mild rejection was observed in all groups; however, GVHD were present only in irradiated groups. Long-term immunosuppression changed the severity of GVHD in G4 and G5. Rejection was the cause of death in G1 while GVHD in G2, 3, 4 and 5, not avoided by the use of TCDBMI. Total chimerism and T-cell chimerism was statistically higher in irradiated groups when compared to G1. **Conclusion:** Extended immunosuppression associated to low dose of irradiation decrease the severity of GVHD, not avoided by the use of TCDBMI.

KEY WORDS - Intestinal transplant. T-cell depletion. Bone marrow.

1. University of Miami School of Medicine, Division of Liver and GI Transplantation.
2. Department of Surgery/ Division of Liver and GI Transplantation. Assistant Professor, PhD – Department of Surgery from Botucatu Faculty of Medicine (UNESP); Ex-fellow of Transplant Division at the University of Miami supported by CNPq.
3. Department of Pathology/ Division of Immunopathology.
4. Department of Surgery/ Division of Kidney and Pancreas Transplantation.
5. Diabetes Research Institute and Cell Transplantation Center.
6. Assistant Professor - Department of Surgery from Botucatu Faculty of Medicine.

Introduction

The use of allogeneic bone marrow infusion as a mean of inducing donor-specific tolerance could provide an immunological specific conditioning regimen for organ transplantation. The major limitation to this approach is the toxicity of whole body irradiation necessary to inactivate the host resistance and permit the marrow engraftment¹. In data to be published we demonstrate that even with low doses of irradiation an increased morbidity and mortality due to graft-versus-host disease (GVHD) was observed in recipients after small bowel transplantation. Low cytoreductive regimens of irradiation can successfully decrease the severity of graft rejection but enhance the occurrence of GVHD.

In this study we evaluate whether nonmyeloablative preconditioning given by low doses of irradiation and associated with unmodified or T-cell depleted (TCD) donor bone marrow (BM) infusions and extended immunosuppression can enhance small bowel allograft and recipient survival.

Methods

Small bowel transplantation was performed using a fully histoincompatible rat strain combination. Male DA (Rt1^a) weighing 80 to 100 g were used as donors and female Lewis (Rt1^l) weighing 180 g as recipients. The animals were obtained from Harlan Sprague Dawley (Indianapolis, IN) and housed at the Division of Veterinarian Resources of the University of Miami.

Small bowel transplantation - Heterotopic small bowel transplant was performed using standard microvascular techniques². Under metofane anesthesia, the abdomen was opened by a midline incision. The donor small bowel (jejunum-ileum) was removed after intraluminal and intravascular irrigation with cold heparinized saline solution (4°C). The bowel was excised with its intact vascular pedicle consisting of the superior mesenteric artery with an aortic cuff and the portal vein. The graft was kept at 4°C until transplantation.

The recipient abdomen was opened and the graft was reperfused by anastomosing the aortic cuff to the recipient infrarenal aorta, while the portal vein was anastomosed to the recipient inferior vena cava. The proximal and distal ends of the graft were exteriorized as stomas (Thiry-Vella Loop).

Animals surviving less than 48 hours were considered technical failures and excluded. All animals were fed with a regular laboratory diet and water beginning immediately after transplant.

Experimental design - Thirty male DA rats and thirty female Lewis rats were used as donors and recipients respectively, for a heterotopic small bowel transplant. Animals were distributed into 5 groups according to the use of radiation, duration of immunosuppression and the use of unmodified (UBM) or TCD bone marrow: group 1 (n=6), without irradiation and groups 2 (n=9), 3 (n=4), 4 (n=5) and group 5 (n=6) was given 250 rd of total body irradiation (TBI) from a cesium-137 source 1 to 2 hours prior the small bowel transplant. Groups 1, 2, 4 and groups 3 and 5 were infused with 100×10^6 UBM cells and TCD BM cells respectively. Animals in groups 1,2,3 were immunosuppressed with 1 mg/kg/FK 506/ IM/ for 5 days and in groups 4 and 5 for 15 days, started on the day of the transplant.

Bone marrow preparation - Fresh donor bone marrow was obtained from femurs and tibias of exsanguinated DA rats. Bone marrow was harvested from the long bones by flushing with RPMI 1640 medium (Life Technologies, Grand Island, NY), using a 23-gauge needle. The bone marrow cells were gently resuspended using an 18-gauge needle and filtered through a sterile nylon mesh. The viability of the cells was checked by trypan blue exclusion and counted before antibody treatment for T cell depletion. Trypan blue exclusion test always showed > 95% viability before infusion. The bone marrow cells were then pelleted by centrifugation at 1500 rpm for 10 min.

For T-cell depletion (TCD), mouse anti-rat CD3 monoclonal antibodies was added to the cell suspension and allowed to incubate at 4°C for 30 minutes. Unbound antibody was removed by washing twice in RPMI medium containing 2% fetal calf serum (Gibco, Grand Island, NY). Cells were then combined with magnetic beads coated with sheep anti-mouse IgG (Dynabeads M-450, Dynal, Lake Success, NY) and gently agitated at 4°C for 1 hour. The final bead:cell ratio was 1:4.

Negative selection of a CD3 positive T-cells was accomplished by exposing the flask containing the labeled marrow to a hand-held magnet for 3 minutes. Elution of the supernatant yielded the final product. Marrow was then resuspended and cell concentration was adjusted so that the total number of cells ($80-100 \times 10^6$) was injected in a 1 ml volume in the femoral vein after dissection immediately after transplant.

Adequacy of T cell depletion was confirmed using flow cytometry for detection of cells expressing DA rats class I antigen (haplotype RT1^a), with a two color staining cocktail (FITC-conjugated Mab to RT1^a and PE-conjugated anti-rat CD3, both from PharMingen, San Diego, CA) before and after depletion.

Immunomagnetic bead-based T-cell depletion were considered efficient when post-depletion of donor CD3+ cells content was greater than 99% of the lymphoid gate.

Postoperative follow-up - Rats were observed daily for clinical signs of graft-versus-host disease (GVHD), such as diffuse erythema (particularly of the ears and extremities), hyperkeratosis of the footpads, skin rash, anorexia, diarrhea and unkempt appearance. The abdomen was palpated daily to detect development of a palpable abdominal mass, a characteristic signal of graft rejection.

Postoperative assessment of chimerism by flow cytometric analysis - Blood samples were collected weekly by tail puncture into anti-coagulated (EDTA) plastic serum vials after light anesthesia. Flow cytometry detection of cells expressing DA rats class I antigen (haplotype RT1^a), were done with a two color staining protocol for whole blood. Briefly, 100 ml of a two color cocktail (FITC-conjugated Mab to RT1^a and PE-conjugated anti-rat CD3, both from PharMingen, San Diego, CA) were incubated with 100 ml of whole blood. After an incubation of 30 minutes, the red blood cells (RBC) were lysed (with lysing reagent for whole blood Becton/Dickinson San Jose, CA). The presence of donor cells in the recipient Lewis rat (DA cells circulating in the Lewis blood stream) were classified as T cells and non-T cells.

The complete analysis was obtained by gating on mononuclear cells by size and granularity first, then segregating the RT1^a positive cells over a background of a non transplanted Lewis (negative control) and within the spectrum of a normal DA (positive control). An additional segregation was done on this last to determined which were also expressing CD3 epitopes. All the analysis were done in a Facs Calibur flow cytometer, San Jose (CA).

Post-transplant biopsies and pathologic studies - Biopsies from the ileostomy and skin were taken every fifteen and thirty days respectively after transplant to assess the presence of rejection and GVHD. Tissue samples were fixed in 10% buffered formalin, embedded in paraffin, sectioned at 4 mm and stained with hematoxylin and eosin. For each biopsy a combination of histological parameters were applied to assess acute and chronic rejection. Acute rejection was graded as mild, moderate and severe based on a semiquantitative scoring system.

The graded features included surface and crypt epithelial injury (reactive epithelial atypia, cryptitis, apoptotic bodies and presence of crypt abscesses), villous blunting, mucosal ulceration, and vasculitis. A

diagnosis of chronic rejection was rendered when prominent obliterative vasculopathy was noted.

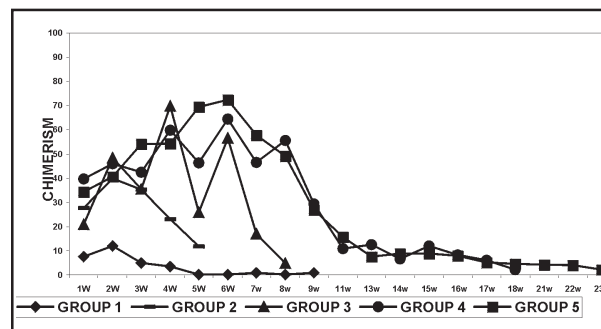
Statistics - The significance of differences between means was determined by using the Anova and Duncan's multiple range test. Values were considered statistically significant for $p < 0.05$.

Results

Histopathologic studies - Ileal biopsies obtained on day 15 after transplant showed minimal to mild acute rejection in all groups. After 30 days, severe acute and early chronic rejection was observed only in non-irradiated animals (group 1) while was considered as mild to moderate in groups 2 and 3. The long-term immunosuppression groups (4 and 5) showed the same histologic pattern of minimal to mild acute rejection during the experiment. Skin biopsies showed the characteristic pattern of GVHD, and were present only in groups submitted to irradiation. GVHD was histologically characterized as moderate to severe in groups 2 and 3 (short course immunosuppression) and as mild in groups 4 and 5 (long-term immunosuppression).

Survival - Clinical evidence of GVHD after transplant, such as diffuse erythema (particularly on the ears and extremities), hyperkeratosis of the footpads, skin infections, anorexia, diarrhea, unkempt appearance and weight loss were the common pattern in irradiated groups, started 3 weeks after transplant. Median survival time was 54,36, 45, 78 and 70 days in groups 1,2,3, 4 and 5 respectively. With exception of group 1 where rejection was the cause of death, all animals in groups 2, 3, 4 and 5 died of GVHD.

Chimeric studies - Figure 1 and Table 1 shows the total chimerism levels (CD3+ and others cells) in all groups.



Group 1 < Groups 2,3,4 and 5 ($p < 0.05$)

FIGURE 1 - Total chimerism (CD3+ and other cells) between groups.

TABLE 1 - Average of total chimerism (CD3+ and other cells) and donor T-cells chimerism in peripheral blood in experimental groups.

Experimental Groups	FK dose	%Total donor Cells	% donor CD3+ Cells in Blood	Median Survival(days)
Itx+UBM (n=6)	5 days	0.2 to 12	0.0 to 2.9	54
Itx+UBM+Rt (n=9)	5 days	11.7 to 39.8	0.6 to 20.6	36
Itx+TCD-BM+Rt (n=4)	5 days	4.8 to 69.7	0.3 to 14.3	45
Itx+UBM+Rt (n=5)	15 days	2.1 to 64.5	5.7 to 32.2	78
Itx+TCD-BM+Rt (n=6)	15 days	2.24 to 72.53	10 to 26.7	70

Itx: intestinal transplant; Rt: radiation

Group 1 < Groups 2,3,4 and 5 (p< 0.05)

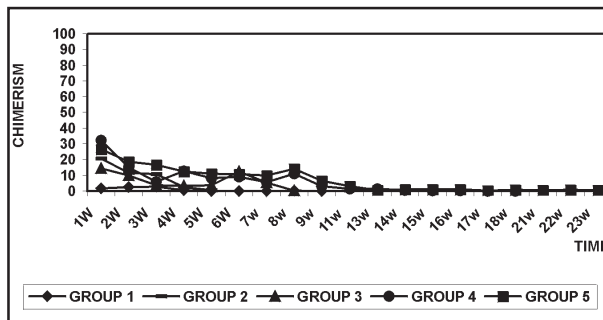
The median chimerism varied from 0.24% to 12% in group 1, 11.78% to 39.84% in group 2, 4.81% to 69.78% in group 3, 2.17% to 64.56% in group 4 and 2.24% to 72.53% in group 5. The total chimerism and the donor T-cell (CD3+) chimerism (Figure 2 and Table 1) reached the high levels in irradiated groups when compared to non-irradiated group (p<0.05). No differences in total chimerism levels were observed between irradiated groups.

the strategy used in this study to deplete de donor bone marrow from mature T-cells when compared to UBM. Rat bone marrow contains sufficient number of mature T-cells, the most important effector cell subsets in initiating a rejection response against the recipient³. Therefore, removal of these cells effectively prevent the occurrence of GVHD. Previous reports⁴ showed that permanent donor-specific tolerance can be achieved for vascularized allografts through mixed chimerism without evidence of GVHD.

However, when BM are used after small bowel transplantation, the characteristics and dose of transferred hematopoietic and lymphoid tissue within the graft requires associated strategies in order to immunomodulate the response after transplant. The passenger leukocytes in the intestine have been shown to have inferior tolerogenic qualities compared with BM cells; in addition, have a lineage profile that predisposed to GVHD⁵.

The high levels of donor CD3+ cells in peripheral blood in the first two weeks after transplant observed in this study were probably the critical factor in the occurrence of GVHD after transplant. Despite the use of TCDBM in G3 and G5, no further decrease in the levels of peripheral donor T cells was observed, suggesting that T cells from the intestinal graft (rather than from the bone marrow), are the cells responsible for the GVHD development. Therefore, immunomodulatory preconditioning regimens addressing the intestinal graft before the transplant seems to be a logical approach in order to enhance the allograft and recipient survival.

We are now evaluating if the combination of donor preconditioning with antilymphocyte serum with the current model can further improve the results after small bowel transplantation.



Group 1 < Groups 2,3,4 and 5 (p < 0.05)

FIGURE 2 - Donor CD3+ cells in peripheral blood between groups.

Discussion

These results suggest that a nonmyeloablative regimen based in low dose of irradiation and an extended course of immunosuppression did not enhance the allograft and recipient survival after small bowel transplantation. Extended immunosuppression was the critical factor in reducing the severity of rejection and GVHD after transplant when associated with low dose of irradiation. The occurrence of GVHD was the common pattern in irradiated groups, not avoided by

Conclusion

Extended immunosuppression associated to low doses of irradiation decrease the severity of GVHD, not avoided by the use of TCDBMI.

References

1. Sharabi Y, Sachs DH. Mixed chimerism and permanent specific transplantation tolerance induced by a nonlethal preparative regimen. *J Exp Med* 1989;169:493-9.
2. Monchik GJ, Russel A. Transplantation of small bowel in the rat: technical and immunological considerations. *Surgery* 1971; 70:693-7.
3. Exner BG, Acholonu I, Ildstad ST. Hematopoiet chimerism, tolerance induction and graft-versus-host disease: considerations for composite tissue transfer. *Transplant Proc* 1998; 30: 2718-22.
4. Colson YI, Zadach K, Nalesnik M, Ildstad ST. Mixed allogeneic chimerism in the rat. *Transplantation* 1995; 60 (9): 971-8.
5. Murase N, Ye Q, Lee RG, Demetris AJ, Abu-Elmagd K, Reyes J, Starzl TE. Immunomodulation of intestinal transplant with allograft irradiation and simultaneous donor bone marrow infusion. *Transplant Proc* 1999; 40: 565-70.

Bakonyi Neto A, Misiakos EP, Tzakis AG, Behro M, Ruiz P, Miller J, Ricordi C, Takegawa BK. Reação do enxerto versus hospedeiro após infusão de células T depletadas da medula óssea no transplante de intestino delgado em ratos. *Acta Cir Bras [serial online]* 2003 Mar-Abr;18(2). Disponível em URL: <http://www.scielo.br/acb>.

RESUMO - Baixas doses de irradiação associadas à infusão de células da medula óssea não previnem a ocorrência da reação do enxerto versus hospedeiro após o transplante intestinal. **Objetivo:** Neste estudo foi avaliado a potencial vantagem em estender o regime imunossupressor associado a infusão de células de medula óssea do doador depletadas de células T na prevenção da reação do enxerto versus hospedeiro após o transplante intestinal. **Métodos:** Transplante heterotópico de intestino delgado foi realizado em ratos Lewis como receptores e DA como doadores, distribuídos em cinco grupos de acordo com a duração da imunossupressão, irradiação e do uso de medula óssea normal ou depletada: G1 (n=6), sem irradiação e G2 (n=9), G3 (n=4), G4 (n=5) e G5 (n=6) foram irradiados com 250 rd. Grupos 1, 2, 4 e G3 e 5 foram infundidos com 100×10^6 células da medula normal e depletada respectivamente. Animais no G1,2,3 foram imunossuprimidos com 1mg/kg/FK506/ IM por cinco dias e G4 e cinco por 15 dias. Anticorpos monoclonais contra células CD3 e colunas magnéticas foram utilizadas para a depleção da medula óssea. Os animais foram examinados para a presença de rejeição, reação do enxerto versus hospedeiro, chimerismo e biópsias intestinais e da pele. **Resultados:** Rejeição mínima foi observada em todos os grupos; entretanto, a reação do enxerto versus hospedeiro somente nos animais irradiados. Extensão da imunossupressão alterou a gravidade da reação nos animais dos G4 e 5. Rejeição foi a causa mortis no G1 e a reação do enxerto versus hospedeiro nos Grupos 2,3,4 e 5, não controlada com a infusão de medula óssea depletada. O chimerismo total e de células T do doador foi estatisticamente maior nos grupos irradiados em comparação ao G1. **Conclusão:** A extensão do regime de imunossupressão associado a baixas doses de irradiação diminui a gravidade da reação do enxerto versus hospedeiro, não abolida pelo uso de medula óssea depletada.

DESCRITORES - Transplante intestinal. Depleção de células T. Medula óssea.

Conflict of interest: none

Financial source: none

Correspondence:

Alexandre Bakonyi Neto

Rua Hortência, 66

18603-660 Botucatu - SP

fefofof@laser.com.br

Data do recebimento: 10/11/2002

Data da revisão: 02/12/2002

Data da aprovação: 18/12/2002