

REFERÊNCIAS

1. Ise T, Ohtsuk H, Matsumoto K, Sano R. Management of the malignant testicular tumor in children. *Cancer* 1976;37:1539-47.
2. Haas RJ, Schmidt P. Testicular germ cell tumors in childhood and adolescence. *World J Urol* 1955;13:203-8.
3. Ross JH, Rybicki L, Kay R. Clinical behavior and contemporary management algorithm for prepubertal testis tumors: A summary of the prepubertal testis tumor registry. *J Urol* 2002;168:1675-9.
4. Kay R. Prepubertal testicular tumor registry. *J Urol* 1993;150:671-4.
5. Perlman EJ, Valentine MB, Griffin CA, Look AT. Deletion of 1 p36 in childhood endodermal sinus tumors by two-color fluorescence in situ hybridization. A Pediatric Oncology Group Study. *Genes Chromosomes. Câncer* 1996;16:15-20.
6. Coppes MJ, Rackley R, Kay R. Primary testicular and paratesticular tumors of childhood. *Med Pediatr Oncol*. 1994;22:329-40.
7. Kramer AS, Kelalis PP. Testicular tumors in children. In Javadpour N ed Principles and management of testicular cancer. New York. Thieme. 1986.
8. Klee GG, Go VLW. Serum tumor markers. *Mayo Clin Proc* 1982;57:129-32.
9. Lange PH, Vogelzang NJ, Goldman A. Marker half life analysis as prognostic tool in testicular cancer. *J Urol*. 1982;128:708-11.
10. Albin A, Isaacs H Jr. Germ cell tumor. In: Pizzo PA. Poplack DG, eds. Principles and Practice of Pediatric Oncology. 2nd ed. Philadelphia: JB Lippincott, 1993.
11. Rushton G, Belman AB, Sesterbenn I. Testicular sparing surgery for prepubertal teratome of the testis: A clinical and pathological study. *J Urol*. 1990; 144:726-40.
12. Pearse J, Glick RD, Abramson SJ. Testicular-sparing surgery for benign testicular tumors. *J Pediatr Surg* 1999;23:70-1.
13. Walker BR, Skoog SJ, Winslow BH. Testis sparing surgery for steroid unresponsive testicular tumors of the adrenogenital syndrome. *J Urol* 1997;157:1460-3.
14. Young RH, Koeliker DD, Scully RE. Sertoli cell tumors of the testis not otherwise specified: A clinicopathologic analysis of 60 cases. *Am J Surg Pathol* 1998;22:709-21.
15. Garbrilove JL, Freiberg EK, Leiter E, Nicolis GL. Feminizing and nonfeminizing Sertoli cell tumors. *J Urol*. 1980;124:757-67.
16. Sharma S, Seam RK, Kapoor HL. Malignant Sertoli cell tumor of the testis in a child. *J Surg Oncol* 1990;44:129-31.

Cologna AJ, Martins ACP, Suaid AJ, Tucci Jr S, Celini FM, Paschoal RM, Paschoalin EL. Testicular tumors in childhood. *Acta Cir Bras* 2003 [serial online] vol 18 suppl 5. Available in www.scielo.br/acb

ABSTRACT – This is a review article on epidemiology, diagnosis and treatment of testes tumors in childhood that represents 1 to 2% of the solid. Germ tumors represent 60 to 75% of pediatric testes tumors of whom the most common is the yolk sac tumor that usually is treated by radical orchiectomy. Teratoma is the second in frequency that has a benign behavior in childhood and can be managed by watchful waiting or partial orchiectomy. Leydig cell and Sertoli cell tumors are the most common of the gonad stroma and both can be treated plain orchiectomy.

KEY WORDS: Yolk sac tumor. Teratoma. Leydig, Sertoli. Testes

Correspondência:

Adauto José Cologna
Departamento de Cirurgia – FMRP-USP
Av. Bandeirantes, 3.900 – 9º Andar
Ribeirão Preto, SP, CEP: 14048-900

20 – RELATO DE CASO

Right retroesophageal subclavian artery

Valéria Paula Sassoli Fazan¹, Rogério Alves Ribeiro², João Alberto S. Ribeiro², Omar Andrade Rodrigues Filho³

Fazan VPS, Ribeiro RA, Ribeiro JAS, Rodrigues Filho OA. Right retroesophageal subclavian artery. *Acta Cir Bras* [serial online] 2003 vol 18 suppl 5. Available in www.scielo.br/acb.

ABSTRACT – Purpose: The subclavian arteries can vary on their origin, course or length. One of the most common anatomical variations is the right subclavian artery originating as the last branch of the aortic arch. This artery is known as a retroesophageal right subclavian artery or “lusory artery”. The right retroesophageal subclavian artery usually is described as not producing symptoms, being most discoveries coincidental. Nevertheless, it may be the site of formation of atherosclerotic plaque, inflammatory lesions or aneurysm. **Case Report:** The present study describes a case of right retroesophageal subclavian artery and discusses the findings according to their clinical and surgical implications. **Conclusion:** The anatomic and morphologic variations of the aortic arch and its branches are significant for diagnostic and surgical procedures in the thorax and neck. If a right retroesophageal subclavian artery is diagnosed during aortic arch repair, corrective surgery should be considered. Intensive care patients should be screened before long term placement of nasogastric tube, in order to avoid fistulization and fatal hemorrhage.

KEY WORDS: Vascular anatomy. Arterial variations. Subclavian artery. Aortic arch. Neck surgery.

1. Assistant Professor, Department of Surgery and Anatomy, School of Medicine of Ribeirão Preto, University of São Paulo, Ribeirão Preto, São Paulo, Brazil
2. Medical Student, School of Medicine of Triângulo Mineiro, Uberaba, Minas Gerais; Brazil
3. Graduate Student and Instructor in Anatomy, School of Medicine of Triângulo Mineiro, Uberaba, Minas Gerais; Brazil

INTRODUCTION

The subclavian arteries can vary on their origin, course or length. Right retroesophageal subclavian artery (RRESA) is a frequent defect of the embryological aortic arches and its incidence is estimated at between 0.5 and 1.8%.¹ This variation is due to interruption of the fourth right aortic arch between the notches for the common carotid artery and subclavian artery while the left fourth arch remains intact.² A regression of the right subclavian artery proximal portion occurs and the retroesophageal aortic arch persists.³

The RRESA is usually described as not producing symptoms, being most discoveries coincidental. Nevertheless, it may be the site of formation of atherosclerotic plaque, inflammatory lesions or aneurysm.² The seriousness of RRESA aneurysm is associated with the high risk of clot-related events, tracheal or venous compression and rupture.^{4,5}

The anatomic and morphologic variations of the aortic arch and its branches are significant for diagnostic and surgical procedures in the thorax and neck. The present study describes a case of RRESA and discusses the findings according to their clinical and surgical implications.

CASE REPORT

During a routine dissection at the School of Medicine of Triângulo Mineiro Human Anatomy Laboratory, an unusual origin and course of the carotid arteries and the right subclavian artery was observed. The body was that of a 54-year-old white female. Particular care was taken in dissecting the regions of the neck and thorax to preserve the aortic arch and its branches. With the aid of an electronic digital caliper (range of 0-300 mm, resolution 0.01mm, Gehaka, SP, Brazil), the diameters and total length of the common carotid arteries were measured from their point of origin to their terminal branching. The diameters of the subclavian arteries at their point of origin were also measured. A common trunk of the right and left common carotid artery (bicarotid trunk), the left subclavian artery and the RRESA were derived from the aortic arch in that order (Figure 1). The right recurrent laryngeal nerve was not formed, but the nerves to the larynx and esophagus branched directly from the vagus as it descended in the neck. The diameters of the common carotid arteries at their point of origin were 1.2 and 1.1 cm for the right and left sides, respectively. At the bifurcation level, the diameters were 1.5 cm for the right and 1.4 cm for the left sides, with total lengths of 12.6 and 11.1 cm, respectively. The diameters of the subclavian arteries at their point of origin were 1.2 cm for the left vessel and 1.6 cm for the retroesophageal vessel. Dissection of the cadaver was continued until its reduction to a small block that contained the structures of interest and was photographed in a posterior view (Figure 1).

This unexpected laboratory finding led us to a retrospective study on the frequency of the presence of a RRESA in our material. From the

anatomical variations recordings of the Human Anatomy Discipline of the School of Medicine of Triângulo Mineiro, 472 cadavers were investigated for the presence of a RRESA, in a total of 126 female (60 white and 66 black) and 346 male (175 white and 171 black). Two other recordings were found, turning this case the third

one. Both RRESA were found on male white cadavers, one of them with a history of mental disorder that could be not well characterized in our records. The percentages of our recordings, including the one reported here are of 0.63% in total (3 of 472), being 0.58% in male (2 of 346) and 0.78% in female (1 of 126).

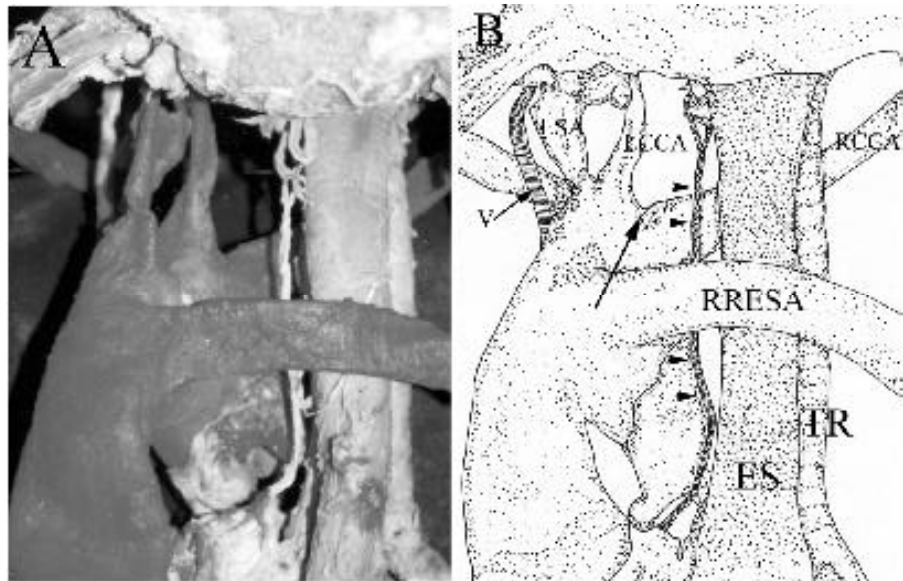


FIGURE 1 - Photograph (A) and schematic drawing (B) of the posterior view of the dissected right retroesophageal subclavian artery (RRESA). Note that the common carotid arteries have a common origin in a bicarotid trunk (arrow). The left subclavian artery (LSA) has a normal origin while the RRESA originates distal and posterior from the aortic arch. V indicates the left vagus nerve and the arrowheads indicate the left recurrent laryngeal nerve. RCCA = right common carotid artery, LCCA = left common carotid artery, ES = esophagus and TR = trachea.

DISCUSSION

Since the incidence of a RRESA is reported to range from 0.2% to 2.5%,⁶ this anomaly is not markedly rare and our percentage is in accordance to that reported in the literature.

The RRESA is more frequent in women⁷ and mongoloid children⁸ and is also associated with Chromosome 22q11 deletion.³ Our casuistic is small (only 3 cases, 1 female and 2 male) but we found that one of our male cadavers had a mental disorder not well characterized. Since the frequency of a RRESA is high in at least two genetic disorders mentioned above, and most of these diseases course with mental disorders, this could be an explanation why we had more male than female cadavers with the variation since it is described to be more frequent in women.

Although described as usually asymptomatic,⁹ the RRESA can cause dysphagia lusoria as a clinical finding, due to the compression of the esophagus between the right common carotid artery and the trachea anterior to it and the right subclavian artery posterior to it. Nevertheless, acute ischemia of the right upper limb due to thrombosis of an aberrant subclavian artery was described by Akers Jr et al.¹⁰ and Boas et al.⁹ Akers Jr et al.¹⁰ reported a case of nonocclusive and presumably nonatherosclerotic thrombosis in a 35-year-old woman that led to an extensive distal embolization requiring amputation of the right hand. Boas et al.⁹ reported a case of acute

ischemia of the right upper extremity due to an extensive thrombosis of a RRESA in a 79-year-old woman that was successfully treated by extensive thrombectomy of the arteries in the upper extremity and right subclavian-to-carotid artery transposition. In both cases, the authors mention the delayed diagnosis of the underlying etiology of the thrombosis. This is a clear example of when knowledge of an anatomical variation is helpful in clinical practice. The presence of a RRESA should be considered especially when ischemia of the upper limb is severe and occlusion is located at the shoulder level.

Another rare but clinically important complication of the RRESA is the arterioesophageal fistula, an usually fatal event. The presence of a RRESA is a risk factor for rupture into the esophagus because the close anatomical relationship between the aberrant artery and the upper respiratory and digestive tract.² The mechanism underlying the development of a fistula involves the induction of limited necrosis of the digestive and arterial walls by pulsatile compression of the esophageal wall between the RRESA and a rigid intubation catheter. Feugier et al.² revised the literature and found 11 cases of fistula between a nonaneurysmal retroesophageal subclavian artery and the esophagus. Hematemesis was precipitated by esogastric intubation in all cases. Fistulization

was associated with predisposing factors in three reports and hemorrhage was fatal in seven cases. Feugier et al.² test that clinical diagnosis of this complication is difficult because of its extreme rarity. In the absence of any evidence suggesting the possibility of an anomaly of the aortic arch system, there are no specific manifestations. They also conclude that the extreme unfavorable prognosis of this rare complication combined with the relatively high incidence of the RRESA in the general population underlines the need of prevention. If a RRESA is diagnosed during aortic arch repair, corrective surgery should be considered. Intensive care patients should be screened before long term placement of nasogastric tube.

REFERENCES

1. Richardson J, Doty D, Rossi N. Operation for Aortic Arch Anomalies. *Ann Thorac Surg* 1981; 31: 426-32.
2. Feugier P, Lemoine L, Gruner L, Bertin-Maghit M, Rousselet B, Chevalier JM. Arterioesophageal Fistula: A Rare Complication of Retroesophageal Subclavian Arteries. *Ann Vasc Surg* 2003; 17: 302-5.
3. Momma K, Matsuoka R, Takao A. Aortic Arch Anomalies Associated with Chromosome 22q11 Deletion (CATCH 22). *Pediatr Cardiol* 1999; 20: 97-102.
4. Roland CF, Cherry KJ. Symptomatic Atherosclerotic Stenotic Disease of an Aberrant Right Subclavian Artery. *Ann Vasc Surg* 1991; 5: 196-8.
5. Schmidt FE, Hewitt RL, Flores Jr AA. Aneurism of Anomalous Right Subclavian Artery. *J Vasc Surg* 1992; 16: 90-5.
6. Nakatani T, Tanaka S, Mizukami S. Anomalous Triad of a Left-Sided Inferior Vena Cava, a Retroesophageal Right Subclavian Artery, a Bilateral Superficial Brachial Arteries in One Individual. *Clin Anat* 1998; 11: 112-7.
7. Easterbrook JS. Identification of aberrant right subclavian artery on MR images of the cervical spine. *J Magn Reson Imaging* 1992; 2: 507-9.
8. Goldstein WB. Aberrant subclavian artery in mongolism. *Am J Roentgenol* 1965; 93: 131-4.
9. Boas N, Desmoucelle F, Bernadet V, ranceschi JC. Rare Cause of Acute Ischemia of the Right Upper Extremity: Thrombosis of a Retroesophageal Subclavian Artery. *Ann Vasc Surg* 2002; 16: 387-90.
10. Akers Jr DL, Fowl RJ, Plettner J, Kempczinski RF. Complications of Anomalous Origin of the Right Subclavian Artery: Case Report and Review of the Literature. *Ann Chir Vasc* 1991; 5: 358-88.

Fazan VPS, Ribeiro RA, Ribeiro JAS, Rodrigues Filho OA. Right retroesophageal subclavian artery. *Acta Cir Bras* [serial on line] 2003 vol 18 suppl 5. Disponível em www.scielo.br/acb.

RESUMO – Objetivo: A artéria subclávia pode ser variável em sua origem, trajeto e/ou comprimento. Uma das variações anatômicas mais comuns é a origem da artéria subclávia direita como o último ramo do arco aórtico. Essa artéria é conhecida como artéria subclávia retroesofágica ou “artéria lusória”. A artéria subclávia direita retroesofágica é comumente descrita como assintomática, sendo os achados, na maioria das vezes, acidentais. Entretanto, essa artéria pode ser um sítio de formação de placas ateromatosas, lesões inflamatórias ou até aneurismas. **Relato de Caso:** O presente estudo descreve um caso de artéria subclávia direita retroesofágica e discute os achados de acordo com sua importância clínica e implicações cirúrgicas. **Conclusão:** Variações anatômicas do arco aórtico e seus ramos são significantes para diagnósticos e procedimentos cirúrgicos do pescoço e do tórax. Caso uma artéria subclávia direita retroesofágica seja diagnosticada durante uma cirurgia do arco aórtico, um procedimento corretivo deve ser considerado. Pacientes em terapia intensiva devem ser investigados para a presença dessa variação anatômica antes de uma sondagem nasogástrica de longa duração para se evitar complicações como fístulas e hemorragia.

DESCRIPTORES: Anatomia vascular. Variações arteriais. Artéria subclávia. Arco aórtico. Cirurgia cervical.

Correspondence to:

Valéria Paula Sassoli Fazan, M.D.; Ph.D.
Department of Surgery and Anatomy
School of Medicine of Ribeirão Preto – University of São Paulo
Av. Bandeirantes 3900, Ribeirão Preto – SP
14049-900 – Brazil
Phone: + 55 16 602-2407
FAX: + 55 16 633-0017
e-mail: vpsfazan@fmrp.usp.br
Conflict of interest: None

Financial Support: CNPq grant nº 501230/2003-3 and FAPESP grant nº 02/09406-5.

Rogério Alves Ribeiro was the recipient of a fellowship from the PIBIC, CNPq while the study was carried out.