

Fibroplasia after polypropylene mesh implantation for abdominal wall hernia repair in rats¹

Fibroplasia após implante de tela de polipropileno para correção de hérnia da parede abdominal em ratos

Márcia Vaz¹, Rodrigo Ketzer Krebs^{II}, Eduardo Neubarth Trindade^{II}, Manoel Roberto Maciel Trindade^{III}

¹ PhD, Post-Graduate Program in Surgery, UFRGS, Porto Alegre, Brazil.

^{II} MD, Department of Surgery, Division of Gastrointestinal Surgery, HCPA/UFRGS, Porto Alegre, Brazil.

^{III} PhD, Associate Professor, Department of Surgery, Division of Gastrointestinal Surgery, HCPA/UFRGS, Porto Alegre, Brazil.

ABSTRACT

Purpose: This study assessed the collagen deposition and correlated it with local inflammatory responses to evaluate the length of time required for fibroplasia when polypropylene meshes are used to repair incisional abdominal wall hernias in rats. **Methods:** Thirty-six male Wistar rats underwent longitudinal resection of a peritoneal and musculoaponeurotic tissue segment (3x2 cm) of the abdominal wall followed by defect reconstruction with polypropylene mesh bridging over aponeurosis. The animals were divided into 6 groups according to the time points for the analysis of fibroplasia: 1, 2, 3, 7, 21 and 30 days post-implantation. Animals were sacrificed at each time point, and the site where the polypropylene mesh was implanted was evaluated histologically to assess inflammatory response and percentage of collagen using computer-assisted videomorphometry. **Results:** Total collagen was found at the mesh site on the 3rd day post-implantation, and increased progressively on all subsequent days up to the 21st day, when it reached its highest percentage ($p < 0.001$). Type III collagen increased progressively from the 3rd to the 21st days, when it reached its highest percentage ($p < 0.001$); on the 30th day, it decreased significantly ($p > 0.001$). Type I collagen was first found between the 7th and 21st days; it reached its highest percentage on the 21st day and then remained stable until the 30th day. The type I to type III collagen ratio increased significantly and progressively up to the 30th day ($p < 0.001$). Neutrophils were found at the mesh site from the 1st to the 21st day post-implantation. Macrophages, giant cells and lymphocytes were seen on the 2nd day. Thirty days after mesh implantation, neutrophils disappeared, but the percentages of macrophages, giant cells and lymphocytes remained stable ($p < 0.001$). **Conclusions:** This study showed that total collagen was first seen on the 3rd day post-implantation, with a higher percentage of type I collagen at the last observational time point. The prolonged healing inflammatory response and the persistence of chronic inflammation surrounding to the mesh did not affect the length of time required for fibroplasia.

Key words: Abdominal Wall. Collagen. Hernia. Surgical Mesh. Polypropylenes. Neutrophils. Rats.

RESUMO

Objetivo: Avaliar o tempo de fibroplasia em tela de polipropileno na correção de hérnias incisionais da parede abdominal, em ratos, através da quantidade de colágeno, correlacionando-o com a resposta inflamatória local. **Métodos:** Trinta e seis ratos machos da linhagem Wistar foram submetidos à ressecção longitudinal de um segmento músculo-aponeurótico e peritoneal (3x2 cm) da parede abdominal, seguida por reforço com tela de polipropileno, em forma de ponte sobre a aponeurose. Os animais foram distribuídos em seis grupos, de acordo com o tempo de fibroplasia a ser estudado (1, 2, 3, 7, 21 e 30 dias de pós-operatório). Após os prazos estabelecidos para estudo da fibroplasia, os animais foram submetidos à eutanásia, e a área de fixação da tela de polipropileno foi avaliada histologicamente quanto à reação inflamatória e à percentagem de colágeno pela técnica videomorfométrica assistida por computador. **Resultados:** Houve aparecimento de colágeno total junto à tela no 3º dia pós-implante, com aumento progressivo na sua proporção em todos os dias subsequentes até o 21º dia, quando atingiu sua proporção máxima ($p < 0,001$). A partir do dia 3, o colágeno III sofreu um aumento progressivo até o dia 21, quando atingiu sua proporção máxima ($p < 0,001$), e no 30º dia apresentou uma redução significativa ($p < 0,001$). O colágeno tipo I surgiu entre o 7º e o 21º dia, apresentou sua máxima proporção no 21º dia e manteve-se inalterado até o final do período de observação. A relação colágeno tipo I/tipo III aumentou progressivamente e inverteu-se no 30º dia de observação ($p < 0,001$). Os neutrófilos foram identificados no 1º dia pós-implante, mantendo-se junto à tela até o 21º dia. Os macrófagos, gigantócitos e linfócitos foram identificados no 2º dia. Trinta dias após a implantação da tela, desapareceram os neutrófilos e mantiveram-se estáveis as proporções de macrófagos, gigantócitos e linfócitos ($p < 0,001$). **Conclusões:** Os resultados do presente estudo evidenciaram a presença de colágeno no 3º dia pós-implante, com predomínio do colágeno tipo I ao final do período de observação. O prolongamento da resposta inflamatória da cicatrização e a persistência do processo inflamatório crônico junto à tela não interferiram no tempo da fibroplasia.

Descritores: Parede Abdominal. Colágeno. Hérnia. Telas Cirúrgicas. Polipropilenos. Neutrófilos. Ratos.

¹Research performed at Department of Surgery, Division of Gastrointestinal Surgery, Federal University of Rio Grande do Sul (UFRGS), Porto Alegre, Brazil.

Introduction

Repair of large abdominal wall hernias has always been a challenge for surgeons. At the end of the 1950s, the introduction of polypropylene mesh by Usher *et al.*¹ was a great step forward in the definitive treatment of hernias and led to a significant reduction in the rate of recurrences^{2,3}. The characteristics of the polypropylene meshes include some of the properties needed for the biomaterials described by Cumberland⁴ and Scales⁵.

Currently there are several synthetic materials available, but polypropylene mesh is definitely the most widely used, with the most recorded experience^{6,7}. The main characteristic of these meshes are that they are inert when infection occurs, that they maintain the tensile strength of the abdominal wall and have an excellent capacity for integration², besides being low cost and malleable, and they have already been tested for years.

In the literature there are many studies evaluating the reaction of the organism to the presence of the polypropylene screen, which is widely used to correct abdominal wall defects of many different etiologies. Most of these studies seek to determine the rates of recurrence, infection and inflammatory response, and the presence of adhesions associated with the use of different mesh types currently available in the market⁷⁻⁹.

It has been shown that the polypropylene mesh becomes intensely covered by dense fibrotic tissue⁸, and that fibrosis results from the local reaction to tissue damage and to the mesh used. The fibroplasia process consists of a harmonious and coordinated sequence of cellular and molecular events which interact to promote the repair and reconstruction of damaged tissue¹⁰⁻¹³. Its extent depends on the level of inflammatory activity, one of the healing stages¹⁴⁻¹⁶, and is a prerequisite for the reconstruction of a mechanically stable abdominal wall. Reinforcement of the abdominal wall with polypropylene mesh is achieved by the increase in the tensile strength of the prosthetic material and as a result of fibrotic reaction induced by the mesh. Biointegration occurs as a result of the infiltration of the inflammatory cells and deposition of connective tissue¹⁷.

Although the polypropylene mesh is widely used to repair abdominal wall defects, and even though there are studies comparing host response to the type of mesh used or to the host's age, no data exist on the length of time required for fibroplasia and, consequently, on the behavior of the aponeurotic healing in polypropylene mesh incorporation, upon which the resistance and integrity of the abdominal wall depend. The aim of the present study is to evaluate the length of time required for fibroplasia when polypropylene meshes are used, by determining the amount of total collagen and type I and type III collagen at different times in the process, correlating it with local inflammatory response.

Methods

The study was a non-controlled experiment with 36 male Wistar (*Ratus norvegicus albinus*) rats weighing between 180 and 220 g. The animals were divided into six groups and handled in compliance with the technical requirements and international guidelines for animal research¹⁸. Anesthesia was performed using a solution of 10% ketamine chlorhydrate (Ketalar® Agener União 100 mg/ml) and 2% xylazine chlorhydrate (Calmium® Agener União 20 mg/ml), in doses of 100 mg/kg and 10 mg/kg IM, respectively^{8,18}.

Under aseptic conditions, a 6-cm midline skin incision was made below the xiphoid process, followed by dissection of the subcutaneous tissue for approximately 4 cm on each side and visualization of the musculoaponeurotic layer. Then an ellipsoid segment in the midline plane was excised, which included the musculoaponeurotic layer and the peritoneum, with 3 cm on the longitudinal axis and 2 cm on the cross-sectional one. For hemostasis, we used continuous suture of the edge with 4-0 polypropylene thread. The musculoaponeurotic defect was repaired by the placement of a 4-cm monofilament polypropylene mesh on the longitudinal axis and of a 3-cm mesh on the transversal one, fixing it with eight 4-0 polypropylene stitches, with the edges of the prosthesis bridging over the anterior aponeurotic plane. The inner surface of the prosthesis was allowed direct contact with the intraabdominal viscera, whereas the outer surface was in direct contact with the subcutaneous tissue. The skin was stitched with continuous suture using a 4-0 monofilament nylon thread. After surgery, the rats were kept in their cages, with available food and water, up to evaluation time.

The times of study established were 1, 2, 3, 7, 21 and 30 postoperative days, and six rats were randomly chosen for each time point. The animals were euthanized using 10% ketamine chlorhydrate and 2% xylazine chlorhydrate. We made an incision at the site of the previous scar and pulled the subcutaneous tissue approximately 5 cm apart from each side of the midline for broad visualization of the abdominal wall and mesh. The abdominal wall was cut open in the left inguinal region, and the musculoaponeurotic layer and mesh were removed, leaving a 1-cm margin beyond the mesh perimeter. The specimens were placed on Styrofoam plates and fixed in buffered formalin (10% formaldehyde buffer solution).

The collected samples were embedded in paraffin blocks, sectioned at a 4 µm thickness and stained with hematoxylin-eosin and Picosirius. The macroscopic orientation of the sections was performed transversally to the meshes.

Hematoxylin-eosin staining allowed for the identification and quantification of inflammatory response with a score based on a predefined scale of 0-3. The slides were analyzed by one pathologist, according to the protocol described in Table 1.

The polarized light Picosirius technique allows the identification of collagen due to its strong birefringence, and two types of collagen fibers can be distinguished: type I collagen (mature collagen) appears orange-red, whereas type III collagen fibers (immature collagen) are green or greenish^{19,20}.

The videomorphometric technique allows the evaluation of slides stained with Picosirius by polarized light using an imaging system (microscope with associated videocamera), and performing a count of the areas filled by collagen and the areas without this element. The amount of collagen on the slides stained with Picosirius polarized light was determined based on the number of birefringent areas. A Zeiss® microscope, model Primo Star, with a Sony (Tokyo, Japan) videocamera was used. The video signal was digitized into 24 bits on a Pentium 133 Megahertz (MHz) PC, using a resolution of 640 (horizontal) and 480 (vertical) pixels and 16 million colors. Image Pro Plus, version 4.1 for Windows 98 (Media Cybernetics, Silver Spring, U.S.A.) was used, and the images were saved in TIFF format. Ten microscopic fields were digitized using a 200x magnification. Morphometric analysis began by segmenting the image, which corresponds to the delimitation of the area of interest in each image. Thereafter,

the program measured the percentage of the previously segmented area of interest in relation to the whole field. This stands for the amount of total collagen. In a new segmentation, the areas with green or greenish birefringence were selected. The measurement of these areas corresponds to type III collagen. The results are expressed as the ratio between type I and type III collagen fibers^{19,21}.

The statistical analysis was made using program SPSS (*Statistical Package for Social Sciences*), version 12, and program WINPEPI DESCRIBE, version 1.55. The chi-square test and Monte Carlo method were used for calculation and Tukey's test was used

for multiple comparisons in the analysis of categorical variables (neutrophils). The analysis of variance between groups (ANOVA) was used, with Tukey's and Dunnett's post-tests for multiple comparisons for the quantitative variables (macrophages, giant cells, lymphocytes and collagen). A significance level of 0.05 ($\alpha \leq 0.05$) was established for all statistical tests.

The study protocol was approved by the Research Ethics Committee of Hospital de Clínicas de Porto Alegre, affiliated with the Graduate Program of the Medical School at Universidade Federal do Rio Grande do Sul (UFRGS), Porto Alegre, Brazil.

TABLE 1 – Assessment of inflammatory response

Infiltration	Macrophages	Giant cells	Lymphocytes	Neutrophils
Absent (0)	Absence of cells	Absence of cells	Absence of cells	Absence of neutrophils (0)
Mild (1)	Does not completely surround the mesh thread	From 1 to 2 giant cells around the mesh thread	From 1 to 2 lymphocytes around the mesh thread	
Moderate (2)	Completely surrounds the mesh thread	From 3 to 5 giant cells around the mesh thread	From 3 to 5 lymphocytes around the mesh thread	Presence of neutrophils (1)
Intense (3)	Completely surrounds the mesh thread to a thickness 2 to 3 times greater than in the moderate case	Over 5 giant cells around the mesh thread	Over 5 lymphocytes around the mesh thread	

Results

No postoperative deaths were observed. There was no mesh infection or rejection during the study period.

The inflammatory response to the polypropylene mesh was assessed by histological exam (hematoxylin-eosin method), whose findings are summarized in Table 2.

TABLE 2 – Microscopic assessment of inflammatory response

Day	Macrophages*	Giant cells*	Lymphocytes*	Neutrophils**
1	0.00 ± 0.00 ^a	0.00 ± 0.00 ^a	0.00 ± 0.00 ^a	100% ^a
2	1.00 ± 0.00 ^b	0.67 ± 0.52 ^b	1.00 ± 0.00 ^b	100% ^a
3	1.50 ± 0.55 ^b	1.00 ± 0.00 ^b	2.83 ± 0.41 ^c	100% ^a
7	2.17 ± 0.41 ^b	2.50 ± 0.55 ^c	2.33 ± 0.52 ^c	100% ^a
21	2.83 ± 0.41 ^b	2.00 ± 0.00 ^c	1.17 ± 0.41 ^d	33% ^a
30	2.33 ± 0.52 ^b	2.00 ± 0.00 ^c	1.00 ± 0.00 ^d	0% ^b

*Values expressed as mean ± SD. ANOVA between different days showed significant difference for p<0.001

**Values expressed as absolute (relative) frequency. Pearson's chi-square test using Monte Carlo method between different days showed significant difference for p<0.001

The ratios and percentage means designated by the same letter do not show significant differences (α = 0.05) according to Tukey's test for multiple comparisons.

On the 1st day post-implant, only neutrophils were observed, indicating an acute inflammatory process. Macrophages, giant cells and lymphocytes were identified on the 2nd day, and the proportion of neutrophils remained stable. Neutrophils, macrophages and giant cells remained unchanged on the 3rd day, compared to the previous day, and an increased proportion of lymphocytes was observed (p<0.001). One week after mesh implantation, the neutrophils, macrophages and lymphocytes did not present any significant change in their proportion, and there was an increased proportion of giant cells compared to the 3rd day (p<0.001). On the 21st day, there was a reduction in the proportion of neutrophils, but it was not statistically significant when compared to previous days (α=0.05). The proportion of macrophages and giant cells remained unchanged compared to the 7th day, and there was a reduction in the proportion of lymphocytes compared to the previous observation period (p<0.001). Thirty days after mesh implantation, neutrophils were absent (p<0.001) and the proportions of macrophages, giant cells and lymphocytes remained stable. The behavior of different inflammatory cells throughout the study period is shown in Figure 1.

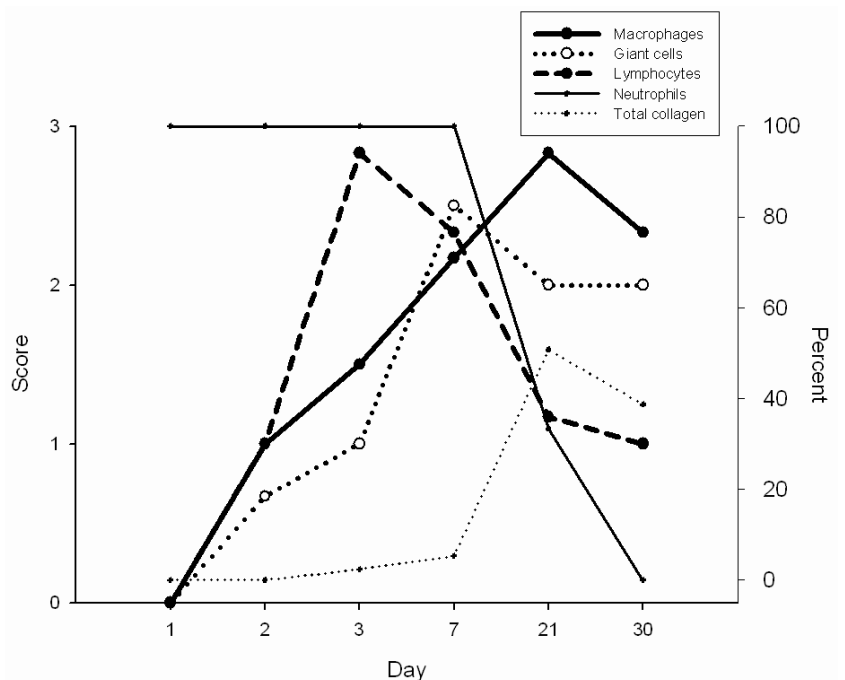


FIGURE 1 – Time evolution of inflammatory cells and fibroplasia on the polypropylene mesh. The values are expressed as scores for macrophages, giant cells and lymphocytes, and as percentage values for neutrophils and total collagen

The videomorphometric analysis of the slides stained with total collagen and of type I and type III collagen fibers in the 10 Picrosirius polarized light showed the mean percentage amount of fields examined (Table 3).

TABLE 3 – Percentage means of total collagen and of type I and type III collagen fractions

		Total collagen*	Type I collagen*	Type III collagen*	Type I / type III collagen ratio*
Group	N	Mean ± SD	Mean ± SD	Mean ± SD	Mean ± SD
Day 1	6	0.00 ± 0.00 ^a	0.00 ± 0.00	0.00 ± 0.00 ^a	--
Day 2	6	0.03 ± 0.05 ^a	0.00 ± 0.00	0.03 ± 0.05 ^a	0.00 ± 0.00
Day 3	6	2.37 ± 0.36 ^b	0.00 ± 0.00	2.37 ± 0.36 ^b	0.00 ± 0.00
Day 7	6	5.33 ± 0.30 ^c	0.00 ± 0.00 ^a	5.33 ± 0.30 ^c	0.00 ± 0.00 ^a
Day 21	6	50.72 ± 3.73 ^d	23.85 ± 2.12 ^b	26.87 ± 3.11 ^d	0.90 ± 0.12 ^b
Day 30	6	38.67 ± 5.31 ^e	21.02 ± 2.93 ^b	17.65 ± 2.64 ^e	1.20 ± 0.11 ^c

*ANOVA between different days showed significant difference for p<0.001

Means designated by the same letters do not show significant differences (α = 0.05) according to Dunnett's test for multiple comparisons.

Total collagen was observed on the 3rd day after mesh implantation, showing a progressive increase on all subsequent days up to the 21st day, when it reached its highest level (p<0.001). Type III collagen was observed on the 3rd day, with a significant difference in its amount compared to that observed on days 1 and 2. After that, type III collagen progressively increased up to the 21st day, when it reached its highest level (p<0.001). On the 30th day, type III collagen showed a significant decrease in relation to the 21st day (p<0.001). Type I collagen appeared between the 7th and 21st days, reached its highest level on the 21st day (p<0.001) and remained stable until the end of the study period. The difference in proportions measured between the two types of collagen was significant on the 3rd and 7th days (p<0.001) and on the 30th day (p<0.05). The type I/type III collagen ratio (Table 3) increased significantly and progressively up to the 30th day (p<0.001). The behavior of total collagen and of type I and type III collagen throughout the study period is shown in Figure 2.

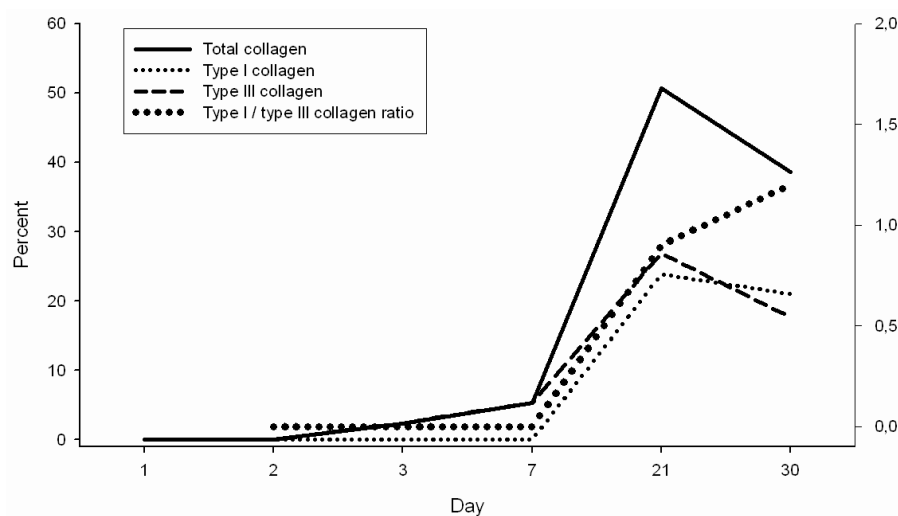


FIGURE 2 – Time evolution of percentage means of total collagen, of type I and type III collagen fractions and of the type I/type III collagen ratio

Discussion

The aim of the present study was to assess the time evolution of fibroplasia on the polypropylene mesh by using an experimental model of incisional hernia in rats. This physiological process is well established for skin wounds and also applies to a wide variety of tissues²². In the literature, several studies have assessed the body's reaction to polypropylene mesh implantation, which is widely used for the repair of abdominal wall defects of different etiologies. However, most studies seek to assess the rates of recurrence, infection and inflammatory response, and the presence of adhesions associated with the use of different mesh types available in the market⁷⁻⁹. According to the literature, since polypropylene mesh acts as a foreign body in the surgical wound, it could cause a prolonged inflammatory response (chronic inflammatory reaction) retarding progression to the proliferative phase of healing, which is responsible for the tensile strength of the scar^{8,22,23}.

This study allowed to observe that neutrophils were present on the surgical wound up to the 21st day, which is a longer period than that described in the literature^{10-13,22}, indicating persistence of the acute inflammatory process. Macrophages were observed on the 2nd day, according to literature data^{10-13,16,22}, reaching their highest levels after the 7th day and remaining high until the end of the study period. This finding differs from classic results, which show that macrophages disappear around the 10th day after mesh implantation^{10-13,16,22}. Lymphocytes were identified on the polypropylene mesh after the 2nd day, which is inconsistent with the findings of other studies, which indicate that they often appear in the wound on the 5th day after tissue injury¹⁰. Note that lymphocytes reached their maximum infiltration between the 3rd and 7th postoperative days, being in line with previous studies¹⁰, and gradually decreased thereafter up to the 21st day, remaining at low levels up to the 30th day. Giant cells, which represent a chronic foreign-body-type inflammatory process, were observed on the 2nd day, but their presence was more pronounced after the 7th day, remaining so up to the end of the study period; these findings concur with those previously described¹⁵. The persistence of neutrophils and macrophages for long time periods indicates a prolonged acute inflammatory process, whereas the early detection of lymphocytes and giant cells and their persistence until the end of the study period indicate a chronic inflammatory process. These findings are consistent with previously reported ones^{15,23,24}. In the healing process classically described for skin wounds^{10-13,22} which is the basis for understanding the repair process of other tissues, neutrophils are the first cells to reach the wounded tissue, appearing approximately 24 hours after injury and remaining there for 3 to 5 days. Macrophages migrate to the wounded area 48 to 96 hours after injury, persisting from the 3rd to the 10th day, constituting the major cell type involved in the control and regulation of wound healing before migration and replication of fibroblasts^{10,11,16,22}. Lymphocytes reach the wound on the 5th day after injury, after inflammatory cells, and reach their maximum level on the 7th day during the proliferative stage¹⁰. In a study with rats which assessed cellular response to the polypropylene mesh, Klinge *et al.*²⁴ perceived that the signs of inflammation reached their maximum values between 7 and 14 days. The same author¹⁵, in another study with rats, reports the presence of giant cells on polypropylene meshes on the 7th postoperative day, whose number increases on the 14th day and continues to rise until the end of the study period, on the 90th day. This author also observed the virtually complete

disappearance of the acute inflammatory process and the presence of cellular infiltrate on the 21st day, which is characteristic of chronic inflammation.

In the present study, total collagen on the polypropylene mesh was detected from the 3rd postoperative day onwards, which reaches its highest percentage mean on the 21st day (50.6%). Collagen was detected on the polypropylene mesh earlier than had been described in the literature^{15,25}, at a higher percentage mean than that observed by Souza Filho *et al.*²⁶, with a decrease in its percentage amount after the 21st day, which is not consistent with the results obtained by other authors for muscle and skin repair^{21,25}. Fibroplasia on skin wounds occurs approximately 5 days after tissue injury and may last for up to 2 weeks^{11,14,16,22}. Noronha *et al.*²⁵ analyzed skin repair in rats after laser application and observed fibroplasia on the 7th day after the procedure, with a sharp increase up to the 28th day, reaching a plateau and then remaining so until the end of the study period (112th day). Klinge *et al.*¹⁵ described the appearance of collagen fibers on polypropylene meshes in rats after the 7th postoperative day. The aponeurosis of the rectus abdominis muscle consists of at least 80% collagen²⁷. Wolwacz Júnior *et al.*²⁸ observed a percentage mean of 75% of collagen in the cross-sectional fascia of control patients. In a study conducted to assess fibroplasia in midline laparotomy wounds in rats, Souza Filho *et al.*²⁶ found out that the mean percentage of total collagen in control rats amounted to 17.68% on the 30th postoperative day. Pickering *et al.*²¹ investigated fibrosis in the gracilis muscle of rats and observed that the collagen amount, determined by videomorphometry, was 16% on the 5th day, reaching a plateau of approximately 80% on the 21st day.

The results show that type III collagen was detected on the polypropylene mesh at the beginning of the healing process (3rd postoperative day), progressively increasing between the 7th and 21st days, when it reached its maximum level and then began to decrease. Type I collagen was detected on the 3rd postoperative day, but at smaller percentage values compared to type III collagen. Its amount was larger after the 7th day and reached its maximum percentage mean on the 21st day. Type I collagen reached a plateau between the 21st and 30th days. The type I/type III collagen ratio showed a progressive increase, with predominance of type I collagen at the end of the study period, indicating an increase in the tensile strength at the mesh site. These findings are in agreement with the classical ones described in the literature for wound healing¹¹ but do not reproduce the results found by other authors, who show an increase in type III collagen^{26,29}. Bellón *et al.*³⁰ carried out a study with rabbits and observed that type III collagen fibers were predominant 2 weeks after polypropylene mesh implantation. Bogusiewicz *et al.*²⁹ assessed collagen deposition on polypropylene meshes in rats and found that 70% of the collagen was immature (type III) 42 days after surgery. Souza Filho *et al.*²⁶ detected fibroplasia in midline laparotomy wounds in rats and noted that the mean percentage of type III collagen was higher than that of type I collagen in control rats on the 30th postoperative day.

According to these data, there is no evidence that a prolonged inflammatory response to polypropylene mesh implantation delays fibroplasia or interferes with type I collagen synthesis, as pointed out by some authors^{15,22,24,26,29}.

The tendency of aponeuroses towards herniation due to changes in the amount of collagen deposition justifies the use of polypropylene mesh implantation for the repair of musculoaponeurotic defects. These findings raise some questions

about the amount of collagen detected at the mesh site, about healthy aponeurosis and about the healing sites of aponeuroses.

Conclusions

This study showed that total collagen was first seen on the 3rd day post-implantation, with a higher percentage of type I collagen at the last observational time point. There was prolonged acute inflammatory response and persistence of a chronic inflammatory process at the mesh site, but these findings did not interfere with fibroplasia.

References

1. Usher FC, Wallace SA. Tissue reaction to plastics; a comparison of nylon, orlon, dacron, teflon, and marlex. *Arch Surg.* 1958;76:997-9.
2. Leber GE, Garb JL, Alexander AI, Reed WP. Long-term complications associated with prosthetic repair of incisional hernias. *Arch Surg.* 1998;133:378-82.
3. Schumpelick V, Klinge U. Prosthetic implants for hernia repair. *Br J Surg.* 2003;90:1457-8.
4. Cumberland VH. A preliminary report on the use of prefabricated nylon weave in the repair of ventral hernia. *Med J Aust.* 1952;(5):143-4.
5. Scales JT. Discussion on metals and synthetic materials in relation to soft tissues and tissue reaction to synthetic materials. *Proc R Soc Med.* 1953;46:647-52.
6. Amid P. Classification of biomaterials and their related complications in abdominal wall hernia surgery. *Hernia.* 1997;1:15-21.
7. Korenkov M, Sauerland S, Arndt M, Bograd L, Neugebauer EA, Troidl H. Randomized clinical trial of suture repair, polypropylene mesh or autodermal hernioplasty for incisional hernia. *Br J Surg.* 2002;89:50-6.
8. d'Acampora AJ, Joli FS, Tramonte R. Expanded polytetrafluoroethylene and polypropylene in the repairing of abdominal wall defects in Wistar rats: comparative study. *Acta Cir Bras.* 2006;21:409-15.
9. Demir U, Mihmanli M, Coskun H, Dilege E, Kalyoncu A, Altinli E, Gunduz B, Yilmaz B. Comparison of prosthetic materials in incisional hernia repair. *Surg Today.* 2005;35:223-7.
10. Park JE, Barbul A. Understanding the role of immune regulation in wound healing. *Am J Surg.* 2004;187(5A):11S-6.
11. Witte MB, Barbul A. General principles of wound healing. *Surg Clin North Am.* 1997;77:509-28.
12. Mandelbaum SH, Di Santis EP, Mandelbaum MHS. Cicatrização: conceitos atuais e recursos auxiliares. Parte I. *An Bras Dermatol.* 2003;78:393-408.
13. d'Acampora AJ, Vieira DS, Silva MT, Farias DC, Tramonte R. Morphological analysis of three wound-cleaning processes on potentially contaminated wounds in rats. *Acta Cir Bras.* 2006;21:332-40.
14. Hunt TK, Hopf HW. Wound healing and wound infection: what surgeons and anesthesiologists can do. *Surg Clin North Am.* 1997;77:587-606.
15. Klinge U, Klosterhalfen B, Muller M, Anurov M, Ottinger A, Schumpelick V. Influence of polyglactin-coating on functional and morphological parameters of polypropylene-mesh modifications for abdominal wall repair. *Biomaterials.* 1999;20:613-23.
16. Steed DL. The role of growth factors in wound healing. *Surg Clin North Am.* 1997;77:575-86.
17. Leroy JL, Mutter D, Forgione A, Inoue H, Vix M, Bailey C, Marescaux J. The new 4DDome prosthesis: an original light and partially absorbable composite mesh for hernia repair. *Hernia.* 2006;10:401-8.
18. Paiva FP, Maffili VV, Santos ACS. Curso de manipulação de animais de laboratório. Fundação Oswaldo Cruz - FIOCRUZ;2005.
19. Montes GS, Junqueira LC. The use of the picosirius-polarization method for the study of the biopathology of collagen. *Mem Inst Oswaldo Cruz.* 1991;86(Suppl 3):1-11.
20. Junqueira LC, Bignolas G, Brentani RR. Picosirius staining plus polarization microscopy, a specific method for collagen detection in tissue sections. *Histochem J.* 1979;11:447-55.
21. Pickering JG, Boughner DR. Quantitative assessment of the age of fibrotic lesions using polarized light microscopy and digital image analysis. *Am J Pathol.* 1991;138:1225-31.
22. Franz MG. The biology of hernias and the abdominal wall. *Hernia.* 2006;10:462-71.
23. Bellon JM, Bujan J, Contreras L, Hernando A. Integration of biomaterials implanted into abdominal wall: process of scar formation and macrophage response. *Biomaterials.* 1995;16:381-7.
24. Klinge U, Klosterhalfen B, Birkenhauer V, Junge K, Conze J, Schumpelick V. Impact of polymer pore size on the interface scar formation in a rat model. *J Surg Res.* 2002;103:208-14.
25. Noronha L, Chin EWK, Kimura LY, Graft L. Estudo morfológico e morfológico da cicatrização após uso de laser erbium: YAG em tecidos cutâneos de ratos. *Bras Patol Med Lab.* 2004;40:41-8.
26. Souza Filho ZA, Greca FH, Noronha L, Maranhão ASA, Calil AP, Hubie DP, Barbosa FM. Abdominal wall healing in reoperated rats. *Acta Cir Bras.* 2007;22:147-51.
27. Wagh PV, Read RC. Defective collagen synthesis in inguinal herniation. *Am J Surg.* 1972;124:819-22.
28. Wolwacz Jr I, Trindade MRM, Cerski CT. The collagen in transversalis fascia of direct inguinal hernia patients treated by videolaparoscopy. *Acta Cir Bras.* 2003;18:196-202.
29. Bogusiewicz M, Wróbel A, Jankiewicz K, Adamiak A, Skorupski P, Tomaszewski J, Rechberger T. Collagen deposition around polypropylene tapes implanted in the rectus fascia of female rats. *Eur J Obstet Gynecol Reprod Biol.* 2006;124:106-9.
30. Bellon JM, Rodriguez M, Garcia-Honduvilla N, Pascual G, Bujan J. Partially absorbable meshes for hernia repair offer advantages over nonabsorbable meshes. *Am J Surg.* 2007;194:68-74.

Correspondence:

Márcia Vaz
Rua Mostardeiro, 1035/1002
90430-001 Porto Alegre – RS Brazil
Phone: (55 51)3332-4245
Fax: (55 51)3331-6780
marvaz@terra.com.br

Conflict of interest: none
Financial source: none

Received: August 18, 2008
Review: October 21, 2008
Accepted: November 19, 2008

How to cite this article

Vaz M, Krebs RK, Trindade EN, Trindade MRM. Fibroplasia after polypropylene mesh implantation for abdominal wall hernia repair in rats. *Acta Cir Bras.* [serial on the Internet] 2009 Jan-Feb;24(1). Available from URL: <http://www.scielo.br/acb>