

Influence of ingaalp laser (660nm) on the healing of skin wounds in diabetic rats¹

Influência do laser ingaalp (660nm) na cicatrização de feridas cutâneas em ratos diabéticos

Paulo de Tarso Camillo de Carvalho^I, Iandara Schettert da Silva^{II}, Filipe Abdalla dos Reis^{III}, Daniel Martins Perreira^{IV}, Ricardo Dutra Aydos^V

^I PhD, Associate Professor, Department of Physiotherapy, Federal University of Sergipe (UFS), Aracaju-SE, Brazil.

^{II} PhD, Associate Professor, Postgraduate Program in Health and Development, West Central Region, UFMS, Campo Grande-MS, Brazil.

^{III} Fellow PhD Degree, Postgraduate in Health and Development, West Central Region, UFMS, Mato Grosso do Sul, Brazil.

^{IV} Master, Assistant Professor, Department of Physiotherapy, UNIDERP, Campo Grande-MS, Brazil.

^V PhD, Associate Professor, Postgraduate Program in Health and Development, West Central Region, UFMS, Campo Grande-MS, Brazil.

ABSTRACT

Purpose: To determine the influence of low-power laser (660 nm) on the collagen percentage and macrophages in skin wounds in diabetic rats. **Methods:** 30 male Wistar rats were used, distributed in two groups: laser treated diabetic (n= 15); untreated diabetic (n = 15). The diabetes was induced by intravenous injection of alloxan into the dorsal vein of the penis, at a rate of 0.1 ml of solution per 100 g of body weight. A wound was made on the back of all the animals. Groups 2 were treated with Aluminium Gallium Indium Phosphide - InGaAlP type diode laser (Photon Laser III DMC[®]) with a continuous output power of 100 mW and wavelength (λ) of 660 nm (4 J/cm²) for 24 s. five animal from each group was sacrificed on the 3rd, 7th and 14th days after wounding. Samples were taken, embedded in paraffin, stained with hematoxylin-eosin, Masson's trichrome, and immunohistochemical macrophage. morphometrically analyzed using the Image Pro Plus 4.5 software. The percentages of collagen fibers and macrophages were determined from the samples from the euthanasia animals. **Results:** The data were treated statistically using analysis of variance (ANOVA) and the Post-hoc Tukey test. The significance level was set at 0.05 or 5%. **Conclusion:** The low-power laser (660 nm) was shown to be capable of influencing the collagen percentage in skin wounds by increasing the mean quantity of collagen fibers and macrophages.

Key words: Laser Therapy, Low-Level. Wound Healing. Collagen. Macrophages. Rats.

RESUMO

Objetivo: Determinar a influência do diodo laser InGaAlP (660 nm) sobre o percentual de colágeno e macrófagos em feridas cutâneas de ratos diabéticos. **Métodos:** Para tanto 30 ratos machos Wistar foram distribuídos em dois grupos: diabético tratado com laser (n=15), diabético não tratado (n = 15). O diabetes foi induzido por injeção intravenosa de aloxana na veia dorsal do pênis, a uma taxa de 0,1 ml de solução por 100 g de peso corporal. A lesão foi confeccionada no dorso de todos os animais utilizando um punch de 8mm. 2 grupos foram tratados com o diodo laser arsenieto de gálio e alumínio dopado com, fosforeto de índio - InGaAlP (tipo Photon Laser III DMC[®]) com uma potência contínua de 100 mW e comprimento de onda (λ) de 660 nm (4 J/cm²) por 24 s. cinco animais de cada grupo foi sacrificado no 3, 7 e 14 dias após a lesão. As amostras obtidas foram emblocadas em parafina, coradas com hematoxilina-eosina, tricrômico de Masson, e para a análise dos macrófagos foi realizado um imunohistoquímico. Os resultados foram avaliados morfometricamente pelo programa Image Pro Plus 4.5. **Resultados:** Os dados foram tratados estatisticamente pela análise de variância (ANOVA) e pós-teste de Tukey. O nível de significância foi fixado em 0,05 ou 5%. **Conclusão:** O laser de baixa potência (660 nm) mostrou-se capaz de influenciar o percentual de colágeno em feridas cutâneas, aumentando a quantidade média de fibras colágenas e macrófagos.

Descritores: Terapia a Laser de Baixa Intensidade. Cicatrização de Feridas. Colágeno. Macrófagos. Ratos.

¹Research performed at the Postgraduate Program in Health and Development, West Central Region, Federal University of Mato Grosso do Sul (UFMS), Campo Grande-MS, Brazil.

Introduction

Healing is a complex process and has attracted the attention of researchers over the years, particularly regarding factors that delay or hinder it. The most important repair failures are those that occur in the initial stages. These lead to accentuation of edema, reduced vascular proliferation and decreased quantities of cell elements such as leukocytes, macrophages and fibroblasts¹.

Poor wound repair in diabetic patients is well documented in the literature. The exact pathogenesis of poor wound healing in diabetes is not completely understood, but evidence from studies involving both human and animal models of diabetes reveals several abnormalities in the various phases of the wound healing process².

Currently, studies are being conducted to seek new therapeutic methods for resolving or minimizing failures of tissue repair presented by patients with diabetes mellitus. Low-level laser therapy (LLLT) techniques are particularly being studied¹.

The therapeutic effects of laser on different types of biological tissue are extensive. These have been demonstrated by *in vitro*^{3,4} and *in vivo* studies^{5,6}.

Researchers^{1,7-11} studying the effect of various lasers on wound healing in diabetic animals have found a higher percentage of wound closure in diabetic and nondiabetic animals. Al-Watban, *et al.*¹² they reported the acceleration of diabetic wound healing in animals using laser photostimulation has not yet been investigated extensively.

The objective of the present study was to determine the influence of low-power (660 nm) laser on the collagen percentage and macrophages in skin wounds in diabetic and non-diabetic rats.

Methods

The sample consisted of 30 adult male albino Wistar rats (*Rattus norvegicus albinus*), with body weight ranging from 310 ± 15 grams. The animals came from the central vivarium at University for the Development of the State and Pantanal Region - UNIDERP under controlled light and temperature conditions, with standard food and water available *ad libitum*. All experimental procedures were carried out in accordance with the norms of the Brazilian College for Animal Experimentation (COBEA). This study was approved by the Committee of Ethics in Research at, University for the Development of the State and Pantanal Region under protocol number 19/2007/CEA/UNIDERP.

Experimental groups

Thirty diabetic animals induced using alloxan were chosen at random to make up the G1 group of untreated diabetic rats (n = 15) and G2 treated diabetic rats (n = 15). These groups were distributed into three subgroups according to the period of euthanasia, three seven and fourteen days after the wounds.

Chemical induction of diabetes (Alloxan)

The rats that had diabetes induced using alloxan were kept without food for the preceding 24 hours, because rats become more susceptible to diabetes under these conditions. Anesthesia

was administered by means of intraperitoneal injection of ketamine (7%) and xylazine (0.3%) at a ratio of 2:1, using 0.2 ml/100 g of body weight. The animals were then placed in dorsal decubitus, ready to receive an intravenous injection of alloxan (2,4,5,6-tetraoxypyrimidine; 5,6-dioxuracil), into the dorsal vein of the penis. A stock solution of 50 mg of alloxan per 0.8 ml of physiological serum was prepared for the alloxan injection at this time. The injection was administered in a proportion of 0.1 ml of solution per 100 grams of body weight, thus resulting in a final dose of 62.5 mg of alloxan per kg of body weight. The animals were treated with glucose solution (10%) during the first six hours after the injection, to prevent convulsions and death, which are common in the hypoglycemic stage. After 24 hours, the glucose was removed from the water. The following glycemia monitoring scheme was used to confirm whether diabetes was present: the glycemia level was measured before diabetes induction and 72 hours thereafter, and the animals that did not present values greater than or equal to 250 mg per deciliter of blood (mg/dl) were discarded.

The glycemia level was measured again on the fifth day after the treatment, to confirm whether the animal continued to be diabetic. Finally, the glycemia level was measured on the day of sacrificing, to determine whether any reversion of the diabetes had occurred. The measurements were made by removing blood from the tail vein and placing one drop on Advantage II® reactive tape. The glycemia level was read using the Glucometer® apparatus, resulting in a mean glycemia level of 315.2 ± 70 mg/dl.

Skin wound production

After weighing each animal received preanesthetic administration of Butorphanol (Turbogestic, 2mg/kg) associated with Acepromazine (Acepran, 1mg/kg), both in a single dose intramuscularly. After 15 minutes was administered Zolazepan and Tiletamine (Zoletil 50, 40mg/kg). Once anesthetized, the animal was placed in prone position, place the sterile with alcohol-iodine, trichotomy. To carry out the injured, used a "PUNCH" of 8mm in diameter allowing the removal of a circular area of skin, with localization to the middle portion of the median sagittal plane.

Laser irradiation

An InGaAlP type diode laser with a continuous output power of 100 mW and wavelength (λ) of 660 nm (visible red) was used. The optical power was calibrated using a Newport multifunction optical meter model 1835C. The spot size was 0,028 cm², energy density of 10J/cm²

Histologic analysis

The wound tissues were fixed with 10% formalin, embedded in paraffin, and sectioned. Sections of 5- μ m thickness were stained using hematoxylin-eosin and Masson's trichrome. The Macrophages, were examined by immunohistochemical stains.

For macrophage staining, anti-macrophage marker mouse monoclonal antibody was diluted 1:1000 in 1% bovine serum albumin in 0.05 M phosphate-buffered saline (pH 7.5) as the primary antibody, and biotinylated goat anti-mouse IgG was used as the secondary antibody. Positive staining was indicated by a brown color.

Morphometric analysis

Morphometric analysis was performed on the slides, by means of image digitization and computational analysis using a specific image processing and analysis program (Image Pro Plus 4.5). To quantify the areas representing collagen and macrophage, five fields observed using an Axiolab microscope (Carl Zeiss, 20x lens) were digitized. The microscope was coupled to an image-capturing Sanyo digital active BLC camera, and this was connected to an Intel Celeron E1400 2.0GHz Dual-Core microcomputer equipped with a video board. All the images were digitized before the quantification process, thereby standardizing the microscope light intensity and condenser height. The collagen and macrophage areas were separated in the image, using the color distribution as the discriminating parameter.

Statistical analysis

The original data were tested with GraphPad software. All the results are showed with mean \pm standard deviation. One way analysis of variance (ANOVA) and post-hoc Tukey's test was used for statistical analysis, and all tests were considered to be statistically significant at $p < 0.05$.

Results

Starting from the general average of the percentage of collagen morphometry data were submitted to analysis of variance (ANOVA) was observed ($p < 0.05$). The Tukey test compared the

paired samples reach the results described below: The result of statistical analysis showed that significant difference $p = 0.0457$ ($p < 0.05$) of mean collagen in subgroup three days between treated animals (19.96 ± 1.89) and untreated (13.19 ± 3.270) (Figure 1).

The comparison of averages of samples of collagen subgroup seven days between the groups treated animals (30.95 ± 4.14) and untreated (16.95 ± 2.36) statistical analysis showed a statistically significant difference $p = 0.0136$ ($p < 0.05$) (Figure 2).

In comparing the means of samples of collagen group fourteen days between the groups treated animals (34.61 ± 2.84) and untreated (26.66 ± 1.78) a statistical analysis showed a statistically significant difference $p = 0.0017$ ($p < 0.01$) (Figure 3).

The results of the number of macrophages were performed between treated and untreated groups, as well as in subgroups, comparing the period of withdrawal to 3, 7 and 14 days after injury.

The average number of samples collected from macrophages with 3 days of treated animals (13.70 ± 3.28) and untreated (36.75 ± 11.64) a statistical analysis showed a statistically significant difference $p = 0.0263$ ($p < 0.05$) (Figure 4).

Comparison of the mean number of macrophages to the seven days between the treated groups ($21, 40 \pm 3.76$) and untreated ($39, 25 \pm 4.09$) a statistical analysis showed a statistically significant difference $p = 0, 0168$ ($p < 0.05$) (Figure 5).

Already in the comparison between the number of macrophages in group fourteen days between the treated groups ($11, 45 \pm 3, 62$) and untreated ($23, 35 \pm 3, 83$) statistical analysis showed a statistically significant difference $p = 0, 0497$ ($p < 0.05$) (Figure 6).

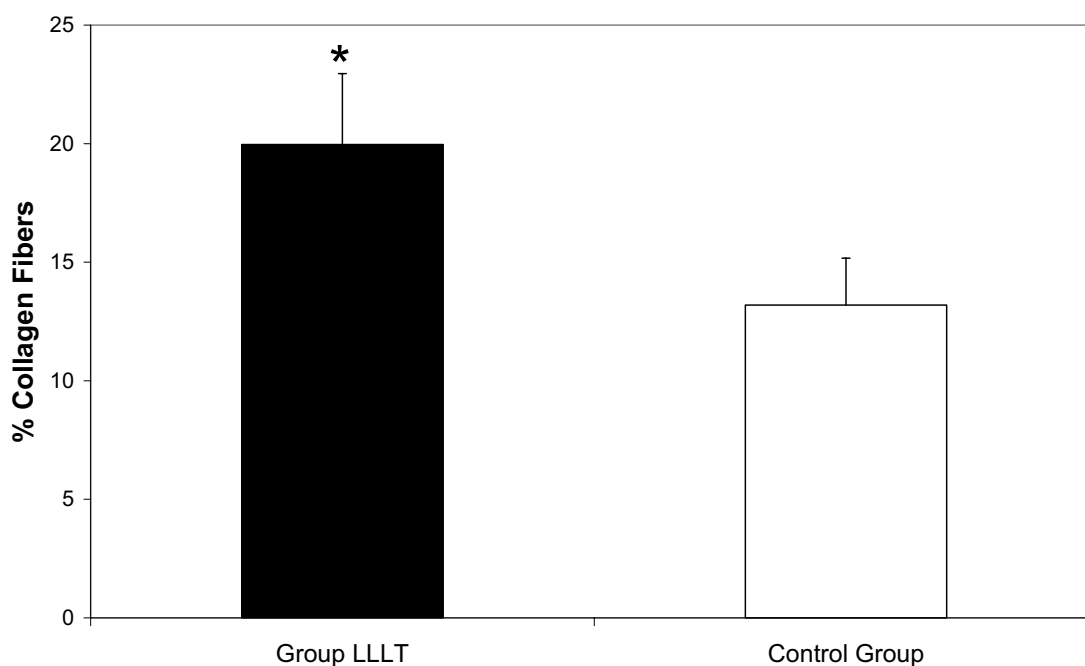


FIGURE 1 - Graph comparing the mean percentage of collagen for 3 days, values are means \pm SEM, $n = 5$ for each time point. * $P < 0.05$ vs. control group (Tukey's test)

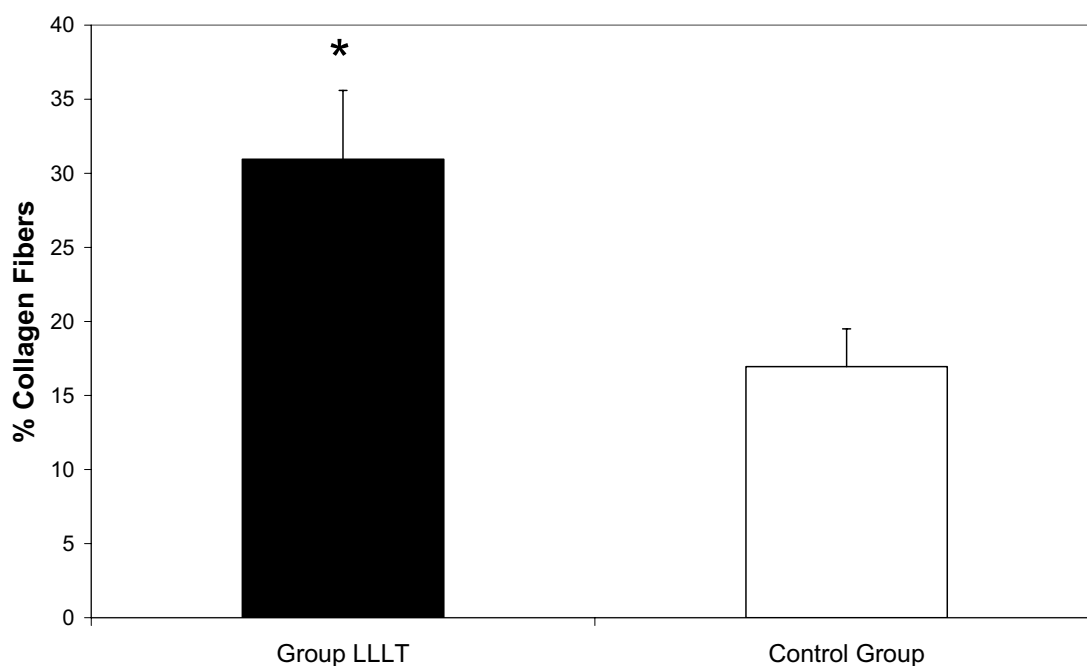


FIGURE 2 - Graph comparing the mean percentage of collagen for 7 days, values are means \pm SEM, n = 5 for each time point. * $P < 0.05$ vs. control group (Tukey's test)

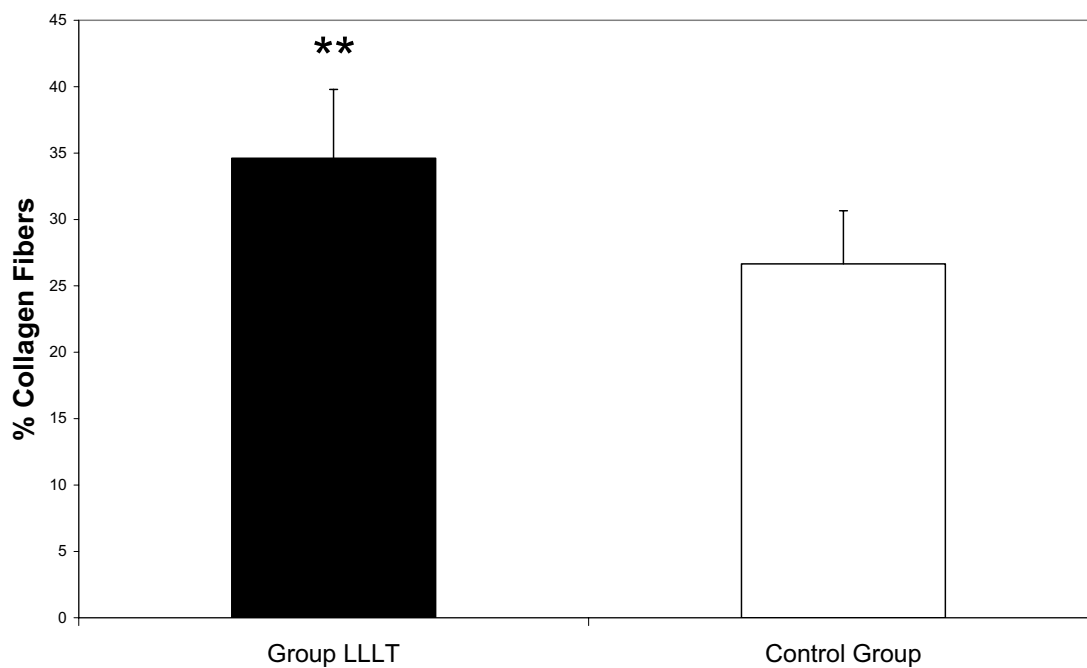


FIGURE 3 - Graph comparing the mean percentage of collagen for 14 days, Values are means \pm SEM, n = 5 for each time point. ** $P < 0.001$ vs. control group (Tukey's test)

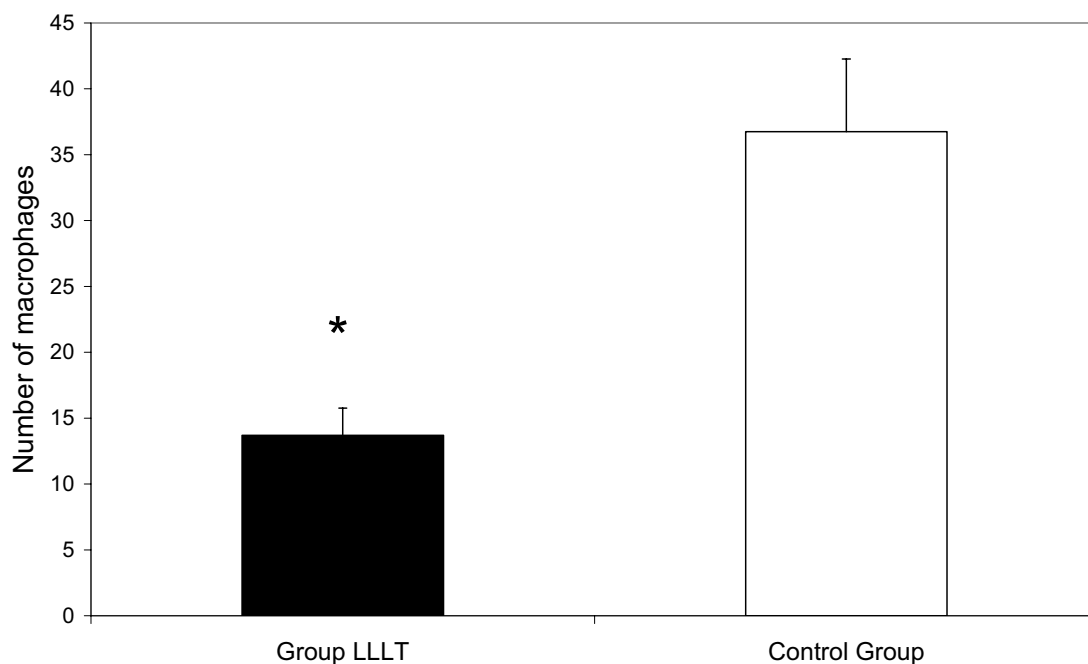


FIGURE 4 - Graph comparing the mean, number of infiltrated macrophages (immunohistochemical staining with anti-macrophage marker monoclonal antibody), 3 days subgroups. Values are means \pm SEM, n = 5 for each time point. * $P < 0.05$ vs. control group (Tukey's test)

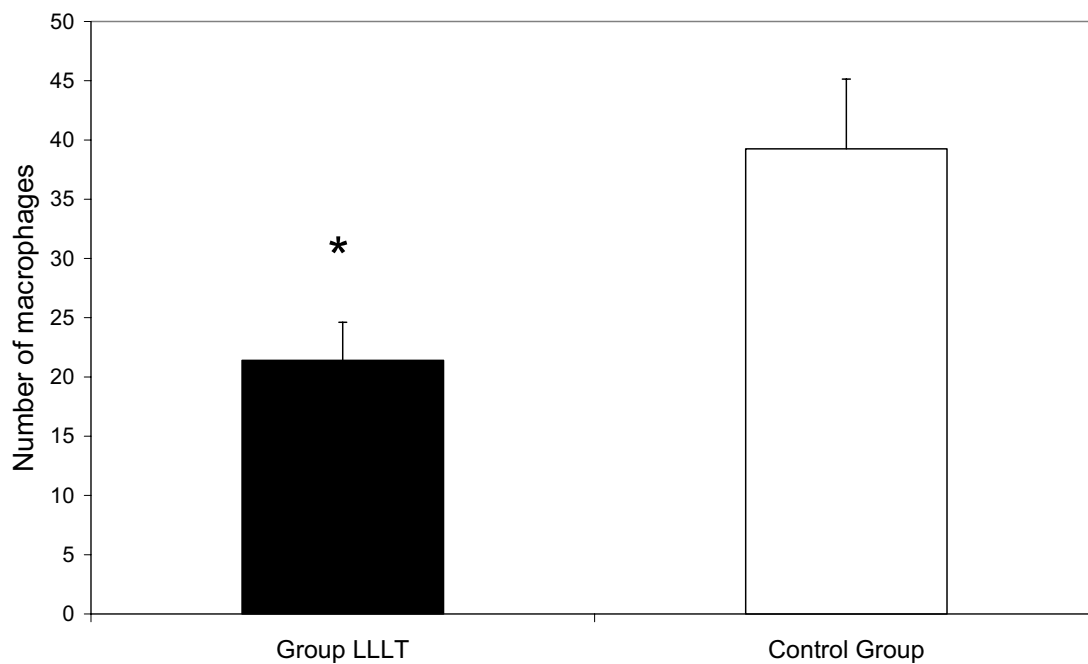


FIGURE 5 - Graph comparing the mean number of infiltrated macrophages (immunohistochemical staining with anti-macrophage marker monoclonal antibody), 7 days subgroups. Values are means \pm SEM, n = 5 for each time point. * $P < 0.05$ vs. control group (Tukey's test)

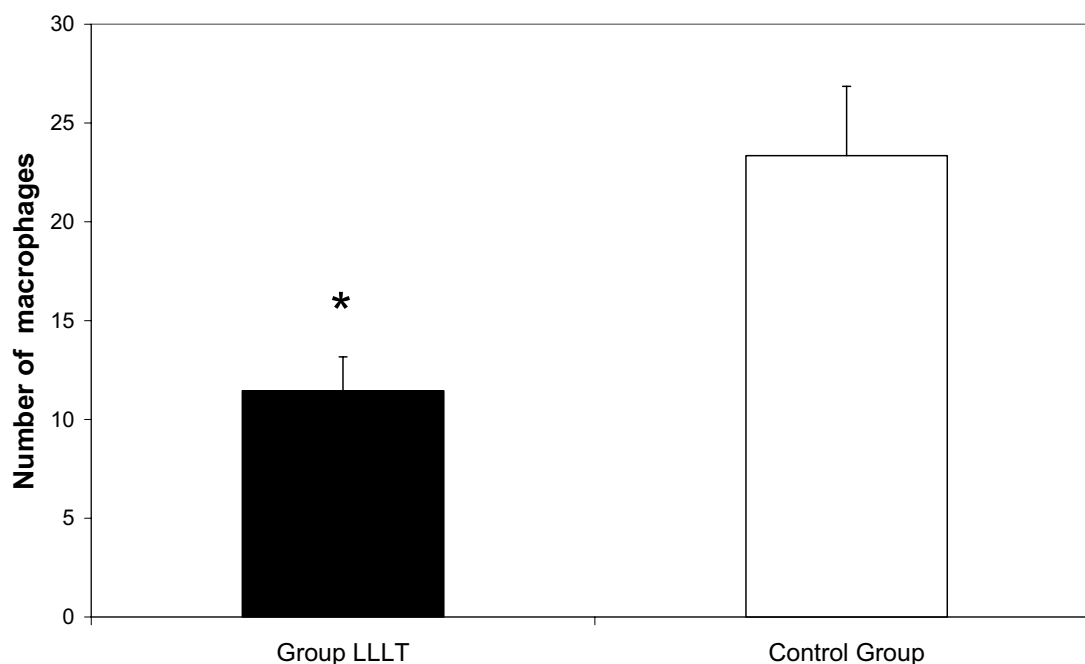


FIGURE 6 - Graph comparing the mean number of infiltrated macrophages (immunohistochemical staining with anti-macrophage marker mouse monoclonal antibody), 14 days subgroups. Values are means \pm SEM, n = 5 for each time point. * $p < 0.05$ vs. control group (Tukey's test)

Light microscopy examination

Microscopically, lesions in the animals of the diabetic group treated with LLLT for 03 days there was presence of diffuse mononuclear inflammatory exudate, and granulation tissue loose in moderate amount, with fibroblasts and collagen fibers distribution disorganized, and a large quantity of newly formed vessels.

How that in lesions of the diabetic group of animals, not treated for the same period, there was the presence of diffuse mononuclear inflammatory exudate, granulation tissue composed of loose moderate amount of newly formed vessels, and disorganized arrangement of fibroblasts and fibers collagen (data confirmed by morphometry).

In the lesions treated with LLLT to 7 days there was the presence of exuberant granulation tissue, composed of moderate amount of newly formed vessels, the largest amount fibroblasts and collagen matrix organized, less mononuclear inflammatory infiltrate (diffuse), and proliferation of cells of layer germination of the epidermis, near the edges of the lesion,. How that in lesions of the diabetic group of animals, not treated for the same period, there was retention of mononuclear inflammatory exudate in comparison with the treated group, but with loose granulation tissue composed of small number of vessels and newly formed areas of hemorrhage, disorganized arrangement of collagen fibers and fibroblasts (Figures 7 and 8).

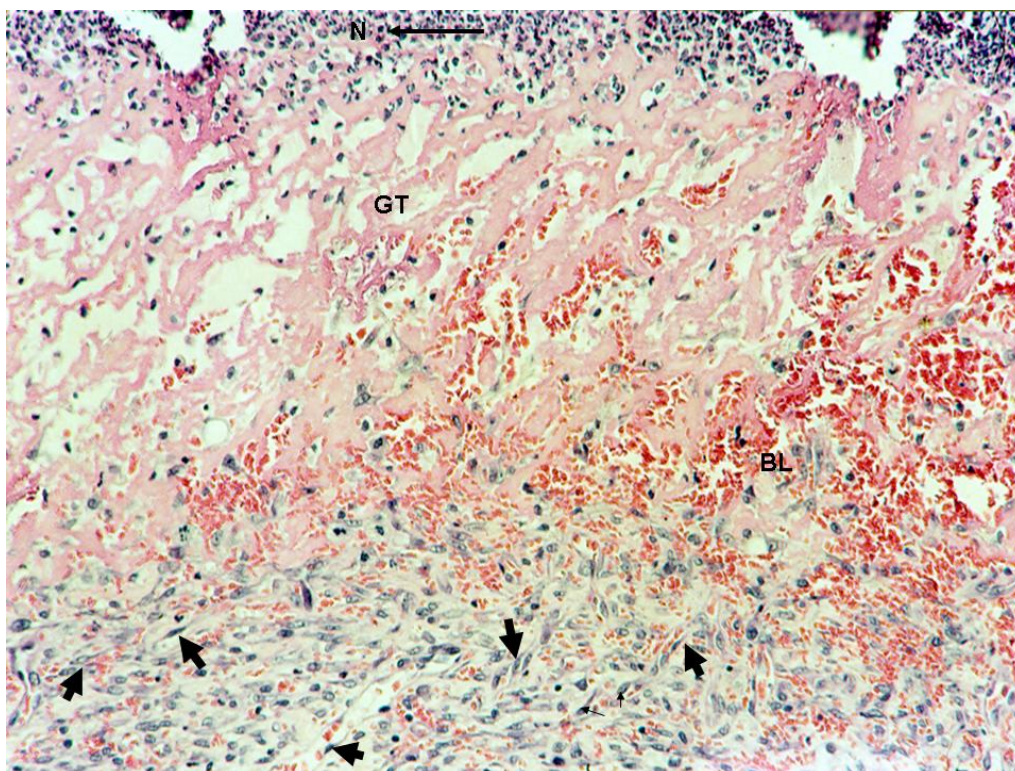


FIGURE 7 - Photomicrograph of histological section diabetic control group at 7 days, you can see no pavement keratinized stratified epithelial tissue (GT) and fibrin crust below leukocyte with dermis showing intense inflammatory infiltrate mainly represented by neutrophils (N) and fibroblasts (arrows), fibers fine and sparse collagen and focal areas of bleeding (BL) and necrosis. Trichrome of Massom. Scale bar of 20µm

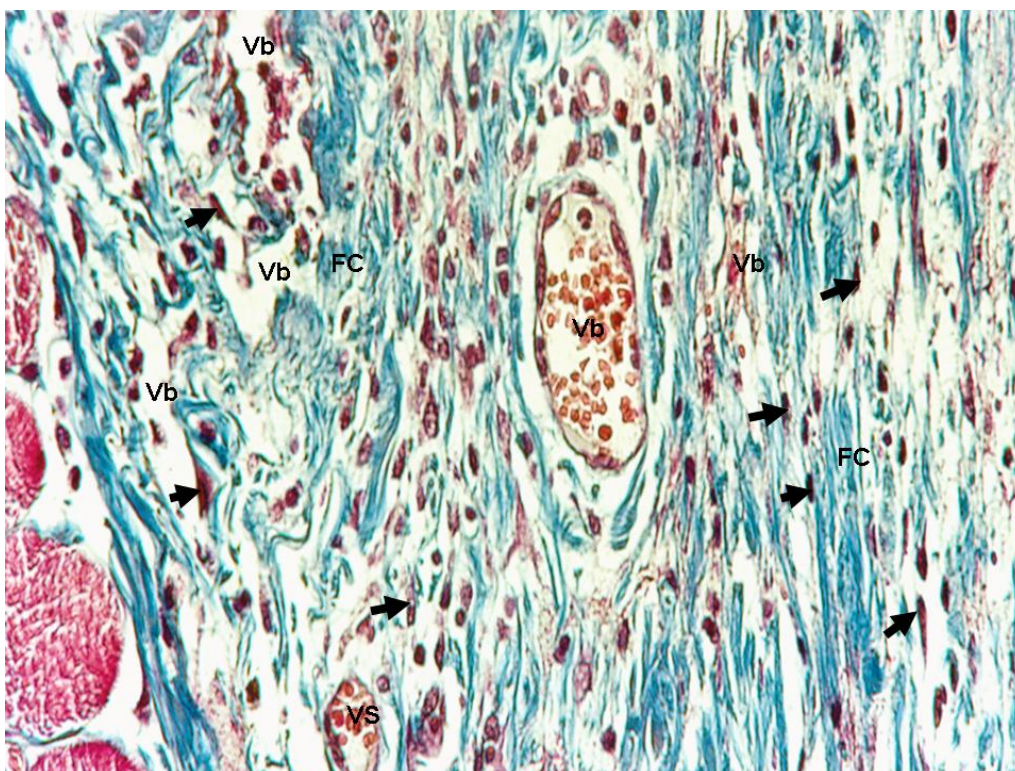


FIGURE 8 - Photomicrograph of histological section diabetic group treated with LLLT at 7 days, pointed out: compact dermis with intense vascularization, granulation tissue organized (FC), neof ormation of vessels (Vb), fibroblasts and collagen fibers thick (arrows). Trichrome of Massom. Scale bar of 20µm

With 14 days of experiment, we observed that both lesions in the animals treated and the untreated LLLT was the replacement of granulation tissue by dense connective tissue composed of fibroblasts and reduction of a few newly formed vessels, and fully reconstituted epidermis, with presence of clear layers, granulosum, spinosum and germinative (basal) mature. Draws attention, the fact that in animals treated with LLLT showed the collagen matrix is more organized than in untreated animals. data this showed by morphometry.

Discussion

In the process of repairing a normal tissue, the fibroblasts are stimulated to proliferate and migrate to the site of the lesion, which synthesize collagen and proteoglycans and restore the integrity of tissue¹.

Diabetes Mellitus in the healing process is modified by several factors with suppression of inflammatory reactions, decreased angiogenesis, changes in the proliferation of keratinocytes, fibroblasts and endothelial cells, increase in apoptosis of keratinocytes and endothelial cells, decrease the migration of fibroblasts, defects in the deposition of collagen and decrease in production of growth factors^{13,14}.

According to Ochoa¹⁵, the Chemokines are critical for white blood cell recruitment to injured tissues and play an important role in normal wound healing processes. In contrast, impaired wound healing in diabetic patients is accompanied by decreased early inflammatory cell infiltration but persistence of neutrophils and macrophages in the chronic, nonhealing wounds. These changes in inflammatory cell recruitment occur in conjunction with alterations in chemokine and growth factor expression. In addition to leukocyte trafficking, many different cell types, including endothelial cells, fibroblasts, and keratinocytes, produce and respond to chemokines, and these interactions are altered in diabetic wounds. Thus, the chemokine system may have both direct and inflammatory-mediated effects on many different aspects of diabetic wound healing.

Several studies^{1,2,3,6,8,9} have demonstrated the efficacy of LLLT in the process of tissue repair mainly due its ability to relieve pain, stimulate tissue repair, reduce the swelling and hyperemia in the anti-inflammatory processes, prevent infections.

The LLLT operating in different wavelength and energy density also has been used in several studies to accelerate the healing process changed in diabetes. In this study during the investigation the percentage of collagen fibers was observed and statistically significant higher values for the group of diabetic animals treated with LLLT, these results were higher during all stage of the study.

Our results are similar to Reddy⁸, which examined the effect of laser radiation Ga-AS (904nm - 7mW - 1J/cm- 5 days / week for 3 weeks) in wounds in the back of diabetic rats promoted an increase of 14% in deposition of collagen in diabetic rats compared to non-irradiated.

Maiya *et al.*¹⁰ irradiated with the HeNe laser (632.8nm; 4.8J/cm, 5 days / week until the healing) wounds on the back of diabetic rats and found complete healing after 18 days, while the diabetic animals had not spent an average of healing the wound in the 59th day. Animals irradiated in this study showed an increased

amount of collagen in scar tissue, an increase in the proliferation of fibroblasts and number of capillaries formed.

Byrnes *et al.*⁹ analyzed the healing of wounds in the back of rats with type II diabetes and found that healing of diabetic animals was irradiated faster (HeNe 632nm 16mW - 4J/cm), and there is an increase in the production of FGF wounds of irradiated animals.

In our study we can observe an increase in the production of collagen in groups of diabetic animals and in patients not subjected to the application of LLLT. Our results are similar to other studies^{1,2,10} in the LLLT promoted the increase of collagen fibers.

The mechanism by which laser photostimulation facilitates collagen production in diabetic wound healing may involve a variety of photostimulating mechanisms.

Yu *et al.*¹⁶ report showed that the absorption of energy by the respiratory chain may cause oxidation of NADH, producing changes in the redox status in both mitochondria and cytoplasm. The activation of electron transport chain results in an increase in the electrical potential across the mitochondria membrane, an increase in the ATP pool, and finally the activation of nucleic acid synthesis. It also enhances the pro-collagen production, increased cross-linking of existing collagen molecules, acceleration of epithelial repair and early growth of granulation tissue. It also increases DNA synthesis, collagen, and procollagen production and may increase cell proliferation or alter locomotor characteristics of the cells.

This study also performed a immunohistochemical study to detect Macrophages and we have seen a severe decline in the number of these cells in the group irradiated with LLLT. These results are similar to studies Bayat *et al.*¹⁷ demonstrated that LLLT decreased the number of Macrophages at day 16 in comparison with the control group, and decreased the depth of new epidermis at day 30 in comparison with the control and nitrofurazone treated groups.

Two days to 5 days after injury, circulating monocytes arrive at the site and are converted to macrophages. Macrophages are central to the wound healing process and are responsible for the amplification, orchestration, and maintenance of the wound healing response. In addition to destroying bacteria and debriding devitalized tissue, they continually secrete a variety of cytokines during the inflammatory phase of healing to include fibroblast growth factor (FGF), tissue growth factor beta (TGF-[beta]), platelet-derived growth factor (PDGF), tissue growth factor alpha (TGF-[alpha]), interleukin-1 (IL-1), tumor necrosis factor alpha (TNF-[alpha]), and insulin-like growth factor¹⁸.

Was observed in this study that the behavior of collagen fibers was related to macrophages and that in time of seven days they were increased when compared with three intensive days, has fourteen days to the number of macrophages undergoes a decrease and collagen fibers became more dense and aligned

The macrophage activation can result in cytokine release which in turn results in site specific and condition specific responses, according to what tissue and what activity the macrophage is responding. These multifunctional effects on macrophages, neutrophils and mast cells may be synergistic to modify pain, edema, tissue repair and remodeling. LLLT also has advantageous effects on collagen synthesis, metabolism, and the rate of defect closure and increased amounts of growth factors and cytokines may be produced by cells in LLLT treated wounds¹⁹.

Conclusion

The low-power laser (660 nm) was shown to be capable of influencing the collagen percentage in skin wounds by increasing the mean quantity of collagen fibers and macrophages in skin wounds in diabetic rats.

References

1. Carvalho PT, Mazzer N, dos Reis FA, Belchior AC, Silva IS. Analysis of the influence of low-power HeNe laser on the healing of skin wounds in diabetic and non-diabetic rats. *Acta Cir Bras.* 2006;21(3):177-83.
2. Meireles GC, Santos JN, Chagas PO, Moura AP, Pinheiro AL. Effectiveness of laser photobiomodulation at 660 or 780 nanometers on the repair of third-degree burns in diabetic rats. *Photomed Laser Surg.* 2008;26(1):47-54.
3. Shefer G, Ben-Dov N, Halevy O, Oron U. Primary myogenic cells see the light: improved survival of transplanted myogenic cells following low energy laser irradiation. *Lasers Surg Med.* 2008;40(1):38-45.
4. Saygun I, Karacay S, Serdar M, Ural AU, Sencimen M, Kurtis B. Effects of laser irradiation on the release of basic fibroblast growth factor (bFGF), insulin like growth factor-1 (IGF-1), and receptor of IGF-1 (IGFBP3) from gingival fibroblasts. *Lasers Med Sci.* 2008;23(2):211-5.
5. Ilic S, Leichliter S, Streeter J, Oron A, DeTaboada L, Oron U. Effects of power densities, continuous and pulse frequencies, and number of sessions of low-level laser therapy on intact rat brain. *Photomed Laser Surg.* 2006;24(4):458-66.
6. Denadai AS, de Carvalho Pde T, dos Reis FA, Belchior AC, Pereira DM, Dourado DM, Silva IS, de Oliveira LV. Morphometric and histological analysis of low-power laser influence on bone morphogenetic protein in bone defects repair. *Lasers Med Sci.* 2009;24(5):689-95.
7. Stadler I, Lanzafame RJ, Evans R, Narayan V, Dailey B, Buehner N, Naim JO. 830-nm irradiation increases the wound tensile strength in a diabetic murine model. *Lasers Surg Med.* 2001;28(3)220-6.
8. Reddy GK. Comparison of the photostimulatory effects of visible He-Ne and infrared Ga-As lasers on healing impaired diabetic rat wounds. *Lasers Surg Med.* 2003;33(5):344-51.
9. Byrnes KR, Barna L, Chenault VM, Waynant RW, Ilev IK, Longo L, Miracco C, Johnson B, Anders JJ. Photobiomodulation improves cutaneous wound healing in an animal model of type II diabetes. *Photomed Laser Surg.* 2004;22(4):281-90.
10. Maiya GA, Kumar P, Rao L. Effect of low intensity helium-neon (He-Ne) laser irradiation on diabetic wound healing dynamics. *Photomed Laser Surg.* 2005;23(2):187-90.
11. Mirzaei M, Bayat M, Mosafa N, Mohsenifar Z, Piryaei A, Farokhi B, Rezaei F, Sadeghi Y, Rakhshan M. Effect of low-level laser therapy on skin fibroblasts of streptozotocin-diabetic rats. *Photomed Laser Surg.* 2007;25(6):519-25.
12. Al-Watban FA, Zhang XY, Andres BL. Low-level laser therapy enhances wound healing in diabetic rats: a comparison of different lasers. *Photomed Laser Surg.* 2007;25(2):72-7.
13. Lerman OZ, Galiano RD, Armour M, Levine JP, Gurtner GC. Lerman OZ, Galiano RD, Armour M, Levine JP, Gurtner GC. Impairment in migration, vascular endothelial growth factor production and response to hypoxia. *Am J Pathol.* 2003;162(1):303-12.
14. Deveci M, Gilmont RR, Dunham WR, Mudge BP, Smith DJ, Marcelo CL. Glutathione enhances fibroblasts collagen contraction and protects keratinocytes from apoptosis in hyperglycaemic culture. *Br J Dermatol.* 2005;152:217-24.
15. Ochoa O, Torres FM, Shireman PK. Chemokines and diabetic wound healing. *Vascular.* 2007;15(6):350-5.
16. Yu W, Naim JO, Lanzafame RJ. Effects of photostimulation, on wound healing in diabetic mice. *Laser Surg. Med.* 1997;20:56-63.
17. Bayat M, Kamali F, Dadpay M. Effect of low-level infrared laser therapy on large surgical osteochondral defect in rabbit: a histological study. *Photomed Laser Surg.* 2009 Jan 26. [Epub ahead of print]
18. Bach KK, Cupp C, Brewster D, Wester D, Keefe M. Effects of activated macrophages and fibroblast growth factor on random skin flap survival in swine. *Laryngoscope.* 1999;109(7 Pt 1):1156-9.
19. Ozelik O, Cenk Haytac M, Kunin A, Seydaoglu G. Improved wound healing by low-level laser irradiation after gingivectomy operations: a controlled clinical pilot study. *J Clin Periodontol.* 2008;35(3):250-4.

Conflict of interest: none
Financial source: none

Correspondence:

Paulo de Tarso Camillo de Carvalho
Av. Ministro Geraldo Barreto Sobral, 2021/1103
49026-010 Aracaju - SE Brazil
Phone: (55 79)8101-9771
pauloufs@terra.com.br

Received: August 19, 2009
Review: October 21, 2009
Accepted: November 25, 2009

How to cite this article

Carvalho PTC, Silva IS, Reis FA, Perreira DM, Aydos RD. Influence of ingaalp laser (660nm) on the healing of skin wounds in diabetic rats. *Acta Cir Bras.* [serial on the Internet] 2010 Jan-Feb;25(1). Available from URL: <http://www.scielo.br/acb>