

Liver cirrhosis on the colonic anastomotic healing in rats¹

Cirrose hepática na cicatrização de anastomose intestinal em ratos

Marcelo di Bonifácio^I, Rogério Serafim Parra^{II}, Ana Luiza Normanha Ribeiro de Almeida^{III}, José Joaquim Ribeiro da Rocha^{IV}, Omar Feres^V

^IFellow Master degree, Department of Surgery and Anatomy, FMRP-USP, Ribeirao Preto-SP, Brazil. Main author, responsible for manuscript preparation

^{II}Fellow Master degree, Department of Surgery and Anatomy, FMRP-USP, Ribeirao Preto-SP, Brazil. Responsible for manuscript writing, critical revision

^{III}Fellow Master degree, Department of Surgery and Anatomy, FMRP-USP, Ribeirao Preto-SP, Brazil. Responsible for English language

^{IV}PhD, Head of Division of Coloproctology, Department of Surgery and Anatomy, FMRP-USP, Ribeirao Preto-SP, Brazil. Responsible for intellectual and scientific content of the study

^VPhD, Associate Professor, Department of Surgery and Anatomy, FMRP-USP, Ribeirao Preto-SP, Brazil. Responsible for intellectual and scientific content of the study, critical revision

ABSTRACT

PURPOSE: To investigate the effects of cirrhosis on colonic anastomosis healing in rats.

METHODS: Fifty five Wistar male rats were used (23 in the control group and 32 in the cirrhosis group). On the first day of the procedure, the rats in the cirrhosis group underwent double ligation and folding of the common bile duct to induce liver cirrhosis, and the control rats underwent a laparotomy and intestinal manipulation. On the fourteenth and thirty-fifth days, all of the animals were biochemically assessed for serum aspartate aminotransferase (AST), alanine aminotransferase (ALT), alkaline phosphatase, bilirubin, total protein, and albumin and for liver histopathology. On the thirty-fifth day, cirrhosis was confirmed. On the twenty-eighth day, all of the animals were subjected to left colon transection and anastomosis. On the seventh day after the colonic anastomosis, the rats were sacrificed and macroscopically evaluated for dehiscence. The region of the colonic anastomosis was removed and subjected to hydroxyproline content measurement, conventional histology, and the immunohistochemical determination of vascular endothelial growth factor (VEGF) and matrix metalloproteinase type 1 (MMP 1).

RESULTS: The biochemical and histopathological examinations confirmed cirrhosis in all of the animals in the cirrhosis group. More deaths occurred after anastomosis in the cirrhosis group (5/25) than in the control group (0/21), and anastomotic dehiscence was more frequent in the cirrhosis group (8/25) than in the control group (0/21). The average hydroxyproline concentration was lower in the cirrhosis group than in the control group. The immunohistochemical studies showed that the average VEGF expression in the cirrhosis group was lower than in the control group, and the average MMP1 expression was higher in the cirrhosis group.

CONCLUSION: Hepatic cirrhosis leads to increased mortality and colonic anastomotic dehiscence, an increased distance between the mucosal edges of the anastomosis area, and a lower hydroxyproline concentration in the colonic anastomosis; therefore, these conditions are deleterious to healing.

Keywords: Wound Healing. Surgical Anastomosis. Colon. Surgical Wound Dehiscence. Liver Cirrhosis. Rats.

RESUMO

OBJETIVO: Investigar os efeitos da cirrose hepática na cicatrização de anastomose intestinal em ratos.

MÉTODOS: Este estudo avaliou o efeito da cirrose hepática na cicatrização de anastomoses em ratos. 55 ratos Wistar machos foram utilizados (23 controles e 32 no grupo cirrose). No primeiro dia os ratos do grupo cirrose foram submetidos à dupla ligadura e enovelamento do ducto hepático comum para indução de cirrose e os ratos controles foram submetidos à laparotomia e manipulação das alças intestinais. No dia 14 e 35, todos os animais foram avaliados bioquimicamente para dosagem sérica da alanina aminotransferase (AST), alanina aminotransferase (ALT), fosfatase alcalina, bilirrubinas, proteínas totais, albumina e histologia do fígado. No dia 35 a

cirrose foi confirmada. No dia 28 todos os animais foram submetidos à colectomia esquerda e anastomose. 70 dias após anastomose os ratos foram submetidos à eutanásia e foram avaliados macroscopicamente a procura de deiscência. A região da anastomose colônica foi removida para dosagem de hidroxiprolina, histologia convencional e imunohistoquímica para determinação do fator de crescimento endotelial vascular (VEGF) e metaloproteinase tipo 1 (MMP 1).

RESULTADOS: A análise bioquímica e histológica confirmou a cirrose em todos os animais do grupo cirrose. Óbito ocorreu em maior frequência após a anastomose no grupo cirrose (5/25) se comparado com grupo controle (0/21), e a deiscência da anastomose foi mais frequente no grupo cirrose (8/25) se comparado com controle (0/21). A concentração média de hidroxiprolina foi menor no grupo cirrose se comparado com grupo controle. A análise imunohistoquímica mostrou que a expressão VEGF no grupo cirrose foi menor que no grupo controle e a expressão média da MMP1 foi maior no grupo cirrose.

CONCLUSÃO: A cirrose hepática leva a aumento de mortalidade e aumento na deiscência de anastomose, aumento na distância entre as pontes mucosas na area da anastomose, menor nível de hidroxiprolina na anastomose colônica e assim pior condição de cicatrização.

Descritores: Cicatrização de Feridas. Anastomose Cirúrgica. Cólon. Deiscência da Ferida Operatória. Cirrose Hepática. Ratos.

Introduction

Anastomotic dehiscence is a serious complication that occurs after gastrointestinal tract operations¹ and increases morbidity and mortality in patients²⁻⁷. Several technical, local, and systemic factors influence the occurrence of colonic anastomotic dehiscence.

Certain systemic conditions, such as hypotension, hypovolemia, intestinal ischemia, low oxygen tension, advanced malignant neoplasia, dehydration, uremia, age and malnutrition, can affect healing⁸⁻¹⁴. Some studies have shown a higher incidence of colonic anastomotic dehiscence in patients with intraoperative hypotension, anemia, and cirrhosis^{1,6}.

Some studies have shown that liver cirrhosis interferes with the healing of abdominal incisions and decreases collagen in these areas, which leads to dehiscence¹⁵⁻¹⁹. Other authors have published studies evaluating the healing of peptic ulcers in patients with hepatic cirrhosis²⁰, but there are few studies on hepatic cirrhosis and anastomosis healing²¹⁻²³. Patients with cirrhosis may require colonic anastomosis, which causes concern on the part of the surgeon²². This study evaluated the influence of hepatic cirrhosis on the healing of colonic anastomosis.

Methods

Healthy, male Wistar rats (55 total; 300 grams, 60 days old; *Rattus norvegicus*) were used in this study. The animals were divided into two groups: cirrhosis and control.

To induce liver cirrhosis, we used an experimental model that consisted of performing a double ligation and folding the common bile duct of the rat^{24,25}. Clinical evaluations were performed by staining the sclera, performing choleric diuresis, and confirming cholestasis by determining the serum AST,

ALT, bilirubin, alkaline phosphatase, total protein, and albumin concentrations²⁵. We also performed a liver biopsy to confirm cirrhosis.

On the first day of the experiment, the rats in the cirrhosis group underwent biliary obstruction, and the rats in the control group underwent a laparotomy and bowel manipulation. On the fourteenth day, all of the animals were subjected to blood withdrawal (2 ml) from the tail vein for biochemical examination. The rats in the cirrhosis group were injected with 0.2 ml of a solution containing 0.02 ml of vitamin K diluted in 0.2 ml of saline. The control rats received 0.2 ml of saline subcutaneously. On the twenty-eighth day, all of the animals were subjected to transection and anastomosis of the left colon and received a subcutaneous injection of either vitamin K (cirrhosis group) or saline (control group), as previously described⁸. On the thirty-fifth day (seven days after the anastomosis), the animals were sacrificed, and their abdominal cavities were evaluated macroscopically for the presence of anastomotic dehiscence and peritonitis. Blood (2 ml) was also collected from the inferior vena cava for the biochemical study. A liver biopsy and a 2-cm resection from the area containing the anastomosis were collected to determine the colonic hydroxyproline content and for histopathological and immunohistochemical evaluations. A biochemical analysis was performed to determine the hydroxyproline concentrations^{26,27}.

The hepatic biopsy tissues were stained with hematoxylin and eosin and Masson's trichrome, and the presence or absence of hepatic cirrhosis was evaluated histopathologically. The tissues containing areas of anastomosis were separated and evaluated by immunohistochemistry for VEGF and MMP1.

Slides were prepared by immunohistochemistry for VEGF and MMP1 and were analyzed with an IBM-PC microcomputer and an Zeiss-Axiophot light microscope. The images were captured with a JVC-TK1270 camera and analyzed

with KS 400 (version 2.0; Kontron Elektronik GmbH). We developed two macro applications for capturing the images and analyzing the immunohistochemical staining. We studied 20 fields in the center of each anastomosis, starting from the edge of the mucosa to the serosa. After capturing the images, the program calculated the percentage of the stained area, and the values were statistically analyzed.

Statistical analyses were performed using a nonparametric Mann-Whitney test²⁸ to analyze the bilirubin, AST, ALT, alkaline phosphatase, total protein, albumin, hydroxyproline, VGEF, and MMP1 results. We used Fisher's exact test to compare the macroscopic findings of the abdominal cavities (adhesions and anastomotic dehiscence) and the death rates. $p < 0.05$ was considered statistically significant.

Results

On the fourteenth day (Table 1) and on the thirty-fifth day (Table 2) of the experiment, the animals in the cirrhosis group had significant increases in their average concentration of total bilirubin, direct bilirubin, AST, ALT, and alkaline phosphatase but a decreased concentration of albumin compared to control group. However, all of the concentrations were within normal ranges.

The biochemical values of the cirrhosis group on the fourteenth and thirty-fifth days were compared, and significant differences were observed for ALT, the total protein, and albumin (Table 3).

TABLE 1 - Mean values for serum determinations – 14th experimental day.

	CIRRHOSIS GROUP	CONTROL GROUP	NORMAL VALUES*	p
TB (mg/dL)	7.10 ± 2.32	0.25 ± 0.13	0.60 ± 0.20	$p < 0.0001$
DB (mg/dL)	4.94 ± 1.61	0.08 ± 0.06	0.30 ± 0.20	$p < 0.0001$
AST (U/L)	366.65 ± 129.85	130.96 ± 20.04	91.00 ± 29.00	$p < 0.0001$
ALT (U/L)	115.87 ± 46.75	47.44 ± 10.48	44.00 ± 18.00	$p < 0.0001$
AP (U/L)	349.74 ± 91.49	140.09 ± 39.11	83.00 ± 29.00	$p < 0.0001$
TP (mg/dL)	7.54 ± 0.38	6.97 ± 0.34	6.47 ± 0.67	$p < 0.0001$
Alb (mg/dL)	2.66 ± 0.29	2.96 ± 0.40	2.93 ± 0.56	$p < 0.0030$

TB=total bilirubin, DB=direct bilirubin, AST=aspartate-aminotransferase, ALT=alanine-aminotransferase, AP=alkaline phosphatase, TP=total protein, Alb=albumin

*Normal values (Castro e Silva Jr)²⁵

TABLE 2 - Mean values for serum determinations – 35th experimental day.

	CIRRHOSIS GROUP	CONTROL GROUP	NORMAL VALUES*	p
TB (mg/dL)	5.99 ± 1.13	0.22 ± 0.11	0.60 ± 0.20	$p < 0.0001$
DB (mg/dL)	4.69 ± 1.08	0.07 ± 0.04	0.30 ± 0.20	$p < 0.0001$
AST (U/L)	344.35 ± 72.94	200.32 ± 48.10	91.00 ± 29.00	$p < 0.0001$
ALT (U/L)	91.05 ± 22.62	64.27 ± 33.32	44.00 ± 18.00	$p < 0.0003$
AP (U/L)	370.40 ± 120.28	136.59 ± 32.37	83.00 ± 29.00	$p < 0.0001$
TP (mg/dL)	6.26 ± 0.88	6.65 ± 0.34	6.47 ± 0.67	$p < 0.0770$
Alb (mg/dL)	1.61 ± 0.34	2.63 ± 0.43	2.93 ± 0.56	$p < 0.0001$

TB=total bilirubin, DB=direct bilirubin, AST=aspartate-aminotransferase, ALT=alanine-aminotransferase, AP=alkaline phosphatase, TP=total protein, Alb=albumin

*Normal values (Castro e Silva Jr)²⁵

TABLE 3 - Mean serum levels on 14th and 35th experimental Day – Cirrhosis group.

	14 th DAY	35 th DAY	NORMAL VALUES*	p
ALT (U/L)	115.87 ± 46.75	91.05 ± 22.62	44.00 ± 18.00	$p < 0.0400$
TP (mg/dL)	7.54 ± 0.38	6.26 ± 0.88	6.47 ± 0.67	$p < 0.0001$
Alb (mg/dL)	2.66 ± 0.29	1.61 ± 0.34	2.93 ± 0.56	$p < 0.0001$

ALT=alanine-aminotransferase, TP=total protein, Alb=albumin

*Normal values (Castro e Silva Jr)²⁵

Clinical course of the animals

The cirrhosis group had a significantly greater number of deaths in the post-anastomotic period ($p < 0.05$) compared to the control group. All of the animals in the cirrhosis group that survived until the day of sacrifice developed hepatic cirrhosis, which was confirmed by histological examinations. There was a greater frequency of anastomotic dehiscence in the cirrhosis group (8/20) than in the control group (0/22) ($p < 0.001$).

Biochemical evaluation of the anastomosis

The mean hydroxyproline concentration was significantly lower in the cirrhosis group (430.46 ± 75.06 mg/g) than in the control group (662.27 ± 126.59 mg/g) ($p < 0.0001$) (Figure 1).

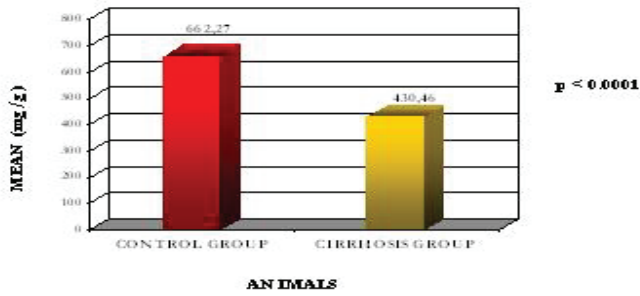


FIGURE 1 – Control Group. There is less distance between the edges and mucosal repair area.

Immunohistochemical analysis

VEGF expression was lower in the cirrhosis group (0.39 ± 0.14 of infiltrated area/ mm^2) than in the control group (0.42 ± 0.12 of infiltrated area/ mm^2) (Figure 2). MMP1 expression was greater in the cirrhosis group (0.39 ± 0.13 of infiltrated area/ mm^2) than in the control group (0.33 ± 0.06 of infiltrated area/ mm^2) (Figure 3). The animals in the cirrhosis group had a greater distance between the edges of the mucosal repair, which revealed worse healing (Figures 4 and 5).

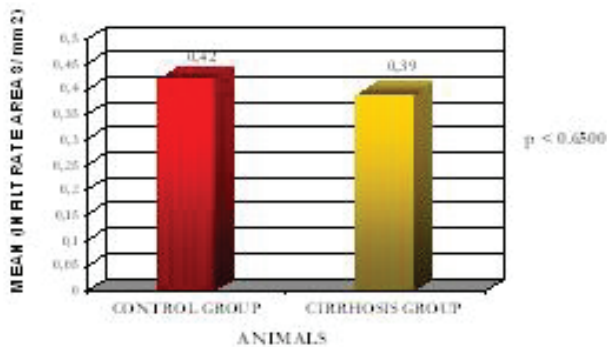


FIGURE 2 – Cirrhosis group. There is greater distance distance between the edges and mucosal repair area.

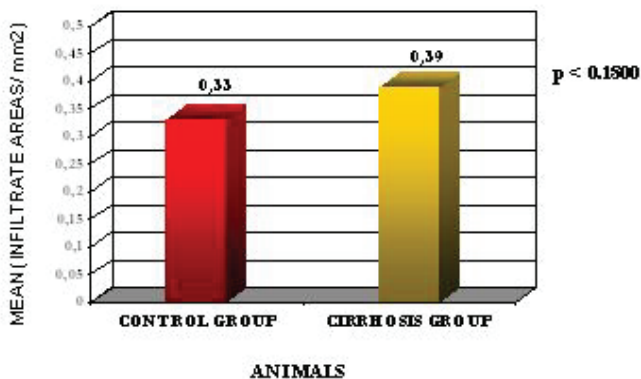


FIGURE 3 - Mean MMP1 values.

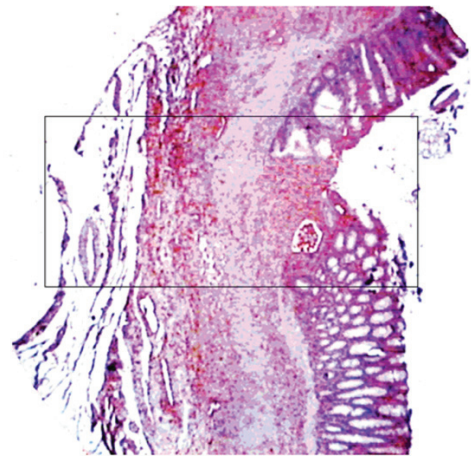


FIGURA 4 - Control group. Smaller distance between the mucous membrane and the repair area.

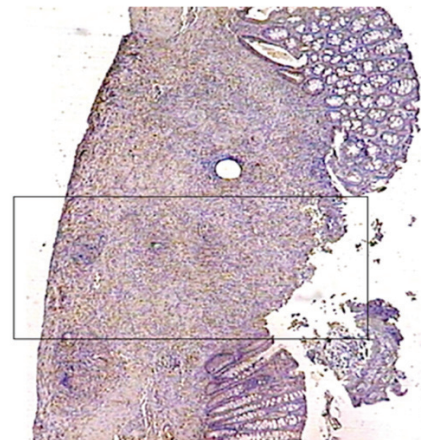


FIGURA 5 - Cirrhosis group. Larger distance between the mucous membrane and the repair area

All of the animals that underwent bile obstruction progressed to cirrhosis. This was confirmed by the hepatic histopathology, which exhibited areas of hepatocellular necrosis, diffuse regenerative nodules, and peri-portal fibrosis, and led to sinusoidal cytoarchitectural disorganization.

Discussion

This experiment studied the effects of hepatic cirrhosis on the healing of colonic anastomosis in rats. To evaluate these effects, we examined the results of biochemical cholestasis, hepatic histopathological analyses, aspects of the abdominal cavity, macro- and microscopic findings of colonic anastomosis, tissue hydroxyproline concentrations, and immunohistochemical analyses of VEGF and MMP1.

We used an experimental model to induce hepatic cirrhosis in rats, which consisted of double ligation and folding

of the common bile duct. This model was used because it has the lowest incidence of duct recanalization²⁵.

On the fourteenth day of the experiment, the biochemical analyses and liver functions were significantly different between the two groups for all of the serum parameters. The bilirubin, AST, ALT and alkaline phosphatase measurements were higher in the cirrhosis group than in the control group. These results were expected because common bile duct ligation is an excellent method for inducing extrahepatic cholestasis in rats²⁵.

On the thirty-fifth day, the mean albumin level in the cirrhosis group (1.61 ± 0.34 mg/dl) was significantly reduced to below the normal level (2.93 ± 0.56 mg/dl). These findings show that cholestasis (but not liver cirrhosis) was established fourteen days after the bile obstruction.

More deaths occurred in the cirrhosis group during the period after the anastomosis; however, no rats died during this period in the control group. This difference was statically significant.

There was no anastomotic dehiscence in the control group, but dehiscence was observed in eight animals in the cirrhosis group (40.0%). This difference between the groups was statistically significant. In a study of fifty-eight cases of abdominal wall dehiscence, a significant relationship was found between dehiscence and hypoproteinemia²⁹. Jaundice, when not accompanied by hypoproteinemia, does not increase the rate of dehiscence, probably because hepatic function is not significantly impaired before hypoproteinemia is established. Increased rates of abdominal wall dehiscence and incisional hernias have been found in jaundiced patients²⁰.

We found a significantly lower hydroxyproline concentration in the cirrhosis group than in the control group. Hydroxyproline is essential for the structural stability of collagen at the end of its synthesis and is very abundant. Proline and hydroxyproline constitute about 25% of the collagen molecule and provide stability to the molecule because they are made of fibrils. Hydroxyproline is measured to biochemically analyze the collagen concentration in the scar tissue, and its increased concentration is commonly associated with lower rates of healing. A lower hydroxyproline concentration has been observed in the healing of the abdominal walls of cirrhotic rats^{17,30}.

Healing worsens as the bile obstruction is prolonged³⁰. In this study, we evaluated anastomosis and the lower hydroxyproline concentration, which correspond to less collagen and less efficient healing in cirrhotic rats. In the control group, the anastomosis area was virtually reconstructed and repaired on the seventh post-operative day. The distance between the mucosal edges was lower

in the control group than in the cirrhosis group. This indicates less capacity for regeneration and epithelialization in the anastomosis areas of the rats in the cirrhosis group.

There was no statistically significant difference in VEGF expression between the two groups at the anastomosis level, but the cirrhosis group had less VEGF expression and angiogenesis. Thus, hepatic cirrhosis may have a possible anti-angiogenic effect and hinder healing of the anastomosis. This conclusion is based on the macroscopic and biochemical parameters that were analyzed. There was more MMP1 in the cirrhosis group than in the control group, but this difference was not significant. We know that metalloproteinases degrade collagen, and, therefore, have deleterious effects on healing. Our findings confirm the negative results regarding the hydroxyproline content and the increased number of dehiscences in the cirrhosis group.

Conclusion

Hepatic cirrhosis increases post-operative mortality and has deleterious effects on the healing of colonic anastomosis.

References

- Schrock TR, Deveney CW, Dunphy JE. Factors contributing to leakage of colonic anastomoses. *Ann Surg.* 1973;177(5):513-8.
- Bearhs OH. Complications of colonic surgery. *Surg Clin North Am.* 1967;47:983-8.
- Debas HT, Thomson FB. A critical review of colectomy with anastomosis. *Surg Ginecol Obstet.* 1972;135:747-52.
- Goligher JC, Graham NG, De Dombal FT. Anastomotic dehiscence after anterior resection of rectum and sigmoid. *Br J Surg.* 1970;57:109-18.
- Makela JT, Kiviniemi H, Laitinen S. Risk factors for anastomotic leakage after left-sided colorectal resection with rectal anastomosis. *Dis Colon Rectum.* 2003;46(5):653-60.
- Pucciarelli S, Toppan P, Friso ML, Fornasiero A, Vieceli G, Marchiori E, Lise M. Preoperative combined radiotherapy and chemotherapy for rectal cancer does not affect early postoperative morbidity and mortality in low anterior resection. *Dis Colon Rectum.* 1999;42:1276-84.
- Ravo B, Metwally N, Castera P, Polansky PJ, Ger R. The importance of intraluminal anastomotic fecal contact and peritonitis in colonic anastomotic leakages. An experimental study. *Dis Colon Rectum.* 1988;31(11):868-71.
- Franca A, Ramalho FS, Ramalho LN, Ribeiro da Rocha JJ, Feres O. Effects of preoperative pelvic irradiation on colonic anastomosis healing. An experimental study in rats. *Acta Cir Bras* 2008;23(Suppl 1):24-30.
- Di Mario F, Gottardelli L, Burra P, Salvagnini M, Dalri L, Leandro G, Contento F, Torri A, Naccarato. A clinic-endoscopic study on healing of lesions and prevention of recurrences in patients with liver cirrhosis and peptic ulcer. *G Clin Med.* 1990;71(4):259-66.
- Colin JF, Elliot P, Ellis H. The effect of uraemia upon wound healing. *Br J Surg.* 1979;66(11):793-7.
- Gilmour DG, Aitkenhead AR, Hothersall AP, Ledingham IM. The

- effect of hipovolaemia on colonic blood flow in dog. *Br J Surg.* 1980;67:82-4.
- 12- Hartmann M, Jonsson K, Zederfeldt B. Importance dehydration in anastomotic and subcutaneous wound healing: an experimental study in rats. *Eur J Surg.* 1992;158(2):79-82.
- 13- Irvin TT, Goligher JC. Aetiology of disruption of intestinal anastomoses. *Br J Surg.* 1973;60(6):461-4.
- 14- Sheridan WG, Lowndes RH, Young HL. Tissue oxygen tension as a predictor of colonic anastomotic healing. *Dis Colon Rectum.* 1987;30:867-71.
- 15- Bayer I, Ellis H. Jaundice and wound healing: an experimental study. *Br J Surg.* 1976;63:392-6.
- 16- Conn HO, Atterbury CE. Cirrhosis. In: Schiff L, Schiff E (eds). *Diseases of the liver.* Philadelphia: J.B. Lippincott; 1987. p.725-864.
- 17- Makishima T. Experimental study of the wound healing in liver cirrhosis. *Nippon Geka Gakkai Zasshi.* 1989;90:1706-12.
- 18- Makishima T, Saito H, Morioka Y. The effect of immunological response on wound healing in rat with liver cirrhosis. *Nippon Geka Gakkai Zasshi.* 1991;92:144-9.
- 19- McGee JO, O'Hare RP, Patrick RS. Collagen-stimulating factors in healing wounds and experimental liver disease. *J Pathol.* 1973;109(1):Pxx.
- 20- Jorge, GD, Leonardi LS, Boin IFSF, Castro and Silva Jr. O, Escanhoela CAF. A new method for the experimental induction of secondary biliary cirrhosis in Wistar rats. *Acta Cir Bras.* 2001;16(2):75-81.
- 21- Le Rolland B, Kahwaji F, Smadja C, Traynor O, Grange D, Franco D. Management of colorectal cancer in patients with cirrhosis and Le Veen shunt. *Int Surg.* 1987;72(2):93-5.
- 22- Metcalf AM, Dozois RR, Wolff BG, Bear Jr. RW. The surgical risk of colectomy in patients with cirrhosis. *Dis Colon Rectum.* 1987;30:529-31.
- 23- Tsugawa K, Koyanagi N, Hashizume M, Tomikawa M, Ayukawa K, Akahoshi K, Sugimachi K. A comparison of an open and laparoscopic appendectomy for patients with liver cirrhosis. *Surg Laparosc Endosc Percutan Tech.* 2001;11:189-94.
- 25- Castro e Silva Jr. O, Mazzeto AS, De Souza MEJ, Picinato MAN, Sankarankutty AK. Obstrução biliar extra hepática. In: Castro e Silva Jr. O (ed.). *Modelos experimentais de pesquisa em cirurgia.* São Paulo: Robe Editorial; 1998. p.193-200.
- 26- Cohen SR, Cornell CN, Collins MH, Sell JE, Blanc WA, Altman RP. Healing of ischemic colonic anastomoses in the rat: role of antibiotic preparation. *Surgery.* 1985;97:443-6.
- 27- Stegemann H, Stalder K. Determination of hydroxyproline. *Clin Chim Acta.* 1967;18:267-73.
- 28- Siegel S. *Nonparametric statistics for the behavioral sciences.* New York: McGraw Hill; 1956.
- 29- Keill RH, Keitzer WF, Nichols WK, Henzel J, DeWeese MS. Abdominal wound dehiscence. *Arch Surg.* 1973;106(4):573-7.
- 30- Greaney MG, Van Noort R, Smythe A, Irvin TT. Does obstructive jaundice adversely affect wound healing? *Br J Surg.* 1979;66:478-81.

Correspondence:

Omar Feres
Faculdade de Medicina de Ribeirão Preto-USP
Departamento de Cirurgia e Anatomia
Disciplina de Coloproctologia
Campus Universitário, 9º andar
14048-900 Ribeirão Preto-SP Brasil
Tel./Fax: (55 16)3621-1122
omar.feres@hspaulo.com.br
rogeriosparra@gmail.com

Received: May 11, 2011

Review: July 12, 2011

Accepted: August 15, 2011

Conflict of interest: none

Financial source: none

¹Research performed at Department of Surgery and Anatomy, Ribeirao Preto School of Medicine, University of Sao Paulo (FMRP-USP), Brazil.

Presented at XII National Congress on Experimental Surgery of the Brazilian Society for Development of Research in Surgery-SOBRADPEC 2011 October 26-29, Ribeirao Preto-SP, Brazil