

Effect of N-acetylcysteine on lung injury induced by skeletal muscle ischemia-reperfusion. Histopathological study in rat model¹

Efeito de N-acetilcisteína em dano pulmonar induzido por isquemia-reperusão de músculo esquelético. Estudo histopatológico em modelo de rato

Amir Sotoudeh^I, Mohammad Ashrafzadeh Takhtfooladi^{II}, Amirali Jahanshahi^{III}, Adel Haghghi Khiabani Asl^{IV}, Hamed Ashrafzadeh Takhtfooladi^V, Mohammadreza Khansari^{VI}

^IAssistant Professor, Faculty of Veterinary Science, Kahnooj Branch, Islamic Azad University, Kerman, Iran. Design, supervised all phases of the study, analysis and interpretation of data, manuscript writing.

^{II}Fellow PhD degree, Department of Surgery, Faculty of Specialized Veterinary Sciences, Science and Research Branch, Islamic Azad University, Tehran, Iran. Conception, design and scientific content of study, analysis and interpretation of data, manuscript writing.

^{III}Fellow PhD degree, Department of Surgery, Faculty of Specialized Veterinary Sciences, Science and Research Branch, Islamic Azad University, Tehran, Iran. Helped with technical procedures, collection and processing of study informations, analysis and interpretation of data.

^{IV}Assistant Professor, Department of Pathology, Faculty of Specialized Veterinary Sciences, Science and Research Branch, Islamic Azad University, Tehran, Iran. Histological analysis.

^VGraduate student, Faculty of Veterinary Sciences, Karaj Branch, Islamic Azad University, Alborz, Iran. Helped with technical procedures and collection of study informations.

^{VI}Master, Department of Physiology, Faculty of Specialized Veterinary Sciences, Science and Research Branch, Islamic Azad University, Tehran, Iran. Statistical analysis.

ABSTRACT

PURPOSE: To investigate whether N-acetylcysteine, a free radicals scavenger has a protective effect against lung injury as a remote organ after skeletal muscle ischemia-reperfusion.

METHODS: Twenty Wistar male rats were divided randomly into two experimental groups: group ischemia-reperfusion (group I) and group ischemia-reperfusion + N-acetylcysteine (group II). All animals were undergone two hours of ischemia by occlusion femoral artery and 24h of reperfusion. Before clamped the femoral artery, 250 IU heparin was administered via the jugular vein to prevent clotting. Rats that were treated with N-acetylcysteine given IV at a dose of 150 mgkg⁻¹, immediately before reperfusion. After 24h of reperfusion, animals were euthanized and left lung harvested for histopathological analysis under light microscopy.

RESULTS: In the group I, tissues showed histological changes with intra-alveolar edema, intra-alveolar hemorrhage and neutrophilic infiltration. Histopathologically, there was a significant difference (P = 0.005) between two groups.

CONCLUSION: Administration of N-acetylcysteine treatment significantly decreased lung injury induced by skeletal muscle ischemia reperfusion according to histological findings.

Key words: Acetylcysteine. Muscle, Skeletal. Lung. Ischemia. Reperfusion. Reperfusion Injury. Histology. Rats.

RESUMO

OBJETIVO: Investigar se N-acetilcisteína, neutralizador de radicais livres, tem efeito protetor contra dano pulmonar como um órgão remoto após isquemia-reperusão de músculo esquelético.

MÉTODOS: Vinte ratos machos Wistar, foram aleatoriamente distribuídos em dois grupos: grupo isquemia-reperusão (grupo I) e grupo isquemia-reperusão +N-acetilcisteína (grupo II). Todos os animais foram submetidos a duas horas de isquemia pela oclusão artéria femoral e 24 horas de reperusão. Antes de ocluir a artéria femoral, foi administrado 250 IU de heparina pela veia jugular para prevenir coagulação. A N-acetilcisteína foi administrada por via intravenosa, na uma dose de 150 mgkg⁻¹, imediatamente antes de reperusão. Após 24 horas de reperusão, os animais foram eutanasiados e o pulmão esquerdo foi removido para análise histológica em microscopia óptica. **RESULTADOS:** No grupo I, os tecidos mostraram alterações histológicas com edema e hemorragia intra-alveolar e infiltração neutrofílica. Houve diferença histopatológica significativa (P = 0.005) entre os dois grupos. **CONCLUSÃO:** O tratamento com a N-acetilcisteína diminuiu significativamente o dano pulmonar induzido por isquemia-reperusão de músculo esquelético

Descritores: Acetilcisteína. Músculo Esquelético. Pulmão. Isquemia. Reperusão. Traumatismo por Reperusão. Histologia. Ratos.

Introduction

Many surgical procedures, such as limb revascularization and free-flap reconstruction, involve prolonged ischemia of skeletal muscle. Ischemic damage can lead to severe postoperative complications¹. There are two components to the reperfusion syndrome, which follows extremity ischemia. The local response follows reperfusion and the systemic response, which results in multiple organ failure and death².

Ischemia reperfusion of the lower extremities causes lung injury because of polymorphonuclear sequestration in pulmonary microvasculature, increased endothelial permeability and interstitial edema³. Ischemic damage results from a decrease in the blood flow of the organ and reperfusion injury results from the enhanced generation of oxygen radicals⁴.

Several agents, such as caffeic acid phenethyl ester or Erdosteine are proposed to be useful against lung injury induced by oxidative stress damage, including ischemia-reperfusion or endotoxin instillation^{5,6}.

N-acetylcysteine is not simply an antioxidant drug. It acts as a glutathione precursor, as a chemical reductant of oxidized thiols, as a scavenger of radical oxygen species, as a vasodilator and also improves microcirculation by restoring the decreased activity of endothelium-derived relaxing factor and may have antiaggregan features^{7,8}. There is growing evidence regarding its beneficial effects in ameliorating lung ischemia-reperfusion injury⁹. However its role in reducing the damage in lung after skeletal muscle ischemia-reperfusion has not been addressed yet.

In this experimental study, we aimed to examine the protective effect of N-acetylcysteine on lung injury induced by the skeletal muscle ischemia-reperfusion by evaluation of histopathology in rat model.

Methods

Research performed in accordance with the Islamic Azad University Law on animal experimentation.

Twenty Wistar male rats weighing 220–250 g (5-7 weeks old) were used in this study. Animals were housed at an average ambient temperature of 22°C under a 12h/12h light/dark cycle before the experiment and were fed on a standard rodent diet and filtered tap water ad libitum. Animals were divided randomly into two experimental groups of ten rats each: group ischemia-reperfusion (group I) and group ischemia-reperfusion + N-acetylcysteine (group II). Anesthesia was induced using intramuscular ketamine (50 mgkg⁻¹) (ketamine Hcl 10% AlfasonWoerden-Holland) plus

xylazine (10 mgkg⁻¹) (2% AlfasonWoerden-Holland). After induction of anesthesia, the left hind limb was completely clipped with an electric shaver. After clipping, disinfecting and dropping (using a sterile technique), a skin incision was made on medial surface of the left hind limb. After isolated the femoral artery and vein from the surrounding structures, femoral artery was exposed and clamped with a mini bulldog forceps.

Before clamped the femoral artery, 250 IU heparin (Heparodic® 5000 Caspian tamin Rasht-Iran) was administered via the jugular vein to prevent clotting. All animals were undergone 2h of ischemia by occlusion femoral artery with a vascular clamp and 24h of reperfusion¹⁰. Rats were maintained in a dorsal recumbency and kept anesthetized throughout the duration of the ischemic period. Additional doses were given as necessary to maintain anesthesia during the experiment. Body temperature was maintained with a heating pad under anesthesia. In group I N-acetylcysteine (150 mgkg⁻¹) was injected intravenous immediately before reperfusion. Following the ischemic period, the vascular forceps was removed and then surgical site was routinely closed. During the reperfusion period, rats were returned to their cages with food and water ad libitum. After 24h of reperfusion, rats were euthanized with an overdose of intraperitoneal pentobarbital injection (300 mgkg⁻¹) and left lung harvested rapidly for histopathological analysis under light microscopy. Lung tissues were placed in 10% formalin solution and processed routinely by embedding in paraffin then tissues were sectioned in 6 µm pieces and stained with Hematoxylin-Eosin stain. An experienced pathologist who was unaware of the treatment conditions made histopathological assessments. Pulmonary injury was graded into four grades as follows: grade 0, no diagnostic change; grade 1, mild neutrophil leukocyte infiltration and mild to moderate interstitial congestion; grade 2, moderate neutrophil leukocyte infiltration, perivascular edema formation, and partial destruction of pulmonary architecture; and grade 3, included dense neutrophil leukocyte infiltration and complete destruction of pulmonary structure¹¹. A total of four slides from each lung sample were randomly screened and the mean was accepted as the representative value of the sample. Statistical analyses were carried out using SPSS statistical software (version 18). Results were expressed as the mean +/- standard deviation. The Mann-Whitney U-test was employed to analyze two groups consecutively. Values of P<0.05 were considered as statistically significant.

Results

All of rats tolerated operation and survived until the final

study period. Figure 1 illustrates representative photomicrograph of the lung tissues from group I and Figure 2 illustrates representative photomicrograph of the lung tissues from group II that obtained 24h after reperfusion. In the group I, tissues showed histological changes with intra-alveolar edema, intra-alveolar hemorrhage and neutrophilic infiltration. These pathological changes, particularly neutrophilic infiltration, were much less in the group II than in the group I. Histopathologically, there was a significant difference ($P=0.005$) between two groups (Table 1).

TABLE 1- Scores of pulmonary histological changes

Group	N	Mean \pm SD*
I	10	2.2 \pm 0.63
II	10	1.3 \pm 0.48

*There is significant difference ($P=0.005$) between two groups.

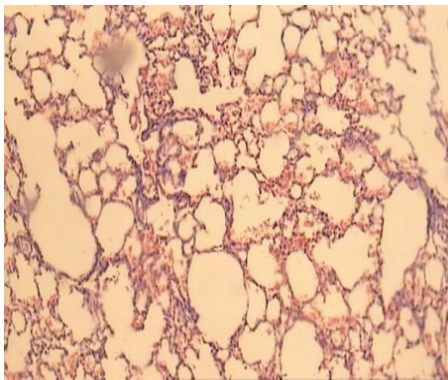


FIGURE 1 - Representative photomicrograph from lungs of the group I.

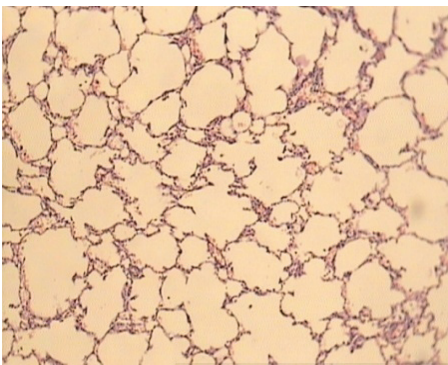


FIGURE 2 - Representative photomicrograph from lungs of the group II.

Discussion

In the lung the end-result of systemic or remote ischemia-reperfusion injury is non-cardiogenic pulmonary

oedema, or adult respiratory distress syndrome². There is evidence to suggest that neutrophils are activated directly by metabolites (e.g. leukotriene B₄, thromboxane A₂, complement C₅), that are produced by the ischaemic tissue and then go on to be trapped in the pulmonary circulation¹². There is also evidence to suggest that neutrophils are activated locally in the lung by the pulmonary endothelial production of platelet activating factor, thromboxane A₂, leukotriene B₄, and oxygen free radicals, which are neutrophil chemo-attractants¹³. The local release of thromboxane A₂ also causes pulmonary vasoconstriction, further increasing the chance of neutrophil-endothelial interaction and the no-reflow phenomenon. Interleukin-8 which is produced by alveolar macrophages and pulmonary endothelial cells and released into the systemic circulation during ischemia-reperfusion is also thought to play a role in activating neutrophils within the pulmonary pool, and the rest of the circulation¹⁴.

N-acetylcysteine exerts its effect both as a source of sulfhydryl groups (repletion of intracellular reduced glutathione) and through a direct reaction with hydroxyl radical¹⁵. Recently, a number of studies in animals suggest benefits from acetylcysteine in the context of systemic inflammatory response syndrome caused by severe sepsis model. In a pig gram-negative sepsis model, an infusion of acetylcysteine reduced pulmonary capillary leak without reducing mortality¹⁶. Acetylcysteine also beneficially modulates inflammatory cell function in animals¹⁶. Endothoxin-induced neutrophil activation in sheep lung is reduced by Acetylcysteine¹⁶. Additional protective effects of N-acetylcysteine may lie within the ability of this compound to reduce oxyradical-related oxidant processes by either directly interfering with the oxidants, or up-regulating antioxidant systems such as superoxide dismutase¹⁵ or enhancing the catalytic activity of glutathione peroxidase¹⁷. N-acetylcysteine has antioxidant property¹⁸ and as a sulfhydryl donor, may contribute to the regeneration of endothelium-derived relaxing factor and glutathione¹². Increasing evidence indicates that the action of N-acetylcysteine is pertinent to microcirculatory blood flow and tissue oxygenation. N-acetylcysteine was shown to enhance oxygen consumption via increased oxygen extraction in patients 18h after the onset of fulminant liver failure¹².

In an experimental study Boerjesson *et al.*¹⁹ showed that treatment with N-acetylcysteine prevents intestinal ischemia-reperfusion induced over activation of pulmonary macrophages and decreases pulmonary content. This observation was supported by Weinbraum *et al.*⁹, which demonstrated, pretreatment of the lungs with N-acetylcysteine during reperfusion period with ischemic reperfused liver effluent prevents acute lung injury. In a randomized clinical trial on patients with acute respiratory distress

syndrome, N-acetylcysteine enhanced recovery from acute lung injury²⁰. There are also several studies concerning beneficial role of N-acetylcysteine in ameliorating myocardial and brain injury^{21,22}.

In the current study, we tested the hypothesis that N-acetylcysteine could protect the lungs from remote organ injury after skeletal muscle ischemia-reperfusion. Our data demonstrate that N-acetylcysteine significantly decreases the severity of acute lung injury, decreases the infiltration of macrophages and polymorphonuclear leukocytes in the lungs, decreases pulmonary vascular permeability and inhibits cellular apoptosis in the lungs after skeletal muscle ischemia-reperfusion injury.

Conclusions

The present study demonstrates that temporary occlusion of the femoral artery of the rats resulted in altered pulmonary endothelial barrier function, with increased protein concentration and neutrophil infiltration. However, administration of the N-acetylcysteine treatment significantly decreased lung injury induced by skeletal muscle ischemia-reperfusion according to our histological findings. These results suggest the possibility of clinical application of N-acetylcysteine in ischemia-reperfusion injury of the lung. Different dosages, alternate time protocols and way of N-acetylcysteine administration for lung injury induced by skeletal muscle ischemia-reperfusion should be investigated in future studies.

References

1. Beyersdorf F, Unger A, Wildhirt A. Studies of reperfusion injury in skeletal muscle: preserved cellular viability after extended periods of warm ischemia. *J Cardiovasc Surg*. 1991;32:664-76.
2. Blaisdell FW. The pathophysiology of skeletal muscle ischemia and the reperfusion syndrome: a review. *Cardiovasc Surg*. 2002;10: 620-30.
3. Welbourn CR, Goldman G, Paterson IS, Valeri CR, Shepro D, Hechtman HB. Pathophysiology of ischaemia reperfusion injury: central role of the neutrophil. *Br J Surg*. 1991;78:651-5.
4. Schoenberg MH, Beger HG. Reperfusion injury after intestinal ischemia. *Crit Care Med*. 1993;21:1376-89.
5. Calikoglu M, Tamer L, Sucu N. The effects of caffeic acid phenethyl ester on tissue damage in lung after hindlimb ischemia-reperfusion. *Pharmacol Res*. 2003;48:397-403.
6. Mehmet S, Efsan UZ, Rana S. The effects of erdosteine on lung injury induced by the ischemia- reperfusion of the hind-limbs in rats. *J Surg Res*. 2008;145:303-7.
7. Tredger JM. N-acetylcysteine: not a simply glutathione precursor. *Transplantation*. 2000;69:703-4.
8. Arstall MA, Yang J, Stafford I, Betts WH, Horowitz JD. N-acetylcysteine in combination with nitroglycerin and streptokinase for the treatment of evolving acute myocardial infarction. Safety and biochemical effects. *Circulation*. 1995;92:2855-62.
9. Weinbroum AA, Rudick V, Ben-Abraham R, Kachevski E.

- N-acetyl-L-cysteine for preventing lung reperfusion injury after liver ischemia-reperfusion: a possible dual protective mechanism in a dose-response study. *Transplantation*. 2000;69(5):853-9.
10. Eberlin KR, McCormack MC, Nguyen JT, Tatlidede HS, Randolph MA, Austen Jr W. Ischemic preconditioning of skeletal muscle mitigates remote injury and mortality. *J Surg Res*. 2008;148:24-30.
11. Koksel O, Yildirim C, Cinel L, Tamer L, Ozdulger A, Bastürk M, Degirmenci U, Kanik A, Cinel I. Inhibition of poly (ADPribose) polymerase attenuates lung tissue damage after hind limb ischemia-reperfusion in rats. *Pharmacol Res*. 2005;51(5):453-62.
12. Harrison PM, Wendon YA, Gimson AES. Improvement by acetylcysteine of hemodynamics and oxygen transport in fulminant hepatic failure. *N Engl J Med*. 1991;324:1852-7.
13. Klausner JM, Paterson IS, Kobzik L. Oxygen free radical mediate ischemia-induced lung injury. *Surgery*. 1989;105:192-9.
14. Baggolini M, Walz A, Kunkel SL. Neutrophil activating peptide-1/interleukin-8, a novel cytokine that activates neutrophils. *J Clin Invest*. 1989;84:1045-9.
15. Galley HF, Howdle PD, Walker BE. The effect of intravenous antioxidants in patients with septic shock. *Free Radic Biol Med*. 1997;23:768-74.
16. Lucht WD, English DK, Bernard GR. Prevention of release of granulocyte aggregates into sheep lung lymph following endotoxemia by N-acetylcysteine. *Am J Med Sci*. 1987;294:161-7.
17. Schillier HJ, Reilly PM, Bulkley GB. Antioxidant therapy. *Crit Care Med*. 1993;21:92-102.
18. Aruoma OI, Halliwell B, Hoey BM. The antioxidant action of N-acetylcysteine: its reaction with hydrogen peroxide, hydroxyl radical, superoxide, and hypochlorous acid. *Free Radic Biol Med*. 1989;6:593-7.
19. Borjesson A, Wang X, Sun Z, Wallen R, Deng X, Johnson E. Effects of N-acetylcysteine on pulmonary macrophage activity after intestinal ischemia and reperfusion in rats / with invited commentaries. *Dig Surg*. 2000;17(4):379-87.
20. Suter PM, Domenighetti G, Schaller M, Laverriere M, Ritz R, Perret C. N-acetylcysteine enhances recovery from acute lung injury in man. A randomized, double-blind, placebo-controlled clinical study. *Chest*. 1994;105(1):190-4.
21. Cuzzocrea S, Mazzon E, Costantino G, Serraino I, Dugo L, Calabrò G, Cucinotta G, De Sarro A, Caputi AP. Beneficial effects of n-acetylcysteine on ischemic brain injury. *Br J Pharmacol*. 2000;130(6):1219-26.
22. Menasché P, Grousset C, Gauduel Y, Mouas C, Piwnica A. Maintenance of the myocardial thiol pool by N-acetylcysteine. An effective means of improving cardioplegic protection. *J Thorac Cardiovasc Surg*. 1992;103(5):936-44.

Correspondence:

Mohammad Ashrafzadeh
Department of Veterinary Surgery
Faculty of Specialized Veterinary Sciences
Sciences and Research Branch
Islamic Azad University
Hesarak, Tehran, Iran
Phone: 1477893855
Dr_ashrafzadeh@yahoo.com

Received: September 20, 2011

Review: November 22, 2011

Accepted: December 19, 2011

Conflict of interest: none

Financial source: none

¹Research performed at Department of Veterinary Surgery, Faculty of Specialized Veterinary Sciences, Islamic Azad University, Tehran, Iran.