

Effect of N-acetylcysteine in liver ischemia-reperfusion injury after 30% hepatectomy in mice¹

Efeito da N-acetilcisteína na lesão hepática por isquemia e reperfusão após 30% de hepatectomia em camundongos

Edwin Jin Su Lee^I, Sonia Maria da Silva^{II}, Manuel de Jesus Simões^{III}, Edna Frasson de Souza Montero^{IV}

^IMD, Department of Surgery, Division of Operative Technique and Experimental Surgery, UNIFESP, Sao Paulo, Brazil. Acquisition of data, manuscript writing.

^{II}PhD, BSc, Department of Surgery, UNIFESP, Sao Paulo, Brazil. Helped with technical procedures, collection and processing of study information.

^{III}PhD, Associate Professor, Department of Morphology, Division of Histology, UNIFESP, Sao Paulo, Brazil. Interpretation of data.

^{IV}PhD, Associate Professor, Department of Surgery, Division of Operative Technique and Experimental Surgery, UNIFESP and Laboratory of Medical Research (LIM-62), Surgical Physiopathology, Faculty of Medicine, Sao Paulo University, Brazil. Supervised all phases of the study, interpretation of data, statistical analysis, manuscript writing, critical revision.

ABSTRACT

PURPOSE: Evaluate the effect of *N*-acetylcysteine in liver remnant after hepatectomy associated to ischemia-reperfusion injury in mice.

METHODS: Male adult BALB/c mice, weighing 20-22g were used. Animals were anesthetized with ketamine (70 mg/kg) and xylazine (10 mg/kg); received *N*-acetylcysteine (150 mg/kg, H-IR-NAC group) or vehicle (H-IR group). Surgical procedures were performed under 10X magnification. Partial hepatectomy (30%) was followed by ischemia-reperfusion injury (30 minutes of ischemia and 60 minutes of reperfusion). Blood sample and liver tissue were removed before animal was euthanized. AST and ALT were evaluated in blood samples and histomorphological analyses were performed in remnant liver. Groups were compared by Mann-Whitney test, and it was considered significant when $p < 0.05$.

RESULTS: Biochemical evaluations showed reduced levels of ALT in NAC group (H-IR-NAC=376±127U/l vs H-IR=636±39U/l, $p=0.023$). AST was similar ($p=0.456$). H-IR group showed hepatic tissue with preserved architecture, large area of steatosis, vascular congestion and rare mitogenic activity. NAC group showed hepatic tissue with small area of steatosis, vascular congestion and elevated mitogenic activity, evidenced by increased binuclear cells (H-IR-NAC=15.88±0.52 vs H-IR=7.4±0.37, $p < 0.001$).

CONCLUSION: *N*-acetylcysteine promotes enzymatic and morphological protection against hepatectomy and ischemia-reperfusion injury.

Key words: Acetylcysteine. Reperfusion Injury. Hepatectomy. Mice.

RESUMO

OBJETIVO: Investigar se a N-acetilcisteína promove proteção do remanescente hepático após ressecção associada à isquemia e reperfusão do fígado em camundongos.

MÉTODOS: Foram utilizados 12 camundongos BALB/c, machos, pesando entre 20-22g. Os animais foram anestesiados com quetamina (70mg/kg) e xilazina (10mg/kg); receberam a N-acetilcisteína (150mg/kg, grupo H-IR-NAC) ou controle (grupo H-IR). Os procedimentos cirúrgicos ocorreram na magnificação de 10X. A lesão por isquemia e reperfusão (30 minutos de isquemia e 60 minutos de reperfusão) foi precedida pela hepatectomia de 30%. Foram utilizados como parâmetro de avaliação: a bioquímica sanguínea (AST e ALT) e a histologia do fígado (coloração de hematoxilina-eosina). Para avaliação estatística empregou-se o teste de Mann-Whitney e o nível de significância foi 5%.

RESULTADOS: Na avaliação bioquímica houve redução no nível de ALT no grupo tratado (H-IR-NAC=376±127 U/l vs H-IR=636±39 U/l, $p=0,023$). AST foi similar ($p=0,456$). Na histologia, o grupo H-IR apresentou um tecido hepático com arquitetura preservada, com grandes áreas de infiltração gordurosa, presença de congestão vascular e de alguma atividade mitótica; o grupo com a N-acetilcisteína apresentou menor infiltração gordurosa e congestão vascular, maior atividade mitótica, evidenciada pela quantidade elevada de células binucleadas (H-IR-NAC=15,88±0,52 vs H-IR=7,4±0,37, $p < 0,001$).

CONCLUSÃO: A N-acetilcisteína promove proteção ao fígado, do ponto de vista morfológico e enzimático, após hepatectomia associada à isquemia e reperfusão

Descritores: Acetilcisteína. Traumatismo por Reperfusão. Hepatectomia. Camundongos.

Introduction

The mortality in the transplant waiting list is still very high, due to scarcity of compatible donors for pediatric recipient¹. Some solutions have been made to increase the number of disposable graft: adult liver reduction, division of cadaver liver providing two possible grafts, or use of grafts from live donors¹⁻³. All of these techniques contributed to improve the number of liver grafts. In the other hand, the existing disproportion between graft and recipient is still a relevant problem: the inappropriate size brings hemodynamic and functional implications, occurring primary non-function or dysfunction³.

The ischemia-reperfusion lesion related to liver surgery and transplantation, in association to volume of parenchyma reduction, can synergically compromise the organ, stimulating laboratorial research to overcome such problems²⁻⁴.

Antioxidative vitamins, enzymes or other free radical scavengers have been shown diminish or neutralize oxygen and nitrogen free radicals^{5,6}. A low weight thiol, the N-acetylcysteine (NAC), has its use established in the acetaminophen intoxication, protecting the liver by increasing hepatic glutathione⁷.

NAC has been used in clinical practices in situations as hemodynamic instabilities, protecting hepatic, pulmonary, cardiac and renal tissues, compromised by ischemia and reperfusion. This applicability is supported by experimental animal studies, some done by our research team that showed local and systemic protection after ischemia-reperfusion injury⁸⁻¹⁰. NAC acts like an antioxidant beyond improving blood flow in microcirculation¹¹.

Since N-acetylcysteine shows protective action against ischemia and reperfusion lesion and that manipulation of liver promotes microcirculation changes, modifying the organ perfusion, it was decided to evaluate if N-acetylcysteine promotes protection to remnant liver after hepatectomy of 30% associated to liver ischemia-reperfusion injury in mice.

Methods

The experimental protocol was submitted and approved by UNIFESP Ethics Committee on Animal Research (CEP#1945/07). It was used twelve adult male BALB/c mice supplied by the Experimental Animal Center of UNIFESP, ranging in age from six to eight weeks and weighing 20-22g. The animals were randomly allocated into two groups: group H-IR ($n = 6$) subjected to hepatectomy + ischemia/reperfusion; group H-IR-NAC ($n = 6$) pretreated with N-acetylcysteine (NAC) (150 mg/kg) and then hepatectomy+ischemia/reperfusion, as for the preceding

group.

Animal preparation consisted of ketamine and xylazine anesthesia (70 and 10 mg.kg⁻¹, respectively) intramuscularly, followed by a midline laparotomy and hydration with warm saline solution (3 mL. kg⁻¹. h⁻¹). Animals were kept over a heating pad during all experimental procedures.

The surgical procedures were performed as follows:

Ischemia/Reperfusion

Fifteen minutes after laparotomy, the hepatic hilum was occluded for 30 minutes with an atraumatic clip placed across it interrupting the blood supply, followed by 60 minutes of reperfusion.

Hepatectomy

During the occlusion, 30% of the liver (right lobes, caudate lobe and quadrate process) was excised, as previously described¹². NAC: animals from this group were treated with intravenous (IV) infusion of NAC (150 mg.kg⁻¹) through vena cava 15 minutes prior to the 30-minute ischemic period and 5 minutes before the 60 minutes of reperfusion.

After reperfusion, blood was drawn for biochemical analysis. Part of median liver lobes was removed and immediately fixed in 10% formaldehyde. Routine histological processes were employed for paraffin inclusion, sectioning and hematoxyline-eosine staining.

Histological aspects

The hepatic aspect was evaluated considering the presence of vascular congestion and fat infiltration, mitotic activity and binuclear nucleus within hepatocytes. The comparison of this last evaluation was made by counting cells with binuclear nucleus in 1000 hepatocytes per animal. Appropriate image capture was made using a light microscope (Axiolab Standart 20, Carl Zeiss, Jena, Germany) coupled to a video camera (AxionCam, Carl Zeiss, Jena, Germany).

Biochemical dosage

The sampled blood was centrifuged and the sera were used for aspartate aminotransferase (AST) and alanine aminotransferase (ALT) determinations, using Cobas Mira.

Statistical analysis

Nonparametric statistical tests were used to compare differences between experimental groups. Values are considered

significantly different for $p \leq 0.05$.

Results

The hepatectomy + ischemia/reperfusion group (H-IR) presented a preserved hepatic architecture. However, it was observed presence of vascular congestion, hepatocytes with cytoplasmatic light areas, indicating lipidic infiltration (Figure 1A). In hepatectomy + ischemia/reperfusion group treated with *N*-acetylcysteine (H-IR-NAC), liver parenchyma showed lower vascular congestion and hepatocytes with diminished cytoplasmatic light areas, and presence of several binucleated hepatocytes, some with large nucleus (Figure 1B). Also, NAC treatment improved the number of binucleated hepatocytes: H-IR= 7.402 ± 0.372 and H-IR-NAC= 15.88 ± 0.523 ($p < 0,001$) (Figure 2).

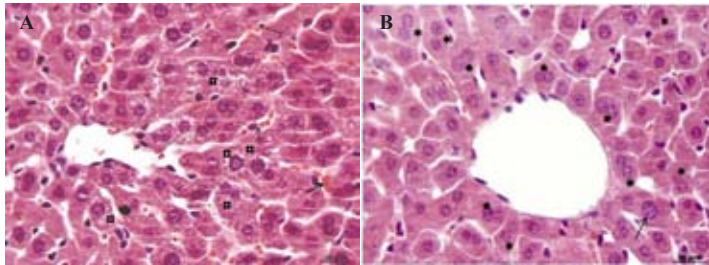


FIGURE 1 - Photomicrographs showing part of the mice liver lobes. **A.** From H-IR (Hepatectomy + ischemia / reperfusion) group. Notice hepatocytes with cytoplasmatic light areas (\square) and vascular congestion (arrow). **B.** From H-IR-NAC (Hepatectomy + ischemia / reperfusion treated with *N*-acetylcysteine) group. Notice large nucleus (arrow) and hepatocytes containing binuclear nucleus (*). H.E.

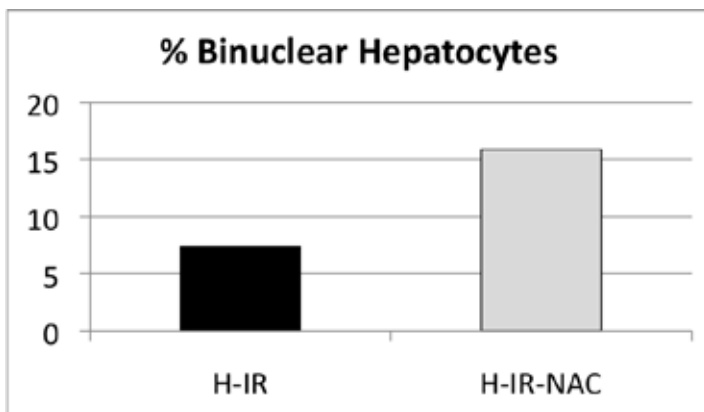


FIGURE 2 - Calculated percentage of binuclear hepatocytes ($p < 0.001$).

NAC treatment decreased both of the enzyme activities, but only ALT was statistically significant. ALT: H-IR= 636 ± 39.1 U/L and H-IR-NAC= 376 ± 127.3 U/L ($*p=0.023$) / AST: H-IR= 1259 ± 304 U/L and H-IR-NAC= 985 ± 347 U/L ($p=0.456$) (Figure 3).

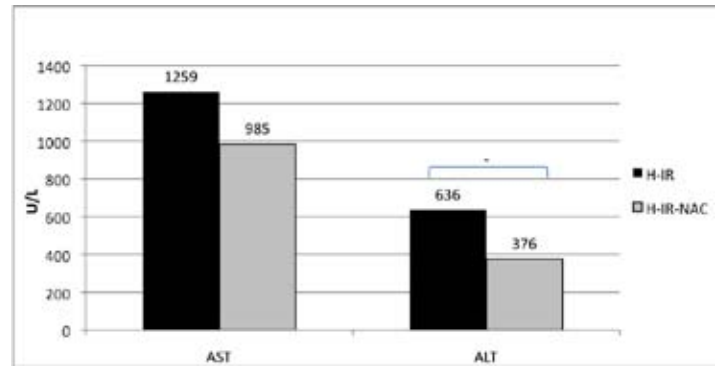


FIGURE 3 - Values of aspartate aminotransferase (AST; $p=0.456$) and alanine aminotransferase (ALT; $*p=0.023$) in both groups.

Discussion

There are numerous potential mechanisms of action by which NAC may exert protective effects¹³. But the interesting about this experiment was to see the enormous increase in binuclear hepatocytes, after use of NAC. Due to the liver fast metabolism, it is very common to appear polyploidy nucleus (having higher genetic load than normal), so more transcriptions happen. In our study, part of the liver was excised, leading to over function of the remaining hepatocytes. The increase in this short period of time (about two hours) is exciting, because *N*-acetylcysteine could not only protect but help in recovery.

James *et al.*¹⁴ observed that IL-6 was increased because of *N*-acetylcysteine in the liver tissue, denoting a mitogenic stimulus, as well. Glantzounis *et al.*¹⁸ showed that microcirculation and alanine aminotransferase activity were better when *N*-acetylcysteine was used, corroborating our findings related to vascular congestion in the parenchyma and ALT levels. It has been proposed that nitric oxide has an important role in the vascular congestion improvement induced by *N*-acetylcysteine¹⁵. Hogg *et al.*¹⁵ proposed a protective mechanism by low weight thiol, in which nitric oxide reacts with glutathione, improving the microcirculation, attenuating vascular congestion and tissue injury. Also ALT level was lower after NAC use. AST and ALT are useful screening tests for detecting liver injury. They are found in hepatocytes and cannot diffuse out of the cells in the physiological condition. When the hepatocyte is injured, plasma membrane can be disrupted and the leakage through extracellular fluid of the enzyme occurs where they can be detected at abnormal levels in the serum. So the ALT reduction could be the protection given by *N*-acetylcysteine as suggested previously¹⁴.

The ischemia-reperfusion lesion associated to liver transplantation can synergically compromise the organ after transplant. It is in this context that *N*-acetylcysteine, as protective

strategy, could minimize the lesion, promoting best functionality of the graft. Further experiments are currently under way to address this hypothesis.

Conclusion

The N-acetylcysteine promotes protection to the remnant liver after hepatectomy and ischemia-reperfusion in mice, based on biochemical and morphological analysis.

References

1. Sieders E, Peeters PM, TenVergert EM, Bijleveld CM, de Jong KP, Zwaveling JH, Boersma GA, Slooff MJ. Analysis of survival and morbidity after pediatric liver transplantation with full-size and technical-variant grafts. *Transplantation*. 1999; 68(4):540-5.
2. Meneu-Diaz JC, Moreno-Gonzalez E, Garcia I, Moreno-Elola A, Perez Saborido B, Fundora Suarez Y, Jimenez-Galanes S, Olivares S, Hidalgo Pascual M, Abradelo M, Jimenez C. Starting a new program of split liver transplantation after a low learning curve: a reality in centers with large experience in liver surgery and whole liver transplantation. *Hepatogastroenterology*. 2008;55(86-87):1699-704.
3. Breitenstein S, Apestegui C, Petrowsky H, Clavien PA. "State of the art" in liver resection and living donor liver transplantation: a worldwide survey of 100 liver centers. *World J Surg*. 2009;33(4):797-803.
4. Troisi R, Cammu G, Militerno G, De Baerdemaeker L, Decruyenaere J, Hoste E, Smeets P, Colle I, Van Vlierberghe H, Petrovic M, Voet D, Mortier E, Hesse UJ, de Hemptinne B. Modulation of portal graft inflow: a necessity in adult living-donor liver transplantation? *Ann Surg*. 2003;237:429-36.
5. Nagel E, Vilsendorf AM, Bartels M, Pilchmary R. Antioxidative vitamins in prevention of ischemia/reperfusion injury. *Int J Vitam Nutr Res*. 1997;67(5):298-306.
6. Rhoden EL, Mauri M, Petteffi, L, Belo-Klein A, Kalil AA, Pereira-Lima L, Rhoden CR. Mortality rate in rats submitted to hepatic ischemia-reperfusion, treated or not with allopurinol. *Acta Cir Bras*. 1999;14(4):166-70.
7. Nakano H, Boudjema K, Alexandre E, Imbs P, Chenard MP, Wolf P, Cinqualbre J, Jaeck D. Protective effects of N-acetylcysteine on hypothermic ischemia-reperfusion injury of rat liver. *Hepatology*. 1995;22(2):539-45.
8. Portella AO, Montero EF, Poli de Figueiredo LF, Bueno AS, Thurow AA, Rodrigues FG. Effects of N-acetylcysteine in hepatic ischemia-reperfusion injury during hemorrhagic shock. *Transplant Proc*. 2004;36(4):846-8.
9. Galhardo MA, Quireze C Jr, Navarro PGR, Morello RJ, Simões MJ, Montero EFS. Liver and lung late alterations following hepatic reperfusion associated to ischemic preconditioning or N-acetylcysteine. *Microsurgery*. 2007;27(4):295-9.
10. Castro AP, Castro Jr MAM; Lauz S, Facin E, Simões MJ, Fagundes DJ. The role of N-acetyl-cysteine in the lung remote injury after hepatic ischemia and reperfusion in rabbits. *Acta Cir Bras*. 2012;27(1):49-55.
11. Vivot C, Stump DD, Schwartz ME, Theise ND, Miller CM. N-acetylcysteine attenuates cold ischemia/reperfusion injury in the isolated perfused rat liver. *Transplant Proc*. 1993;25:1983-8.
12. Yadav SS, Gao W, Harland RC, Clavien PA. A new and simple

technique of total hepatic ischemia in mouse. *Transplantation*. 1998;65:1433-6.

13. McKay A, Cassidy D, Sutherland F, Dixon E. Clinical results of N-acetylcysteine after major hepatic surgery: a review. *J Hepatobiliary Pancreat Surg*. 2008;15:473-8.
14. James LP, McCullough SS, Lamps LW, Hinson JA. Effect of N-acetylcysteine on acetaminophen toxicity in mice: relationship to reactive nitrogen and cytokine formation. *Toxicol Sci*. 2003;75(2):458-67.
15. Hogg N, Singh RJ, Kalyanaraman B. The role of glutathione in the transport and catabolism of nitric oxide. *FESB Lett*. 1996;382:223-8

Correspondence:

Edna Frasson de Souza Montero
Alameda Espada, 134/ Res. Onze
06540-395 Santana de Parnaíba – São Paulo Brasil
edna.montero@gmail.com

Received: November 17, 2011

Review: January 18, 2012

Accepted: February 15, 2012

Conflict of interest: none

Financial source: National Council for Scientific and Technological Development (CNPq)

¹Research performed at Department of Surgery, Division of Operative Technique and Experimental Surgery, Federal University of Sao Paulo (UNIFESP), Brazil.