

Immediate graft histological assay, post pig's liver transplantation¹

Marcus Vinicius Henriques Brito^I, Marialva Tereza Ferreira de Araújo^{II}, Luane Cristine Batista Cunha^{III}, Antônio Jorge Barbosa de Oliveira^{IV}, Jacqueline Barreto Rodrigues^{IV}, Nathalya Botelho Brito^{IV}

^IPhD, Full Professor, Head of the Department of Integrate Health, Medical School, Para State University (UEPA), Brazil. Conception and design of the study, surgical procedures, analysis of data, manuscript writing.

^{II}Associate Professor, Morph physiology Department, UFPA, Belem-PA, Brazil. Histopathological examinations, critical revision.

^{III}MD, Resident, Joao de Barros Barreto, University Hospital, Belem-PA, Brazil. Technical procedures, acquisition and interpretation of data.

^{IV}Graduate students, Medical School, UEPA, Belem-PA, Brazil. Grants from Institutional Program for Scientific Initiation (PIBIC) of the National Council of Technological and Scientific Development (CNPq), Ministry of Science, Technology and Innovation, Technical procedures.

ABSTRACT

PURPOSE: To describe the vascular and tissue histopathological changes in seven sequential experimental liver transplantations in pigs.

METHODS: Fourteen female pigs, *Sus domesticus* species, with body mass between 5 and 8 kg were utilized. After the end of all anastomoses of the graft implantation in the receptor, the animal was monitored for 30 minutes, and at its end one of the biopsies was collected for histological analysis. The histological criteria utilized were: lytic hepatocyte necrosis, density of septal and portal inflammatory infiltrated, sinusoidal congestion and hemorrhage. The analysis was performed separately for the portal region in zone 1, 2 and 3.

RESULTS: Among the structural changes undergone by the graft, those with greater frequency and intensity were vascular congestion and steatosis, which stood out in transplantations 5, 6 and 7.

CONCLUSIONS: The technique demonstrated vascular alterations represented by vasocongestion, edema and minimum inflammatory reaction. In relation to the parenchyma, was observed macrovacuolar pan-acinar steatosis, focal lytic and occasional hemorrhages, beyond the accumulation of hemosiderin in Kupffer's cells.

Key words: Liver Transplantation. Histology. Swine.

Introduction

Liver transplantation is indicated when the perspective of survival, resulting from the liver disease is less than one year, without clinical or surgical alternatives of treatment which is not the transplantation that has presented a global rate of survival of about 80% in three years^{1,2}. Brazil has been offering the procedure free by Health Public System (SUS), being the second country in the world in realized transplantations a year by the public system, making possible to investigate the effect of socio-economical inequalities on the transplantation result³. Ophir Loyola Hospital, in Belem, has had the service of collecting livers since 2007 and is awaiting permission to hold the graft⁴.

The training of anesthetic-surgical teams through experimental surgeries in animals has been considered a fundamental step before its clinical application because of the technical complexity involved in liver transplantation^{5,6}. Haschek *et al.*⁶ complemented that a pig is an useful model for studies in biomedical research, once it presents similarities to humans in structure and functions^{7,8}.

On histology, liver is divided into lobules with portal areas at the periphery and the central lobule vein. However, in terms of physiology, is organized into acini with arterial or portal flow to enter in the acini in the portal/periportal areas⁷. The hepatocytes of these areas constitute "zone 1" of the lobes, which is the most irrigated area, giving it more resistance to face a circulatory disturb, a greater regeneration capacity and also a greater number of enzymes to perform oxidative metabolism. The hepatocytes of the intermediate zone 2, express a mixed enzyme pattern between zones 1 and 3. Finally the ones which are adjacent to central veins (pericentral) form the third zone, that is less irrigated and therefore present lower concentration of nutrients and oxygen. This is the reason that they express enzymes targeted to a chemical and anaerobic metabolism, more susceptible to ischemia injury and having a lower regenerative capacity⁹.

The scarceness of papers describing liver transplantation in pigs and the analysis of the histopathological configuration have justified the realization of this research, which aims to analyze the histological structure immediately after graft liver transplantation in pigs, in order to corroborate to the training and improvement of the technique aiming not only to extend the anatomical knowledge and the experience, but also decreasing, this way, the incidence of surgery complications.

Methods

The Ethical Committee on Research of the State University of Para approved this experiment (protocol n. 02/2009). The handling of all animals used during this research was done according to the Brazilian regulations in force for animal vivisection (Federal Law 11.794, 2008) and the norms of the Brazilian College for Animal Experimentation.

Fourteen female pigs specie *Sus domesticus* were utilized for studying the technique of liver transplantation, with body mass between 5 and 8 Kg. The animals were allocated in appropriate vivarium with individual fences measuring 150cm x 150cm, cemented floor, water *ad libitum*, being offered 500g of ration daily, environmental temperature and natural light. Besides, a technician in vivarium carried out the sanitization of the cages daily. There was pre-surgery fasting of 24h.

All utilized techniques for collecting the graft, implantation and its complications, were carried out according to the description by Brito *et al.*¹⁰⁻¹².

Fragments measuring 5/5 mm were collected with the liver still in the donor animal, directed to histological analysis to the graft transplantation itself, for serving as a normal pattern model of a pig liver.

In the receptor, thirty minutes after the reperfusion, new fragments of liver measuring 5/5 mm were collected with the animal still alive, also conducted to histological analysis, being each piece singly identified. The material was fixed in formaldehyde of 10%, prepared by standard technique and stained by Hematoxilin-Eosin, Gomori Tricomoc and Perls' techniques. The blades were numbered according to the number of the animal and the transplantation and evaluated the main points observed in the pilot project: presence of cellular infiltrated and eosinophilous, vascular congestion, edema, hemorrhage, and the presence of pigments of hemosiderin, steatosis and lytic necrosis.

The utilized histological criteria were: hepatocyte lytic necrosis, density of portal and septal infiltrated inflammatory, sinusoidal congestion and hemorrhage. Each item was graduated from 1 to 3 crosses, in the following way: 1-Mild, 2-Moderate and 3-Strong.

The analysis of all parameters mentioned above was realized in the portal region, zone 1, zone 2 and zone 3 of the liver lobule.

For making possible the statistic analysis of the findings, coming from histological blades, the following values were considered:

Absent: Numeric value 1.

Mild (+): Numeric value 2.

Moderate (++) : Numeric value 3.

Strong (+++) : Numeric value 4.

After collecting histological and biochemical material, the euthanasia was carried out with an injection of 50 ml of KCl 10% EV. The carcass was discarded in biological trash involved in a hospital plastic bag.

The statistic study of the obtained results was realized in the Bio-statistic Department of UEPA. According to the nature of variables, the comparative statistic analysis was applied and utilized ANOVA non-parametrical tests with Bonferroni's correction. In all tests, the rate of hypothesis rejection of nullity was fixed in 0.05 or 5% ($\alpha \leq 5\%$), being the significant values assigned with an asterisk (*).

Results

Vascular congestion is observed in histological blades of liver transplantations in pigs. Zones 1 and 2, closer to the portal areas, showed a difference significant after reperfusion post-transplantation (Figure 1).

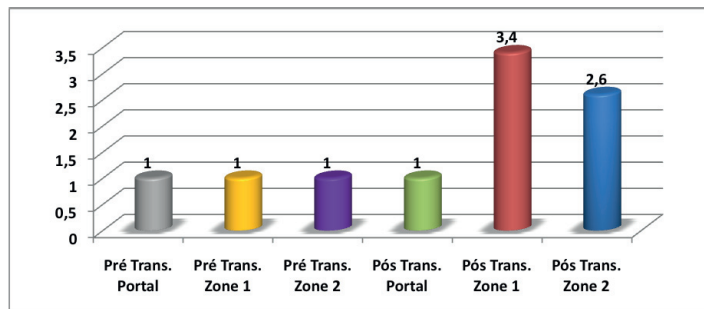


FIGURE 1 – Vascular congestion observed in histological blades of liver transplantations in pigs realized in LES 2009. Zones 1 and 2, closer to the portal areas, showed an acute vascular congestion after reperfusion post-transplantation. $p < 0.05$ (ANOVA x Bonferroni).

About tissue histopathological changes in post transplantation period was observed acute steatosis in proximal zones to the portal areas, caused by reperfusion post-transplantation (Figure 2), as so as lytic necrosis and hemorrhage (Figure 3.1), portal edema (Figure 3.2), steatosis and congestion (Figure 3.3), inflammatory infiltrated (Figure 3.4) and hemosiderin deposit (Figure 3.5).

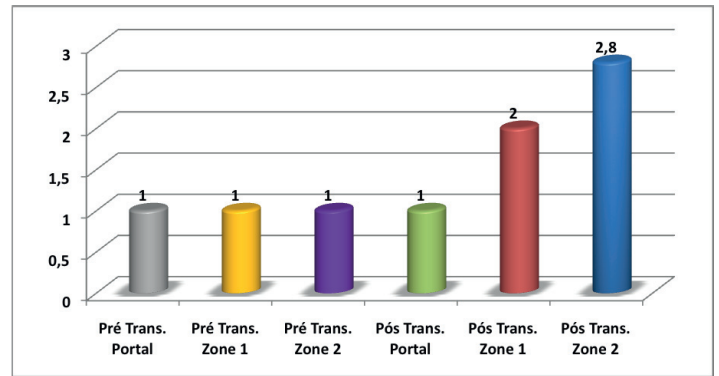


FIGURE 2 - Steatosis observed in histological blades of liver transplantations in pigs realized in LES 2009. There was an acute steatosis in proximal zones to the portal areas caused by reperfusion post-transplantation. $p < 0.05$ (ANOVA x Bonferroni).

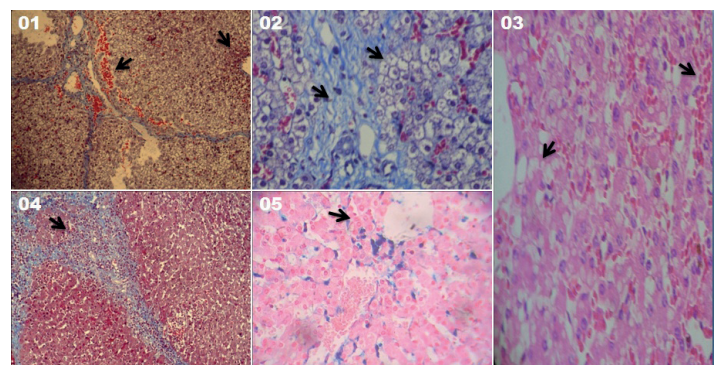


FIGURE 3 - Hepatic parenchyma post-transplantantion. 1) Lytic necrosis and hemorrhage. 2) Portal edema. 3) Steatosis and congestion. 4) Inflammatory infiltrated. 5) Hemosiderin deposit.

Discussion

A sample of pigs was utilized, being chosen as experimental model due to their anatomic and liver similarities to men as well as dogs; however, pigs are less subjected to ethics restrictions than dogs^{5,13}. After the end of all anastomoses of graft implantation, the animal was monitored for 30 minutes, and by the end, the other biopsy collected to analysis evaluating the feasibility of the graft and study of histological alterations after 30 minutes of the re-vascularization of the graft was performed.

In the post-transplantation analysis we observed different alterations. In sample number 1, was observed acute sinusoidal vasocongestion, portal and lobular, predominating in zone 1. In the portal space we observed a discreet edema, with scarce lymphocytes and congested vessels. Moreover, observed diffuse pan-acinar steatosis of moderate intensity in zone 2.

In transplantation 2 observed mild sinusoidal congestion, edema and inflammatory infiltrated with lymphocytes, also scarce in the portal space. Hepatocyte beams were preserved, with

vacuolated hepatocytes in several areas, characterizing diffuse pan-acinar steatosis with intensity varying from mild to moderate. In addition, there were foci of periportal hemorrhage, with an extension to the sept. In this area, there was lytic necrosis of the hepatocyte with the presence of inflammatory parenchymatous infiltrated and lymphocyte portal. Was also observed the presence of eosinophilic infiltrated, what may represent a reaction of local incompatibility due to halogen antigen, probably coming through the blood transfusion.

In these two animals, still observed the presence of several brownish pigments suggesting hemosiderin in the portal space and Kuppfer's cells being realized for the confirmation of Perls' staining. This finding is probably related to the transfusion that was realized in these animals, which may have caused lysis of hematias, releasing ferritin that spilled by sinusoids, being the phagocyte by Kuppfer's cells, once one of the causes of excessive destruction of hematias was blood transfusion¹⁴.

Similar results were observed in samples 3 and 4.

In relation to transplantations 5, 6 and 7, there were similar findings in transplantations 5 and 6 and a little difference in 7. In samples number 5 and 6, the polygonal architecture was without alterations in the sinusoid, but with vasocongestion from moderate to strong, predominating in the periportal zone. In the portal space a discreet edema was observed, vasocongestion and scarce lymphocytes, characterizing mild inflammatory reaction, with little significance.

The hepatocytes presented a vacuolated aspect, with transparent macro and micro-vacuoles, characterizing diffuse macro-vacuolar pan-acinar steatosis. There was absence of necrosis, hemorrhage and Kuppfer's cells in normal aspect, without evidencing hemosiderin pigments.

In the blades of transplantation number 7 occurred varied vasocongestion sinusoids, quite mild, with predominance in zone 1, however, with some lobules, inadequate perfusion areas were present. This finding may be explained by the occurrence of malignance hyperthermia with three heart vascular failures, reverted during the procedure. This alteration provides the deviation of blood flow to other organs as brain, heart and kidneys. In hepatocytes, observed scarce diffuse macro-vacuolar pan-acinar steatosis with little hemorrhage foci and lytic necrosis surrounding the hemorrhagic region, as well as the hemosiderin pigment in this zone without eosinophilic reaction.

Among the structural modifications suffered by the graft, the ones that most called attention were the vasocongestion and the steatosis, both representing cellular adaptations to hypoxia, which the graft was submitted to, as well as surgical and oxidative stress,

as explained by Andrade Junior *et al.*¹⁵ in their research with rats.

After a period of ischemia, at the moment of the re-perfusion, there was the formation of free radicals and the activation of natural anti-oxidant mechanisms occurring simultaneously. If the product of this reaction tends to the excess of free radicals, oxidative phenomena will occur resulting in the lipid peroxidation of the cellular membrane¹⁶, what may explain the occurrence of steatosis, thus, observed in the histological analysis.

The releasing of hormones as adrenaline or growth hormone, as anoxic causes, provoked a decrease in the oxygen provision, diminishing the oxidation capacity of fatty acids and the energy supply, necessary for the protein synthesis of the hepatocyte¹⁵. The fatty degeneration is considered reversible if the causes are removed. In general, the fatty degeneration is a common and non-specific indication of cellular aggression coming from several etiologies, although the location and the circumstance in which the lesion occurs may suggest a pathogenic mechanism or a specific disease.

The vascular congestion represents an immediate adaptation to the hypoxia that the graft is submitted to stages of hot and cold ischemia, as intense vasoactive substances resulting from surgical stress.

The ischemia imposed by the deprivation of nutrients and deficiency of drainage determines varied levels of tissue lesion, until liquefied necrosis. The softening and lysis of the necrotic tissue is due to enzymes released by the dead tissue, by inflammatory cells or a casual agent, favored by the structure and constitution of the tissue¹⁵.

The observed lesions differed from the classical alterations observed in the syndrome of ischemia and re-perfusion, what could be explained by the brief period of the adopted re-vascularization, once this study intended to evaluate the acute lesions presented by the graft. In studies with great time of ischemia, as by Lasi *et al.*¹⁶, that utilized dogs as models and the solution of preservation by Collins, collecting biopsies during the procedure and 2 hours after the re-vascularization, the diffuse bleeding, hydropic degeneration, edema interstitial and the necrosis of coagulation could be, then, observed.

In the study by Castro *et al.*¹⁷ liver post-transplantation biopsies were realized immediately after the re-perfusion of the organ (time zero), on the 7th and 15th day of post-transplantation. In this research was described that, at time zero, liver biopsies presented as the most frequent lesions: hydropic degeneration of hepatocytes, macro steatosis and micro-vacuolar, intra-lobular aggregated of neutrophilus, focal hepatocellular necrosis and intra-cytoplasm cholestasis. It is possible that these alterations could be

developed since the donor's agonistic stage until the moment of organ implantation and reperfusion.

The hydropic degeneration, the microvesicular steatosis and the cholestasis are denominated lesions of preservation ("harvesting" type). They usually result from ischemia that the liver is submitted to, however, other factors as the utilized drugs and toxins may also cause them. The intra-lobular aggregated and portals of neutrophils observed in 77.08% of the biopsies were attributed to the organ manipulation during the procedure, being this alteration denominated "surgical hepatitis"^{17,18}.

Several observed findings, in great part, occurred in this initial stage, which only intended to establish technical adaptations in the experimental transplantation in pigs, caused by the utilization of saline as a preservation solution, what, as known, provides an increase of lesions in the stage of post-ischemia reperfusion. We suggest further researchers which may accomplish improvements in intra-surgical conditions, as the utilization of other solutions of preservation in order to minimize the effects of the process of ischemia, techniques with greater agility in the realization of the procedures, especially in producing anastomoses, as we could collect biopsies from several liver regions, therefore evaluating, more precisely, the blood afflux in all parenchyma.

Conclusions

The technique described demonstrated to be feasible and effective for the histological analysis. Vascular alterations were represented by vasocongestion, edema and minimum inflammatory reaction. In relation to the parenchyma, we could observe macro vacuolar pan-acinar steatosis, lytic and occasional hemorrhages, the accumulation of hemosiderin in Kupffer's cells, and eosinophilic infiltrated surrounding the necrotic and portal lesion.

References

1. Castro-e-Silva Junior O. Transplante de fígado: indicação e sobrevida. *Acta Cir Bras.* 2002;17:83-91.
2. Martín TA. Trasplante hepático en el Perú y en el mundo. *Diagnóstico (Perú).* 2011;50:173-4.
3. Oliveira DMS, Drachler ML, Oliveira LS. Fatores de risco para a falência do transplante ortotópico de fígado no Rio Grande do Sul, Brasil. *Cad Saúde Pública.* 2007;23:187-95.
4. Pará. Portaria nº 701 de 02 de dezembro de 2005. Dispõe sobre a criação do serviço de transplante de fígado. *Diário Oficial do Estado do Pará.* Disponível em: http://www.ioepa.com.br/novo/includes/mostramateria.asp?ID_materia=49865&ID_tipo=21 > acesso em: 15.03.2013.
5. Torres OJM, Servin TN, Servin SCN, Valadão JA, Gomes TRV, Salgado Filho N. Transplante hepático ortotópico experimental em

- suínos: resultados iniciais. *J Bras Transpl.* 2005;8:305-8.
6. David AI, Chida VV, Lee ADW, Fiuza FSOR, Calil DM, Mantovani DC, Maranhão ER, Campi GB, Llanos JC, Ferraz Neto BH. Multivisceral transplantation in pigs: a model for research and training. *Einstein (São Paulo).* 2011;9:372-6.
7. Vale-Echeto OE, Vásques DP, Camacho Bracho JE, Vale-Oviedo OR, Oviedo de Vale MG. Pathological anatomy study of a hemorrhagic disease in four (4) pigs. *Rev Cient (Maracaibo).* 2008;18:28-34.
8. Fagundes DJ, Taha MO. Modelo animal de doença: critérios de escolha e espécies de animais de uso corrente. *Acta Cir Bras.* 2004;19:59-65.
9. Nagato AC, Silva MAS, Trajano ETL, Alves JN, Bandeira ACB, Ferreira TA, Valença SS, Bezerra FS. Quantitative and morphological analyses of different types of human liver. *Braz J Morphol Sci.* 2011;28(4):275-9.
10. Brito MVH, Cunha LCB, Oliveira AJB, Sabba MF, Rodrigues JB, Soares LPMA. Immediate intra and post-surgery complications of the orthotopic liver transplantation in pigs. *Rev Para Med.* 2009;23:7-12.
11. Brito MVH, Cunha LCB, Soares LPMA, Sousa AAVO, Brito NB, Miyagawa EK. Descrição dos procedimentos de implante de enxerto hepático total no transplante ortotópico em suínos. *J Bras Transplant.* 2010;13:1221-75.
12. Brito MVH, Cunha LCB, Sousa AAVO, Brito NB, Vera MO. Descrição de técnica anestésica no transplante hepático ortotópico em suínos. *Rev Para Med.* 2013;27:7-10.
13. Manzanero AA. Biological desing. *Rev Venez Cir.* 2011;64:34-5.
14. Sala MA. Lesão celular - degeneração, necroses, apoptoses, pigmentos, degeneração. *Ribeirão Preto, 2006.* Disponível em <http://www.forp.usp.br/mef/digipato/lesao.do>
15. Andrade Júnior DR, Andrade DR, Santos AS. Study of rat hepatocytes in primary culture submitted to hypoxia and reoxygenation: action of the cytoprotectors prostaglandin E1, superoxide dismutase, allopurinol and verapamil. *Arq Gastroenterol.* 2009;46:333-40.
16. Lasi M, Uvo RAB, Fávero SSG, Szutan LA, Assef, JC, Araujo MF, Percario S, Felipe Junior J, Capua Junior A, Mastroti RA. Transplante hepático: avaliação do estresse oxidativo e das alterações histopatológicas na detecção de lesão celular, em preservação de 24 horas (estudo experimental em cães). *J Biomolec Med Free Rad.* 1996;2:55-9.
17. Castro AF, Castro LPF, Leite VHR, Paulino Junior E, Lima AS, Gazzola L, Toppa, NH. Achados histológicos em 48 pacientes transplantados do fígado: biópsias do enxerto pós-reperusão (tempo zero) e de três a 15 dias pós-transplante. *J Bras Patol Med Lab.* 2002;38:301-6.
18. Torres OJM, Pantoja PB, Barbosa ES, Barros CA, Servin ETN, Servin SCN. Hemodynamics alterations during orthotopic liver experimental transplantation in pigs. *Acta Cir Bras.* 2008;23(2):135-9.

Correspondence:

Marcus Vinicius Henriques Brito
Rua Apinagés, 630/202
66.033-170 Belém – PA Brasil
Tel.: (55 91)3222-9752/8854-8895
marcusvhbrito@gmail.com

Received: May 14, 2013

Review: July 16, 2013

Accepted: Aug 19, 2013

Conflict of interest: none

Financial source: National Council of Scientific and Technological Development (CNPq)

¹Research performed at Laboratory of Experimental Surgery, Para State University (UEPA), Belem-PA, Brazil.