



The effects of subcutaneous injection of nicotine on osseointegration of machined and anodized implants in rabbits¹

Maria Salete Sandini Linden^I, Marcos Eugênio de Bittencourt^{II}, João Paulo De Carli^{III}, Daniela Cristina Miyagaki^{IV}, Pâmela Letícia dos Santos^V, Luiz Renato Paranhos^{VI}, Francisco Carlos Groppo^{VII}, Juliana Cama Ramacciato^{VIII}

^IPhD, Full Professor, Department of Dentistry, Universidade de Passo Fundo (UPF), RS, Brazil. Acquisition, analysis and interpretation of data; manuscript writing; final approval.

^{II}PhD, Full Professor, Department of Dentistry, UPF, Passo Fundo-RS, Brazil. Statistical analysis, final approval.

^{III}PhD, Associate Professor, Department of Dentistry, Passo Fundo-RS, Brazil. Statistical analysis, manuscript preparation, final approval.

^{IV}PhD, Associate Professor, Department of Dentistry, Passo Fundo-RS, Brazil. Acquisition of data, manuscript preparation, final approval.

^VPhD, Associate Professor, Department of Health Sciences, University of Araraquara (UNIARA), Araraquara-SP, Brazil. Manuscript preparation and writing, critical revision, final approval.

^{VI}PhD, Associate Professor, Department of Dentistry, Universidade Federal de Sergipe (UFSE), Lagarto-SE, Brazil. Manuscript preparation, critical revision, final approval.

^{VII}PhD, Full Professor, Department of Physiological Sciences, Universidade Estadual de Campinas (UNICAMP), Brazil. Conception and design of the study, final approval.

^{VIII}PhD, Associate Professor, Department of Dentistry, Faculdade São Leopoldo Mandic, Campinas-SP, Brazil. Conception and design of the study, final approval.

Abstract

Purpose: To evaluate the influence of subcutaneous injection nicotine in osseointegration process on different implant surfaces.

Methods: Twenty-two male rabbits were distributed into two groups according to the subcutaneous injections: (1) nicotine 3 mg/day/kg and (2) 0.9 % NaCl 3 mL/day/kg, three times a day; subgroups were then designated-machined and anodized implants were placed in the right and left tibia bones, respectively. The animals were submitted euthanasia after periods of eight weeks to determine nicotine and cotinine levels, alkaline phosphatase and biomechanical analysis.

Results: The plasmatic levels of nicotine and cotinine were 0.5 ± 0.28 ng/mL and 9.5 ± 6.51 ng/mL, respectively. The alkaline phosphatase analyses in blood levels in control group were observed 40.8 ± 11.88 UI/L and 40.75 ± 12.46 UI/L, for the surfaces machined and anodized, respectively. In the test group was observed levels 37.9 ± 4.84 UI/L, for both implant surfaces. No significant differences were observed between control and test groups and between the implant surfaces regarding alkaline phosphatase blood levels. For biomechanics, no significant differences were observed in control group between the machined (25 ± 8.46 Ncm) or anodized (31.2 ± 6.76 Ncm) implants. However, the treatment with nicotine induced higher torque than control in both machined (38.3 ± 13.52 Ncm) and anodized (35.5 ± 14.17 Ncm) implants, with $p = 0.0024$ and $p = 0.0121$, respectively.

Conclusion: Subcutaneous injection of nicotine following implant insertion didn't have effect on osseointegration, independently from the implant surface.

Key words: Bone-Implant Interface. Dental Implants. Nicotine. Osseointegration. Rabbits.

■ Introduction

Failure to achieve osseointegration of dental implants has been related to several factors, such as poor bone quality and smoking. The addictive element in tobacco, nicotine, has been shown to be of the highest importance when understanding the negative effects of smoking on bones¹. The specific mechanism of action that nicotine plays specifically on the activity of osteoblasts and osteoclasts is still unknown. Studies have isolated nicotine as their exposure agent and assessed its effect of dental implants have found no significant difference in osseointegration between animals with or without exposure to nicotine². Therefore, it is hypothesized that nicotine, by itself is not able to interfere with the bone healing around titanium implants.

Nicotine interferes in the wound healing by causing direct cutaneous vasoconstriction, increasing levels of fibrinogen, hemoglobin and blood viscosity, impairing cellular protein synthesis and the adherence of gingival fibroblasts³. It has been also demonstrated that nicotine may have beneficial anti-inflammatory effects, which may reduce the symptoms of other systemic inflammatory diseases, such as ulcerative colitis⁴.

One possible solution to smoker patients could be changing the dental implant surface, in order to enhance bone response and thus, improve the clinical success rate. The use of implants with microtopography changed surface could benefit patients with risk factors such as smoking⁵⁻⁶. Results of clinical studies with short-length and machined-polished dental implants (Branemark® Type) showed that failure rates were higher, particularly when the implants were inserted into trabecular bone⁷. For this reason, implants with a rough structure are now preferred and Branemark® implants have also been modified to include a rough surface (Ti-Unite® Surface). Albrektsson

and Wennerberg⁸ asserted that “moderately rough” implants (for example, 1.0 – 2.0 µm) tend to show better clinical results than the machined type.

Surface-modified implants, obtained with additive and subtractive techniques, such as oxidizing, airborne particle abrasion, acid etching and combinations of these techniques have been developed⁹. According to Zhu *et al.*¹⁰ modified surfaces improve biocompatibility, increase cellular adhesion and proliferation. Studies by Rocci *et al.*⁵ and Bahat¹¹ have indicated that modifications of the surface and macro design of the implant are particularly important for its longevity.

Previous reports have demonstrated that a higher and faster extension of bone formation occurs more on oxidized implants than on machined implant surfaces, when measured with removal torque tests and histomorphometry¹². Albrektsson *et al.*¹³ found that oxidized titanium implants showed more bone-implant contact than in the anodized implants and higher removal torque values than in machined implants after 6 weeks in New Zealand white rabbits.

The present study observed the effect of low dose of nicotine in osseointegration of two implants of the same design, with two different types of surface topographies, i.e., machined and oxidized surfaces.

■ Methods

The study was reviewed and approved by the Ethics Committee of Universidade de Passo Fundo (#535/2006).

Twenty-two (n = 44 tibia) adult male New Zealand white rabbits (*Oryctolagus cuniculus*) weighing 3.5 to 4.0 kg, aged 8 to 10 months were used. All rabbits were housed in animal facilities at 25 °C, in 12-hour light: dark cycles. Throughout the experimental period, the rabbits were housed in individual plastic

cages, and a normal chow diet and water were provided ad libitum.

The animals were randomly distributed into two groups: * Control Group – animals received subcutaneous injection of 0.9 % NaCl mL/Kg/day, (Sodium chloride 0.9 %®, Darrow, Rio de Janeiro, RJ, Brazil) three times a day (n = 22). *Test Group - animals received subcutaneous injections of nicotine (nicotine

hydrogen tartrate salt 98 %, Sigma-Aldrich, Copenhagen, Denmark A/S) 3 mg/kg/day, three times a day (n = 22). Nicotine and SF injections were made until the end of the 8-week after surgical procedure.¹⁴ These were then each divided into two subgroups – machined and anodized dental implants – corresponding to dental implant used, respectively (Figure 1).

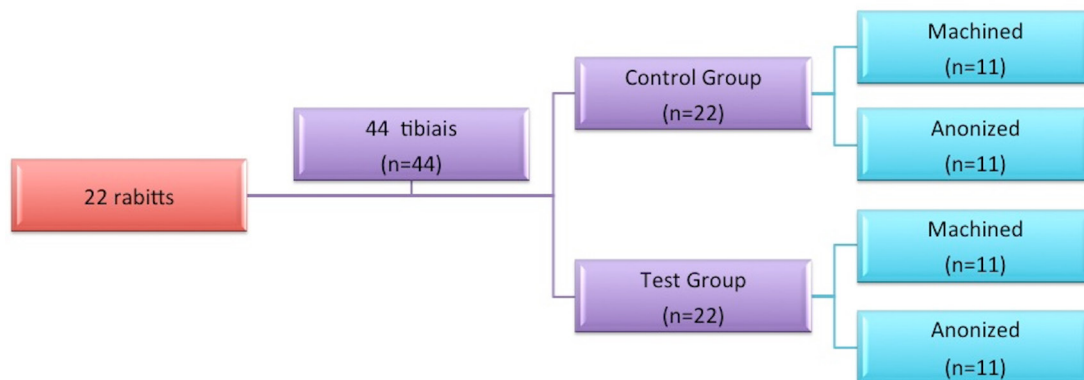


Figure 1 - Flowchart for exemplification of groups division.

Surgical procedure

The animals received atropine (0.50 mg – 0.44 mg/kg/i.p.) (Sulfato de Antropina 0,5 %, Labovet, Feira de Santana, BA, Brazil) 15 minutes before surgery. General anesthesia was administered by an intramuscular injection of 2 % xylazine hydrochloride 5 mg/kg (Rompun, Bayer AS, Saúde Animal, SP, Brazil) and ketamine hydrochloride at a concentration of 50 mg/kg (Francotar; Vibrac do Brasil Ltda., SP, Brazil).

Experimental surgery for implant placement was performed as previously described¹⁵⁻¹⁶. Then, the trichotomy was performed on the tibia of the rabbits, removing all the hairs from the area to be operated. Followed by the antisepsis of the region with the use of gauze soaked in iodine solution (PVPI

10%, Riodeine Degermante, Rio de Janeiro-RJ, Brazil) with the topic PVP-I (PVP-I topico®, Riodeine Degermante, Rioquímica, São José do Rio Preto-SP, Brazil). The local anesthesia by infiltrative injection with mepivacaine 2 % (0.3 mL/kg, Scandicaine 2 %® with adrenalin 1:100.000, Septodont, Paris, France).

A careful surgical technique was performed with an incision 3.0 cm in length was made on the proximal tibia just below the knee to the depth of the bone tissue. The soft tissue was carefully dissected and lifted with the aid of a periosteal elevator (Quinelato®, Rio Claro, São Paulo, Brazil), exposing the bone tissue for implant insertion. After pre-threading of receptor site, the implants were inserted in each proximal metaphysis, under 40 N of torque.

One machined-surface (Master Screw®,

Conexão Sistemas de Prótese, Arujá-SP, Brazil), in the right and one anodized-surface implant (Master Vulcano Actives®, Conexão Sistemas de Prótese, Arujá-SP, Brazil) in left tibia were placed of each animal. Both implants were 3.75 mm in diameter, 6.0 mm long and screw-shaped with external-hexagon (ASTM grade 4). Soft tissues were replaced and sutured with monofilament wire (Nylon 5.0®, Ethicon, Johnson, São José dos Campos-SP, Brazil).

After the suturing were realized intramuscular pentabiotic (0.1 mL/kg, Fort Dodge Saúde Animal Ltda, SP, Brazil) immediately and via oral at 5 days postoperatively. Sodic dipyrone (1 mg/kg/day, Ariston Indústrias Químicas e Farmacêuticas Ltda, São Paulo-SP, Brazil) was also administered, via oral. Neither food or movement restriction was applied to the animals that remained in individual cages during the experimental period. All rabbits were euthanized by a lethal dose of pentobarbital (200 mg/kg) at 8 weeks after surgery.

Alkaline phosphatase analyses and nicotine/cotinine detection and quantification

Blood samples (10 ml) were obtained from jugular vein and used to dose alkaline phosphatase, nicotine and cotinine serum levels, after eight weeks of surgery. Alkaline phosphatase activity was colorimetrically obtained by automated laboratory techniques using p-nitrophenilphosphate as substrate.

The major nicotine metabolite – cotinine – was detected and quantified by Gas Chromatography – Flame Ionization detector (CG/FID, Chromatographer HP 5890 II, Capillary Column BP 624 – 30 m) after solid phase extraction (SPE, Varian HF Bond Elut LRC Certify).

Cotinine (98 % purity (-) - Cotinine, Sigma) was used as analytical standard. The method sensitivity was 0.1 ng/mL.

Biomechanical analysis - Removal torque measurement

After the euthanized of the animals in eight weeks after surgery, the implants were carefully exposed. A reverse torque rotation force was applied to the osseointegrated implants, using a torque gauge (TQ 680, Digital/Portable - C/R S-232, Instrutherm Measurement Instruments Ltda), until rotation was detected. Peak values of resistance to reverse torque rotation were recorded in N.cm when rupture occurred between the implant and bone.

Statistical analysis

Alkaline phosphatase in each group was compared by Mann-Whitney's test. Kruskal-Wallis's and Dunn's test were used to analyze the removal torque. Pearson's correlation test was used to observe the relationship among removal torque and cotinine levels. The significance level considered for the tests was 5 %. GraphPad 6.0 was used to perform all tests.

■ Results

Alkaline phosphatase analyses and nicotine/cotinine detection and quantification

This objective to evaluate the effect of nicotine on the osseointegration process data was obtained related to activity of nicotine, cotinine and alkaline phosphatase.

The plasmatic levels of nicotine and cotinine were 0.5 ± 0.28 ng/mL and 9.5 ± 6.51 ng/mL, respectively. The cotinine concentrations were about twenty times higher than the nicotine concentrations. There was a high (Pearson test, $r = 0.9413$) and significant ($p = 0.0015$) correlation between nicotine concentrations (Figure 2).

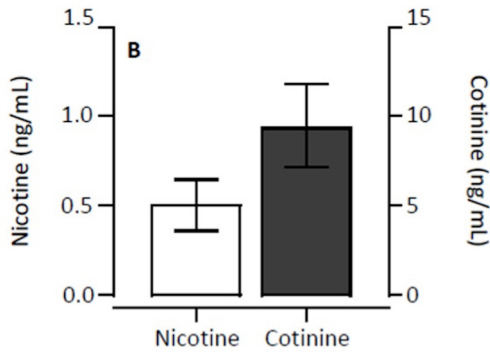


Figure 2 - Nicotine and cotinine plasmatic concentration mean (median and standard deviation).

The alkaline phosphatase analyses in blood levels, in control group was observed 40.8 ± 11.88 UI/L and 40.75 ± 12.46 UI/L, for the implant surfaces machined and anodized, respectively. In the test group was observed levels 37.9 ± 4.84 UI/L, for both implant surfaces. No significant differences were observed between control and test groups ($p = 0.402$) and between the implant surfaces ($p = 0.999$) regarding alkaline phosphatase blood levels (Figure 3).

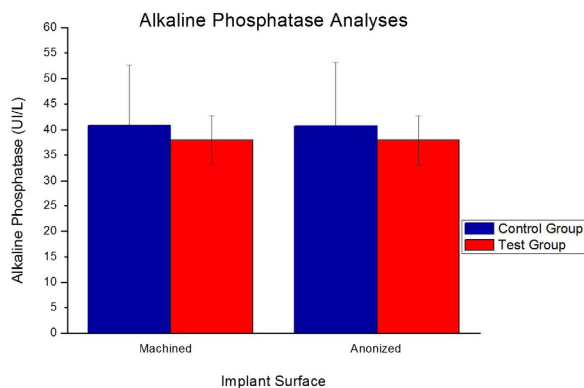


Figure 3 – Alkaline phosphatase analyses (median and standard deviation).

Biomechanical analysis - Removal torque measurement

To evaluate the osseointegration intergroups and between the surfaces of the implants was used the removal torque. The torque values (in Ncm) used in (control and test) considering the surface of each implant (machined - right tibia and Anodized-left tibia) in the rabbits of both groups.

The Figure 4 shows the torque force for implant removal. No significant differences were observed in control group between the machined (25 ± 8.46 Ncm) or anodized (31.2 ± 6.76 Ncm) implants ($p > 0.05$). However, the treatment with nicotine induced higher torque than control in both machined (38.3 ± 13.52 Ncm) and anodized (35.5 ± 14.17 Ncm) implants, with $p = 0.0024$ and $p = 0.0121$, respectively.

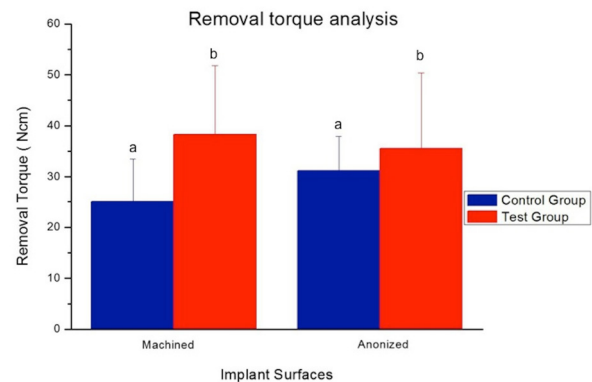


Figure 4 – Torque force for implant removal according to the groups. Similar letters shows significant differences ($p < 0.05$) between control and test.

Correlations analyses

Considering both implants together (machined and anodized), no significant correlation was observed between torque and

alkaline phosphatase, nicotine and cotinine. Torque force showed moderate and significant correlation with nicotine ($r=0.51$, $p=0.0012$) and cotinine ($r=0.40$, $p=0.0140$), but not with alkaline phosphatase. However, the correlation between torque was higher for machined implants than the anodized ones, considering both nicotine ($r=0.72$, $p=0.0005$) and cotinine ($r=0.61$, $p=0.0056$). There was no significant correlation for anodized implants.

■ Discussion

The present study analyzed the influence of subcutaneous injection of nicotine in osseointegration of machined and anodized dental implants in tibia of rabbits. The results showed that low nicotine dose administration did not cause deleterious effects on bone healing and implant osseointegration, which is in agreement with other study¹⁴⁻¹⁵. Cotinine levels observed in the rabbits after the daily doses of nicotine were equivalent to concentrations observed in light smokers (less than 10 ng/mL)¹⁶⁻¹⁷, which did not reproduce the negative impact of cigarette around titanium implants. According to Cesar-Neto *et al.*¹⁸ subcutaneous administration of nicotine (3 mg/kg) three times a day, did not influence healing around implants.

Heavy smokers probably have high doses of cotinine in plasma at the time of implant insertion, however, other agents present in tobacco, may be responsible for the detrimental effects.

It was previously reported that daily nicotine injection to obtain constant and low cotinine levels in the blood does not influence the osseointegration^{12,17-19}, however, the objective of the study was to analyze if the implant topography surface can improve osseointegration. The reverse torque removal values are directly related to the contact bone/implant interface, bone density, quantity of

cortical bone around the torque after certain periods. There was no significant differences between the torques induced by machined and anodized surfaces of test groups in the present experiment, which is in agreement with others reports⁵⁻¹⁹. Likewise, no difference was observed in the control groups. Balatsouka *et al.*¹⁷ also found no interference of 15 mg/day nicotine administered via miniosmotic pump in the osseointegration. Although no statistically differences between groups were observed, the results may suggest that bone formation occurred to a higher and faster extent directly on oxidized, but not on machined implants surfaces^{12,20-21} suggesting possible osteogenesis.

Other clinical assays also showed better primary stability and secondary stability for oxidized surface titanium implants when compared with machined surface implants^{5,11,13}. These differences can be explained by the interaction between growth/hormone factors and rougher surface topography that favor cellular differentiation and mineralization. This beneficial effect of rough surfaces in osseointegration has been confirmed by experimental and clinical studies^{14,20,22}.

In addition, low concentrations of nicotine showed a stimulatory effect on cell replication, especially at low concentrations (0.025 μM), it had a significant stimulatory effect on fibroblast proliferation²² as well as in human osteoblast-like cells²³, which could explain the higher torque necessary to remove the implants in nicotine than in control group found in the present study.

The level of alkaline phosphatase in blood is an indicator of bone formation²⁴. In the present study, the low daily doses of nicotine did not cause significant alterations in the alkaline phosphatase levels. Previous studies have showed that the implant superficial roughness also did not influence alkaline phosphatase serum levels²⁵⁻²⁶. The

heterogeneous oxide seems to have a slightly improved bone response, particularly in the first weeks after implantation²¹. This difference was, however, not observed after longer healing periods²⁸, being similar to the present results found between anodized (35.5 ± 14.2 Ncm) and machined (38.3 ± 13.5 Ncm) implants of the test group.

More recently, Bain *et al.*⁶ reported no difference in failure rate implants in smokers when compared with nonsmokers. They attributed the high success rate (98.5 % for both groups) to a roughened implant surface, corroboration by other authors⁵. It appears that the use of implants with an altered surface microtopography has the potential to benefit patients with risk factors such as smoking. In addition, it appears that smoking does not play a significant role in achieving osseointegration of surface-modified dental implants. Thus, titanium oxide-enriched implants may be more suitable for use under challenging conditions involving compromised bone⁵⁻⁶.

Further studies are necessary to define clearly the relationship between the characteristics of an ideal implant surface and the healing process. In particular, it is important to know the effects of local factors and hormones on the cell responses to the implant surface. This new information will help us to achieve better clinical results in implant placement in patients with continuing smoking habits and the impact of the implant surface is currently under investigation.

■ Conclusion

Subcutaneous low dose injection of nicotine during 8 weeks following implant insertion did not have effect on osseointegration, independently from the implant surface.

■ References

1. Nitzan D, Mamlider A, Levin L, Schwartz-Arad D. Impact of smoking on marginal bone loss. *Int J Oral Maxillofac Implants.* 2005;20:605-9. PMID: 16161745.
2. Berley J, Yamano S, Sukotjo C. The effect of systemic nicotine on osseointegration of titanium implants in the rat femur. *J Oral Implantol.* 2010;36:185-93. PMID: 20553172.
3. Snyder HB, Caughman G, Lewis J, Billman MA, Schuster G. Nicotine modulation of in vitro human gingival fibroblast beta1 integrin expression. *J Periodontol.* 2002;73:505-10. PMID: 12027252.
4. McGrath J, McDonald JW, Macdonald JK. Transdermal nicotine for induction of remission in ulcerative colitis. *Cochrane Database Syst Rev.* 2004:CD004722. PMID: 15495126.
5. Rocci A, Martignoni M, Gottlow J. Immediate loading of Branemark System TiUnite and machined-surface implants in the posterior mandible: a randomized open-ended clinical trial. *Clin Implant Dent Relat Res.* 2003;5 Suppl 1:57-63. PMID: 12691651.
6. Bain CA, Weng D, Meltzer A, Kohles SS, Stach RM. A meta-analysis evaluating the risk for implant failure in patients who smoke. *Compend Contin Educ Dent.* 2002;23:695-702. PMID: 12244737.
7. Jaffin RA, Berman CL. The excessive loss of Branemark fixtures in type IV bone: a 5-year analysis. *J Periodontol.* 1991;62:2-4. PMID: 2002427.
8. Albrektsson T, Wennerberg A. Oral implant surfaces: Part 1--review focusing on topographic and chemical properties of different surfaces and in vivo responses to them. *Int J Prosthodont.* 2004;17:536-43. PMID: 15543910.
9. Sykaras N, Iacopino AM, Marker VA, Triplett RG, Woody RD. Implant materials, designs, and surface topographies: their effect on osseointegration. A literature review. *Int J Oral Maxillofac Implants.* 2000;15:675-90. PMID: 11055135.
10. Zhu X, Chen J, Scheideler L, Reichl R, Geis-Gerstorfer J. Effects of topography and composition of titanium surface oxides on osteoblast responses. *Biomaterials.* 2004;25:4087-03. PMID: 15046900.

11. Bahat O. Technique for placement of oxidized titanium implants in compromised maxillary bone: prospective study of 290 implants in 126 consecutive patients followed for a minimum of 3 years after loading. *Int J Oral Maxillofac Implants.* 2009;24:325-34. PMID: 19492649.
12. Palma VC, Magro-Filho O, de Oliveria JA, Lundgren S, Salata LA, Sennerby L. Bone reformation and implant integration following maxillary sinus membrane elevation: an experimental study in primates. *Clin Implant Dent Relat Res.* 2006;8:11-24. PMID: 16681489.
13. Albrektsson TJC, Lundgren AK, Sul Y, Gottlow J. Experimental Studies on oxidized implants. A histomorphometric and biomechanical analysis. *Appl Osseointegration Res.* 2000;1:21-4.
14. Duygulu F, Karaoğlu S, Zeybek ND, Kaymaz FF, Güneş T. The effect of subcutaneously injected nicotine on achilles tendon healing in rabbits. *Knee Surg Sports Traumatol Arthrosc.* 2006;14:756-61. PMID: 16465534.
15. Santos PL, Molon RS, Queiroz TP, Okamoto R, Faloni APS, Gulinelli JL, Luvizuto ER, Garcia-Junior IR. Evaluation of bone substitutes for treatment of peri-implant bone defects: biomechanical, histological, and immunohistochemical analyses in the rabbit tibia. *J Periodontal Implant Sci.* 2016 Jun;46(3):176-96. PMID: 27382506.
16. Linden MSS, Paranhos LR, De Carli JP, Trentin MS, de Bittencourt ME, Santos PL, Groppo FC, Ramacciato JC. Influence of nicotine on machined- and anodized-surface implants. Histometric analysis. *J Clin Exp Dent.* 2017;9(10):e1207-11. PMID: 29167710.
17. Balatsouka D, Gotfredsen K, Lindh CH, Berglundh T. The impact of nicotine on osseointegration. An experimental study in the femur and tibia of rabbits. *Clin Oral Implants Res.* 2005;16:389-95. PMID: 16117761.
18. César-Neto JB, Duarte PM, Sallum EA, Barbieri D, Moreno H, Nociti FH. A comparative study on the effect of nicotine administration and cigarette smoke inhalation on bone healing around titanium implants. *J Periodontol.* 2003;74:1454-9. PMID: 14653391.
19. Alam AA, Nowzari H. Clinical evaluation of dental implants with surfaces roughened by anodic oxidation, dual acid-etched implants, and machined implants. *Int J Oral Maxillofac Implants.* 2005;20:793-8. PMID: 16274156.
20. Ivanoff CJ, Widmark G, Johansson C, Wennerberg A. Histologic evaluation of bone response to oxidized and turned titanium micro-implants in human jawbone. *Int J Oral Maxillofac Implants.* 2003;18:341-8. PMID: 12814308.
21. Shibli JA, Grassi S, de Figueiredo LC, Feres M, Marcantonio E, Iezzi G. Influence of implant surface topography on early osseointegration: a histological study in human jaws. *J Biomed Mater Res B Appl Biomater.* 2007;80:377-85. PMID: 16850464.
22. Kallala R, Barrow J, Graham SM, Kanakaris N, Giannoudis PV. The in vitro and in vivo effects of nicotine on bone, bone cells and fracture repair. *Expert Opin Drug Saf.* 2013;12:209-33. PMID: 23410538.
23. Papaioannou KA, Markopoulou CE, Gioni V, Mamalis AA, Vayouraki HN, Kletsas D, Vrotsos IA. Attachment and proliferation of human osteoblast-like cells on guided bone regeneration (GBR) membranes in the absence or presence of nicotine: an in vitro study. *Int J Oral Maxillofac Implants.* 2011;26:509-19. PMID: 21691597.
24. Yuhara S, Kasagi S, Inoue A, Otsuka E, Hirose S, Hagiwara H. Effects of nicotine on cultured cells suggest that it can influence the formation and resorption of bone. *Eur J Pharmacol.* 1999;383:387-93. PMID: 10594333.
25. Sul YT, Johansson CB, Jeong Y, Röser K, Wennerberg A, Albrektsson T. Oxidized implants and their influence on the bone response. *J Mater Sci Mater Med.* 2001;12:1025-31. PMID: 15348359.
26. Sul YT, Johansson CB, Röser K, Albrektsson T. Qualitative and quantitative observations of bone tissue reactions to anodized implants. *Biomaterials.* 2002;23:1809-17. PMID: 11950051.
27. Larsson C, Emanuelsson L, Thomsen P, Ericson LE, Aronsson BO, Kasemo B, Lausmaa J. Bone response to surface modified titanium implants - studies on the tissue response after 1 year to machined and electropolished implants with different oxide thicknesses. *J Mater Sci Mater Med.* 1997;8:721-9. PMID: 15348780.

■ Acknowledgement

To Conexão® for supplying the materials.

Correspondence:

Pâmela Leticia dos Santos
Departamento de Ciências da saúde, Universidade de Araraquara
Rua Carlos Gomes, 1338
14801-340 Araraquara - SP Brasil
Tel.: (55 16)98154-1577
pamelasantos@hotmail.com

Received: Sep 08, 2017

Review: Nov 10, 2017

Accepted: Dec 11, 2017

Conflict of interest: none

Financial source: none

¹Research performed at Department of Dentistry, Universidade de Passo Fundo (UPF), RS, and Universidade Federal de Sergipe (UFSE), Lagarto-SE, Brazil.

