

Celiac disease and constipation: an uncommon atypical clinical manifestation

Doença celíaca e constipação: uma manifestação clínica atípica e pouco frequente

Enfermedad celíaca y constipación: una manifestación clínica atípica y poco frecuente

Cristiane Boé¹, Adriana Chebar Lozinsky¹, Francy Reis Patrício², Jacy Alves B. de Andrade³, Ulysses Fagundes-Neto⁴

ABSTRACT

Objective: To report two cases of patients with celiac disease (CD) whose main complaint was chronic constipation.

Case description: Two girls, aged 18 and 30 months, had chronic constipation refractory to standard treatment. Both patients concomitantly evidenced low weight gain and short stature. The investigation of the digestive-absorptive function was positive for IgA antibodies against tissue transglutaminase. The diagnosis of CD was confirmed by a small bowel biopsy that showed moderate/severe villous atrophy and increased intraepithelial lymphocytic infiltration. One month after starting the dietary treatment with a gluten-free diet, both patients recovered from constipation, with the passage of soft stools daily.

Comments: CD may be presented in the classical, asymptomatic or atypical forms. In the latter form, isolated manifestations, such as constipation, delay the diagnosis of the disease.

Key-words: constipation; celiac disease; child.

RESUMO

Objetivo: Relatar dois casos de doença celíaca (DC) com manifestação de constipação.

Descrição do caso: Dois pacientes do sexo feminino, com 18 e 30 meses de idade, respectivamente, apresentando história de constipação crônica refratária ao tratamento. Como apresentavam concomitantemente baixo ganho ponderal e estatural, foi realizada investigação da função digestiva-absorptiva, que resultou positiva para o anticorpo IgA antitransglutaminase tecidual. O diagnóstico de DC foi confirmado por biópsia de intestino delgado que revelou atrofia vilositária moderada/intensa e infiltrado linfocítico intraepitelial. Um mês após o início do tratamento com dieta isenta de glúten, ambas as pacientes passaram a apresentar fezes pastosas diariamente.

Comentários: A DC pode se apresentar nas formas clássica, assintomática e atípica, em que manifestações isoladas como constipação podem retardar o diagnóstico.

Palavras-chave: constipação intestinal; doença celíaca; criança.

RESUMEN

Objetivo: Relatar dos casos de enfermedad celíaca (EC) con manifestación de constipación.

Descripción del caso: Dos pacientes del sexo femenino, con 18 y 30 meses de edad, respectivamente, presentando historia de constipación crónica refractaria al tratamiento. Como presentaban concomitantemente baja ganancia de peso

Instituição: Disciplina de Gastroenterologia do Departamento de Pediatria da Escola Paulista de Medicina da Universidade Federal de São Paulo (Unifesp), São Paulo, SP, Brasil

¹Residente da Disciplina de Gastroenterologia do Departamento de Pediatria da Escola Paulista de Medicina da Unifesp, São Paulo, SP, Brasil

²Doutora em Anatomia Patológica pela Escola Paulista de Medicina da Unifesp; Professora Associada do Departamento de Anatomia Patológica da Escola Paulista de Medicina da Unifesp, São Paulo, SP, Brasil

³Doutora em Gastroenterologia pelo Departamento de Pediatria da Escola Paulista de Medicina da Unifesp, São Paulo, SP, Brasil

⁴Doutor em Gastroenterologia e Pediatria pela Escola Paulista de Medicina da Unifesp; Professor Titular da Disciplina de Gastroenterologia do Departamento de Pediatria da Escola Paulista de Medicina da Unifesp, São Paulo, SP, Brasil

Endereço para correspondência:

Cristiane Boé
Rua Mavari, 111 – Mooca
CEP 03181-110 – São Paulo/SP
E-mail: cristianeboe@hotmail.com

Fonte financiadora: Bolsa Produtividade em Pesquisa – Conselho Nacional de Desenvolvimento Científico e Tecnológico (CNPq), Processo nº 304.150/2009-6

Conflito de interesse: nada a declarar

Recebido em: 27/5/2011

Aprovado em: 18/10/2011

ponderal y estatural, se realizó investigación de la función digestiva-absortiva, que resultó positiva para el anticuerpo IgA antitransglutaminasa tejdual. El diagnóstico de EC fue confirmado por biopsia de intestino delgado que reveló atrofia vellositaria moderada/intensa e infiltrado linfocítico intraepitelial. Un mes después del inicio del tratamiento con dieta exenta de gluten, ambas pacientes pasaron a presentar heces pastosas diariamente.

Comentarios: La EC puede presentarse en la forma clásica, asintomática y atípica, en que manifestaciones aisladas como constipación pueden retardar el diagnóstico.

Palabras clave: constipación intestinal; enfermedad celíaca; niño.

Introduction

Celiac disease (CD) is a permanent intolerance to gluten that occurs in genetically susceptible individuals and is characterized by complete or partial atrophy of the mucosa of the proximal small bowel, hyperplasia of the intestinal crypts and intraepithelial lymphocytic infiltration, leading to malabsorption of dietary nutrients⁽¹⁾. CD is considered a chronic immune-mediated enteropathy⁽²⁾ and is closely associated with the major histocompatibility complex (MHC) class II molecules HLA-DQ2 and HLA-DQ8⁽³⁾.

Classical CD, described in 1888 by Samuel Gee in Sdepanian, Morais & Fagundes-Neto⁽³⁾, is characterized by chronic diarrhea, abdominal distension, weight loss and/or failure to thrive, vomiting, abdominal pain, irritability, and gluteal wasting⁽⁴⁾. Although this is still the most common form of CD, atypical and clinically silent presentations are being reported with increasing frequency.

Constipation is rarely described as an atypical manifestation of CD, particularly in pediatric patients. In 1972, Egan-Mitchell and McNicholl⁽⁵⁾ analyzed a series of 112 children with a diagnosis of CD and found that 12 (10.7%) had constipation. On the other hand, Sharma, Poddar and Yachha⁽⁶⁾ conducted a study of 18 children with suspected CD in 2007 and found that only one (4%) had constipation as an atypical manifestation.

Within this context, we report two cases of patients with CD who presented with the atypical manifestation of chronic constipation. This report was approved by the *Universidade Federal de São Paulo* School of Medicine Research Ethics Committee.

Case description

Case 1

A 36-month-old girl presented with an 18-month history of constipation. The patient had been receiving follow-up at the Hospital São Paulo Department of Orthopedics due to a history of “chronic recurrent torticollis” (sic). Due to a concomitant complaint of chronic constipation, she was referred to our service, the Department of Pediatric Gastroenterology of the aforementioned hospital. According to her mother, the patient began to exhibit difficulty with bowel movements at the age of 18 months, with passage of hardened, thick, sausage-shaped stools with cracks on the surface. The patient strained and reported pain during bowel movements, and stools were occasionally coated with strands of bright red blood. These symptoms had thus far been managed unsuccessfully with administration of low-dose lactulose and periodic use of glycerin suppositories.

The patient had been exclusively breastfed until age 6 months. Throughout this period, she reportedly had two to three bowel movements per day, passing soft stools with no difficulty. At age 7 months, the patient was placed on a weaning diet consisting of whole cow’s milk and instant cereal (Mucilon® rice and oat formula) and gluten-containing solids (pasta). Relevant family history included a 6-year-old sibling with difficult-to-control epilepsy since age 3 years.

Physical examination revealed a weight of 11.4kg and height of 88.5cm (both within the 3rd percentile for age), mild pallor, and a palpable, hard mass extending across the left lower quadrant and left flank. Inspection of the anus revealed no abnormalities. A small amount of hardened stools was present in the rectal vault.

The following diagnostic hypotheses were considered: wasting and stunting (z scores: weight-for-age, -1.9; height-for-age, -1.6; weight-for-height, -1.5), chronic constipation, and iron deficiency anemia. A comprehensive workup was requested (complete blood count, serum iron and ferritin, thyroid-stimulating hormone and free thyroxine, urinalysis and urine culture, stool ova and parasites, and plain abdominal radiographs). A monosodium/disodium phosphate (Fleet®) enema was prescribed for fecal disimpaction, followed by maintenance lactulose (Lactulona®), 2mL/kg/day.

The patient returned one month later for follow-up. There had been no improvement in constipation; however, the prescribed therapeutic regimen had not been

followed. Due to the patient's poor weight and height and low serum iron and ferritin levels (Table 1), further investigation with hydrogen breath testing after glucose, lactose, fructose, and lactulose loading was requested for assessment of digestive-absorptive function (Table 2), as were serum anti-tissue transglutaminase (tTG) antibody and immunoglobulin A (IgA) levels. Glucose, lactose, and lactulose load tests were within normal limits, with elevations in exhaled H₂ level <20ppm above fasting (baseline) levels. In the lactulose load test, an increase in exhaled H₂ levels is expected at 60 minutes, due to the non-absorbable nature of this carbohydrate (the elevated level reflects the fermentative action of the colonic flora). The fructose load test was indicative of fructose malabsorption, but not intolerance, as the patient did not exhibit any symptoms of the latter. As serum anti-tissue transglutaminase antibody levels were above normal (33.62 units; reference range, <20), an endoscopic small bowel biopsy was scheduled. The patient's serum IgA level was 111.1mg/dL (reference range, 24–190mg/dL). Histological examination of the biopsy specimen revealed patchy villous atrophy, diffuse intraepithelial lymphocytosis, and slightly increased lymphoplasmacytic infiltration of the lamina propria (Marsh stage 3A)⁽⁷⁾ (Figures 1 and 2). In view of these findings, a diagnosis of CD was

made and the patient was placed on a gluten-free diet. Within two months of dietary treatment, the patient was having daily bowel movements and passing soft stools.

Case 2

A 30-month-old girl presented with a history of chronic constipation and fecal soiling since age 27 months. According to the patient's mother, bowel movements were painful and occurred only once every five days; stools were large and hardened, but no blood or other pathological elements were present. Treatment with below-recommended doses of lactulose (Farlac[®]) had been attempted with no effect. The patient received mixed feeding until age 8 months and, during this period, had two to three daily bowel movements, passing soft stools with no difficulty. A solid diet was introduced at age 6 months, consisting of an age-appropriate cow's milk formula and age-appropriate solids as recommended by the child's pediatrician. Wheat-derived flour was introduced at this time. Relevant family history included a grandfather with Crohn's disease and mother with chronic constipation.

On physical examination, weight was 11.7kg and height was 92cm (z scores: weight-for-age, -1.37; height-for-age, -0.78; weight-for-height, -1.04). The patient appeared

Table 1 - Laboratory workup

Parameters	Case 1	Case 2	Reference range
Iron (mcg/dL)	32	85	37–170
Ferritin (ng/mL)	8.4	27.0	11.0–307.0
Thyroid-stimulating hormone (μUI/mL)	1.24	3.68	0.34–5.60
Thyroxine, free (ng/dL)	0.80	1.08	0.58–1.64
Stool, ova and parasites (three specimens)	Negative	–	Negative
Urinalysis	Normal	–	
Hemoglobin (g/dL)	11.5	13.5	12.0–15.5
Hematocrit (%)	35.0	42.2	35.0–45.0

Table 2 - Hydrogen breath testing – case 1

	Fructose	Lactose	Lactulose	Glucose
Fasting	0	4	1	0
15'	0	3	0	0
30'	10	0	0	0
45'	27	0	8	0
60'	36	14	27	1
90'	15	7	20	1
120'	10	10	12	0

Hydrogen breath test after glucose, fructose, lactose, and lactulose load. H₂ levels expressed as parts per million (ppm)

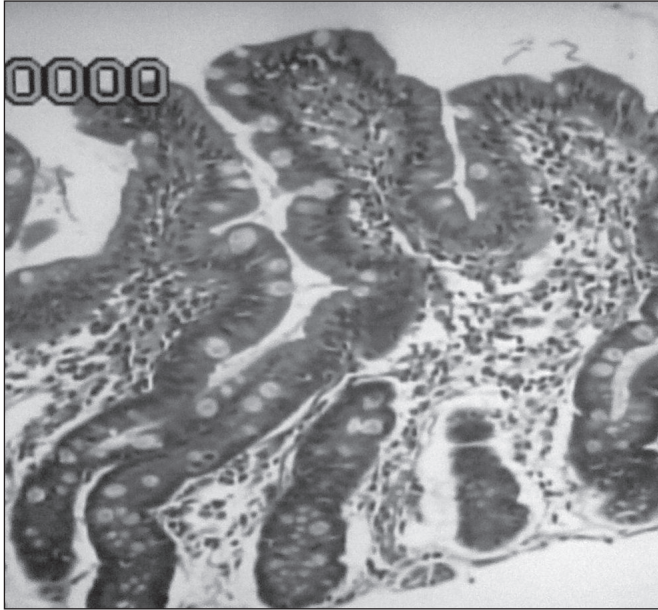


Figure 1 - Small bowel biopsy showing patchy villous atrophy, intraepithelial lymphocytosis, and slightly increased lymphoplasmacytic infiltrate in the lamina propria. H&E stain, original magnification 10x – case 1

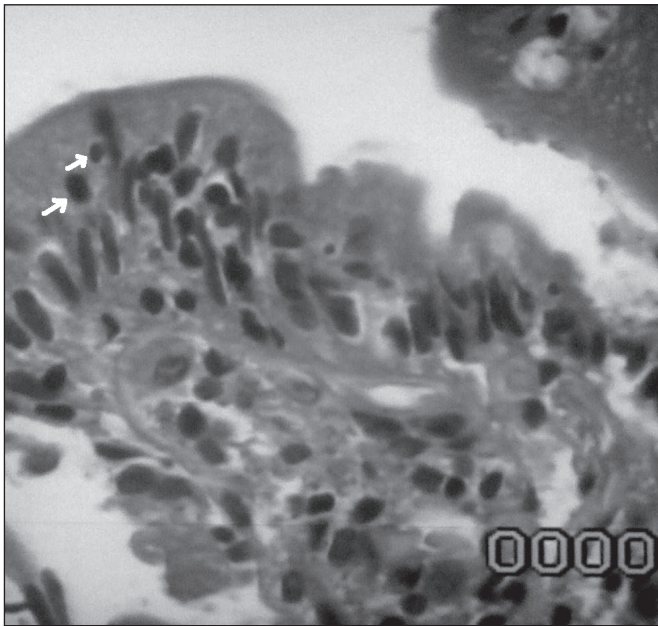


Figure 2 - Case 1. Small bowel biopsy showing abundant villous intraepithelial lymphocytes (arrows). H&E stain, original magnification 100x – case 1

emaciated and had abdominal distension with a palpable mass in the left flank. The differential diagnosis included underweight and chronic constipation. Plain abdominal radiographs revealed gas and stool buildup throughout

the colon and an apparent fecal mass retained in the rectal vault. A phospho-soda enema was prescribed for home disimpaction, followed by maintenance lactulose (2mL/kg/day) and mineral oil (2mL/kg/day). As the patient continued to exhibit constipation and growth restriction one year after initial presentation (weight 13.1 kg; height 98 cm; weight-for-age z score, -1.07), further investigations were requested (complete blood count, thyroid-stimulating hormone, free thyroxine, and ferritin) (Table 1). A CD serological screening panel was also requested, consisting of the following tests: anti gliadin antibodies (AGA), IgA and IgG; antiendomysial antibodies (EMA); anti-tTG antibodies; and HLA-DQ2 and DQ8 typing.

Celiac serology was positive, to wit: EMA titers, 1:320 (reference range, nonreactive); IgA-AGA, 9.9 (reference range, ≥ 1); IgG-AGA, 3.6 (reference range, ≥ 3); anti-tTG, 165; HLA-DQ2, positive. In view of these findings, an endoscopic duodenal biopsy was performed. Gross examination revealed the mosaic or “cracked-mud” duodenal mucosal pattern indicative of CD. Histological examination under conventional light microscopy showed moderate villous atrophy, a substantial increase in the number of intraepithelial lymphocytes, increased lymphoplasmacytic infiltration of the lamina propria, and crypt hyperplasia (Marsh stage 2)⁽⁷⁾. The patient was instructed to follow a gluten-free diet. After one month of dietary management, constipation had resolved completely.

Discussion

CD is a permanent, immune-mediated intolerance to gluten⁽²⁾. In Europe and the United States, the prevalence of CD ranges from 1 in 100 to 1 in 200⁽⁴⁾. In a study of blood donors from the city of São Paulo, Brazil, Oliveira *et al*⁽⁸⁾ showed that CD should not be considered a rare disease, as its prevalence in the city was at least 1 in 214 population.

In addition to the classic form of CD, the other recognized forms of this disease are: 1) asymptomatic or clinically silent – typical gluten-sensitive enteropathy, with no clinical manifestations. Most of these patients are first-degree relatives of persons with CD and insulin-dependent diabetics⁽⁴⁾; 2) nonclassical or atypical – characterized by one or few presenting symptoms, with onset in late childhood; patients may present with isolated manifestations such as short stature, treatment-refractory iron deficiency anemia, arthritis or arthralgia, epileptic

seizures, enamel hypoplasia, dermatitis herpetiformis, elevated transaminases, precocious puberty, recurring abdominal pain, and constipation⁽⁴⁾. Constipation is consistently cited as one of the presenting symptoms of atypical CD, particularly in review articles; however, it has only rarely been described (with supporting evidence) as a symptom of CD in the literature.

Our extensive review of the literature yielded only two articles describing constipation as a symptom of CD in children^(5,6). These rare descriptions of constipation as an atypical manifestation of CD led Hungerford⁽⁹⁾, in 1996, to write a letter to the editor of *Australian Family Physician* in which he revealed his disappointment with the paucity of reports of this symptom in pediatric patients, as, in his personal experience, chronic constipation was not unusual in adult patients with CD.

CD is increasingly recognized in adults with no presenting complaints of diarrhea. An ever greater percentage of patients are asymptomatic; diagnosis is often made during screening. Atypical forms of the disease are becoming more common⁽¹⁰⁾. The North American Society for Pediatric Gastroenterology, Hepatology and Nutrition recommends that CD be considered in the differential diagnosis of children with persistent gastrointestinal symptoms, including recurring abdominal pain, constipation, and vomiting⁽¹¹⁾. In 2007, a multicenter U.S. study showed that more widespread CD screening could increase detection of the disease

in the country⁽¹²⁾. In this study, conducted between 2002 and 2004, 22 cases of CD were diagnosed in a sample of 976 subjects, four of whom reported constipation. This represented a very significant leap in the number of new cases from 0.27 per 1,000 to 11.6 per 1,000 screened.

Both patients described in this case report had chronic constipation and negative weight and height z scores. It is common knowledge that chronic constipation is highly prevalent among pediatric patients seeking specialized gastroenterology care, and that the vast majority of these cases are of functional etiology. However, when constipation presents alongside a variety of red flags, including compromised nutritional status, it should be regarded as an indication of in-depth diagnostic studies. In both patients described herein, constipation and signs of undernutrition persisted during outpatient follow-up, which prompted assessment of digestive-absorptive function, leading to a diagnosis of CD.

To conclude, it bears stressing that CD may present in a variety of forms, namely: classical or symptomatic, asymptomatic, and atypical. Although there have been few descriptions of chronic constipation as a symptom of CD, the prevalence of this atypical manifestation does not appear to be negligible. Therefore, it is essential that healthcare providers be aware of it as a possible atypical presenting symptom of CD and pursue relevant investigations when the disease is suspected.

References

1. Sdepanian VL, Morais MB, Fagundes-Neto U. Celiac disease: clinical characteristics and methods used in the diagnosis of patients registered at the Brazilian Celiac Association. *J Pediatr (Rio J)* 2001;77:131-8.
2. Autoria não referida. National Institutes of Health Consensus Development Conference Statement on Celiac Disease, June 28-30, 2004. *Gastroenterology* 2005;128 (4 Suppl 1):S1-9.
3. Sdepanian VL, Morais MB, Fagundes-Neto U. Celiac disease: evolution in knowledge since its original centennial description up to the present day. *Arq Gastroenterol* 1999;36:244-57.
4. Fasano A. Clinical presentation of celiac disease in the pediatric population. *Gastroenterology* 2005;128:S68-73.
5. Egan-Mitchell B, McNicholl B. Constipation in childhood coeliac disease. *Arch Dis Child* 1972;47:238-40.
6. Sharma A, Poddar U, Yachha SK. Time to recognize atypical celiac disease in Indian children. *Indian J Gastroenterol* 2007;26:269-73.
7. Oberhuber G, Granditsch G, Vogelsang H. The histopathology of coeliac disease: time for a standardized report scheme for pathologists. *Eur J Gastroenterol Hepatol* 1999;11:1185-94.
8. Oliveira RP, Sdepanian VL, Barreto JA, Cortez AJ, Carvalho FO, Bordin JO et al. High prevalence of celiac disease in Brazilian blood donor volunteers based on screening by IgA antitissue transglutaminase antibody. *Eur J Gastroenterology Hepatol* 2007;19:43-9.
9. Hungerford C. Constipation can be a sign of coeliac disease. *Aust Fam Physician* 1996;25:802-3.
10. Rampertab SD, Pooran N, Singh P, Green PH. Trends in clinical presentation of celiac disease in the US over the last fifty years. *Gastroenterology* 2003; 124 (Suppl 1):A659.
11. Hill ID, Dirks MH, Liptak GS, Colletti RB, Fasano A, Guandalini S et al. Guideline for the diagnosis and treatment of celiac disease in children: recommendations of the North American Society for Pediatric Gastroenterology, Hepatology and Nutrition. *J Pediatr Gastroenterol Nutr* 2005;40:1-19.
12. Catassi C, Kryszak D, Louis-Jacques O, Duerksen DR, Hill I, Crowe SE et al. Detection of celiac disease in primary care: a multicenter case-finding study in North America. *Am J Gastroenterol* 2007;102:1454-60.