

Tonsillar lymphoma in children with unilateral tonsillar enlargement

Linfoma tonsilar em crianças com assimetria tonsilar

Linfoma tonsilar en niños con asimetría tonsilar

Alexandre Caixeta Guimarães¹, Guilherme Machado de Carvalho², Reinaldo Jordão Gusmão³

ABSTRACT

Objective: To demonstrate the importance of a medical examination with emphasis on changes of the palatine tonsils (PT) and proper anamnesis to early identify patients with tonsillar lymphoma.

Case description: Case 1 – 5-year-old girl with a muffled voice noted by her mother and a report of “feeling a strange sensation in the throat” for two weeks. She was previously treated in another service at the beginning of the symptoms with amoxicillin without improvement. An important increase in the right PT was noted, with smooth surface and absence of crypts. The diagnosis of non-Hodgkin lymphoma (NHL) was confirmed after surgery. On further investigation, positive mesenteric lymph nodes were noted. Case 2 – 11-year-old girl came to the emergency service to investigate a painless nodule in the left palatine tonsil with progressive growth for one year, without other complaints. She had previously undergone other medical consultations, but no importance was given to the patient’s complaint. Oroscopy showed that the left PT was increased crossing the midline and with a nodule in the upper pole. Patient also had NHL.

Comments: A detailed examination of the oral cavity and neck is essential to identify suspicious tonsillar lymphoma. Patients with unilateral tonsillar enlargement and other findings suggestive of malignancy should undergo tonsillectomy.

Key-words: palatine tonsil; child; lymphoma.

RESUMO

Objetivo: Demonstrar a importância do exame físico com ênfase nas alterações das tonsilas palatinas (TP) e na anamnese direcionada para a identificação precoce de pacientes com linfoma de TP.

Descrição do caso: Caso 1 – Menina de cinco anos com voz abafada, observada pela mãe, e “sensação de algo estranho na garganta” há duas semanas. Foi atendida em outro serviço no início do quadro, sendo medicada com amoxicilina, sem melhora. Apresentava aumento importante da TP direita com superfície lisa e ausência de criptas. Após cirurgia, foi confirmado o diagnóstico de linfoma não Hodgkin (LNH). Na investigação também foi identificado acometimento dos linfonodos mesentéricos pelo linfoma. Caso 2 – Menina de 11 anos procurou o pronto-socorro para investigar nódulo em TP esquerda, indolor, de crescimento progressivo há um ano, sem outras queixas. Já havia passado por consultas médicas anteriores, não tendo sido valorizada a queixa da paciente. A TP esquerda encontrava-se aumentada, ultrapassando a linha média e com nódulo no polo superior. Também foi diagnosticado LNH após exame anatomopatológico.

Comentários: Um exame minucioso da cavidade oral e do pescoço é essencial para identificar alterações suspeitas de linfoma tonsilar. Pacientes com assimetria tonsilar e outros achados sugestivos de malignidade devem ser submetidos à tonsilectomia.

Palavras-chave: tonsila palatina; criança; linfoma.

Instituição: Departamento de Otorrinolaringologia, Cabeça e Pescoço do Hospital da Universidade Estadual de Campinas (Unicamp), Campinas, SP, Brasil

¹Médico Residente em Otorrinolaringologia da Disciplina de Otorrinolaringologia, Cabeça e Pescoço da Faculdade de Ciências Médicas da Unicamp, Campinas, SP, Brasil

²Mestre em Medicina pela Faculdade de Ciências Médicas da Universidade Nova de Lisboa, Lisboa; Médico Residente em Otorrinolaringologia da Disciplina de Otorrinolaringologia, Cabeça e Pescoço da Faculdade de Ciências Médicas da Unicamp, Campinas, SP, Brasil

³Doutor em Ciências Médicas pela Unicamp; Chefe do Serviço de Otorrinolaringologia Pediátrica da Unicamp e do Departamento de Oftalmologia/Otorrinolaringologia da Faculdade de Ciências Médicas da Unicamp, Campinas, SP, Brasil

Endereço para correspondência:

Alexandre Caixeta Guimarães
Rua José Ponchio Vizzari, 303 – Barão Geraldo
CEP 13085-170 – Campinas/SP
E-mail: alecxl2@hotmail.com

Conflito de interesse: nada a declarar

Recebido em: 1/9/2011

Aprovado em: 28/11/2011

RESUMEN

Objetivo: Demostrar la importancia de un examen físico con énfasis en las alteraciones de las tonsilas palatinas (TP) y en la anamnesis dirigida a la identificación temprana de pacientes con linfoma de TP.

Descripción del caso: Caso 1 – Niña de cinco años, con voz velada, observada por la madre, y «sensación de algo extraño en la garganta» hace dos semanas. Fue atendida en otro servicio en el inicio del cuadro, siendo medicada con amoxicilina, sin mejora. Presentaba aumento importante de la TP derecha con superficie lisa y ausencia de criptas. Después de la cirugía, se confirmó el diagnóstico de linfoma no Hodgkin (LNH). En la investigación también se identificó acometimiento de los nodos linfáticos mesentéricos por el linfoma. Caso 2 – Muchacha de 11 años buscó al servicio de urgencia para investigar nódulo en TP izquierda, indolora, de crecimiento progresivo hace un año, sin otras quejas. Ya había pasado por consultas médicas anteriores, no habiendo sido valorizada la queja de la paciente. La TP izquierda se encontraba aumentada, sobrepasando la línea media y con nódulo en el polo superior de esa. También se diagnosticó LNH después de examen anatomopatológico.

Comentarios: Un examen minucioso de la cavidad oral y del cuello es esencial para identificar alteraciones sospechosas de linfoma tonsilar. Pacientes con asimetría tonsilar y otros hallazgos sugestivos de malignidad deben ser sometidos a tonsilectomía.

Palabras clave: tonsila palatina; niño; linfoma.

Introduction

Palatine tonsils (PTs) are important tissues of the Waldeyer's tonsillar ring, located at the transition between the oral and nasal cavities in the oropharynx. PTs are symmetrically and laterally located in the tonsillar fossae. They are composed of bodies of lymphoid tissue between the palatoglossal and palatopharyngeal arches (anterior and posterior pillars of the fauces, respectively). Their lower limit is the base of the tongue. PTs have an important immune function.

Unilateral enlarged PT caused by repeated tonsillitis, chronic tuberculosis infections, actinomycosis, anatomical variations with changes in the tonsillar fossa depth or asymmetric anterior pillar, and benign and malignant tumors is a common finding of clinical examinations during medical visits^(1,2).

According to a study by Sengupta, lymphomas are the most common malignant tumors of the head and neck in the pediatric population. And non-Hodgkin lymphoma (NHL) was the most

common type of tonsillar malignancy⁽³⁾. The most common presentation of NHL is painful cervical lymphadenopathy. Extranodal involvement is more common in NHL than in cases of Hodgkin's lymphoma, mainly in PT⁽⁴⁾. In children with AIDS, lymphoma is the most frequent tumor, especially in cases of enhanced growth⁽⁵⁾.

This high prevalence of lymphomas in PT among the pediatric malignancies, their high morbidity and mortality, and the impact of early treatment on the progression of the disease warrant the presentation of these clinical cases with the purpose of demonstrating the importance of a physical examination focused on changes in the PT and anamnesis leading to the early diagnosis of these cases.

In the present manuscript, we report on two cases of tonsillar lymphoma in children showing tonsil asymmetry treated at the Service of Pediatric Otorhinolaryngology of Hospital das Clínicas of Universidade Estadual de Campinas (Unicamp). This study was approved by the Research Ethics Committee of the School of Medical Sciences of Unicamp, in compliance with all conditions of the Resolution n. 196/96 and complementary resolutions.

Case report

Case 1

A 5-year-old Caucasian female patient was taken to the pediatric emergency department by her mother because of a change in her voice pattern (muffled voice). The patient reported feeling something "weird" in her throat for the past two weeks. She was asymptomatic before that. During medical examination, the patient reported nocturnal snoring, some episodes of apnea, nighttime awakenings, reduced appetite, and 0.5kg weight loss in the past two weeks. She did not present with fever, odynophagia, or significant difficulty swallowing. Upon onset of symptoms, she was seen at another health care facility and received amoxicillin, without symptom resolution. The emergency department pediatrician found enlarged PT and referred the patient to assessment by the otorhinolaryngology team. During oral clinical examination, physicians found significantly enlarged right PT, showing a smooth surface and no crypts, without signs of inflammation, crossing the midline and in contact with the left tonsil, which showed normal size (Figure 1). Both rhinoscopy and otoscopy showed no abnormalities. Neck palpation did not detect palpable masses or lymph nodes. Blood test showed presence of 12,040 leukocytes/mL, without lymphocytosis. Computed tomography of the neck showed enlarged right PT, no tracheal deviation, absence of abscesses or lymph node enlargement (Figure 2). The

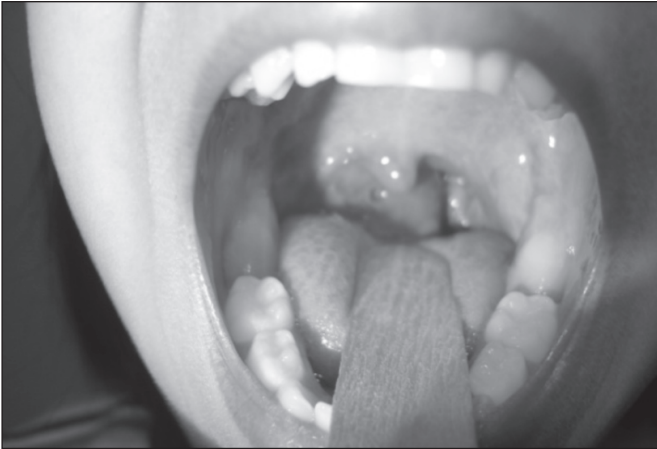

Figure 1 - Oral clinical examination performed in patient 1 during medical visit: remarkable asymmetry of size and shape of the right palatine tonsil, crossing the midline

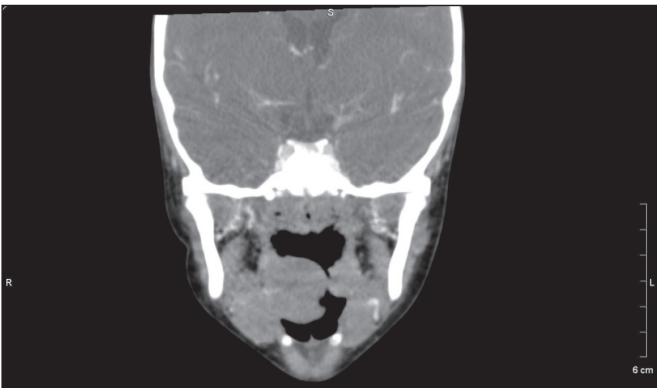


Figure 2 - Coronal section of computed tomography of patient 1: evident asymmetry of the palatine tonsils

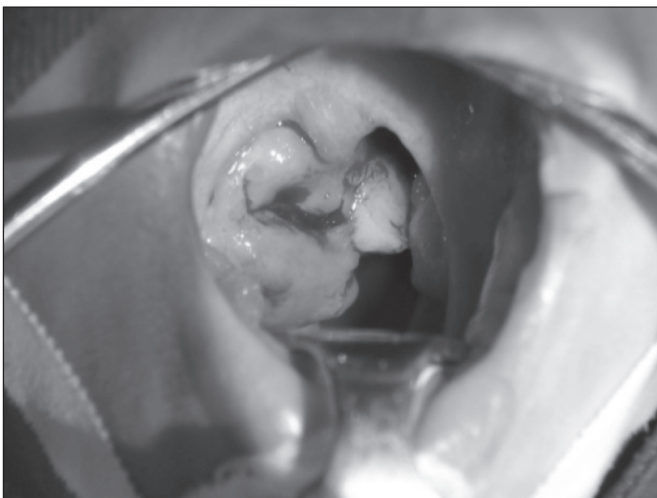


Figure 3 - Intraoperative oral examination of patient 1: oral examination is facilitated by the use of surgical instruments making asymmetry more evident; a lobulated lesion is also visible in the upper portion of the right palatine tonsil, which had not been identified previously

patient underwent adenotonsillectomy (Figure 3). The result of the anatomic pathology test was diffuse large B-cell NHL in the right PT. The adenoid vegetations and the left tonsil did not show abnormalities on the anatomic pathology test. Chest X-rays, gallium scintigraphy, bone marrow biopsy, myelogram, CSF collection, cervical and chest CT showed no evidence of abnormalities. Total abdominal CT revealed onion skin-like image in the right iliac fossa, which was suggestive of ileoileal intussusception. Abdominal ultrasound showed image compatible with these findings, as well as the presence of three enlarged mesenteric lymph nodes. The patient underwent laparoscopy and biopsies of the terminal ileum and mesenteric lymph nodes, which also showed NHL. After being treated with chemotherapy, the patient has been in clinical remission, showing reduced abdominal mass according to the imaging tests.

Case 2

An 11-year-old Caucasian female patient was taken to the emergency department because of a painless nodule in the left PT, which had been growing for the past year. She reported absence of dyspnea, snoring, previous tonsillitis, or other complaints. She had been seen by medical doctors before, but her complaint was not deeply investigated. The emergency department pediatrician found asymmetric PTs and requested a referral for investigation of the finding because assessments by the otorhinolaryngology team were easily available at our health care facility. Oral clinical examination showed enlarged left PT, crossing the midline and the presence of a hardened nodule of about 1.5cm in diameter in the upper portion of the tonsil. The right PT showed no abnormalities. Similarly, rhinoscopy and otoscopy did not detect any abnormal results. Neck palpation did not reveal palpable masses or lymph nodes. The following tests were performed: chest X-ray, gallium scintigraphy, bone marrow biopsy, myelogram, CSF collection, cervical, chest and abdominal CT, which also showed no abnormalities. The patient underwent bilateral tonsillectomy. The result of the anatomic pathology test revealed diffuse large B-cell NHL. Chemotherapy was initiated, and the patient's remission was established based on clinical examinations and imaging tests.

Discussion

In the present article, we report on the cases of two patients who sought medical care in an emergency department because of unilateral enlarged PT. Such abnormality led the emergency department pediatricians to refer the patients to otorhinolaryngological assessment. Although the symptoms of the first case

started only two weeks earlier, her lymphoma had affected the mesenteric lymph nodes and the mucosa of terminal ileum; while in the second case, lymphoma was restricted to the PT. However, the clinical sign that led to the diagnostic hypothesis in both cases was unilateral enlarged PT.

It is important to stress that in the first case the child had been seen at another pediatric health care facility a couple of days earlier, and amoxicillin was prescribed to treat her tonsillar asymmetry. In this case, because there was absence of symptoms of infection of the pharynx and tonsils, such as exudate in the tonsils, painful cervical adenopathy, or fever, there was no need for the use of antibiotic therapy.

The second case also shows that the asymmetry and changes in the appearance of the tonsil were not considered in the absence of other findings, as the patients attended some medical visits without proper investigation.

Tonsillar asymmetry or suspicion of neoplasia is classically listed as one of the indications for tonsillectomy⁽⁶⁾. The incidence of malignancy in patients undergoing tonsillectomy is low (approximately 2.5:10,000)⁽⁷⁾.

Tobias Gómez *et al*⁽⁸⁾ conducted a study in which the risk factors associated with malignancy in children undergoing surgery because of tonsillar asymmetry were the presence of enlarged cervical lymph nodes and abnormal appearance of the tonsils. Among the patients who underwent surgery, 20% had tonsil cancer⁽⁸⁾. In a retrospective study conducted in Paraná involving children and adults, 50 patients underwent tonsillectomy because of tonsillar asymmetry and two adults had lymphoma, one of them with systemic symptoms, while the other one was asymptomatic. None of the children had lymphoma⁽⁹⁾.

Other factors should be considered before indication for tonsillectomy in children with unilateral tonsillar enlargement,

namely: previous history of malignancy, organ transplantation, and immunodeficiencies, which increase the risk for posttransplant lymphoproliferative disease (abnormal proliferation of lymphoid cells associated with the Epstein-Barr virus)⁽¹⁰⁾.

A study with 100 patients undergoing tonsillectomy because of asymmetric PT, in which 10 patients had a diagnosis of NHL, indicated tonsillectomy for fast growing enlarged PT showing abnormal appearance. Other factors suggested as signs of malignancy were: fever, night sweats, cervical, axillary, or inguinal lymph node enlargement, hepatosplenomegaly, and no response to clinical treatment⁽¹¹⁾.

A retrospective study conducted at a tertiary pediatric hospital covering a period of 57 years found six cases of tonsillar NHL, and all of these cases initially presented with unilateral tonsillar enlargement with no symptoms such as fever, night sweats, or weight loss. Other signs and symptoms were: tonsillar nodule, erythema, nasal voice, recurrent tonsillitis, dysphagia, obstructive sleep apnea, ipsilateral otalgia, and submandibular lymphadenopathy. All children with asymmetric PT should be closely followed up until the possibility of lymphoma is ruled out, and tonsillectomy should be indicated if there is suspicion, because the consequences of a late diagnosis can be devastating⁽¹²⁾.

A thorough examination of the oral cavity and the neck, with special attention to oral clinical examination is essential to identify changes suspicious of tonsillar lymphoma, which can be diagnosed early by means of tonsillectomy. We believe that the presence of evident unilateral tonsillar enlargement, lesion or change in the PT appearance, fast growth of a PT, presence of cervical lymph node enlargement, nocturnal fever, and weight loss are important risk factors for tonsillar lymphoma in children with tonsillar asymmetry.

References

1. Cinar F. Significance of asymptomatic tonsil asymmetry. *Otolaryngol Head Neck Surg* 2004;131:101-3.
2. Berkowitz RG, Mahadevan M. Unilateral tonsillar enlargement and tonsillar lymphoma in children. *Ann Otol Rhinol Laryngol* 1999;108:876-9.
3. Sengupta S, Pal R. Clinicopathological correlates of pediatric head and neck cancer. *J Cancer Res Ther* 2009;5:181-5.
4. Mohammadianpanah M, Omidvai S, Mosalei A, Ahmadloo N. Treatment results of tonsillar lymphoma: a 10-year experience. *Ann Hematol* 2005;84:223-6.
5. Gianvecchio RP, Tan DM, Yamamoto E, Rodrigues FC, Cunha GA, Baldelin CG. Burkitt's lymphoma in child with aids. *Rev Paul Pediatr* 2003;21:99-103.
6. Brodsky L, Poje CP. Tonsillite, tonsilectomia e adenoidectomia. In: Bailey BJ, Johnson JT, editors. *Otorrinolaringologia: cirurgia de cabeça e pescoço*. 4th ed. Philadelphia: Lippincott Williams & Wilkins; 2009. p. 161-4.
7. Sturn-O'Brien AK, Hicks JM, Giannoni CM, Sulek M, Friedman EM. Optimal utilization of histopathologic analysis of tonsil and adenoid specimens in the pediatric population. *Int J Pediatr Otorhinolaryngol* 2010;74:161-3.
8. Tobias Gómez S, Palomar Asenjo V, Borrás Perera M, Pérez Hernández I, Ruiz Giner A, Palomar García V. Clinical significance of unilateral tonsillar enlargement. *Acta Otorrinolaringol Esp* 2009;60:194-8.
9. Ballin AC, Koerner HN, Ballin CH, Pereira R, Alcântara LJ, Taques GR *et al*. Palatine tonsils asymmetry: 10 years experience of the Otorhinolaryngology service of the clinical hospital of the Federal University of Paraná. *Arq Int Otorrinolaringol* 2011;15:67-71.
10. Broughton S, McClay JE, Murray A, Timmons C, Sommerauer J, Andrews W *et al*. The effectiveness of tonsillectomy in diagnosing lymphoproliferative disease in pediatric patients after liver transplantation. *Arch Otolaryngol Head Neck Surg* 2000;126:1444-7.
11. Qi J, Fan X, Wang C, Ma J, Tang H. Unilateral tonsillar enlargement and malignant tonsillar lymphoma. *Lin Chuang Er Bi Yan Hou Ke Za Zhi* 2002;16:469-70.
12. Dolev Y, Daniel SJ. The presence of unilateral tonsillar enlargement in patients diagnosed with palatine tonsil lymphoma: experience at a tertiary care pediatric hospital. *Int J Pediatr Otorhinolaryngol* 2008;72:9-12.